PrepLadder

FMGE NOTES

FOR MORE FREE NOTES
AND EBOOKS VISIT
https://t.me/
Latestneetpgnotes

CLICK THIS PAGE
TO JOIN!!!

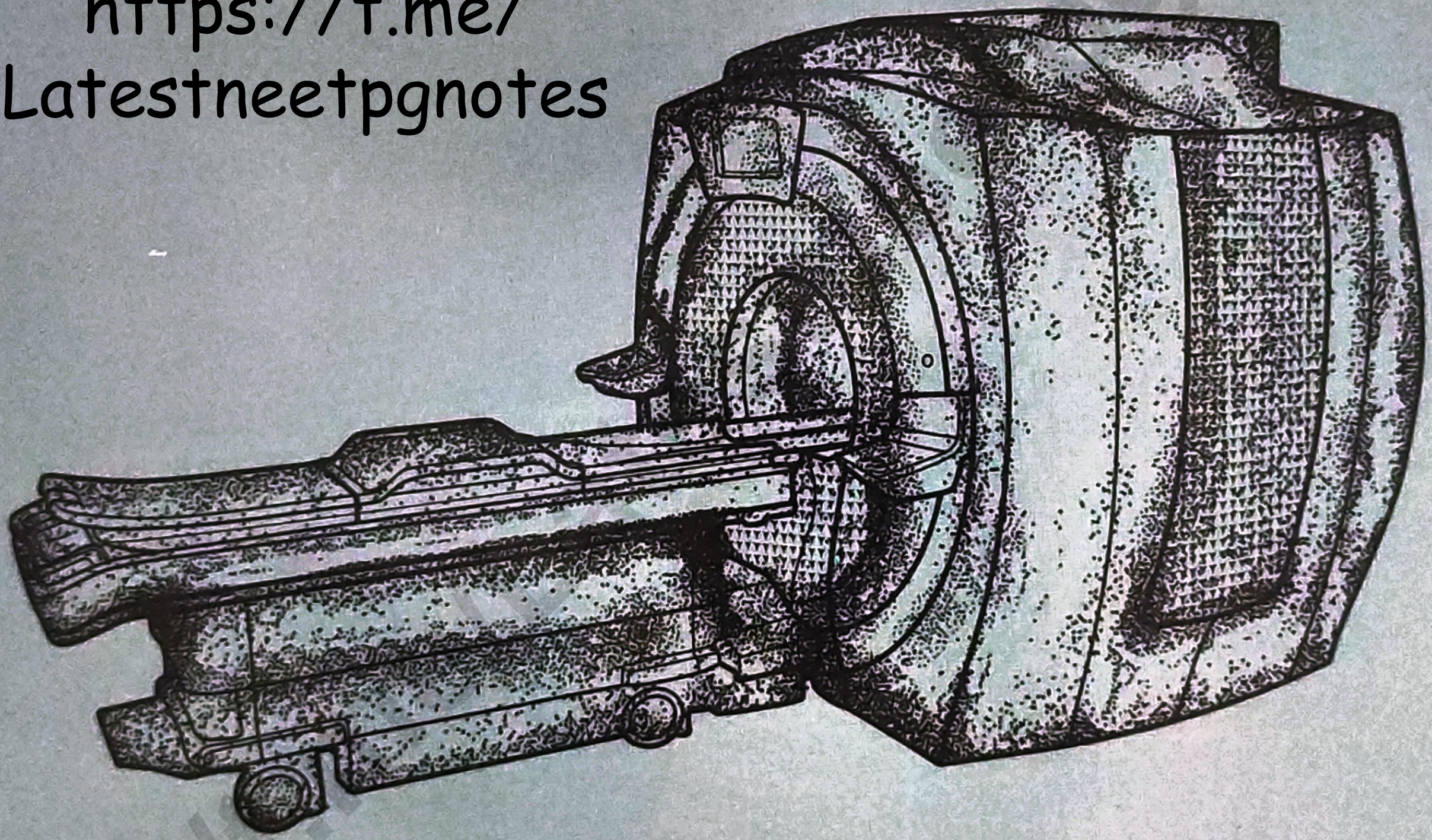

https://t.me/Latestneetpgnotes

RADIOLOGY

Based on video lectures by
Dr. Khaleel Ahmed

DISCLAIMER

FOR EDUCATIONAL PURPOSES ONLY. NOT FOR SALE/PROFITABLE PURPOSES. ALL RESPONSIBILITIES AND ISSUES RELATED TO THIS COPY WILL BE FACED BY THE BEARER.
ALL COPYRIGHT OWNED BY PREPLADDER PVT. LTD

https://t.me/Latestneetpgnotes

For more free ebooks and notes, visit

https://t.me/Latestneetpgnotes

Or click this page to join

INDEX

1.	Introduction	1
2.	Radiation units & doses	16
3.	Imaging in COVID-19	25
4.	X-Ray Part - 1	34
5.	X-Ray Part - 2	40
6.	CT Scan Part - 1	53
7.	CT Scan Part - 2	67
8.	Ultrasound Part - 1	81
9.	Ultrasound Part - 2	93
10.	Ultrasound Part - 3	100
11.	Obstetrics Ultrasound	115
12.	Magnetic Resonance Imaging Part - 1	129
13.	Magnetic Resonance Imaging Part - 2	139
14.	Nuclear Medicine Part - 1	148
15.	Nuclear Medicine Part - 2	155
16.	Radiotherapy Part - 1	162
17.	Radiotherapy Part - 2	166
18.	Gastrointestinal Radiology Part - 1	171
19.	Gastrointestinal Radiology Part – 2	180
20.	Neuroradiology Part - 1	197
21.	Neuroradiology Part - 2	205
22.	Neuroradiology Part - 3	214
23.	Neuroradiology Part - 4	220
24.	Neuroradiology Part - 5	228
25.	Hepato-biliary Radiology	239
26.	Pancreatic Radiology	247
27.	Genitourinary Radiology	251
28.	Musculoskeletal Radiology Part - 1	264
29.	Musculoskeletal Radiology Part - 2	279
30.	Musculoskeletal Radiology Part - 3	292
31.	Musculoskeletal Radiology Part - 4	301

https://t.me/Latestneetpgnotes

32.	DEXA Scan	308
33.	Cardiovascular Radiology	312
34.	Respiratory Radiology	325
35.	Angiography	349
36.	Contrast Agents	354
37.	Women Radiology	364
38.	Dental Radiology	369

https://t.me/Latestneetpgnotes

Chapter 1

INTRODUCTION TO RADIOLOGY

Symbols in Radiology

00:03:45

Trefoil Radiation hazard

High energy ionizing radiation

Biohazard

Non ionizing radiation

MRI Restriction

Equipments

00:06:02



X-ray

https://t.me/Latestneetpgnotes

PrepLadder

Ultrasound

CT-Scan



MRI



Mammography



C-Arm X-ray



DEXA Scan

Note:

- C-Arm x-ray – Used in fluoroscopy, OT theaters
- DEXA Scan (Dual Energy X-ray Absorptiometry)
  - Used to measure Bone Mineral Density
- MRI – Claustrophobia may occur.

Important scientists in Radiology 00:10:14

Father of radiology	→ W.C. Roentgen [discovered X-ray on 8th Nov, 1895] (8th Nov - International day of radiology) → Theme for 8th Nov, 2020 – Supporting patients during COVID -19

https://t.me/Leetpgnotes

PrepLadder

Father of radioactivity	→ Henry Becquerel
Father of Interventional radiology	→ Charles Dotter (Contributed for balloon angioplasty)

→ X -ray	W.C. Roentgen
→ CT scan	Sir Godfrey Hounsfield, Allan Cormack
→ Mammography	Robert Egan
→ Medical USG	John Wild
→ Obstetrics USG	Ian Donald
→ Medical MRI	Paul Lauterbur & Mansfield
→ Principal of NMR (Nuclear magnetic resonance)	Felix Bloch & Purcell
→ Gamma Knife (stereotactic Radiosurgery)	Lars Leksell

Wilhelm Conrad Roentgen → Father of radiology → German Physicist → Awarded noble prize in 1901 → Discovered X – rays on 8th Nov, 1895	 Sir Wilhelm roentgen	 1st x-ray Roentgen's wife "Bertha's hand"

https://t.me/Latestneetpgnotes

PrepLadder

Henry Becquerel

→ Father of Radioactivity



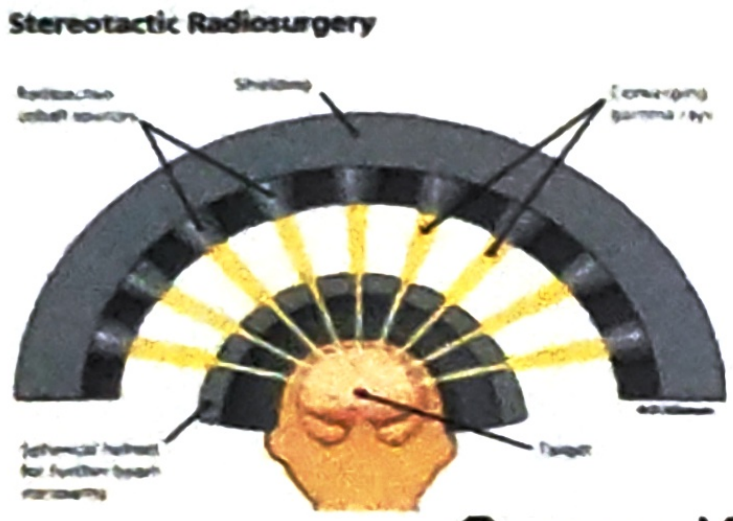

Gamma Knife Surgery

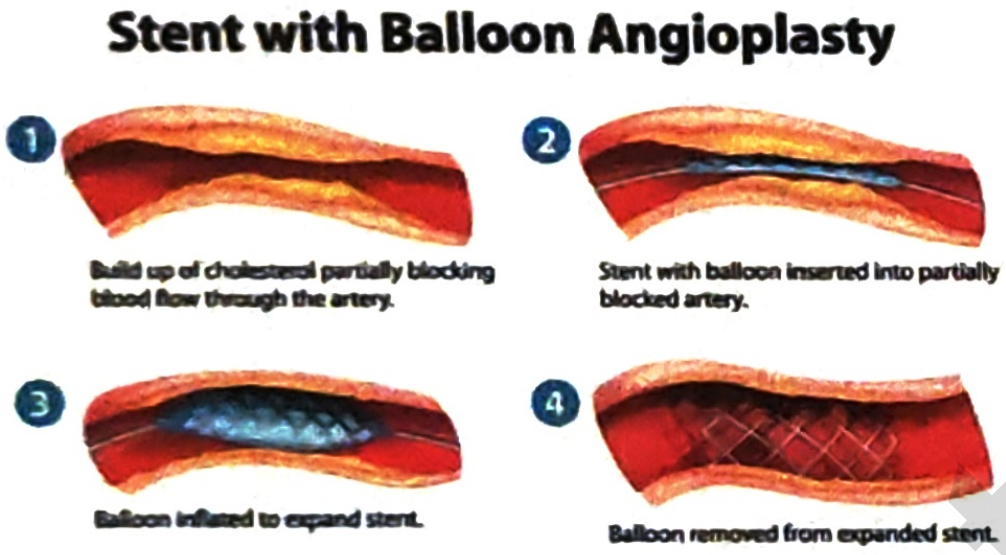

Basic Terminology

00:17:25

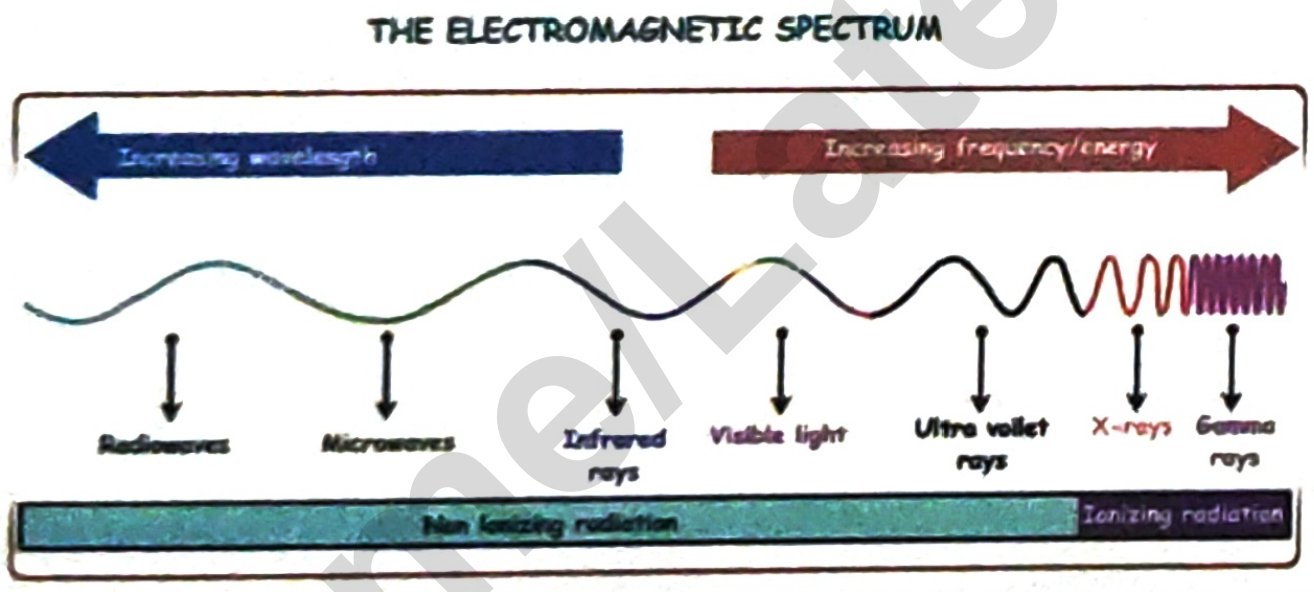

Types of Radiation	
Ionizing radiation	Non-Ionizing radiation
→ Electromagnetic (High Energy) • X-rays • α -rays • Cosmic rays → Particulate beams • α - ray • β -ray • Protons • Neutrons	→ Electromagnetic (Low Energy) • U.V rays • Visible light • Infrared rays • Radio waves (used in MRI) • Microwaves → Sound waves • Ultrasound

https://t.me/Latestneetpgnotes

PrepLadder

Ionizing power/ Damaging power:

α – rays › β - Rays › x- rays › γ – rays

Note:

α – RAYS → maximum biological damage

→ Higher linear energy transfer

Penetration power

γ – rays › x – rays › β – rays › α – rays

Note:

If neutrons given in option then → n › γ › x › β › α rays



Q. X – rays differ from Y –ray in all the following except?

a. Wavelength

b. Frequency

c. Energy

d. Velocity

e. Origin

Ans: d) Velocity

Explanation

→ Wavelength, frequency & energy

- Frequency - γ - Rays › x-rays
- Energy – γ - rays › X – rays
- Wavelength – x rays › γ rays

E α V/λ

→ E – Energy

→ V – Frequency

→ λ – Wavelength

https://t.me/Latestneetpgnotes

PrepLadder

→ All electromagnetic radiations have the same Velocity ($3 * 10^8$ m/s)

→ Origin

- X-rays – extra nuclear
- γ-rays – Intra nuclear

X-Ray	γ rays
→ High energy ionizing radiation → Higher wavelength → Lesser Frequency Origin – Manmade, Extranuclear	→ Higher energy ionizing radiation → Lesser Wavelength } Compared to X-Rays → Higher Frequency } Origin - Disintegration of unstable nucleus, Intranuclear

Diagnostic Modality Terminology	White	Black
X-rays	Radio opaque	Radiolucent
CT scan	Hyperdense	Hypodense
USG	Hyperechoic	Hypoechoic
MRI	Hyperintense	Hypointense

https://t.me/Latestneetpgnotes

00:28:44

Diagnostic Modalities		
Non ionizing Radiation	Ionizing Radiation	
	γ - Rays	X- rays
Sound Waves – USG – Doppler Radio Waves – MRI – MRCP Infrared Waves – Thermography	→ Nuclear Scan – Scintigraphy (Tc^{99m} / Radioisotope) → Bone scan (Tc^{99m} / MDP studies) → SPECT (Tc^{99m}) (Single photo emission Computerized tomography) → PET scan – 18 FDG. (Positron emission tomography)	– Radiography – Fluoroscopy – Angiography – Mammography – CT scan – Bronchography – Barium Studies – DEXA scan (Dual Energy X- ray Absorptiometry) – IVP/IVU (Intravenous phlebography/ Intravenous urography) – Hysterosalpingography (HSG) – Micturation cystography (MCU) – Retrograde urethrography (RGU) - Endoscopic retrograde Cholangiopancreatography (ERCP)

Ultrasound Abdomen

Ultrasound-Antenatal Scan

https://t.me/Latestreetpgnotes

PrepLadder



Doppler Ultrasound

MRI- T1W

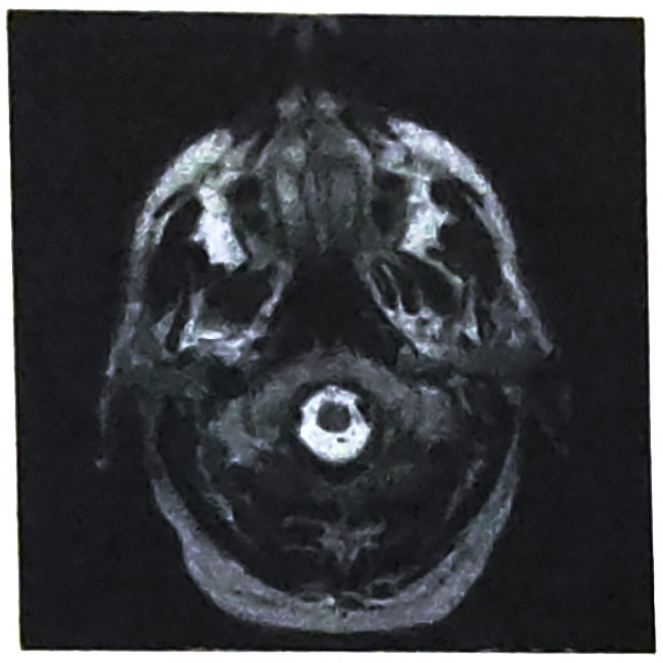

MRI- T2W

CT-Scan

Note:

WW2 [World War 2]

→ Water appears white in T2W images.

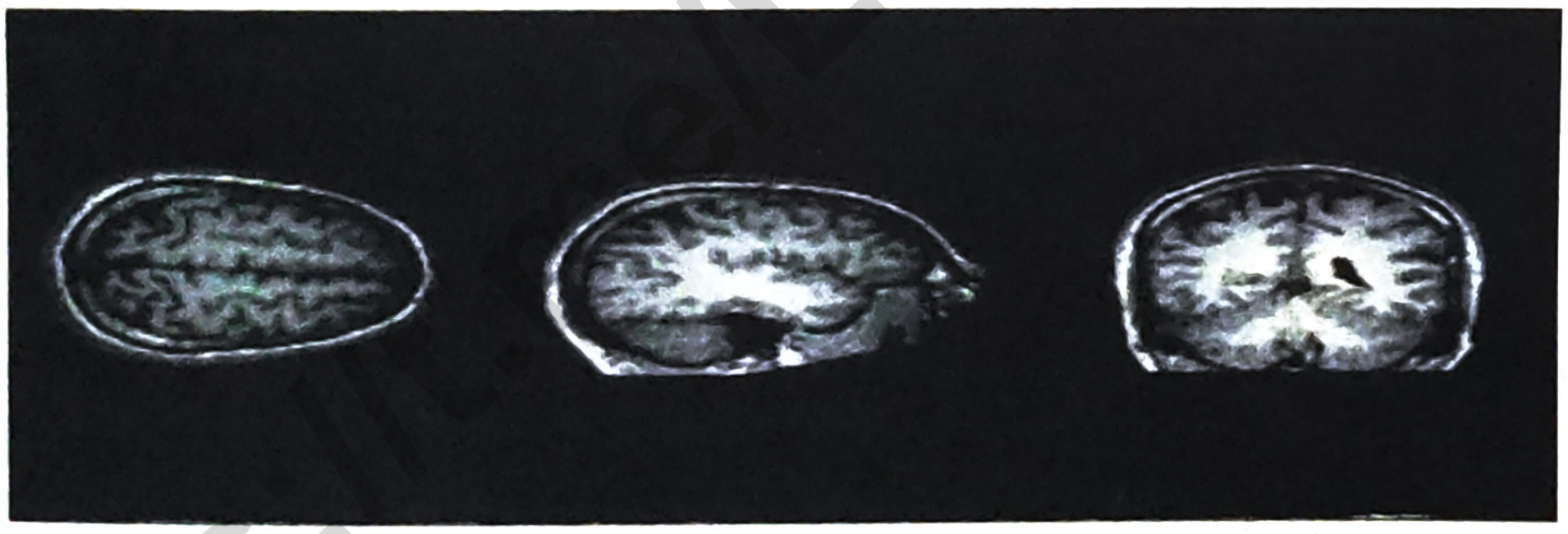

Axial Sagittal Coronal

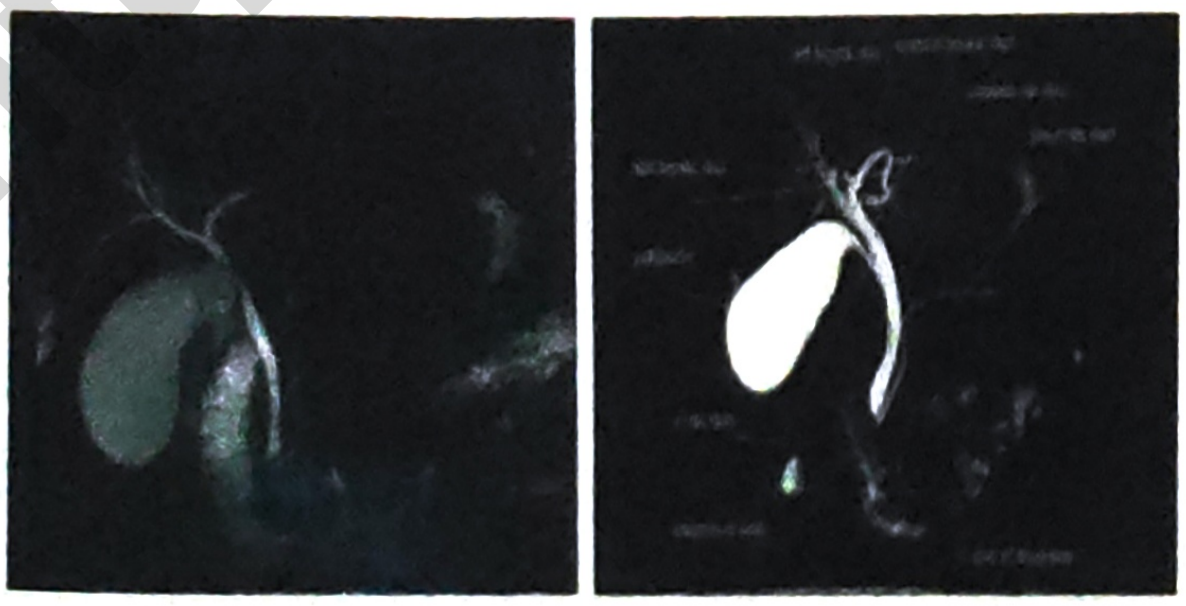

MRCP

→ Non-contrast study

→ T_2W Image

Secretin Injections

https://t.me/Latestpgnotes

PrepLadder

Thermography

Thermometer

Thermography

- Uses infrared Waves

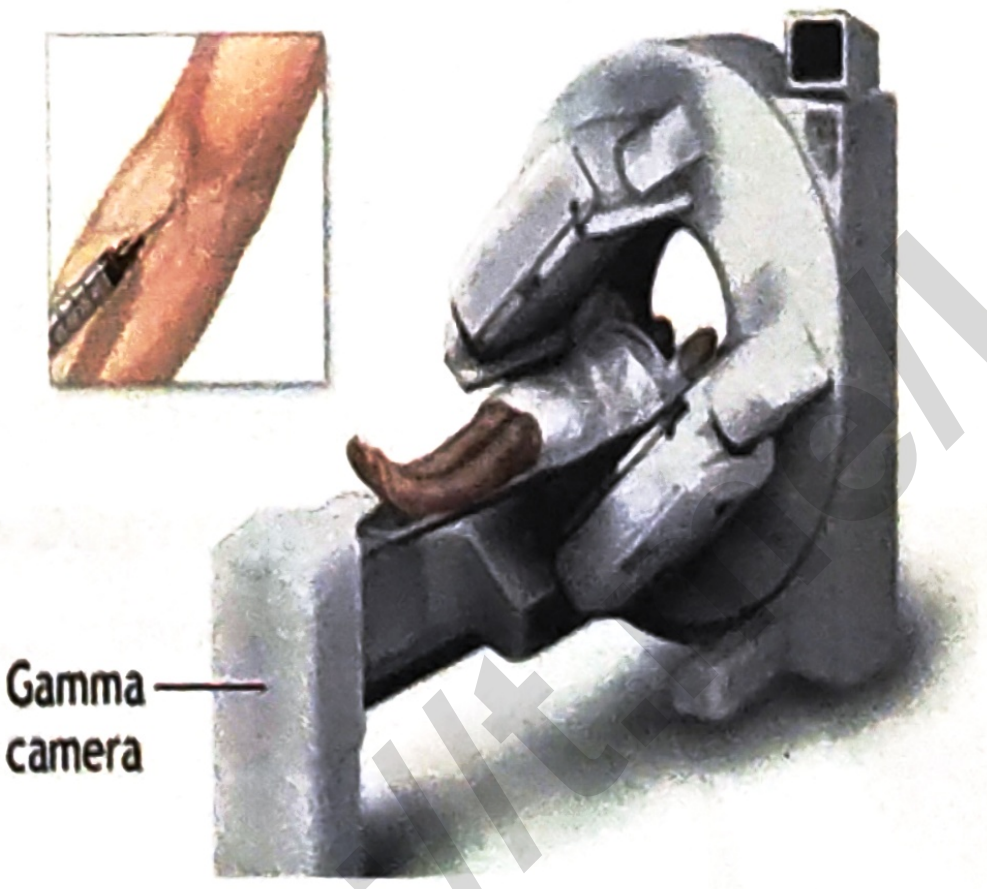

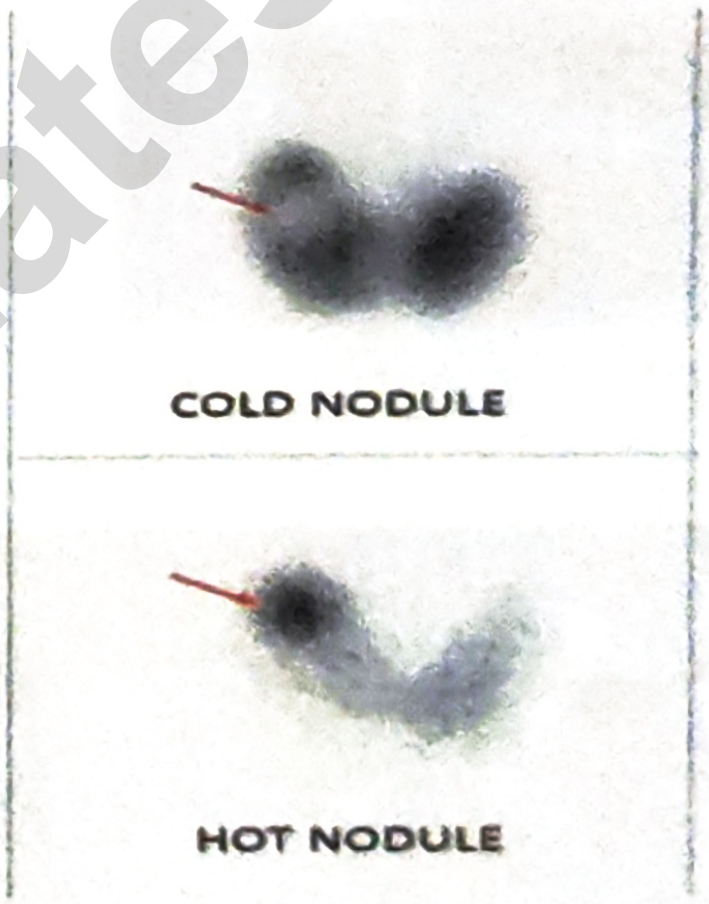

Scintigraphy

https://t.me/Latestneetpgnotes

Note:

Scintigraphy

→ Uses Gamma rays

→ Decreased Uptake-cold Nodule

→ Increased Uptake-Hot Nodule

→ Uses – TC^{99m} Pertechnetate

PrepLadder

Note:

Bone Scan

→ Gamma Rays

→ TC^{99m} – MDP

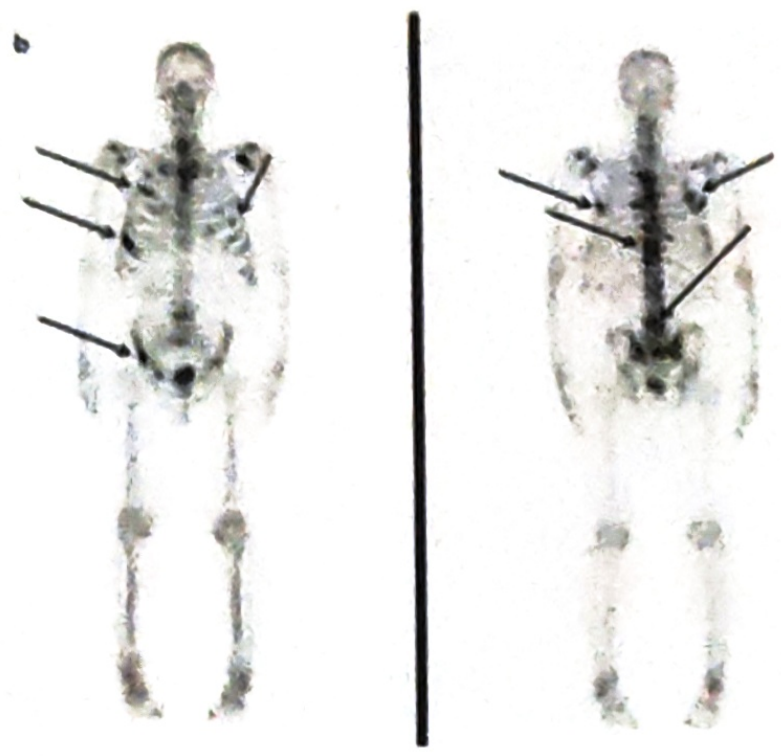

Bone Scan

Note:

Spect [Single-Photon Emission Computed Tomography]

→ Gamma Rays

→ 360° revolving camera – 3D images

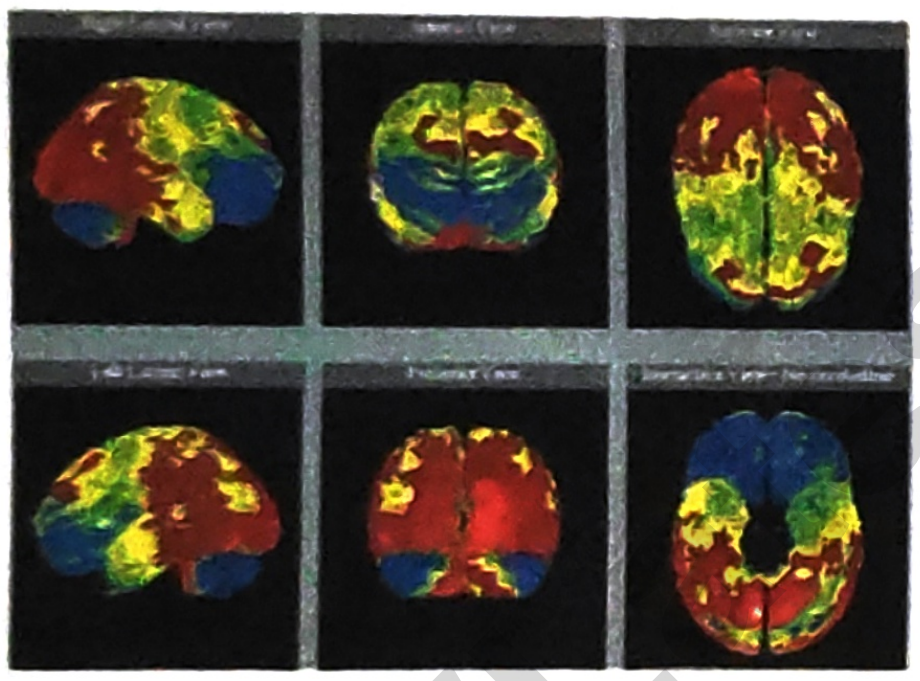

SPECT SCAN

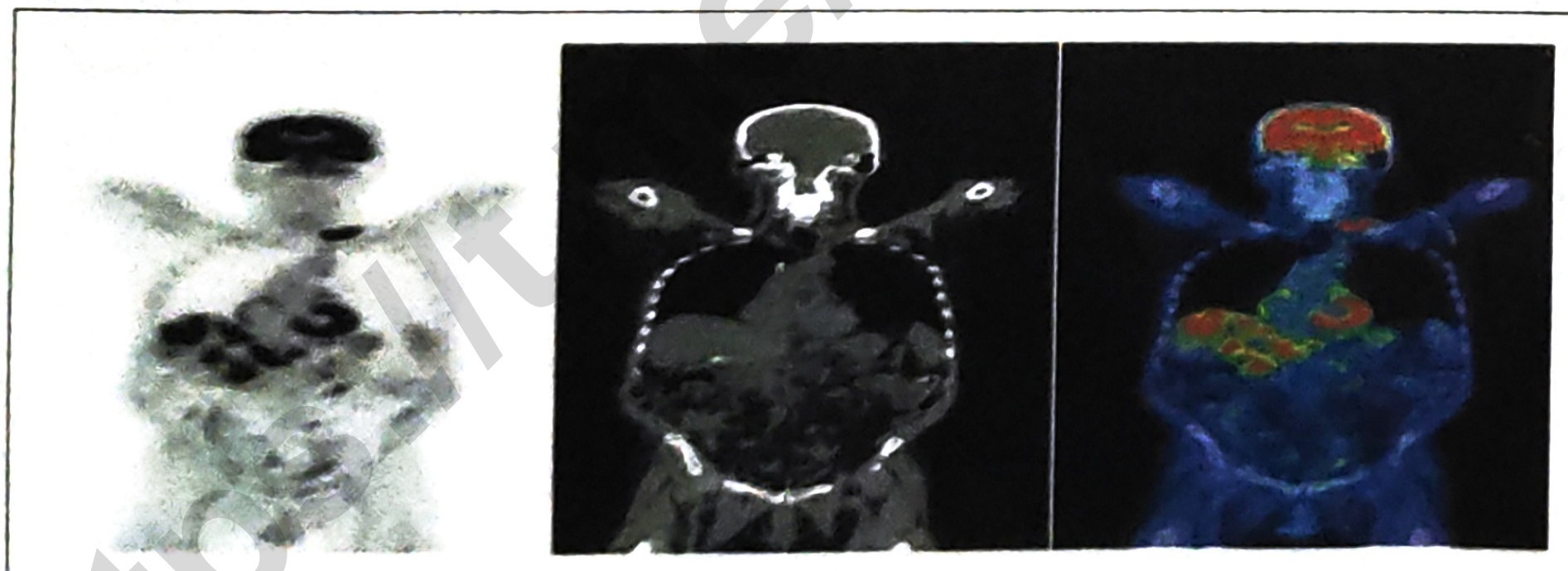

PET Scan	Coronal CT Scan	PET-CT Scan
→ Functional details → γ rays	→ Anatomical Details → X-rays	→ Both Anatomical and function Details → Higher Radiation

stneetpgnotes

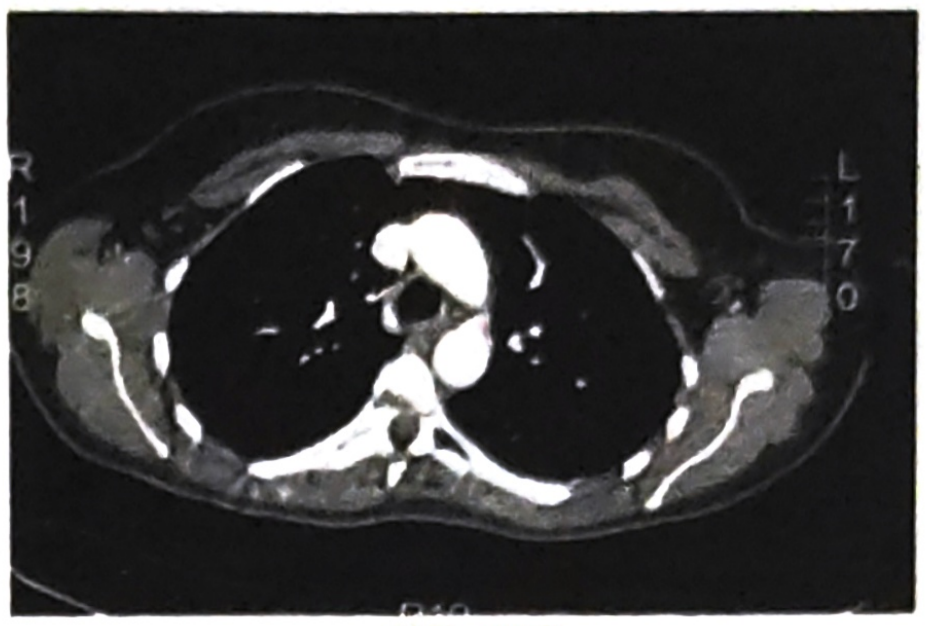

CE-CT

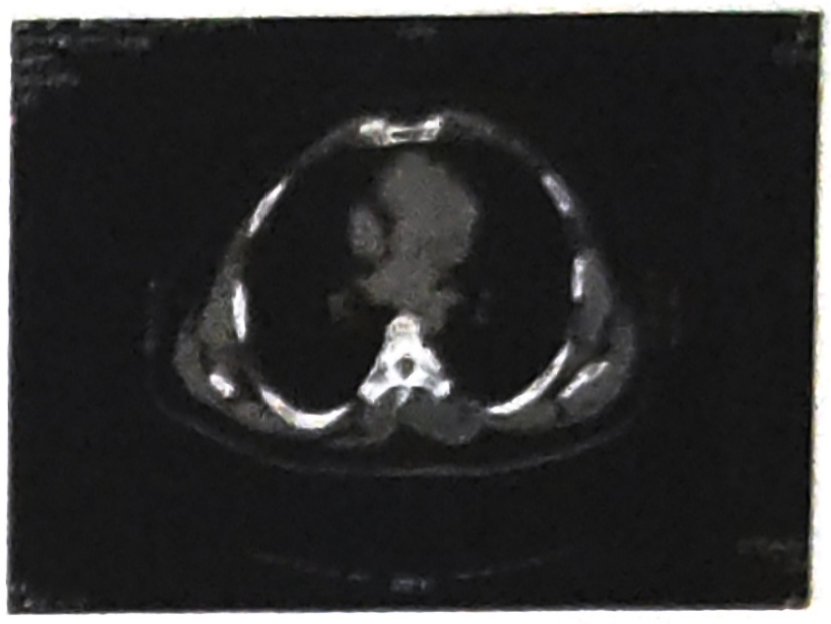

NCCT

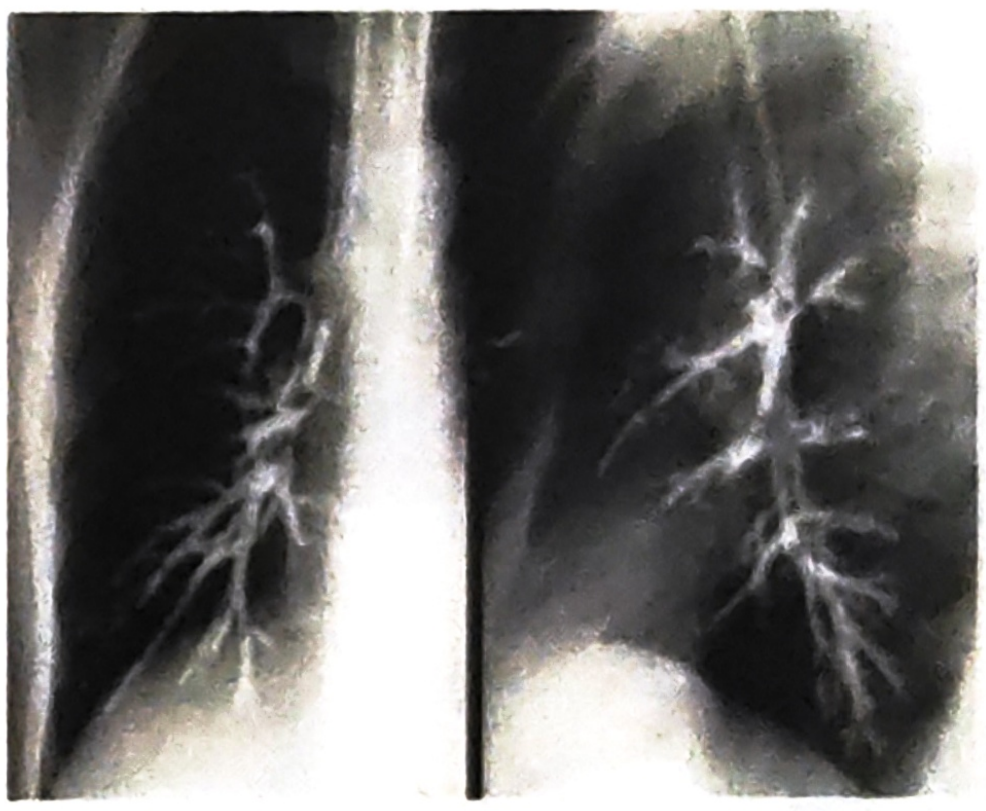

Bronchography

Note:

Video of X-ray – Fluoroscopy

Uses:

→ Barium studies

→ Diaphragm paralysis

→ Orthopedics & Angiography

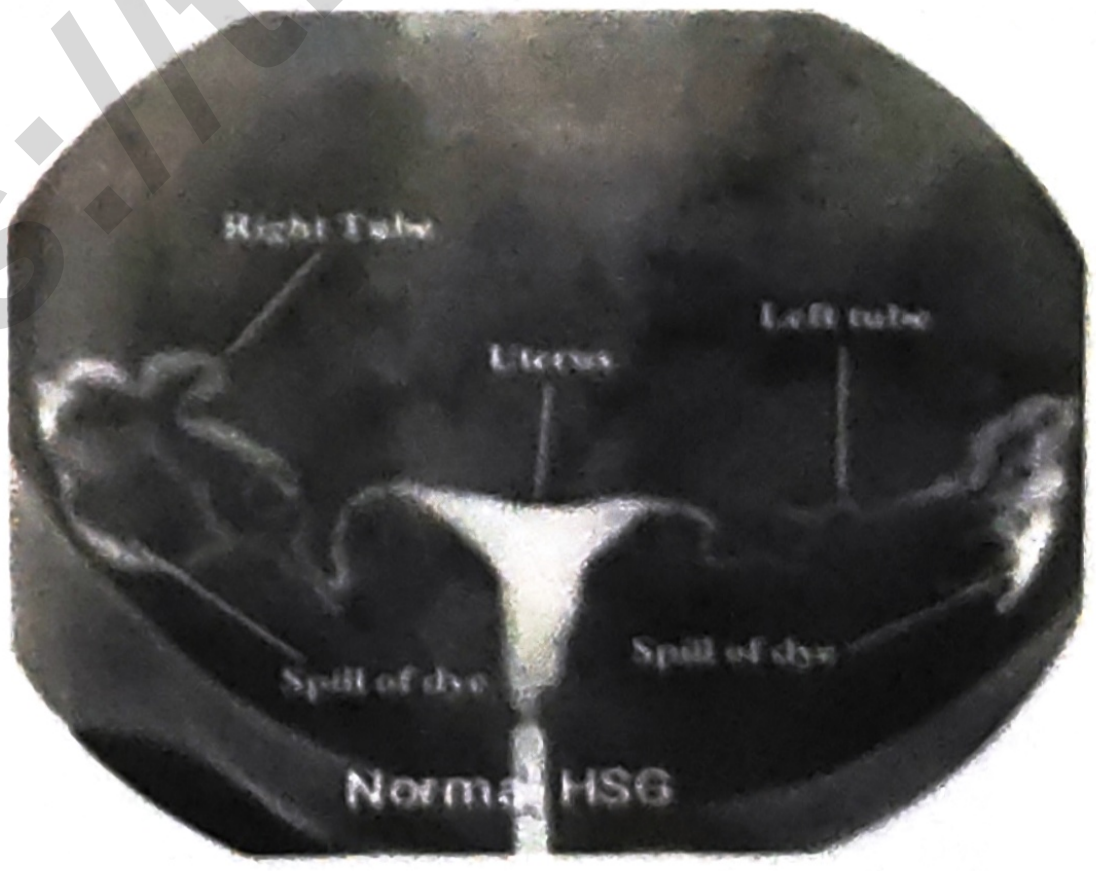

Hysterosalpingogram

https://t.me/Latestneetpgnotes

PrepLadder

Q. All the following investigations are Non Ionising Radiation except?

a. FAST

b. MRCP

c. Orthopantomogram

d. Thermography

Orthopantomogram

→ X-ray

→ Panoramic view of maxilla, Mandible, Teeth.

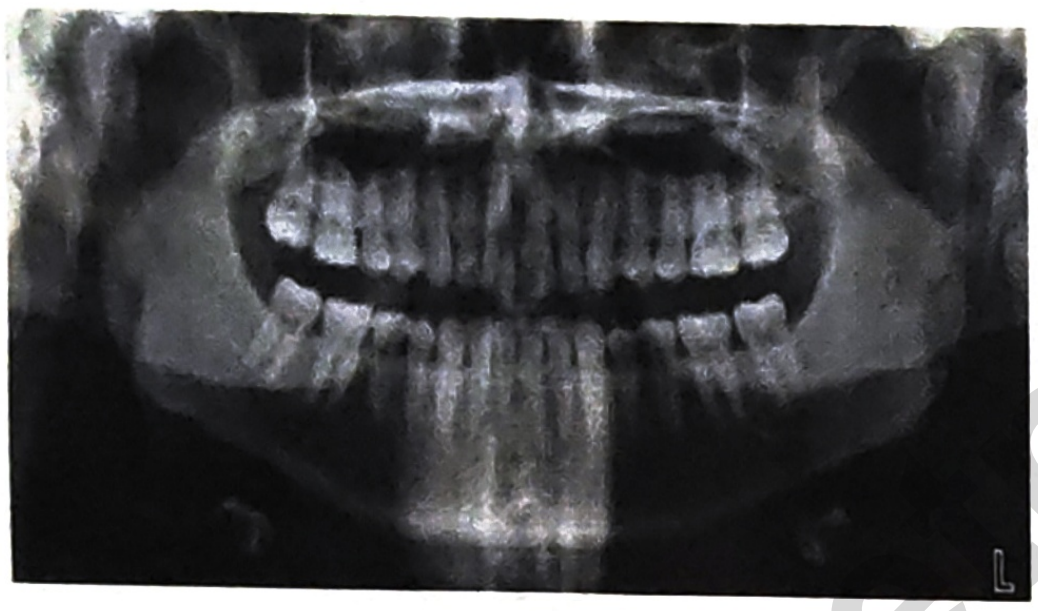

Intravenous Pyelography

00:55:33

Intravenous Urography	
Nephrogram – Able to view kidney shadow	Pyelogram – Able to view pelvic calyceal system & Ureter
Note: In adult polycystic kidney disease ↓ Swiss cheese appearance – nephrogram	Note: In adult polycystic kidney disease ↓ Spider leg appearance on pyelogram

https://t.me/bestneetpgnotes

PrepLadder

Nephrogram

Pyelogram

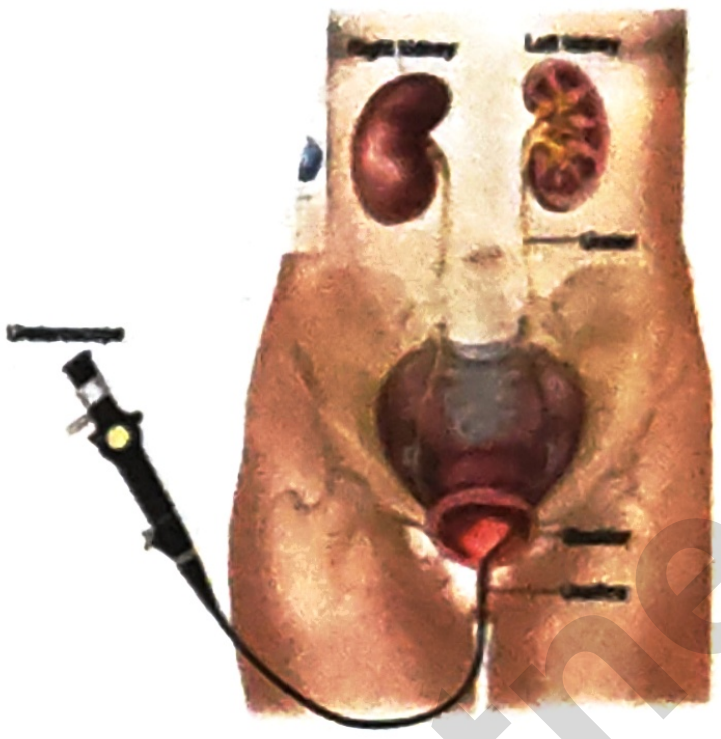

Retrograde Pyelogram

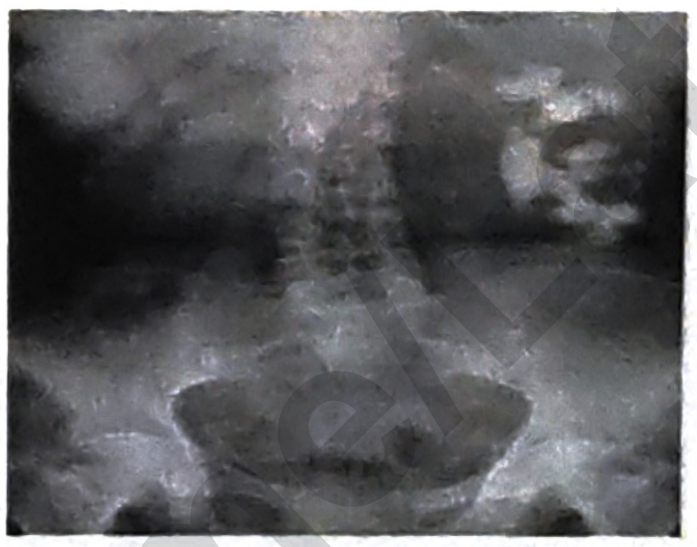

Staghorn Calculi/ Struvite Stone

Micturating cystourethrography

→ Also known as voiding cystourethrography

→ IOC for vesicoureteral reflex

→ Also used to evaluate posterior urethra

Micturating cystourethrography

https://t.me/latestneetpgnotes

PrepLadder

Retrograde urethrography

→ It is used to evaluate anterior urethra

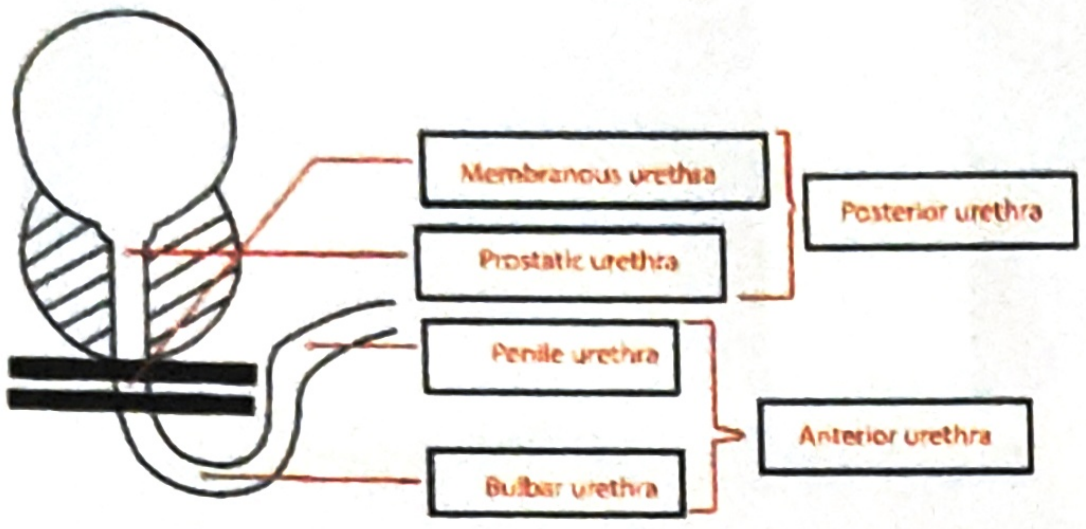

Q. All the following investigations use Ionising Radiation except?

a) DEXA

b) MCU

c) Angiography

d) POCUS

Note:

POCUS → Point of care Ultra Sound

Invertogram

01:05:01

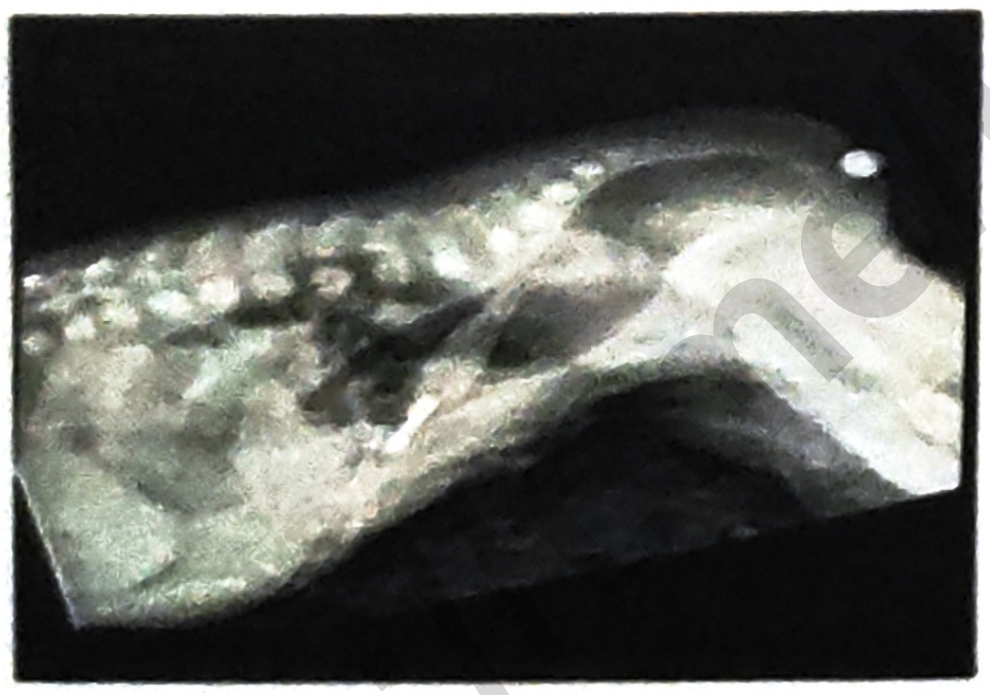

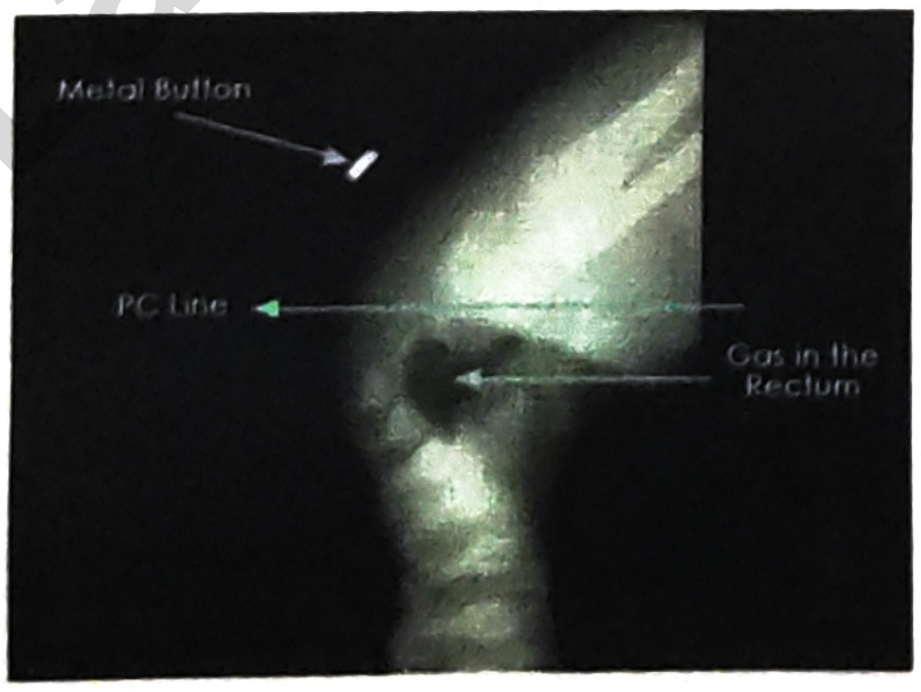

Invertogram

→ Used to evaluate anal atresia

→ To know high anal or low anal atresia

→ Done 24 hrs after birth with baby upside down position

→ Then the distance b/w metal button on anal dimple to air in rectum is measured

→ If distance is

> 2 cm – High anal atresia → Abdominal Approach is better

> 2 cm – Low anal atresia → Perineal approach is better

https:// latestneetpgnotes

PrepLadder

ERCP (Endoscopic Retrograde Cholangiopancreatography)

→ After inserting endoscope upto Ampulla of vater, dye is injected into Biliary Tree and pancreatic duct.

→ If linear lucency is seen in CBD or ERCP indicates biliary ascariasis

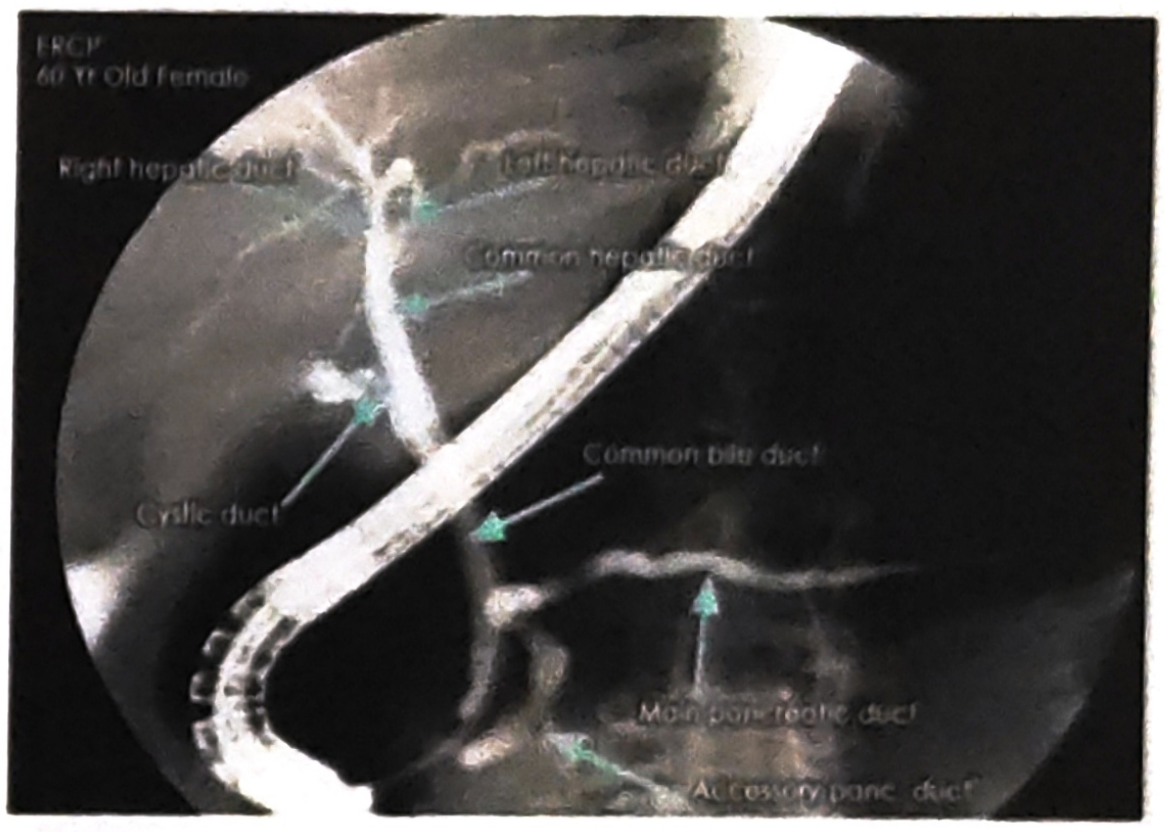

ERCP

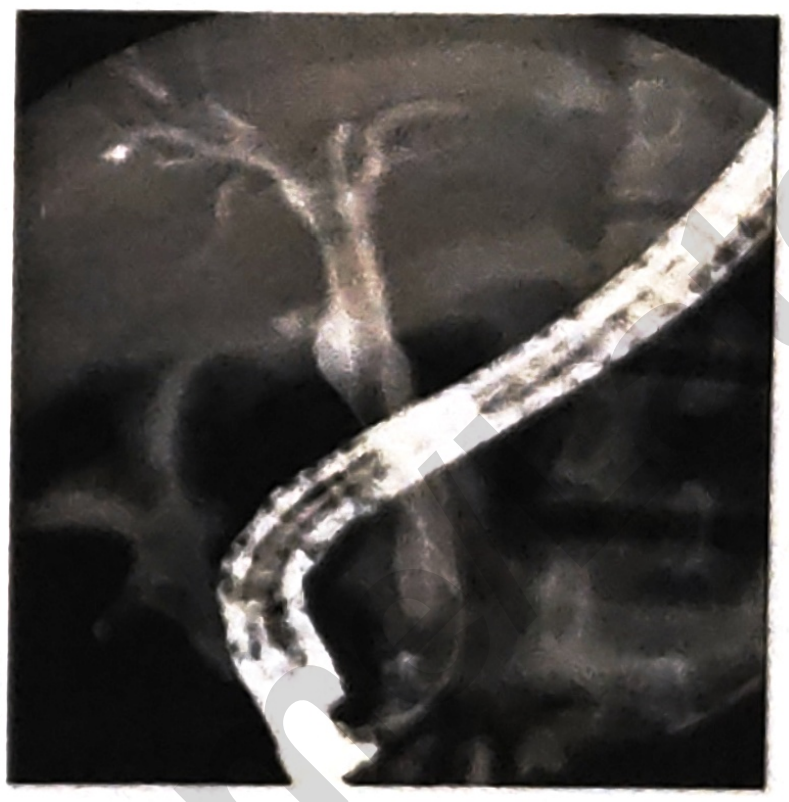

ERCP Showing linear lucency in CBD – Biliary ascariasis

ERCP	MRCP
Invasive	Non-Invasive
Uses Contrast	T2W, Non-Contrast
Uses X-ray (Ionising Radiation)	Non- Ionising
Diagnostic & Therapeutic	Diagnostic

https://t.me/latestneetpgnotes

Chapter 2

RADIATION UNITS & DOSES

Radiation Units 00:00:13

	Conventional	S.I
Exposure dose	Roentgen	Coulomb / kg
Absorbed dose	Rad	→ Gray 1 Gray = 100 Rad → 1 Rad = 0.01 Gray
Equivalent dose	Rem	Sievert → 1 SV = 100 Rem → 1 Rem = 0.01 SV
Effective dose	Rem	Sievert
Radio activity	Curie	Becquerel → Bq = 1 disintegration/ sec → 1 Curie = 3.7 * 1010 Bq

Equivalent dose

→ Absorbed Dose X radiation quality factory (RQF)

Note:

- RQF for α − rays = 20
- RQF for X-rays & γ − rays = 1

Effective dose

→ Takes into consideration tissue susceptibility / tissue weighting factor

https://t.me/Latestneetpgnotes

PrepLadder

TLD Batch: (Thermo-luminescent dosimeter) 00:08:13

→ Detect the amount of radiation an occupation worker Has been exposed

→ It is made up of lithium fluoride (LIF) or Caso4 Dysprosium

→ It is worn under apron at chest level

→ Read every 3 months.

Thermo-Luminescent Dosimeter

AERB Guidelines for radiation protection

→ Minimum Thickness

- LEAD APRON - 0.25 mm
- GONADAL SHIELD - 0.5 mm
- PROTECTIVE BARRIER - 1.5 mm

X-ray Protection Kit

https://t.me/Latestneetpgnotes

PrepLadder

Protective Barrier

ICRP

INTERNATIONAL COMMISSION ON RADIOLOGICAL PROTECTION

IAEA

International Atomic Energy Agency

Atoms for Peace and Development

NCRP

National Council on Radiation Protection & Measurements

परमाणु ऊर्जा नियामक परिषद

पऊनिप

AERB

ATOMIC ENERGY REGULATORY BOARD

https://t.me/Latestneetpgnotes

PrepLadder

AERB guidelines for radiation protection

00:13:20

Dose limitations		
Parts of body	Occupational Exposure	Public Exposure
Whole body	• 20 mSv/ year averaged over 5 Consecutive years • 30 msv in any single year	1 msv/y
Lens of eyes (Equivalent dose)	150 mSv in a year (ICRP – 20 mSw/year)	15 mSv /y
Skin (Equivalent dose)	500 mSv in a year	50 mSv /y
Extremities (Hands & Feet) Equivalent dose	500 mSv in a year	
Abdomen pregnant female	2 mSv	1 mSv
Fetus/ Embryo	1 mSw	0.5 mSv
For pregnant radiation workers, after declaration of pregnancy 1 mSv on the embryo / fetus should not exceed		

Note:

The above guidelines are not for patients.

00:19:24

Diagnostic Modality	Radiation Dose
Chest Radiograph PA View	0.02 mSv
Abdominal Radiograph AP view	0.7 mSv
Skull Radiograph	0.07 mSv
Mammography	0.5-0.7 mSv
IVP	2-3 mSv

https://t.me/Latestneetpgnotes

PrepLadder

Barium Enema	7-8 mSv
CT HEAD	1-2 mSv
CT CHEST	4-6 mSv
CT ABDOMEN	10 mSv
PET	5-10 mSv
PET-CT	15-25 mSv
BONE SCAN	4 mSv
CARDIAC SCINTIGRAPHY	6-10 mSv

Q. Which of the following investigations have the maximum Radiation Exposure?

a) Chest Radiograph

b) Mammography

c) Intravenous Pyelography

d) Barium Enema

Effects of Radiation on Fetus

00:22:34

Gestational Age	Fetal Development	Radiation effect
0-2 week	Fertilization, implantation and Blastogenesis	All or none Loss of pregnancy Failure to implant but surviving embryos no significant risk
2-8 weeks	Organogenesis	Teratogenicity Congenital malformations Growth Retardation
8-15 weeks	Early Fetal Period (8-15 weeks maximum risk period for Mental Retardation)	Severe Mental Retardation, Severe IQ deficit and Microcephaly Growth Retardation
16-25 weeks		Lower risk of mental retardation
25-40 Weeks	Late Fetal Period	Miscarriage and Neonatal Death based on Dose
2-40 week	Genetic mutation	Childhood Cancer Risk

https://t.me/Latestneetpgnotes

PrepLadder

Accidental radiation exposure in pregnancy 00:24:59

HIGH DOSE RADIATION EXPOSURE

→ ICRP

- < 10 RAD (100 m Gy) not a medical ground for termination

→ ACOG

- THRESHOLD FOR MEDICAL CONCERN - 5 RAD

→ >100 RAD serious risk for fetal CNS damage mental retardation.

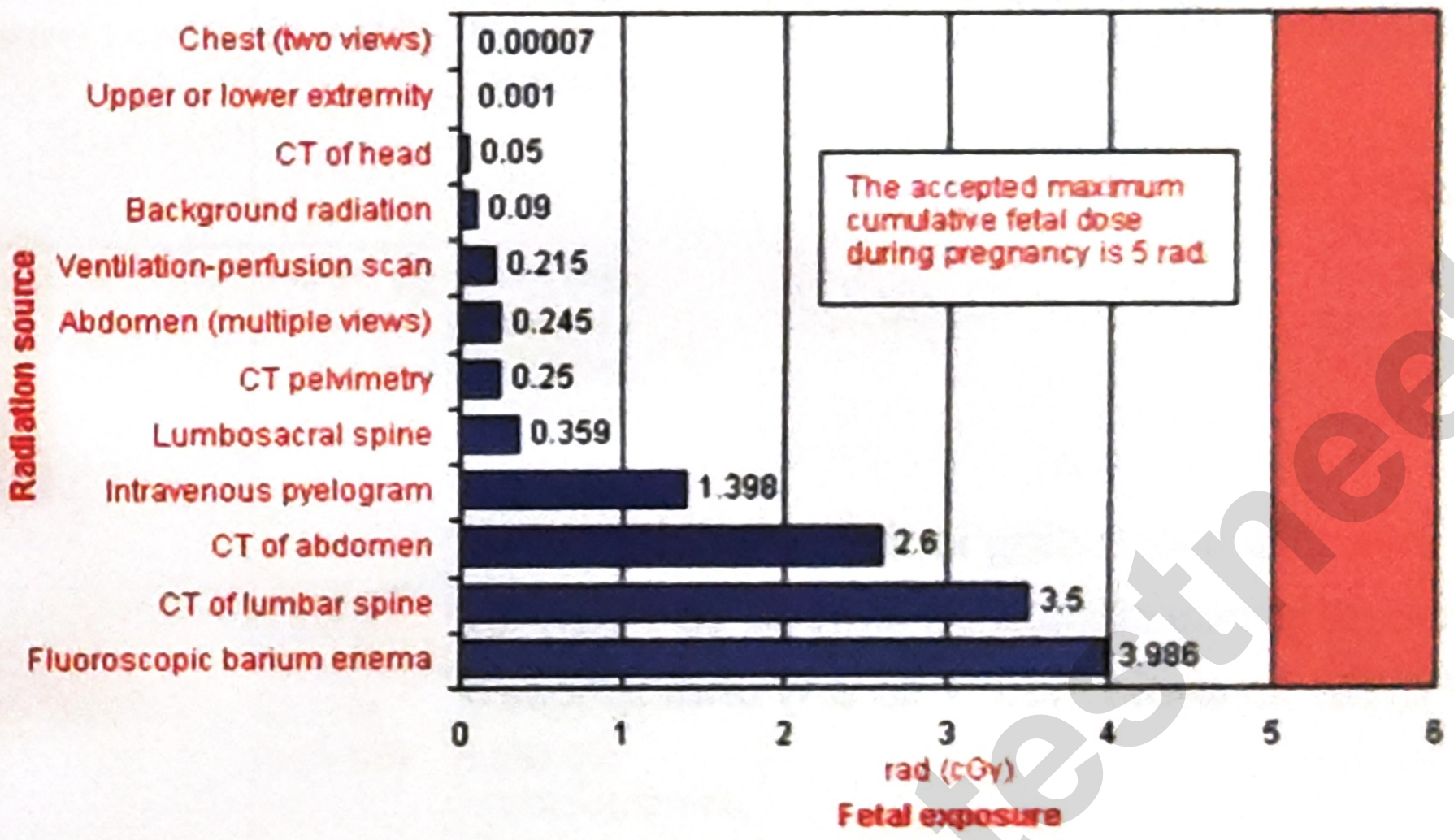

Guidelines for X-ray examination/ Exposure during pregnancy

→ A single diagnostic procedure does not result in harmful fetal effects (< 5 rad)

→ Concern about possible effects of high-dose ionizing radiation exposure should not prevent medically indicated diagnostic X-ray procedures

→ Ultrasonography and MRI are not associated with known adverse fetal effects.

→ Radiation exposure through radiography, computed tomography (CT) scan, or nuclear medicine imaging techniques is at a dose much lower than the exposure associated with fetal harm.

→ The use of gadolinium contrast with MRI should be limited; use only if very necessary to improve outcome

→ Breastfeeding should not be interrupted after gadolinium administration.

https://t.me/Latestneetpgnotes

PrepLadder

Principles of Radiation Protection

00:27:59

- Justification
- Optimization
- Limitation of dose

ALARA stands for – As Low as Reasonably Achievable

→ No limitation of use of Investigation in case of patients.

Basic factors for radiation protection

- Time
- Distance – Inverse square Law
- Shielding

10 Days rule

→ It states all radiologic investigation using ionizing radiation in a female of reproductive age group should be limited to FIRST 10 DAYS of her menstrual cycle to avoid injury to any undiagnosed pregnancy.

28 Days rule

→ This means that radiological examination, if justified, can be carried throughout the cycle until a period is missed. Thus the focus is shifted to a missed period and the possibility of pregnancy.

00:35:27

DICOM stands for – Digital Imaging and Communication in Medicine

PACS stands for – Picture Archiving and Communication system

DICOM

PACS

https://t.me/Latestneetpgnotes

Acute radiation syndromes

00:37:50

→ An exposure of 1-2 GY radiation - acute hematopoietic syndrome

→ An exposure of 6-10 GY radiation - acute GI syndrome

→ An exposure of 20 GY radiation - acute CNS syndrome

Acute Radiation syndromes					
Syndrome	Dose	Prodromal stage	Latent stage	Manifest Illness stage	Recovery
Hematopoietic (Bone marrow)	> 1 – 2 Gy	Anorexia Nausea Vomiting	Pt. starts to feel better	Blood counts ↓ fever Bleeding Infections	Most recover
Gastrointestinal (GI)	> 6-10 Gy	Anorexia, Nausea, Vomiting, Abdominal Cramps, diarrhea	Pt. start to feel better	Severe diarrhea, electrolyte imbalance, dehydration	Death can occur in few weeks
Cardiovascular (CV) Central Nerve System (CNS)	> 20 Gy symptom in few minutes	Anorexia, Nausea, Vomiting, Loss of consciousness, Burning Sensations	Partial functionality	Convulsion, death	Usually death within few days

00:42:42

Stochastic	Deterministic (Non – Stochastic)
They are not dose dependent	They are dose dependent
They have no threshold	They have a threshold
They can occur at low doses	They have a threshold
Severity of effect is not related to dose, but Probability of occurrence of stochastic effects increases as the dose increases	Severity of effect is directly proportional to the absorbed dose

https://t.me/Latestneetpgnotes

PrepLadder

For more free ebooks and notes, visit

https://t.me/Latestneetpgnotes

Or click this page to join

IMAGING APPROACH FOR COVID-19 CONFIRMED PATIENTS 00:07:06

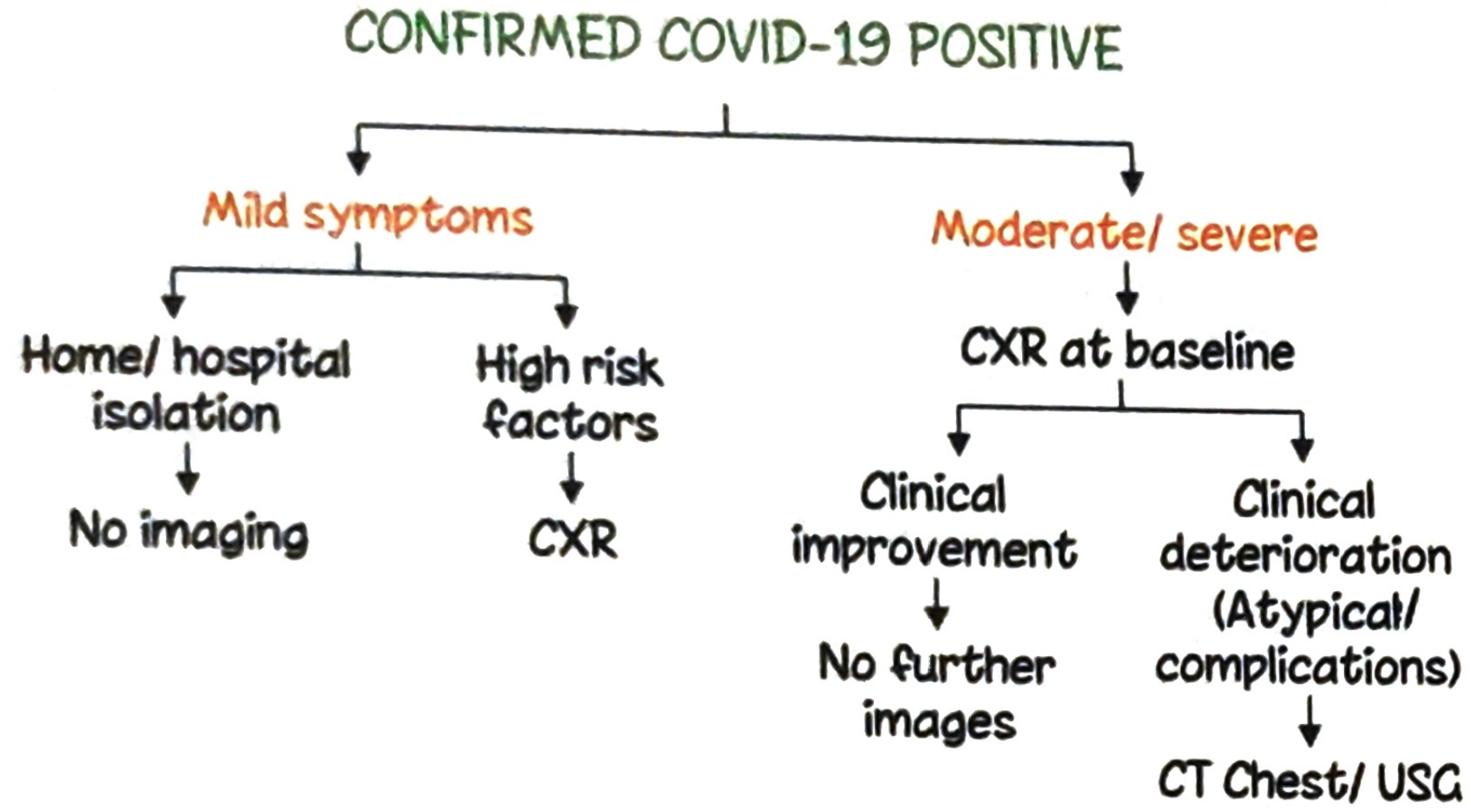

IMAGING STRATEGY 00:10:00

- Imaging of COVID-19 Patients should focus on
  - →CXR – 1st line modality
  - →CT scan – in specific situations
  - →Bedside portable USG- Adjunct → for worsening conditions
  - →Avoid non-essential imaging and transportation to radiology department

CHEST RADIOGRAPH 00:11:20

Uses

- Indicated in patients with moderate to severe symptoms at baseline
- In mild cases, with risk factors
  - →Age > 60 yrs
  - →Cardiovascular disease
  - →Diabetes mellitus
  - →Immune compromised states
  - →Chronic liver/ kidney/ lung diseases

- Peripheral predominant, multiple, Bilateral areas of Ground Glass opacities and consolidation

PrepLadder

https://t.me/Latestneetpgnotes

CHEST – CT
00:12:33

Indications

→ Suspected case

- RT-PCR negative with clinical suspicion
- Equivocal CXR pattern
- Emergency situation – Surgery planned
- Molecular Diagnostic – Not available

→ Proven case

- Hospitalized, symptomatic patients with specific indications for CT
  (Complications / worsening)

Key findings

- Peripheral predominant, multiple, Bilateral areas of Ground Glass opacities
- Crazy pavement – thickening of Interlobar & Intralobar septa
- Consolidation – multifocal
- Reverse halo sign/ Atoll sign
- Central ground glassing surrounded by peripheral consolidation

GROUND GLASS OPACITIES (GGO) VS CONSOLIDATION
00:16:28

GGO	Consolidation
• Area of haziness with prominent Bronchovascular Markings • Partial collapse or filling of alveoli • Hounsefield units → -800 to – 100 hu	• Area of haziness with obscured Bronchovascular Markings. A/w air Bronchograms • More exudates filling of alveoli • Hounsefield units → 20 to 30 hu

https://t.me/Latestneetpgnotes

PrepLadder

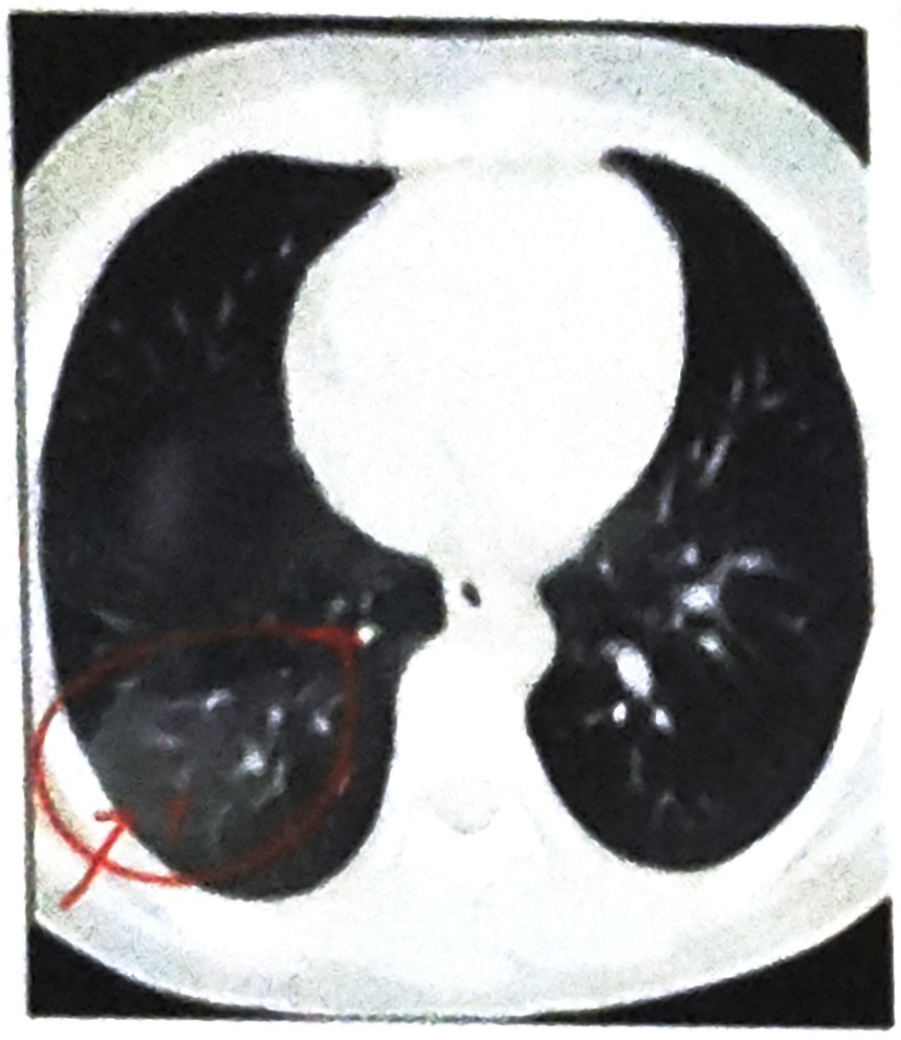	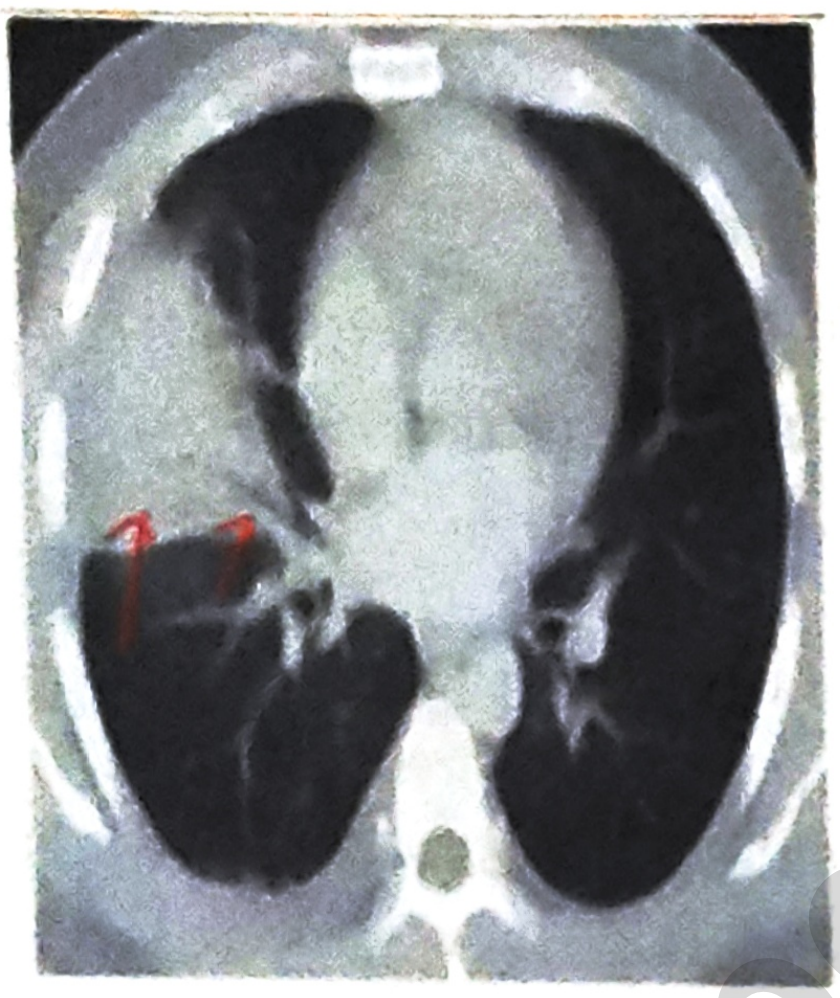
Ground Glass Appearance- Vascular markings can be seen through the haziness	Consolidation- No Vascular markings seen through the opacites, Air Bronchograms are seen



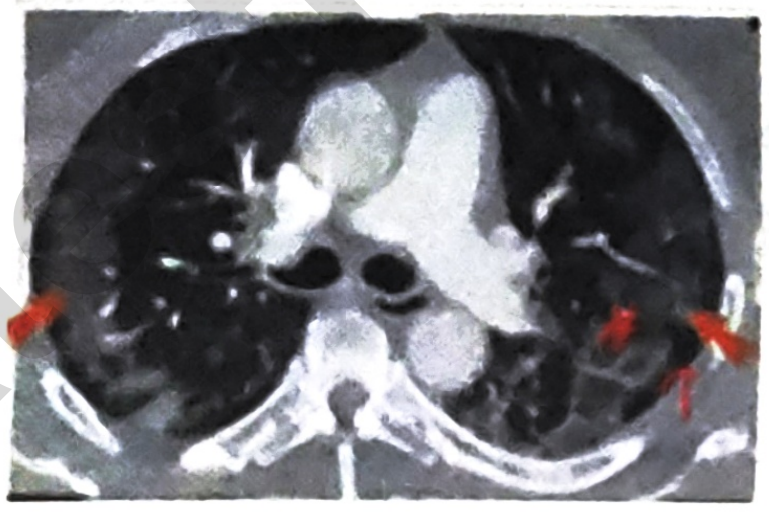

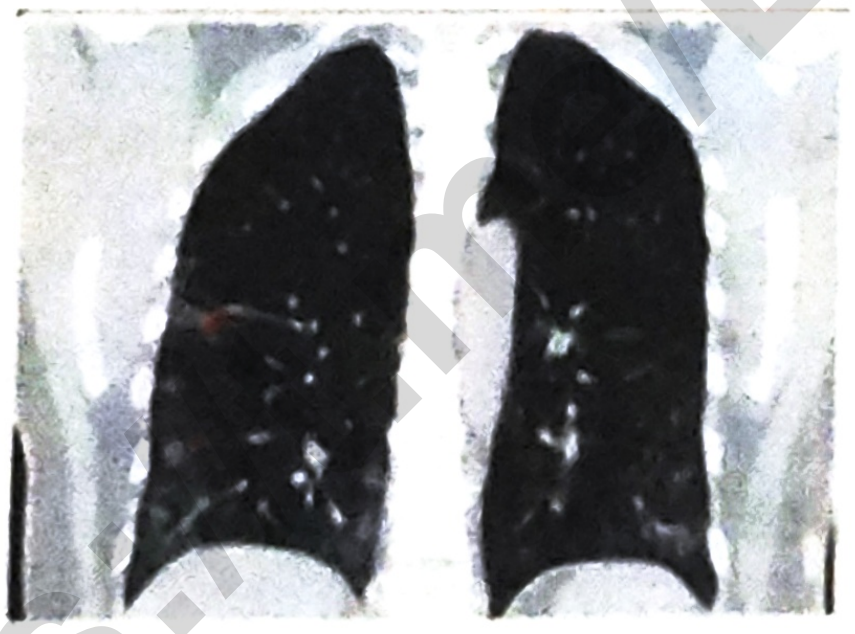

- Multifocal, peripheral, Rounded Ground Glass Opacities

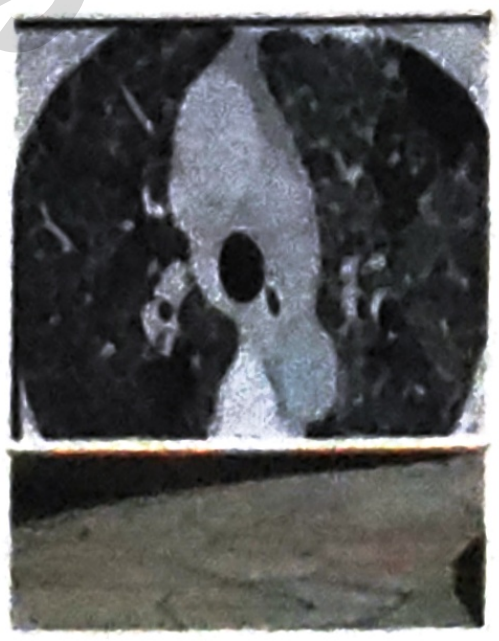

Crazy pavement

Multifocal consolidation

https://t.me/Latestpgnotes

PrepLadder

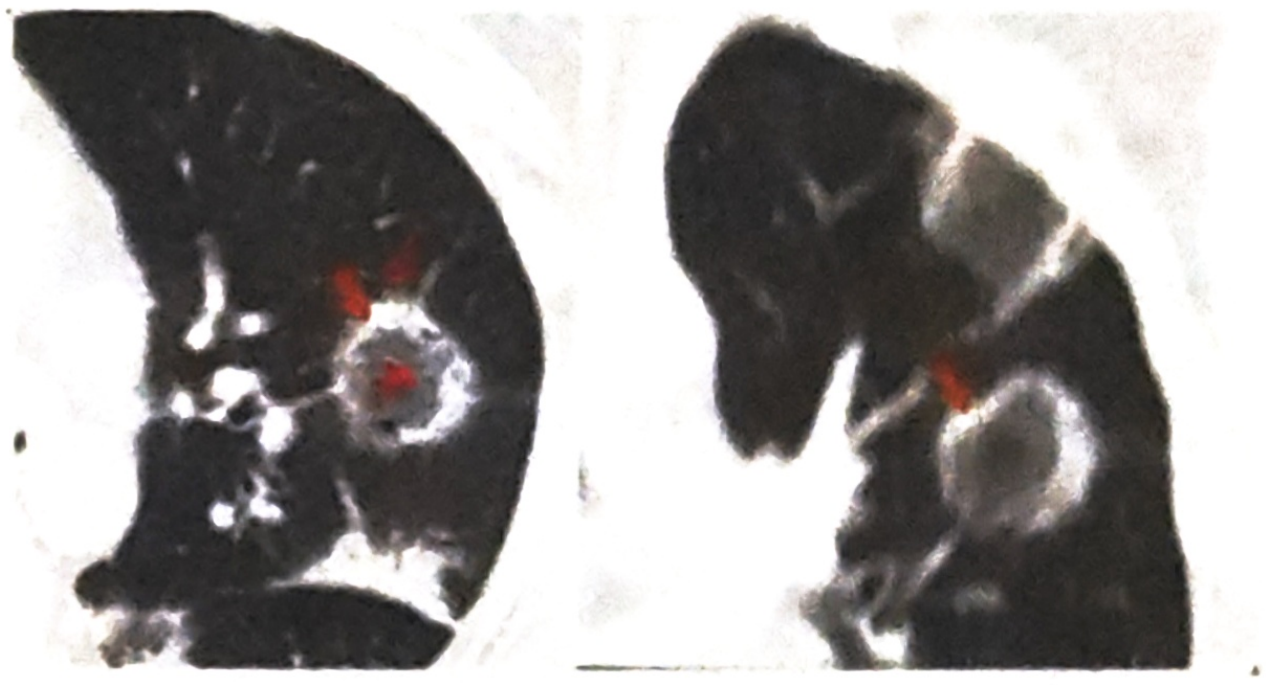

Reverse Halo sign or Atoll sign

Note:

Crazy pavement

- COVID-19
- Pulmonary artery proteinosis

Reverse halo Sign

- COVID-19
- Cryptogenic organizing pneumonia

→ Findings which are NOT SEEN in COVID-19

- Pleural Effusion
- Cavitation
- Pulmonary nodules
- Lymphadenopathy

COVID-19 PNEUMONIA IMAGING CLASSIFICATION 00:22:38

COVID – 19 pneumonia imaging classification	CT findings
Typical appearance	– Peripheral bilateral ground-glass opacity with or without consolidation – Multifocal ground-glass opacity of rounded morphology – Consolidation – Visible intralobular lines ("crazy-paving") – Reverse halo sign
Indeterminate appearance	– Multifocal, diffuse, perihilar, or unilateral ground-glass opacity with or without consolidation lacking a specific distribution and are non-rounded or non-peripheral
Atypical appearance	– Isolated lobar consolidation – Discrete small nodules ("tree-in-bud") – Lung cavitation – Pleural effusion

https://t.me/Latestneetpgnotes

PrepLadder

Q. What does CO-RADS 5 indicate?

a) Mild infection of COVID – 19

b) Moderate infection of COVID – 19

c) Severe infection of COVID – 19

d) Very high suspicion for COVID - 19

Note:

CORADS

→Indicates the level of suspicion of COVID-19

→Not the severity of infection

CO-RADS (COVID-19 REPORTING AND DATA SYSTEM) 00:24:58

	Level of suspicion for pulmonary involvement of COVID-19	Summary
CO-RADS 0	Not interpretable	Scan technically insufficient for assigning a score
CO-RADS 1	Very low	Normal or non-infectious
CO-RADS 2	Low	Typical for other infections but not COVID-19
CO-RADS 3	Equivocal/ unsure	Features compatible with COVID-19 but also other diseases
CO-RADS 4	High	Suspicious for COVID-19
CO-RADS 5	Very high	Typical for COVID-19
CO-RADS 6	Proven	RT-PCR positive for SARS-CoV-2

https://t.me/Latestneetpgnotes

PrepLadder

CT- SEVERITY SCORE

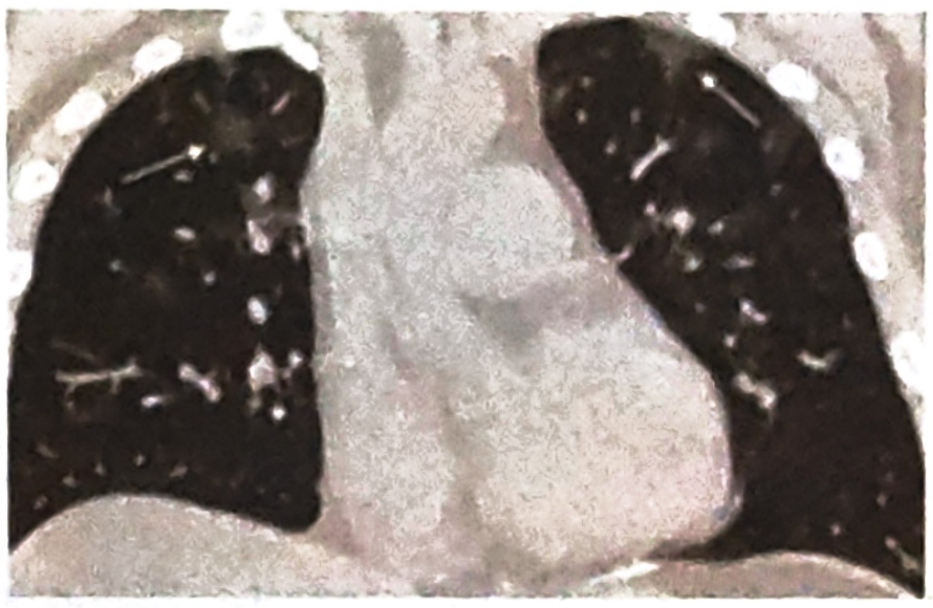

→ Based on the level of involvement, Each lobe have given score between 0 to 5

- Score 0 – No involvement
- Score 5 - › 75%/ Extensive involvement

Maximum CT Severity Score – 5 lobes → 5x5= 25

CT – SEVERITY SCORE

Involved area in each lobe	Score
‹ 5 %	Score 1
5-25%	Score 2
25-50%	Score 3
50-75%	Score 4
› 75%	Score 5

INTERPRETATION OF CT SEVERITY SCORE

Score	CT Severity
‹ 8	Mild
9-15	Moderate
› 15	Severe

Note:

- Suspicion of COVID-19 – CO-RADS
- Severity of COVID-19 – CT SEVERITY SCORE

CHEST CT REPORT FORMAT FOR COVID-19

00:34:38

- Duration of symptoms
- Description of CT findings
- CORADS
- CT severity score
- Additional findings
- Conclusion

https://t.me/Latestneetpgnotes

PrepLadder

Note:

DDX for Viral Pneumonia

- COVID-19
- Influenza
- Organizing pneumonia
- Drug reactions

ULTRASOUND

00:37:20

Uses:

To assess

- The severity of pneumonia
- The progression of ARDS

POCUS

→ Point of care ultrasound

→ Portable

Normal Lung USG

→ Bat wing appearance

→ A – lines – Horizontal reverberation artifacts

→ Lung sliding

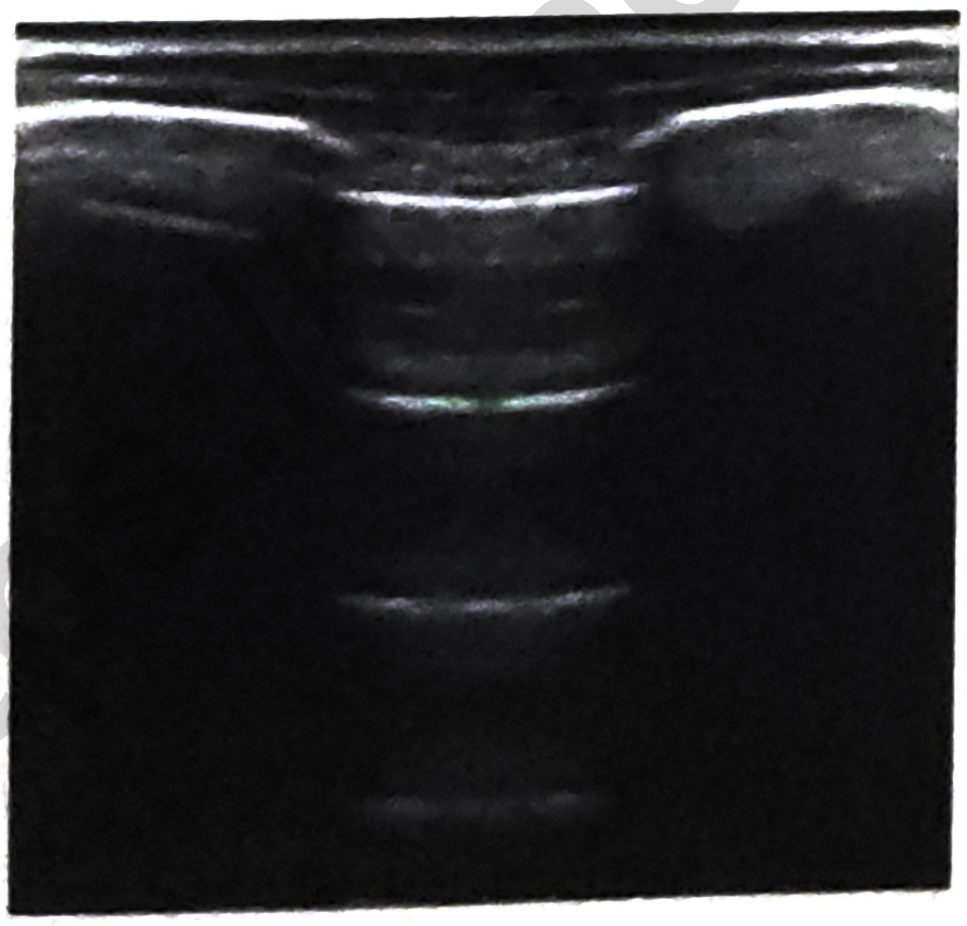

https://t.me/Latestneetpgnotes

PrepLadder

COVID-19 ULTRASOUND



- B-Lines

-Multiple, > 3/ Lung zone, vertical

Not specific for COVID-19

Note:-

- B-Lines seen in
- Interstitial edema
- Cardiogenic/ Non- cardiogenic edema



NUCLEAR MEDICINE

00:41:46

→ Increased uptake of 18- Fluoro- Deoxy Glucose in areas of GGO in patients with COVID-19 have been reported



https://t.me/Latestneetpgnotes

PrepLadder

Chapter 4

X RAY PART (PART 1)

00:00:14

X-RAY

- → First discovered by: W.C. ROENTGEN 8th November 1895
- → X-ray are produced when fast moving stream of Electron produced by Cathode strikes the anode.
- → Properties of X- ray
  - – Electromagnetic radiation
  - – Ionizing radiation
  - – Wavelength: 0.1 – 1A° or 0.01nm - 0.1nm
  - – Speed (same for all electromagnetic radiation) : 3×10^8 mt/sec

X-RAY TUBE

00:01:33

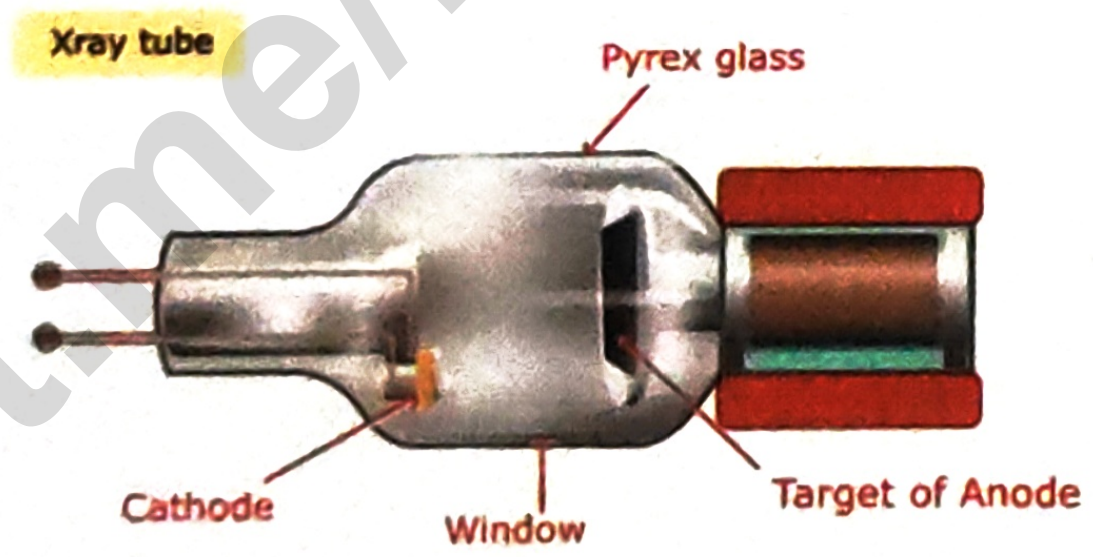

- → Vacuum containing glass tube made of - Pyrex glass
- → Thinning of glass tube allows X Rays to come out- Window of X – ray tube
- → Cathode and target of anode made of – TUNGSTEN
- → TUNGSTEN
  - • High melting point
  - • High tensile strength

https://t.me/Latestneetpgnotes

PrepLadder

Cathode gets heated up due to potential difference
↓
Ejects electron via thermionic emission
↓
Attracted toward target of anode
↓
X Rays are generated
↓
Come out via window of X ray tube



MODERN X RAY TUBE 00:05:39

→ Motor attached - creates rotatory anode

→ Target of Rotatory anode is made of tungsten + Rhenium (to increase tensile strength)

→ Cathode - made of tungsten + thorium (to increase melting point)

→ Major mechanism of Heat loss - Radiation

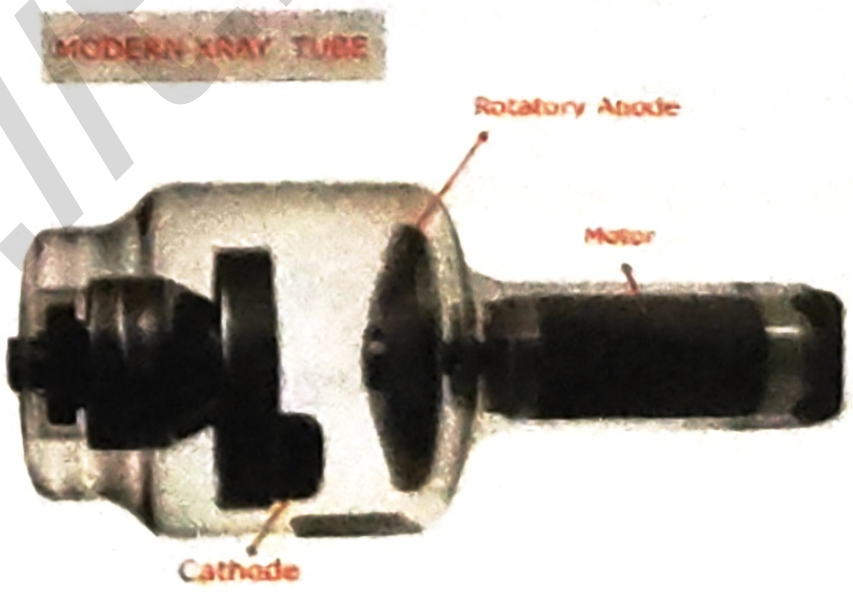

Q. All the statements about modern X-ray tube are true except:

a) cathode is made of Tungsten and Thorium

b) Anode is made up of Tungsten and Rhenium

c) Major mechanism of Heat loss is by Radiation

d) Rotatory Cathode is used

PrepLadder

https://t.me/Latestneetpgnotes

Stationary Anode

→ Dental Radiographs

→ Portable X-rays



Anode	
Modern X ray Tube	Tungsten +Rhenium
Mammography	Molybdenum
Dense Breast Mammography	Rhodium

Q. Chief source of X – Ray generation in Radiology?

a) Thermionic emission

b) Bremsstrahlung radiation

c) Photoelectric effect

d) Compton effect

Ans. b) Bremsstrahlung radiation

00:11:05

Thermionic emission → At cathode → Generation of electron beam	Bremsstrahlung radiation/ Braking radiation → Chief source of X-ray generation in conventional radiography → Leads to generation of Continuous spectrum of varying energies of X-ray 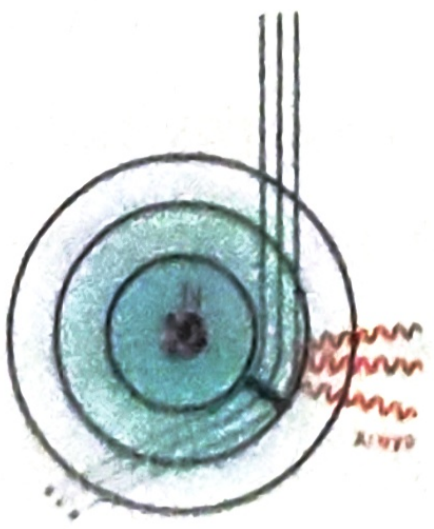

https://t.me/Latestneetpgnotes

Photoelectric effect

- → Low energy photon interaction with inner shell electron
- → Leads to generation of Characteristic X- rays
- → Chief source of X-ray generation – Mammography
- → Depends on the Atomic number of the element used.

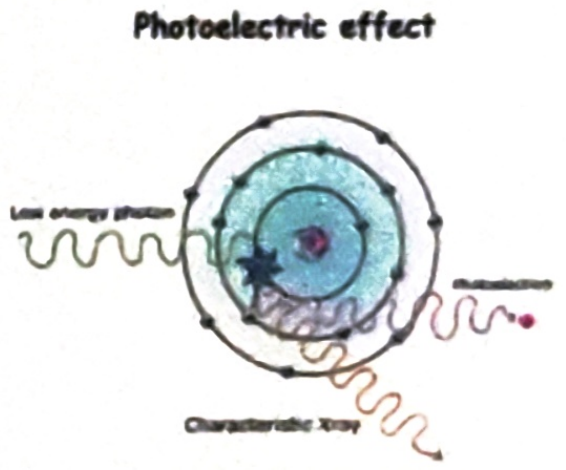

Compton effect

- → High energy photon interaction with outer shell electron.
- → Leads to generation of scatter radiation
- → Chief Source of X-Ray generation
- – Diagnostic radiology

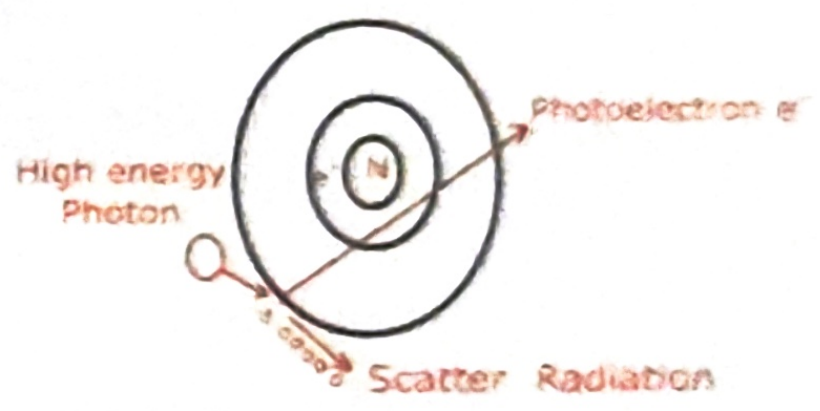

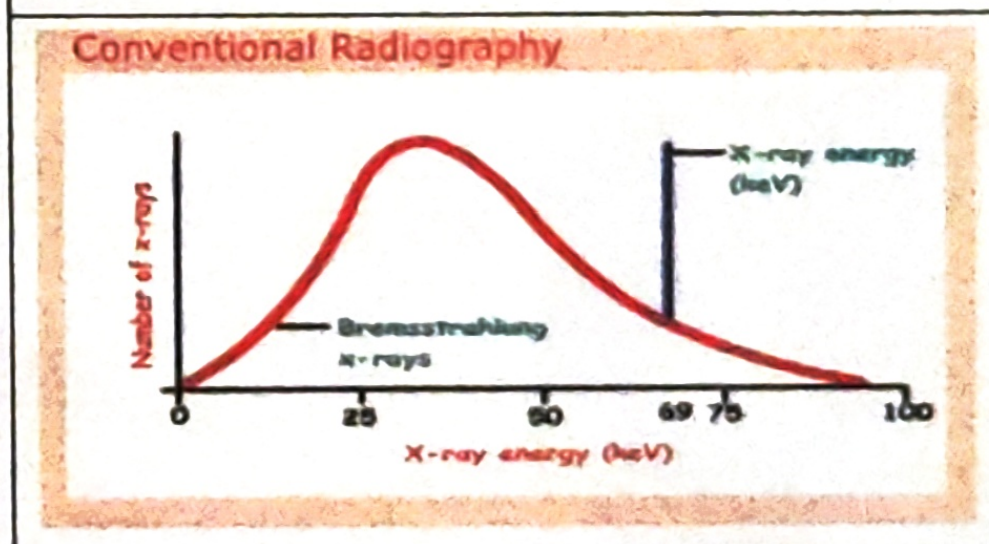

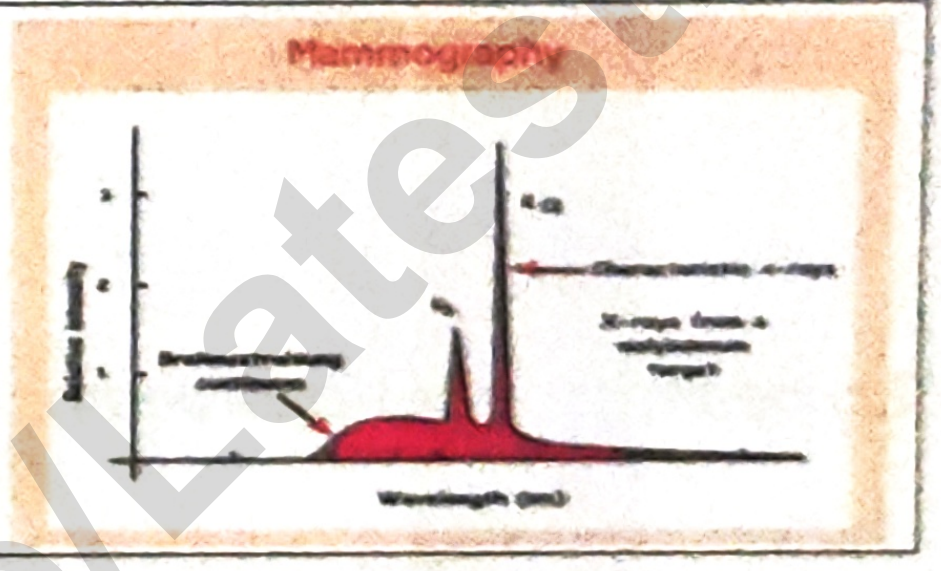

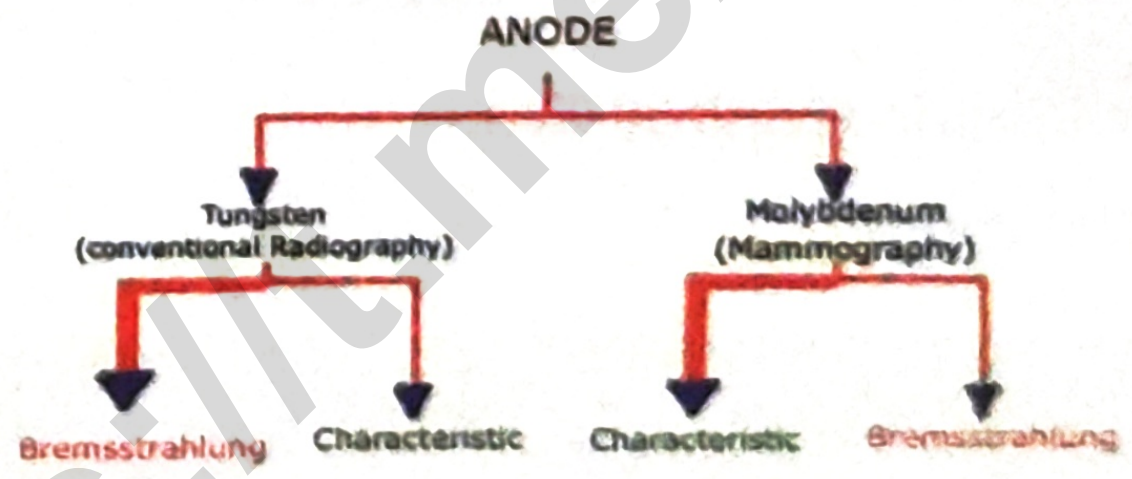

00:23:49

Photoelectric effect	Compton effect
Low energy photon interaction	High energy photon interaction
Interaction with inner shell electron	Interaction with outer shell electron
All of the energy of photon is used up	Only a part of photon energy is used
Photoelectron, positive charged ion, characteristic X-ray	Photoelectron, Positive charged ion, scatter Radiation

https://t.me/Latestneetpgnotes

PrepLadder

Q. Photoelectric effect is interaction of

a) High energy photon with innermost shell electron

b) Low energy photon with outermost shell electron

c) High energy photon with outermost shell electron

d) Low energy photon with innermost shell electron

Q. Only Part of Photon Energy is used in

a) Thermionic Emission

b) Bremsstrahlung Radiation

c) Photoelectric Effect

d) Compton Effect

→ Filter

00:26:59

- Made of Aluminum
- Filters out low energy X-ray.

→ Cones / collimation

- Made of lead
- Convert divergent X Ray beam to directional beam

→ GRID

- Parallel lead lines kept behind patient and in front of film.
- Prevents scatter radiation from the image.
- Improve image contrast
- Increases radiation dose.

→ X-ray film

- Made of Silver bromide or Silver halide
- When X-ray fall on X-ray film it turns black.

→ Safe light used in DARK ROOM PROCEDURES: - Red light

https://t.me/Latestneetpgnotes

PrepLadder



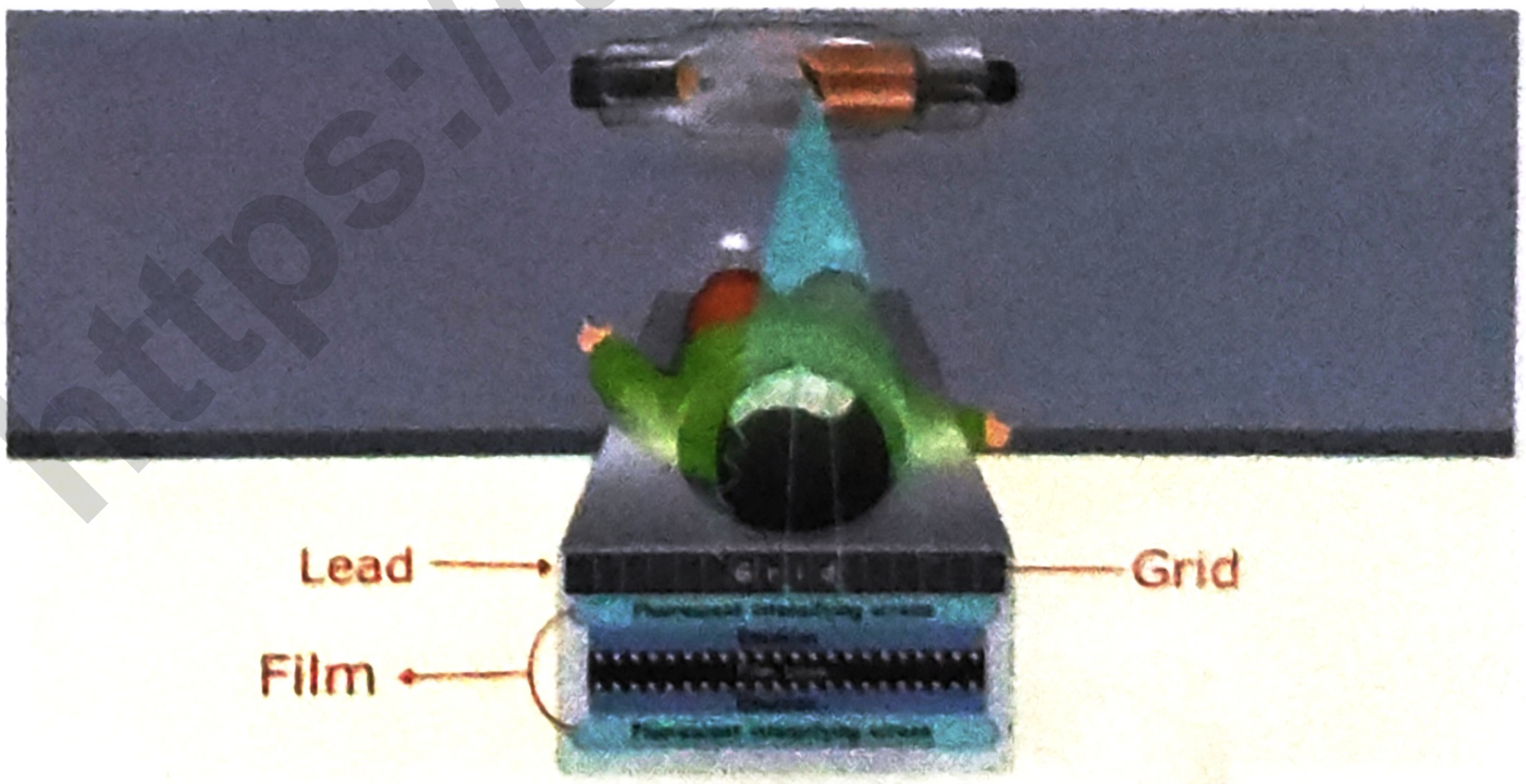

https://t.me/Latestneetpgnotes

PrepLadder

Chapter 5

X RAY PART 2

00:00:16

Component	Material used
X-ray Tube	Pyrex Glass Tube
Cathode	Tungsten
Anode	Tungsten
Window	Thinning of Glass Tube
Filter	Aluminium
Collimator	Lead Plates
Focusing Cup	Nickel
Protective housing	Lead Lined Metal case
x-ray Film	Silver Bromide Emulsion
Safe Light	Red Light

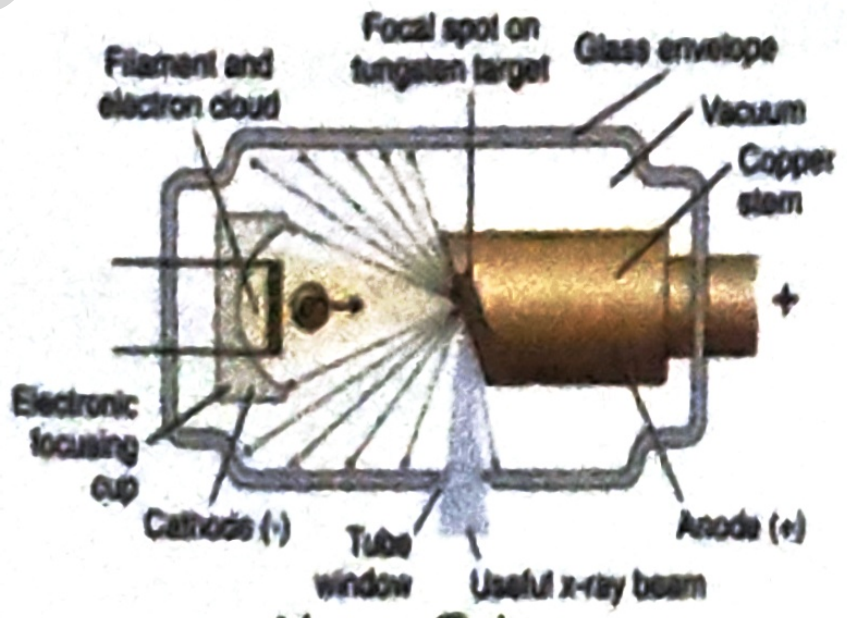

X-ray Tube

Protective Housing



https://t.me/Latestneetpgnotes

PrepLadder

X-Ray interaction with Matter

00:03:00

- Cohorent scattering (energy < 10 KeV)
- Compton scattering
- Photoelectric effect

} Relevant to X-ray imaging (Compton scattering, Photoelectric effect)

- Pair production (energy > 1.02 MeV)

00:04:07

KVp (Kilovoltage Peak)	Milliampere second (mas)
KVp α energy α Quality of X-ray α penetration α $\frac{1}{\text{contrast}}$ → Chief determinant of contrast of X Ray film: KVp → Therefore to improve contrast → decrease KVp	→ Milliampere – Current (no. of electrons/ Unit area) → Seconds – Exposure time → Mas ∝ Quantity ∝ Number of x ray ∝ Blacking of film ∝ Contrast

NOTE:

1) Contrast – the ability to differentiate black from white
2) To improve contrast of an X – Ray film - ↓ KVp / ↑mas
3) To improve contrast of an X – Ray film in a morbidly obese patient - ↑ mas

Over Penetrated Too high KVp

Over Penetrated View have too much kVp

https://t.me/Latestneetpgnotes

PrepLadder

Under exposed – Very low mas	Correct exposure – Good mas	Over exposed – High mas

00:13:16

	Quality	Quantity
KVP	↑ (primary)	↑
mas	No change	↑ (primary)
Time	No change	↑
Filtration	↑	↓

Q. What should be done to improve contrast of X-ray film in a morbidly obese patient?

a) Increase Kvp

b) Increase mas

c) Decrease Kvp

d) Decrease mas

MAMMOGRAPHY

00:16:40

→ X-ray Technique (low energy X – rays (low kV and high mA))

→ Used to evaluate or screen patients with Breast cancer.

Guidelines

→ American College of Radiology-suggests Annual SCREENING Mammography to be done in females above the age of 40yrs

→ American Cancer Society –suggests Annual Screening Mammography to be done in females above the age of 45 yrs

→ If the patient Is BRCA +, Strong Family History of Breast cancer – screening can be started between 25-30 years

https://t.me/Latestneetpgnotes

Difference between Mammography & Conventional X-Rays

Feature	Mammography	Conventional X Rays
Anode	Molybdenum	Tungsten
Filter	Molybdenum	Aluminum
Exit window	Beryllium	Glass
Compression device	Yes	No
KVp	Low (20-30kv)	Higher (60-70 kv)

Note:

Avoid using Mammography in painful condition like:

→ Mastitis

→ Breast Abscess

Standard Views

→ 2 views from each breast

- Right craniocaudal view
- Right mediolateral view
- Left craniocaudal view
- Left mediolateral view

Note:

Craniocaudal View – Lateral & Medial aspect of Breast

Medial Lateral Oblique view – Upper & lower quadrant + Axillary Tail

– Maximum breast tissue evaluation

https://t.me/Latestneetpgnotes

PrepLadder

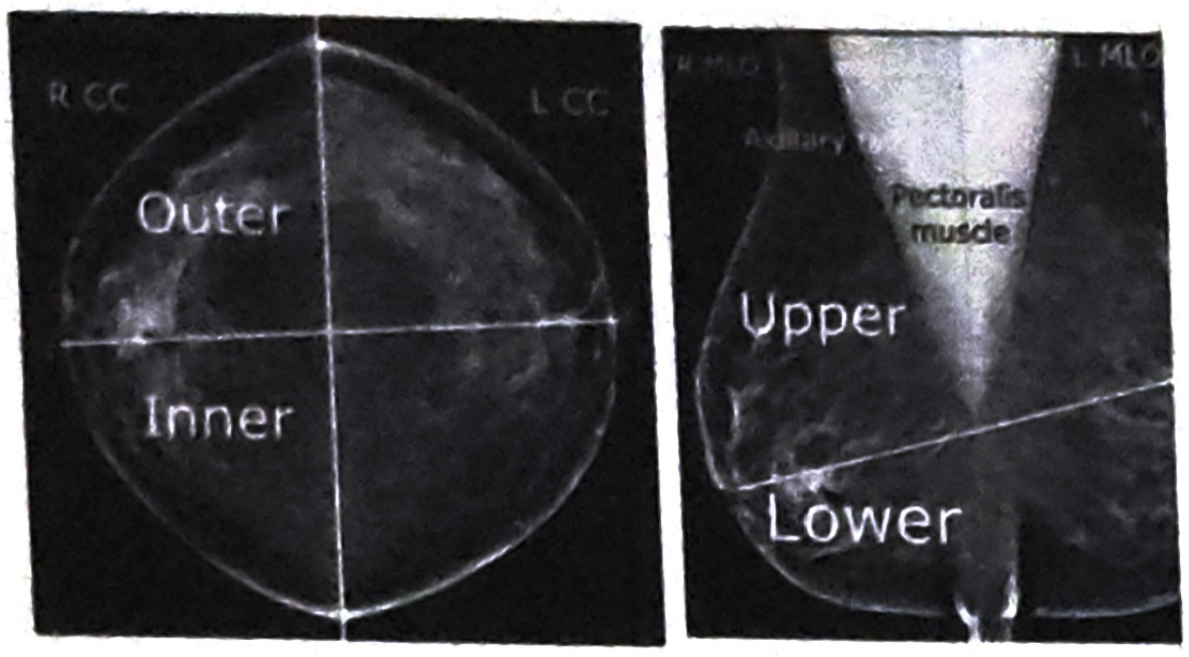

Digital Tomosynthesis

00:27:09

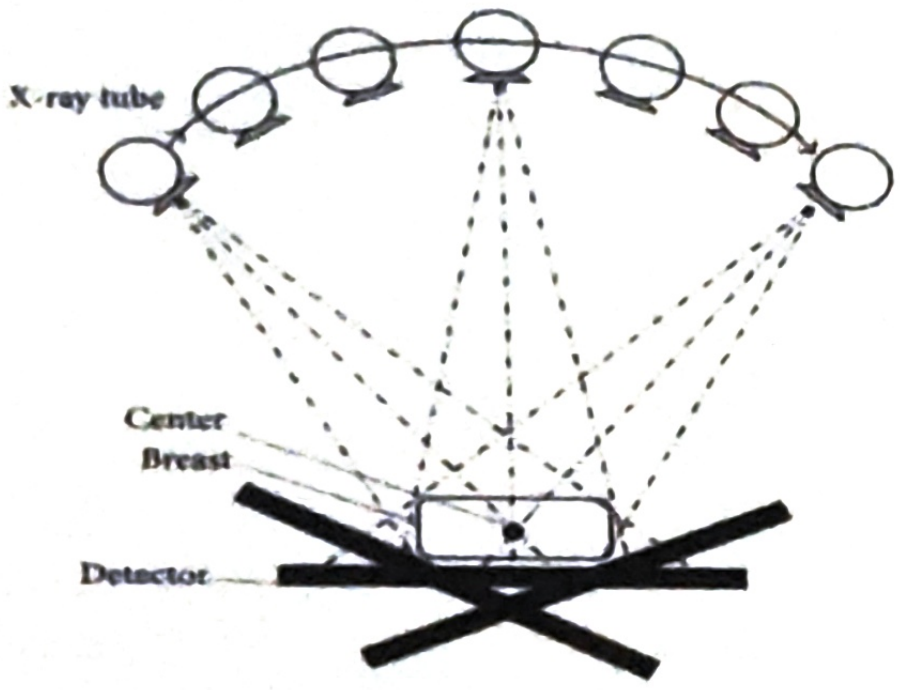

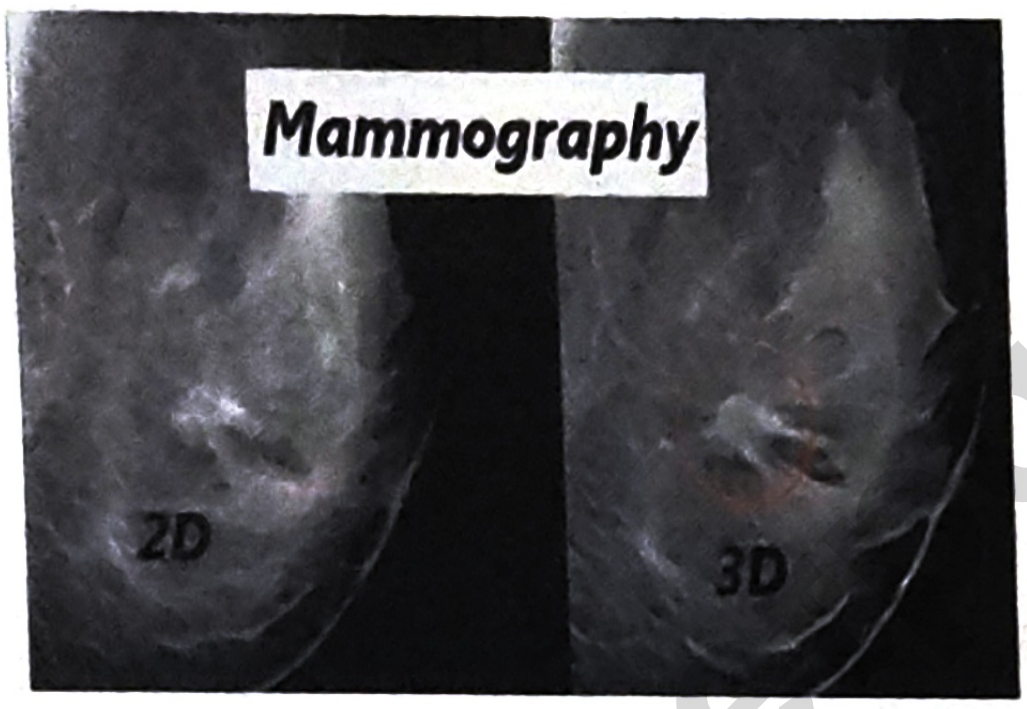

→ In this, X-ray tube rotates in the form of an arch and take multiple images across the lesion.
- Better evaluation of the lesion

→ Routine mammography – 2 D Images
- Leading to the superimposition of Normal Tissues

→ Digital Tomo synthesis – 3 D images
- Avoid the superimposition

Features suggesting of malignancy on mammography

00:29:33

- Irregular borders
- Architectural distortion
- Microcalcification clusters – Fine, Linear Branching (<0.5mm; >10 in numbers)



https://t.me/Latestneetpgnotes

PrepLadder

Features suggesting of benign lesion on mammography

- Well defined regular border
- Fat content present (e.g. Lipoma, Galactocele, hamartoma)
- Macro calcification

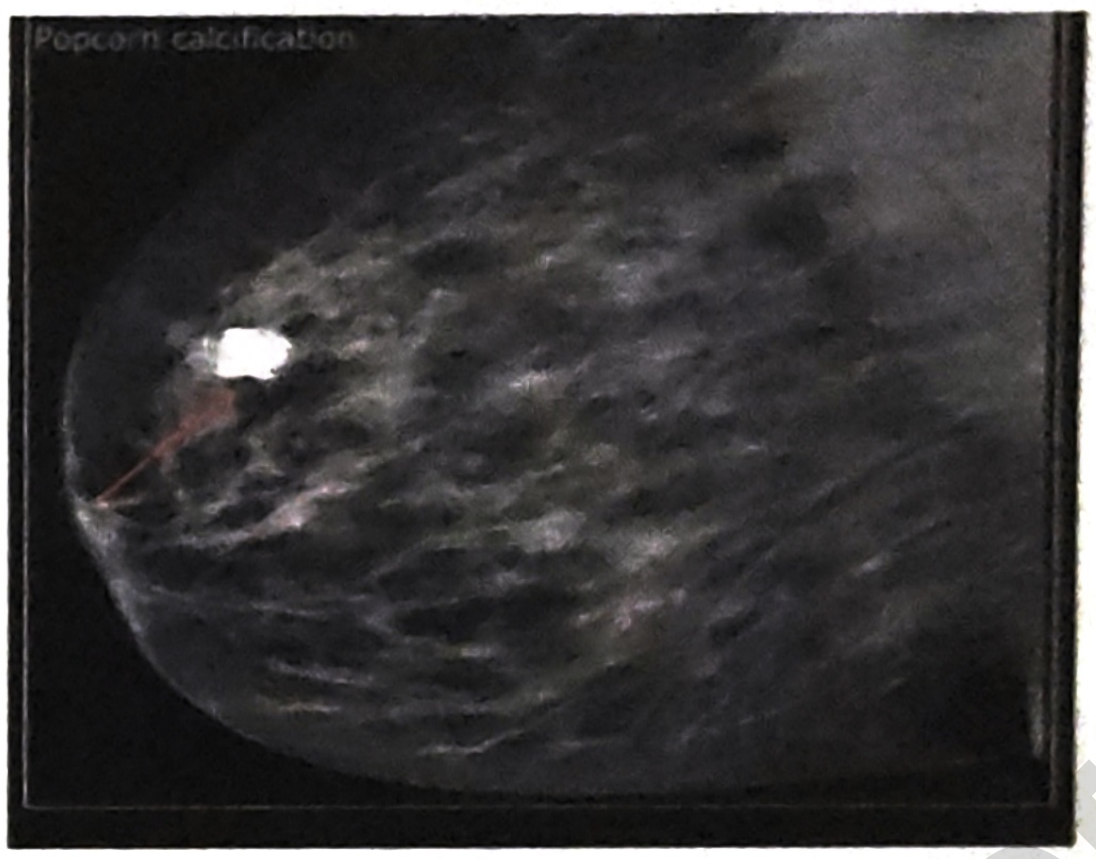

Note:

→ Popcorn calcification on mammography → Features of fibroadenoma

→ Dense POPCORN Calcification on chest X ray → Pulmonary hamartoma

→ POPCORN calcification on MRI - BRAIN → Cavernous angioma

→ POPCORN calcification on pelvic radiography
  - Chondrosarcoma

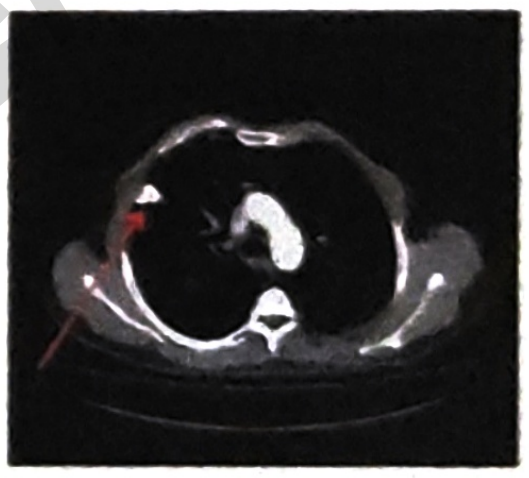

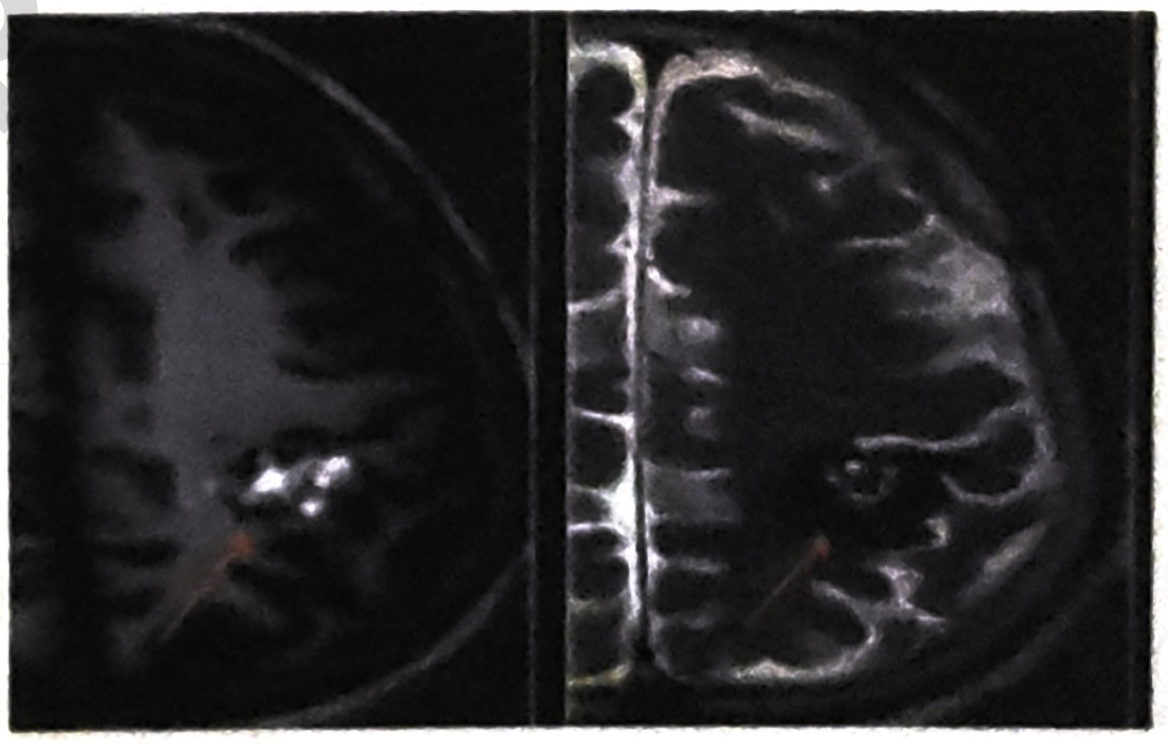

https://t.me/Latestneetpgnotes

PrepLadder

00:35:10

Different densities according to differential attenuation:

→ 5 X ray densities
- Air
- Fat
- Soft tissue/ Fluid
- Bone
- Metal

→ Most radio opaque / Radio dense - metal (white)

→ Most radio lucent – air (Black)

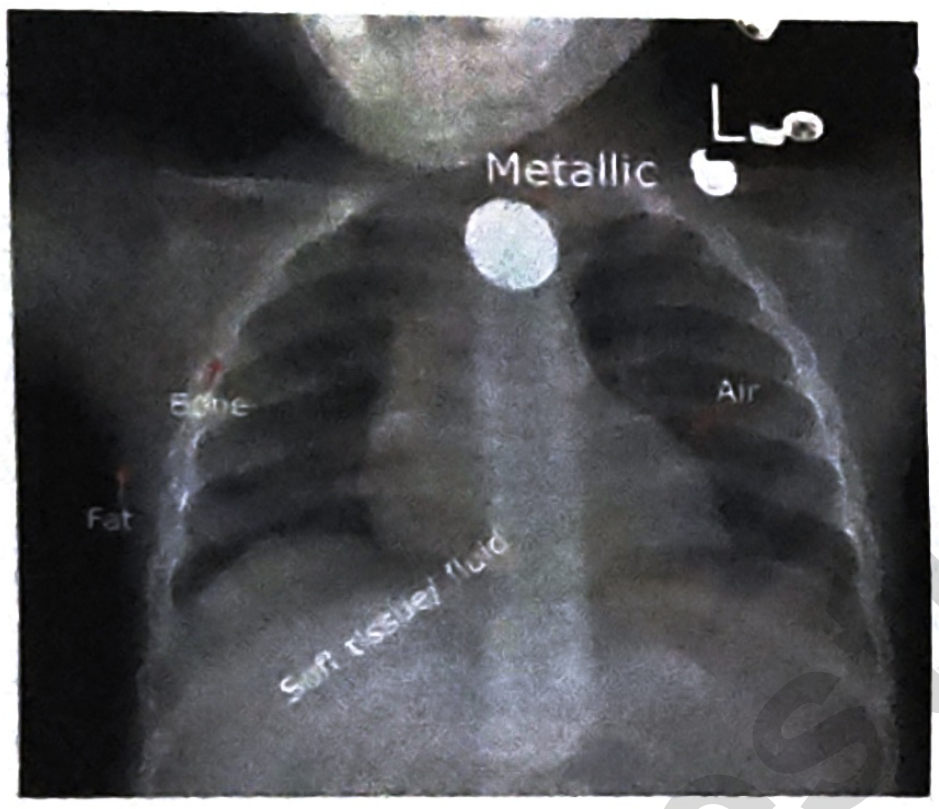

Note:

→ Battery – Present with Double Rim.

→ Coin – No Double Rim

Coin in Esophagus	Coin in Trachea
→ Coronal Plane → Air stripe Located anterior to it.	→ Sagittal plane (because of larynx) → Air stripe located within or near to the coin
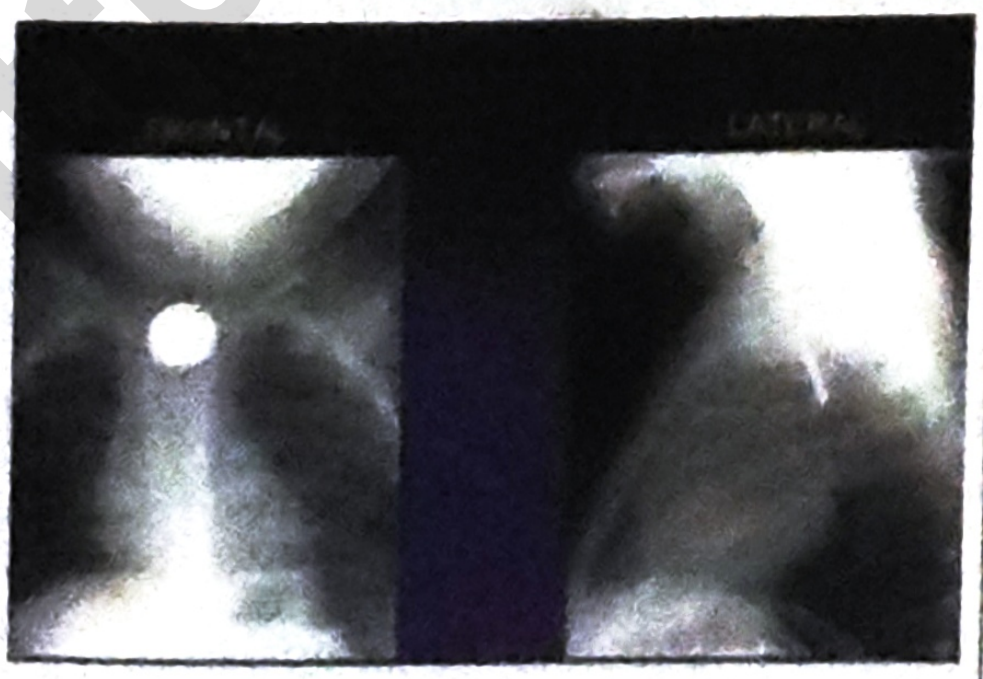	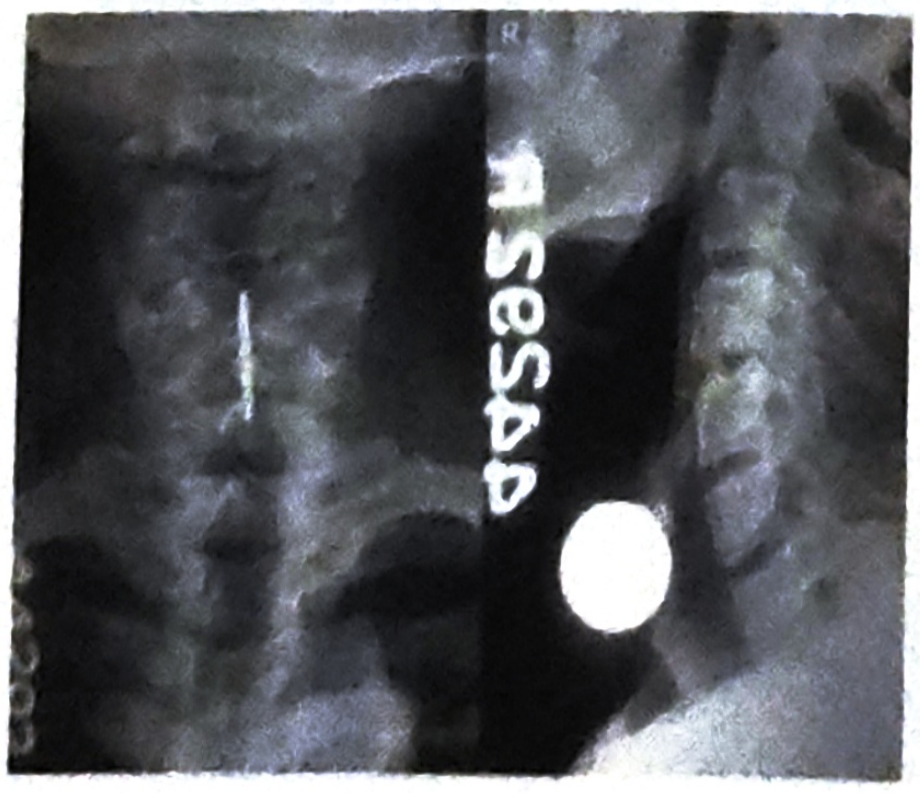

https://t.me/Latestneetpgnotes

PrepLadder

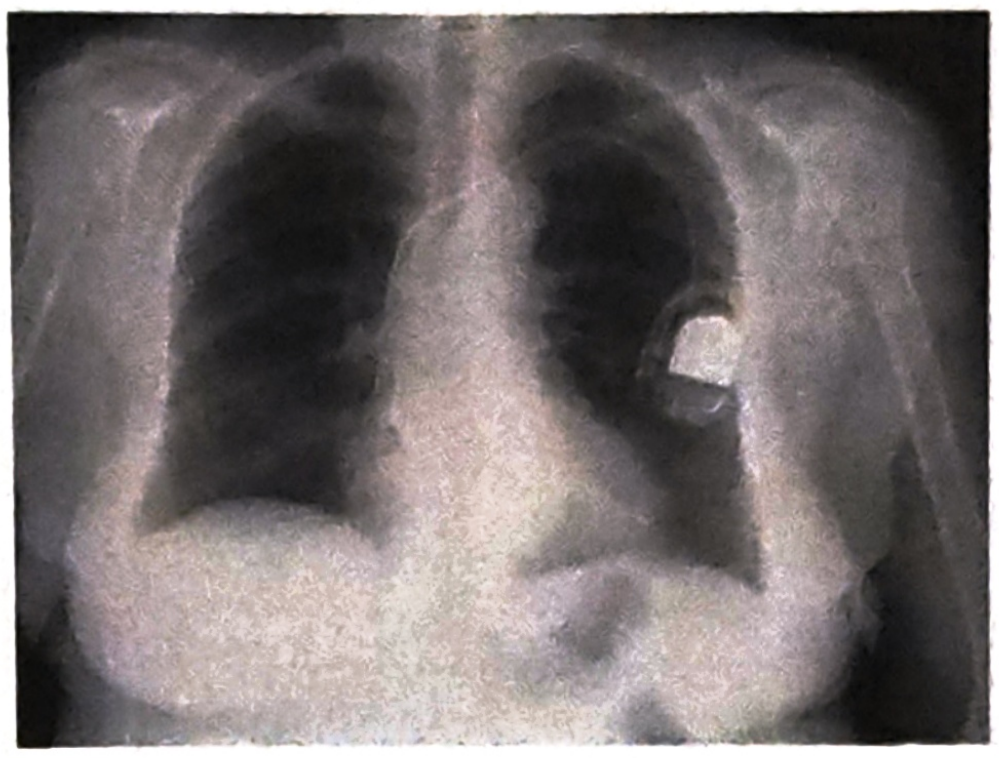

Cardiac Pacemaker

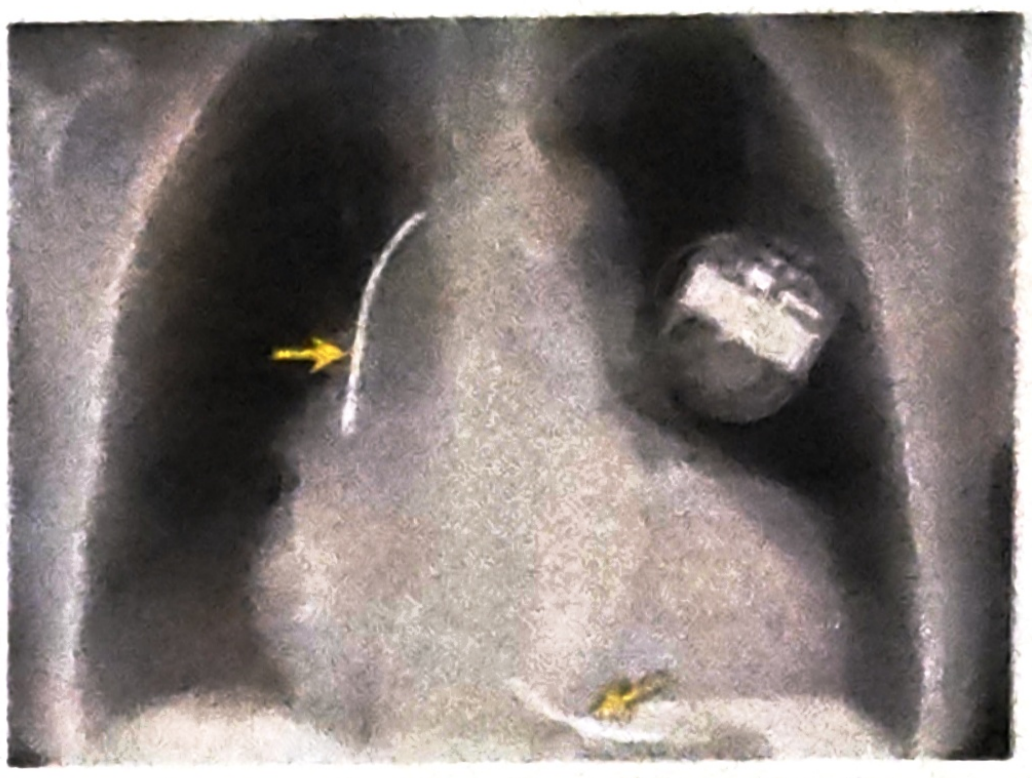

Implantable Cardioverted Defibrillator

Q. Best method to know the position and integrity of Implantable Cardioverter Defibrillator is:

a) Plain Radiograph

b) MRI

c) USG

d) CT scan

Q. A woman injured her fingers due to a broken glass, What investigation is to be ordered initially if glass is suspected to be retained inside?

a) Plain Radiograph

b) CT Scan

c) MRI

d) Ultrasonography

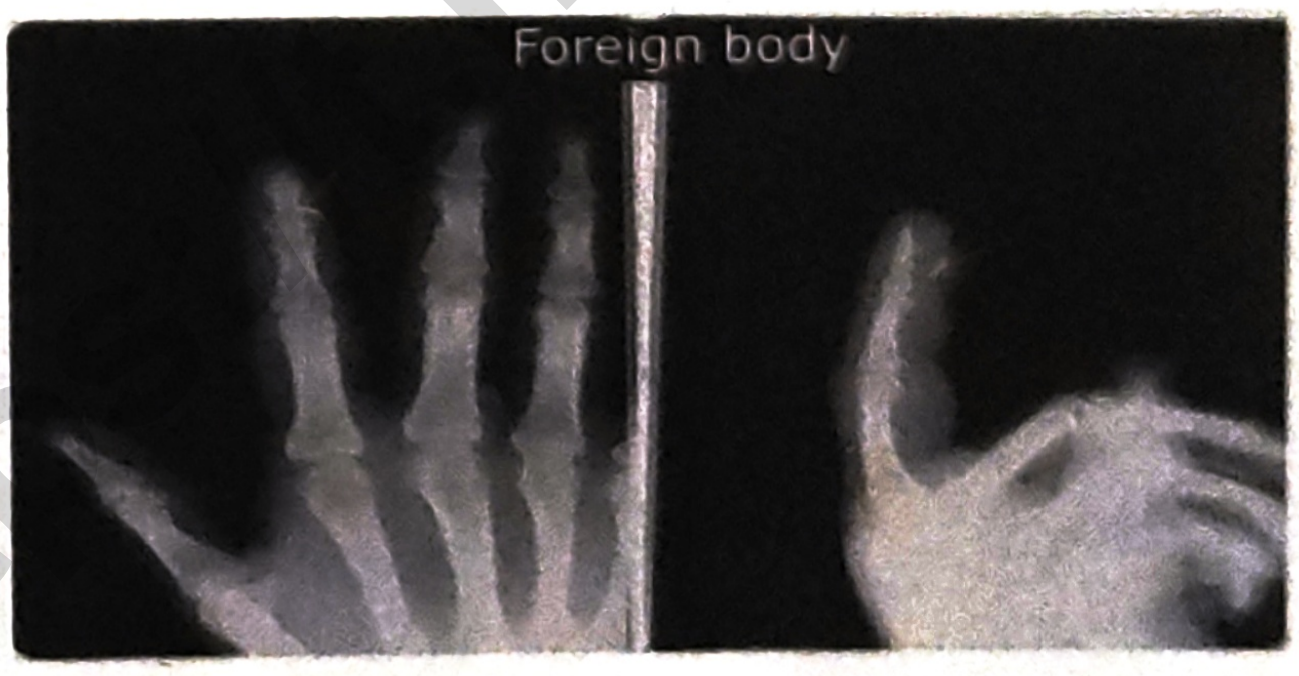

Foreign body in the hand

Note:

→ Glass, Metal - Radiodense → Radiography

→ Plastic, Wood - Ultrasound (Initial Investigation)

https://t.me/Latestneetpgnotes

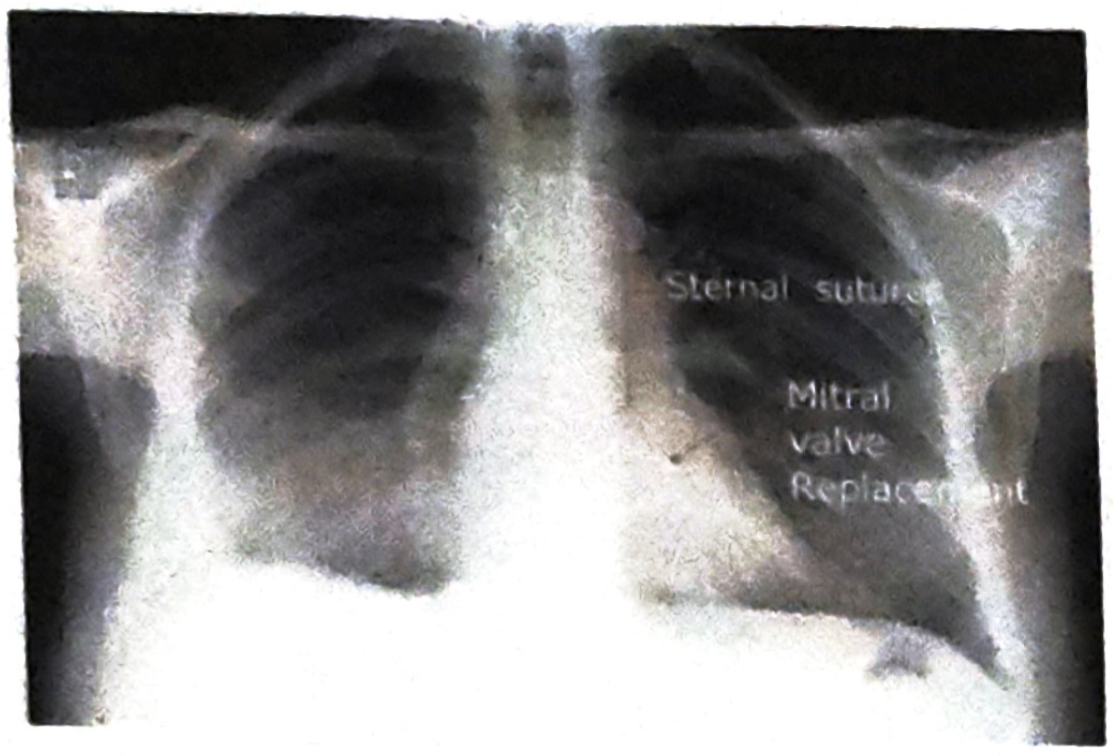

Mitral valve replacement X-ray

Gingko leaf sign on chest X-ray

→ Radiating lucencies along pectoralis muscle in CXR – Gingko leaf sign

→ Seen in subcutaneous emphysema / surgical emphysema

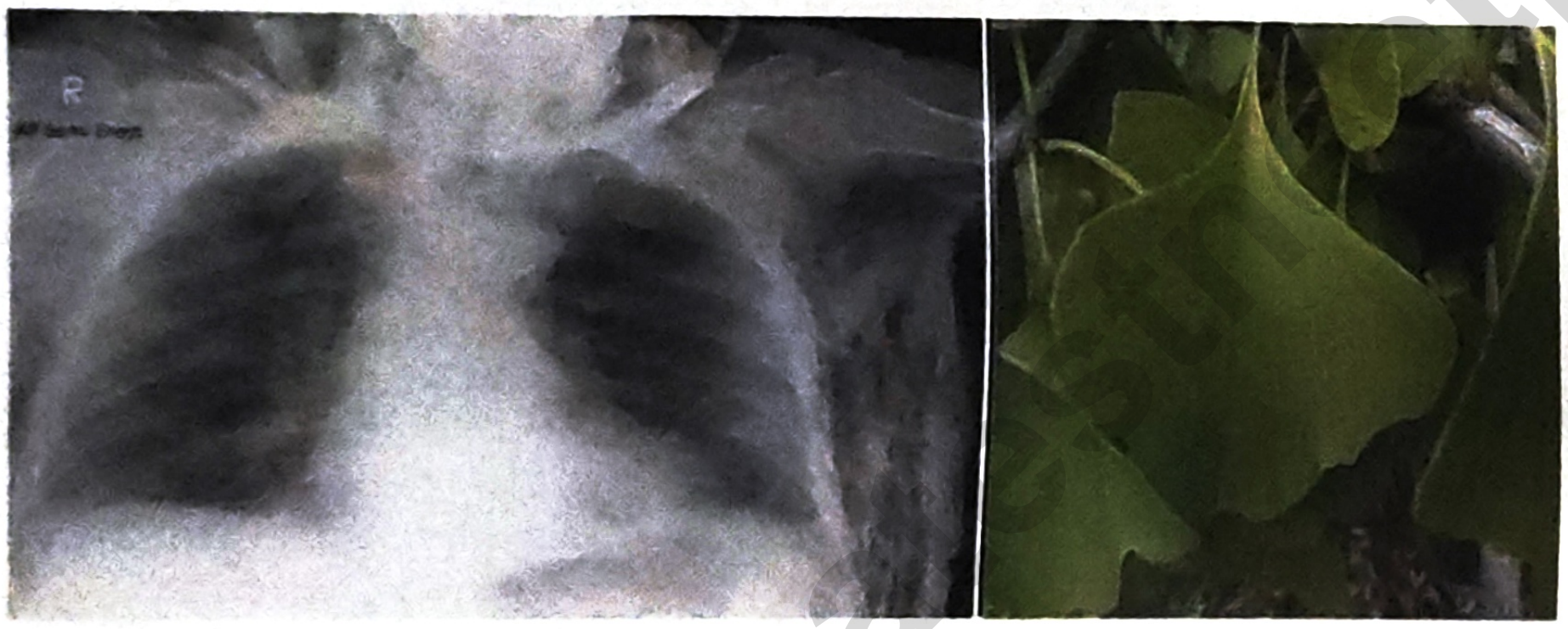

Subcutaneous Emphysema - Gingko leaf sign

POLAND'S syndrome (Congenital)

→ Absence of pectoralis muscle breast tissue on one side

→ On CXR – absent breast shadow on one side

→ Can also be postmastectomy status

→ Evaluate the metastatic deposits in bones & Lungs in such cases.

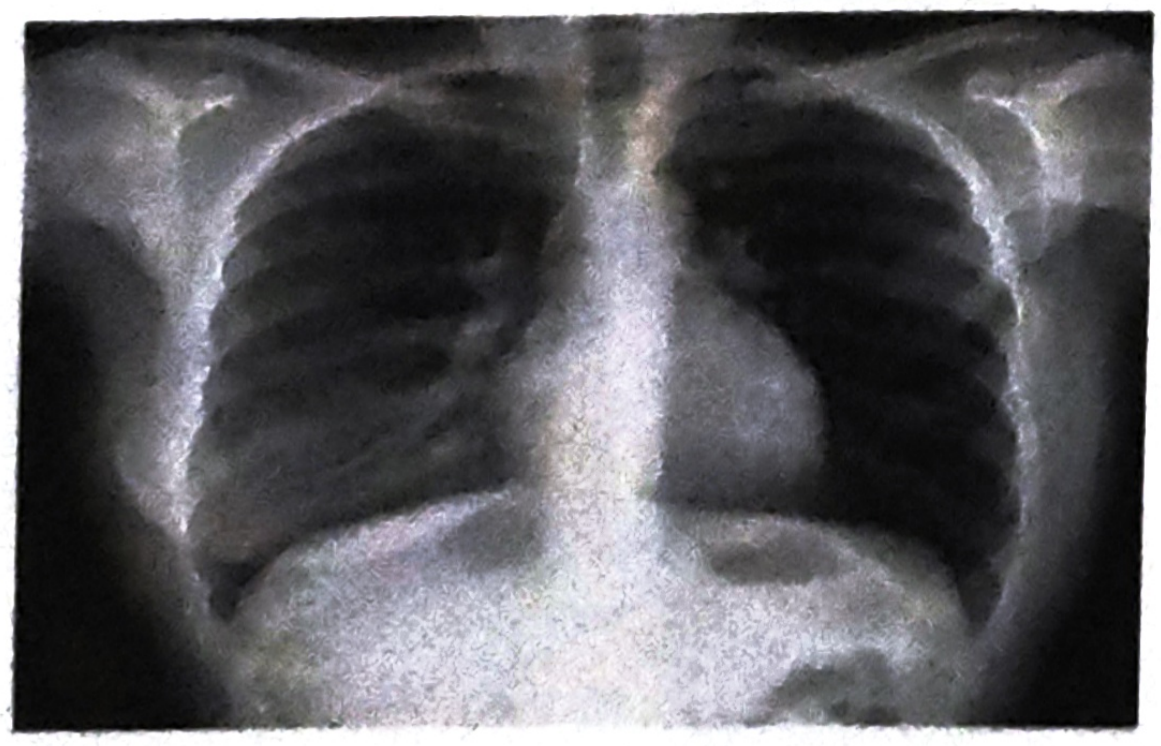

Absence of Breast shadow in the left side

https://t.me/LatestPGnotes

00:45:10

Important X ray Views	
Chest x-ray PA View	Most commonly performed in full inspiration
Chest x-ray AP View	Trauma, supine [Comatose, ventilated]
Ipsilateral Lateral Decubitus View	Pleural effusion → Best view
Lordotic View	Lung apex, middle lobe pathologies
Chest x-ray Erect	Best X ray view - pneumoperitoneum, Hollow viscus perforation
Abdominal Radiograph	Preferred X-ray view for intestinal obstruction

Note:

- → Expiratory CXR PA – Pneumothorax.
- → IOC for pleural effusion – Ultrasound
- → Air under Diaphragm
  - – Pneumoperitoneum
  - – Hollow viscus perforation
- → IOC for pneumoperitoneum – CT scan
- → Best of Intestinal Obstruction – CE-CT

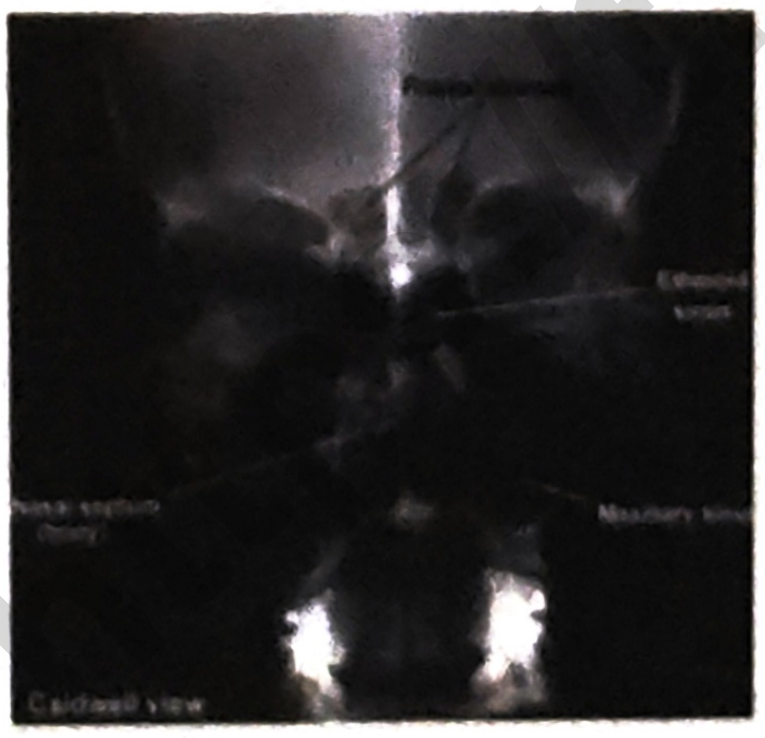

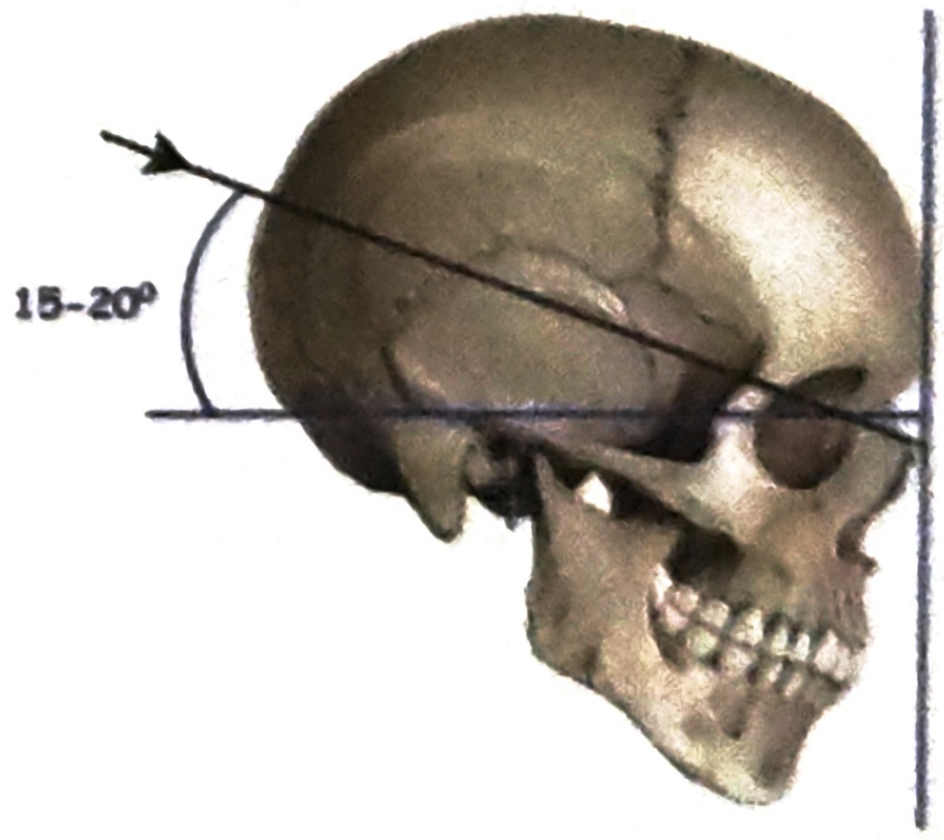

Caldwell View

t.me/Latestneetpgnotes

PrepLadder

Important X-ray Views	
Caldwell View	Occipito Frontal View for Frontal Sinus And superior orbital Fissure
Water view	Occipitomental View For Maxillary sinus and Orbital Floor
Pierre View	Occipitomental View with Open Mouth
Townes View	Skull AP view with 30 degree Angulation for Foramen Magnum, Dorsum sella and Petrous bones and Inferior orbital fissure
Rhese View	Optic Canal/Orbital Foramen
Stenvers view	Internal Auditory canal, petrous temporal bone
Lateral Skull x-ray	Sella
Odontoid view	C1/C2 Fracture -Dens Fracture
Skyline view	Patella
Strykers view	Hill Sachs Lesion
Judet view	Acetabulum
Von rosen view	Developmental Dysplasia of Hip

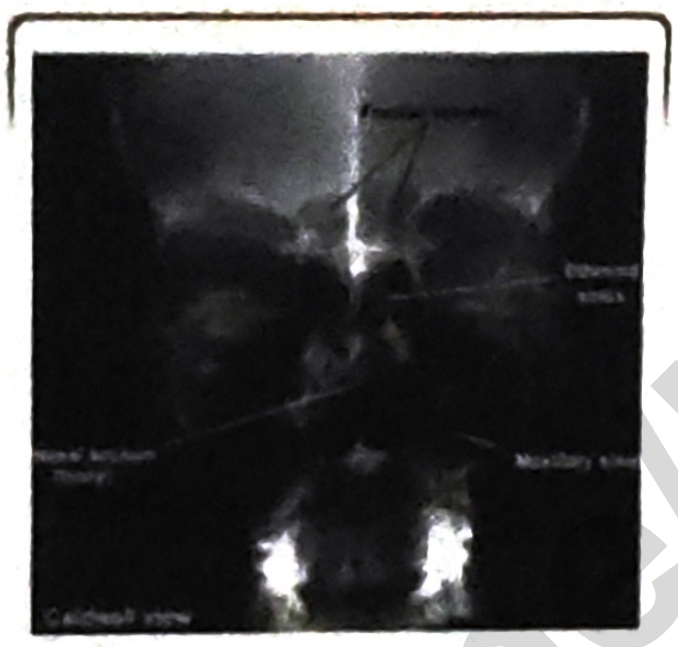

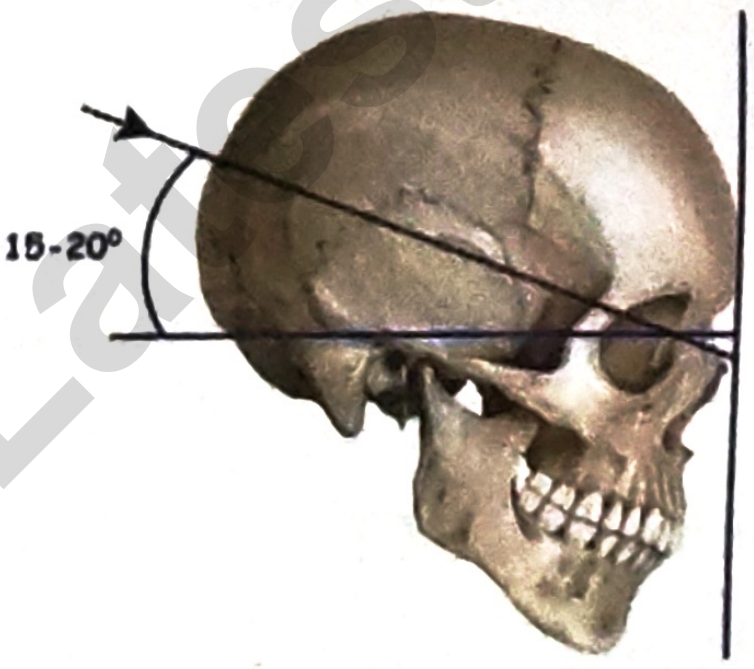

Water view (occipito mental view)

POINTS TO REMEMBER

AREA	VIEW
Superior orbital fissure	Caldwell view
Inferior orbital fissure	Towns view
Orbital floor/ maxillary sinus	Water view
Optic canal/ Orbital foramen	Rhese view

https://t.me/Latestneetpgnotes

PrepLadder

Computerized radiography VS Direct digital radiography 00:54:18

Computerized radiography	Direct digital radiography
Photostimulable phosphor plate ↓ Laser beam ↓ Electronic Image	Fixed electronic panel (amorphous selenium) X-rays ↓ Electronic image
Slower worker flow	Faster work flow
Variety of X-rays can be taken	Variety of X-rays cannot be taken
Phosphor plate can be reused	

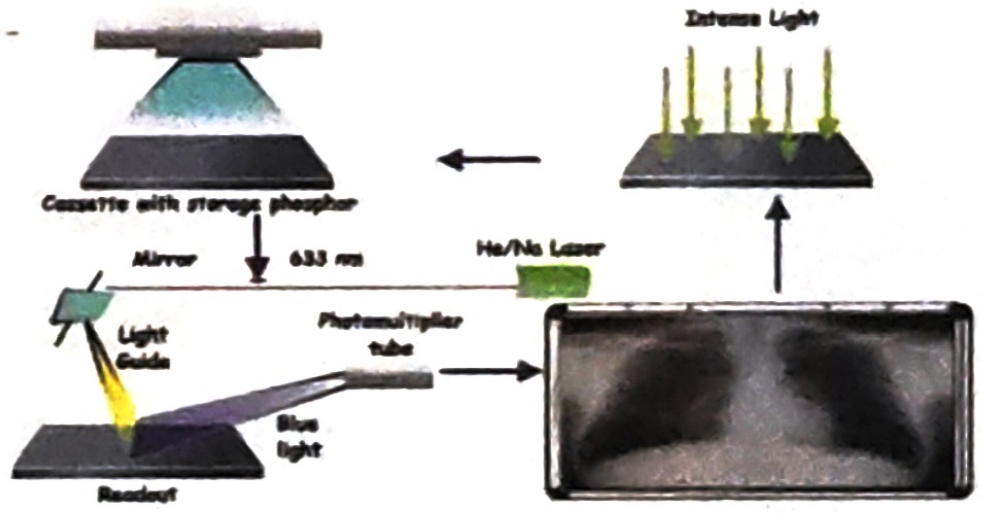

Computerized radiography

Image reader

Direct Digital Radiography

Other uses of X-rays 00:59:27

→ Placement of ET-Tube

- Tip of ET-Tube should be > 5 cms from carina.

https://t.me/Latestneetpgnotes

PrepLadder

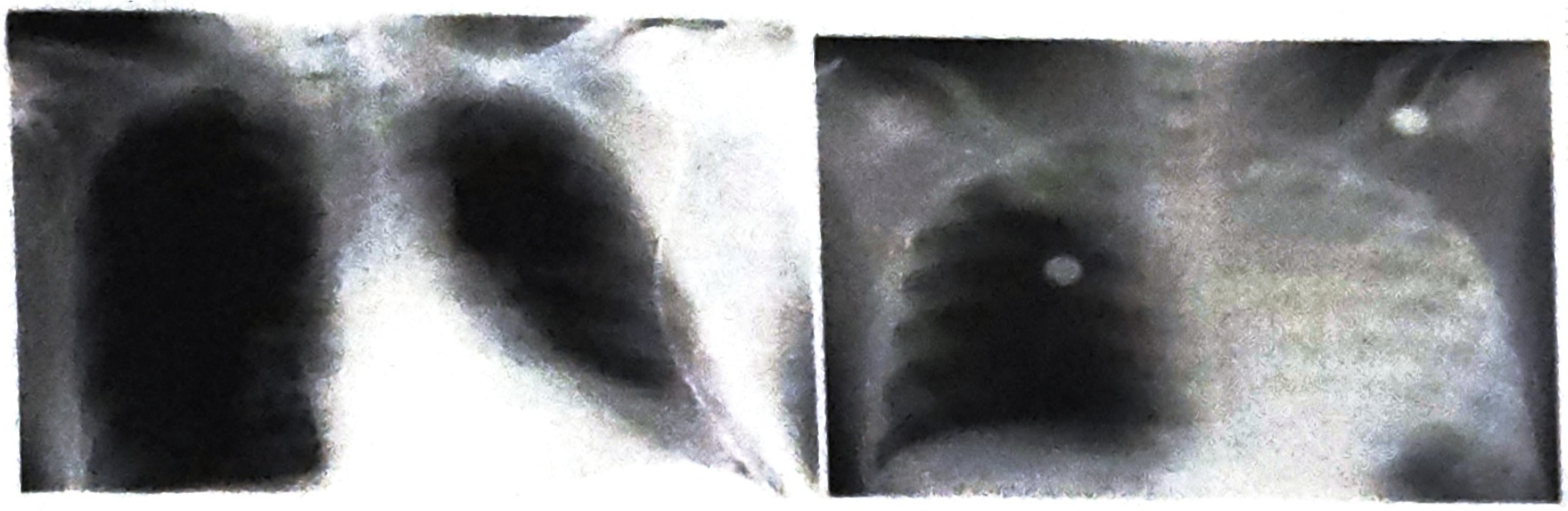

Post intubation CXR

Placement of Nasogastric Tube

Coiling of NG Tube	
Pure Esophageal atresia ↓ Only coiling	Tracheo-esophageal Fistula ↓ Coiling + ↑ed air in abdomen
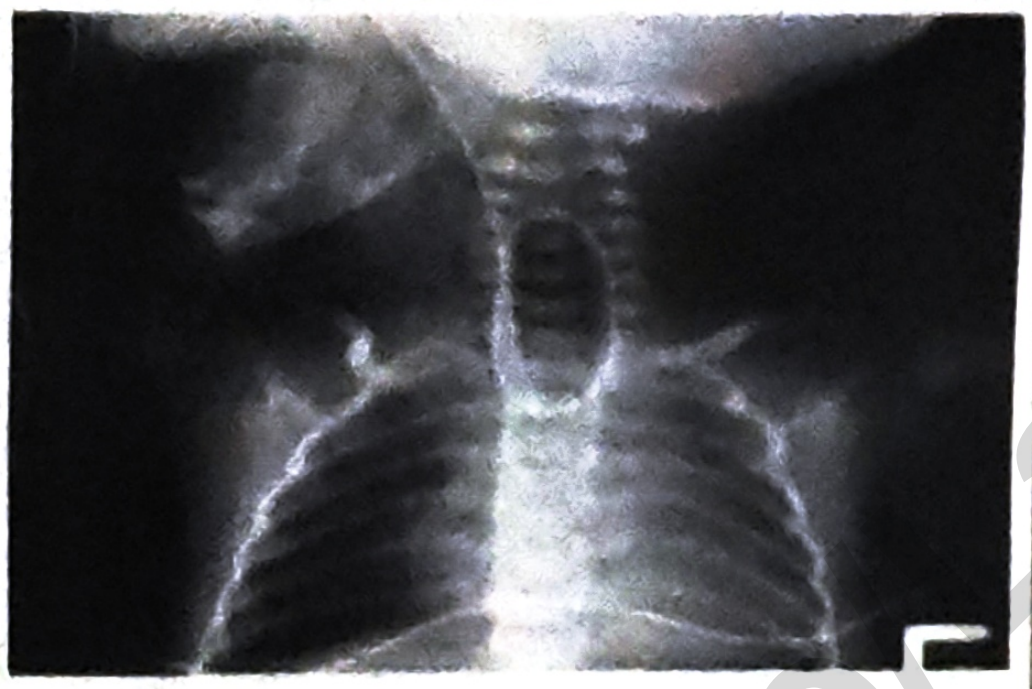	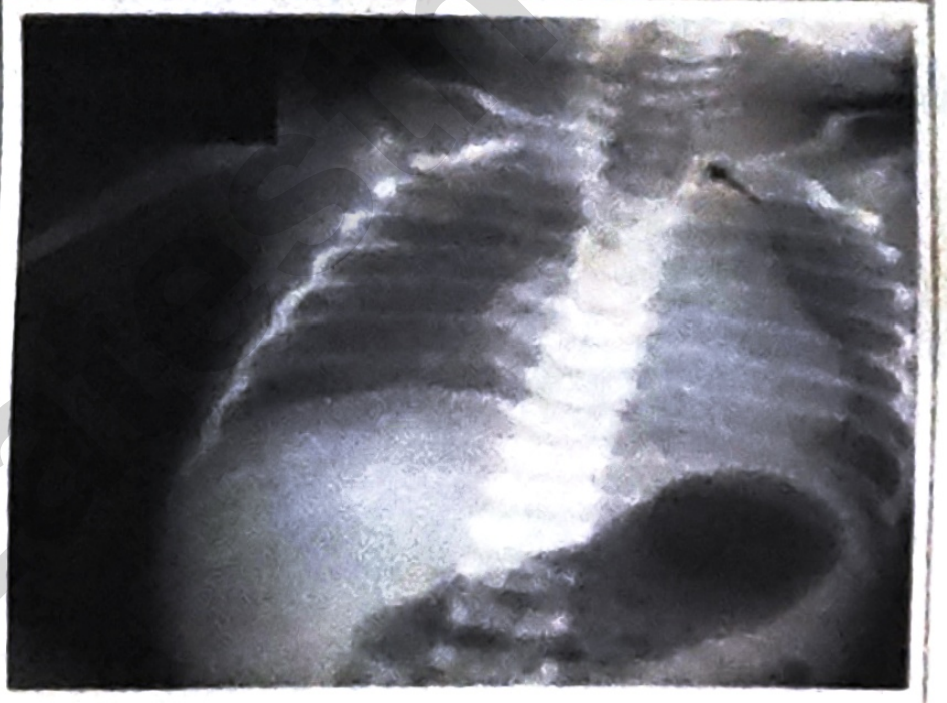

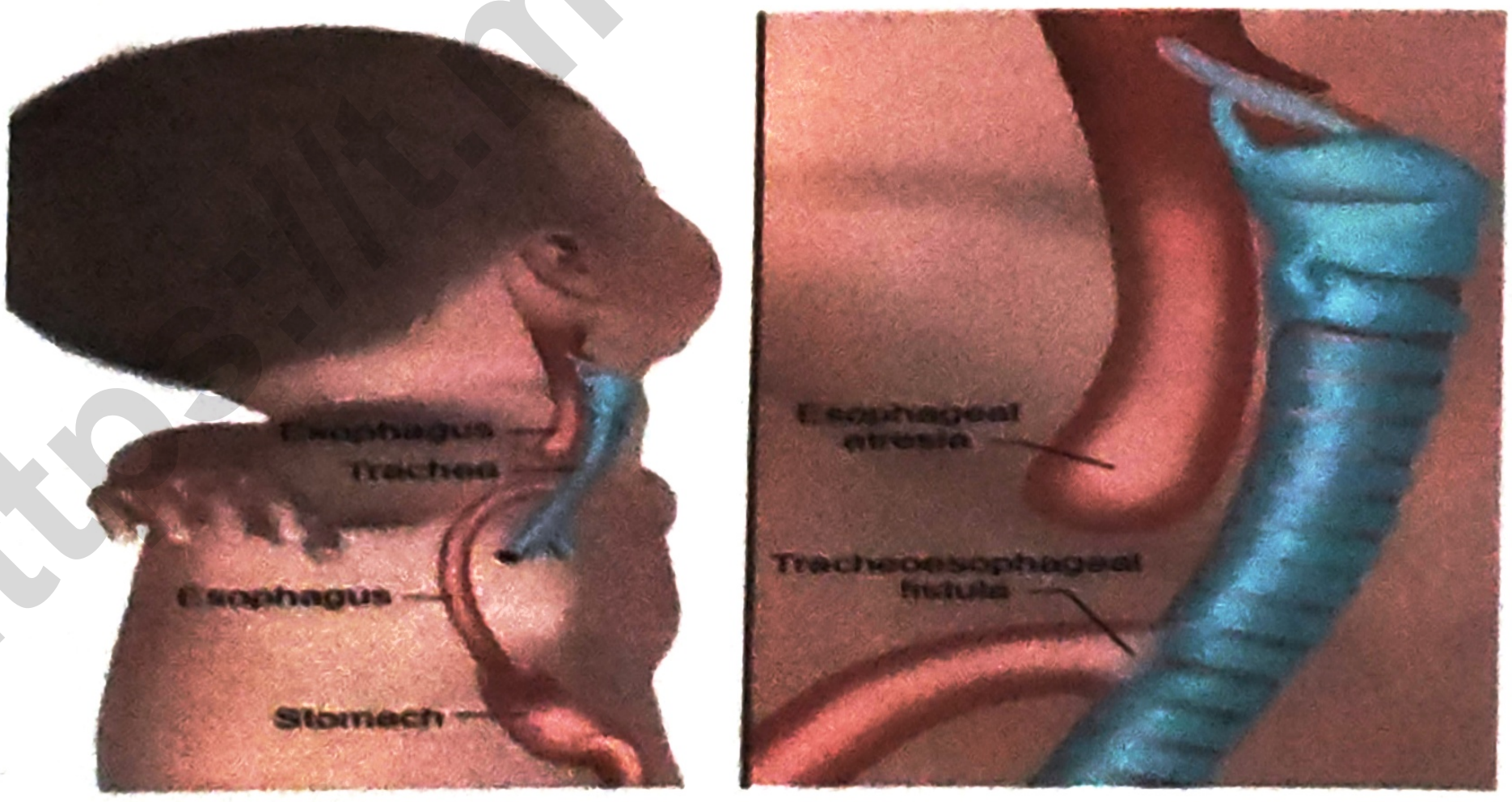

Tracheo-esophageal Fistula

https://t.me/neetpgnotes

PrepLadder

Chapter 6

CT-SCAN PART -1

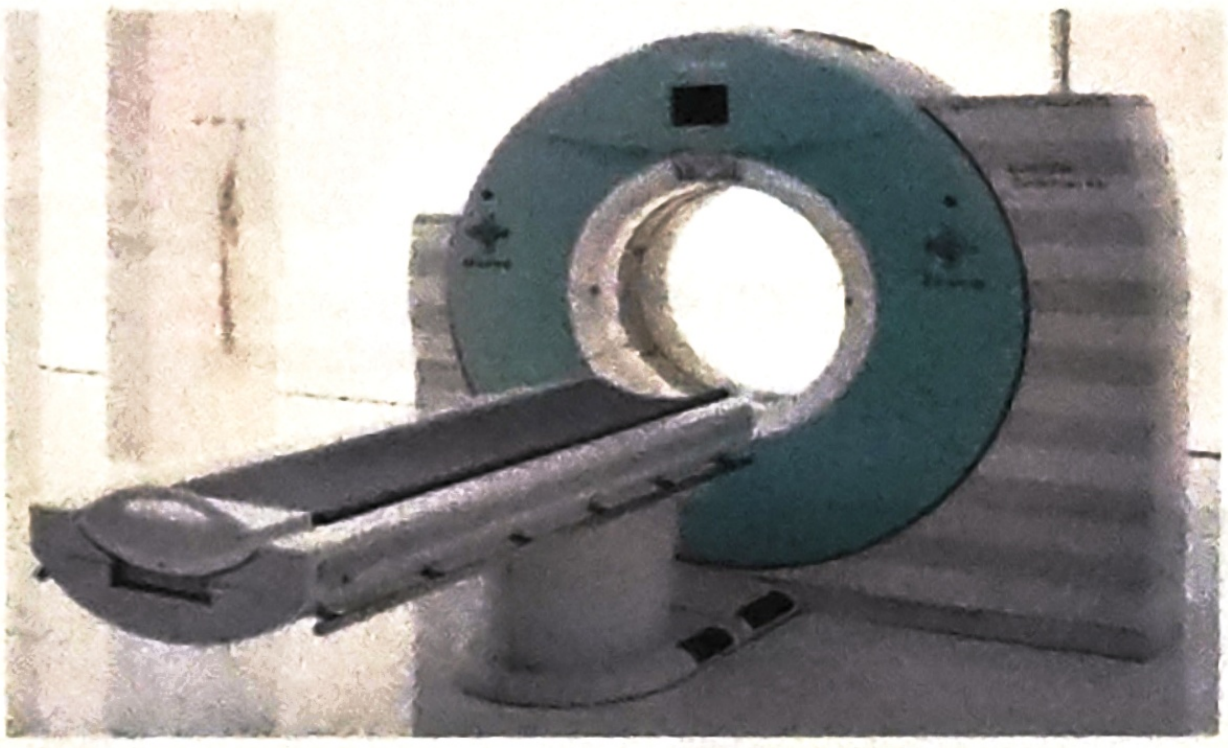

Components of CT scan:

1) Gantry
2) Couch
3) X-ray tube → Beam of X-ray pass through patient and goes to detector
4) Detectors → transfer of digital data

CT Scan: 00:01:11

→ Invented by Sir Godfrey Hounsfield in 1972

→ Hounsfield worked as a engineer in Electro musical instruments company

→ ALLAN CORMACK also paid some contribution to the invention.

→ It works on the principle of linear attenuation of X-Ray

Hounsfield unit:

→ Linear attenuation is measured in Hounsfield units

→ Linear attenuation depends on the density of tissues.

https://t.me/Latestneetpgnotes

Hounsfield unit

Reference Value	-1000	Air	Hypodense (black)
	- 50 – 100	Fat	
	0	CSF/ Water	
	60-+70	Acute Bleed	Hyperdense (white)
	130	Contrast	
	200-+250	Calcification	
	400 - + 1000	Cortical Bone	

NOTE:

→If cortex of bone appears densely white – CT scan image

→If cortex of bone appears black – MRI IMAGE

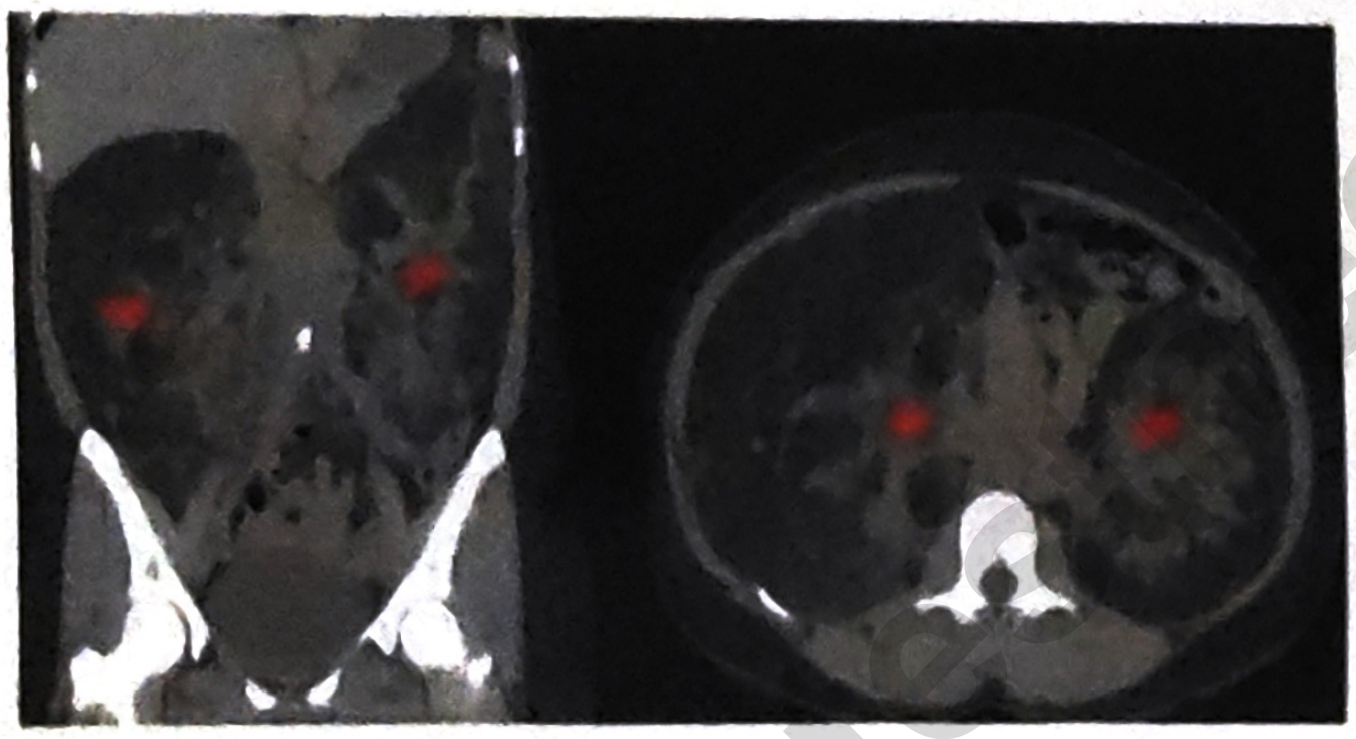

B/L Angiomyolipoma – Tuberous Sclerosis

Evolution of CT scan 00:09:38

→ Conventional CT:

- Time consuming and manually operated
- Uses pencil beam of X-ray
- Used only for head CT

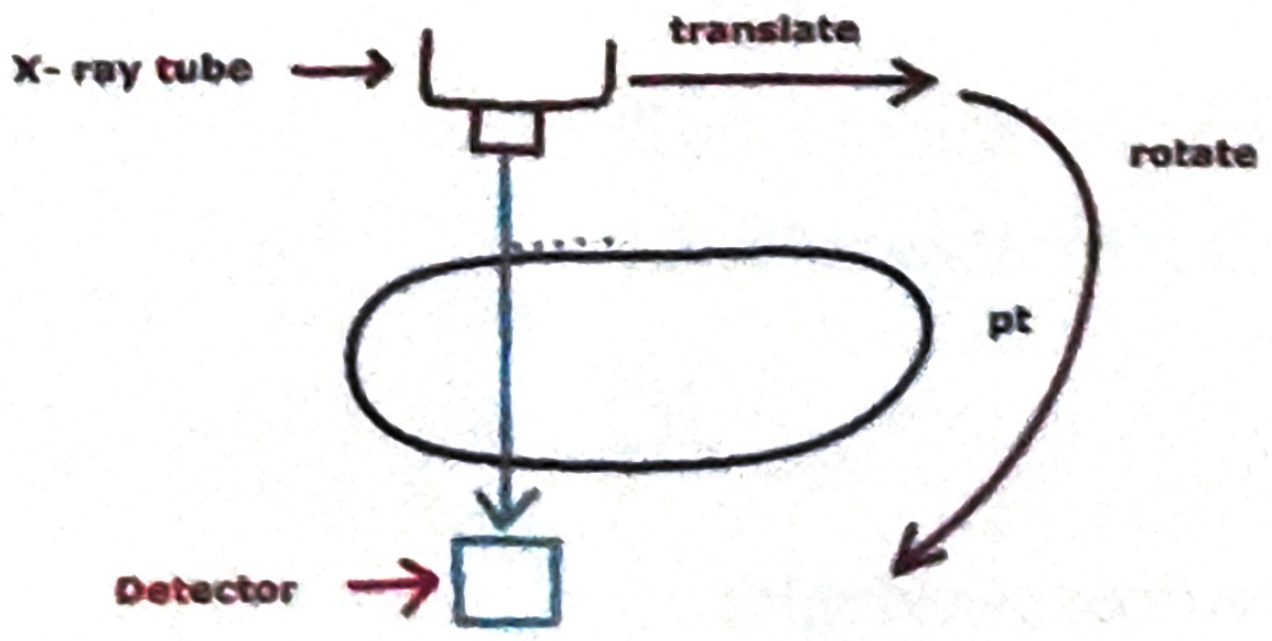

Conventional CT

https://t.me/Latestneetpgnotes

PrepLadder

→ Spiral/ Helical CT:

- Uses slip ring technology
- Has simultaneous power supply b/w Gantry and Couch
- Imaging of trunk in a single breath hold is possible.

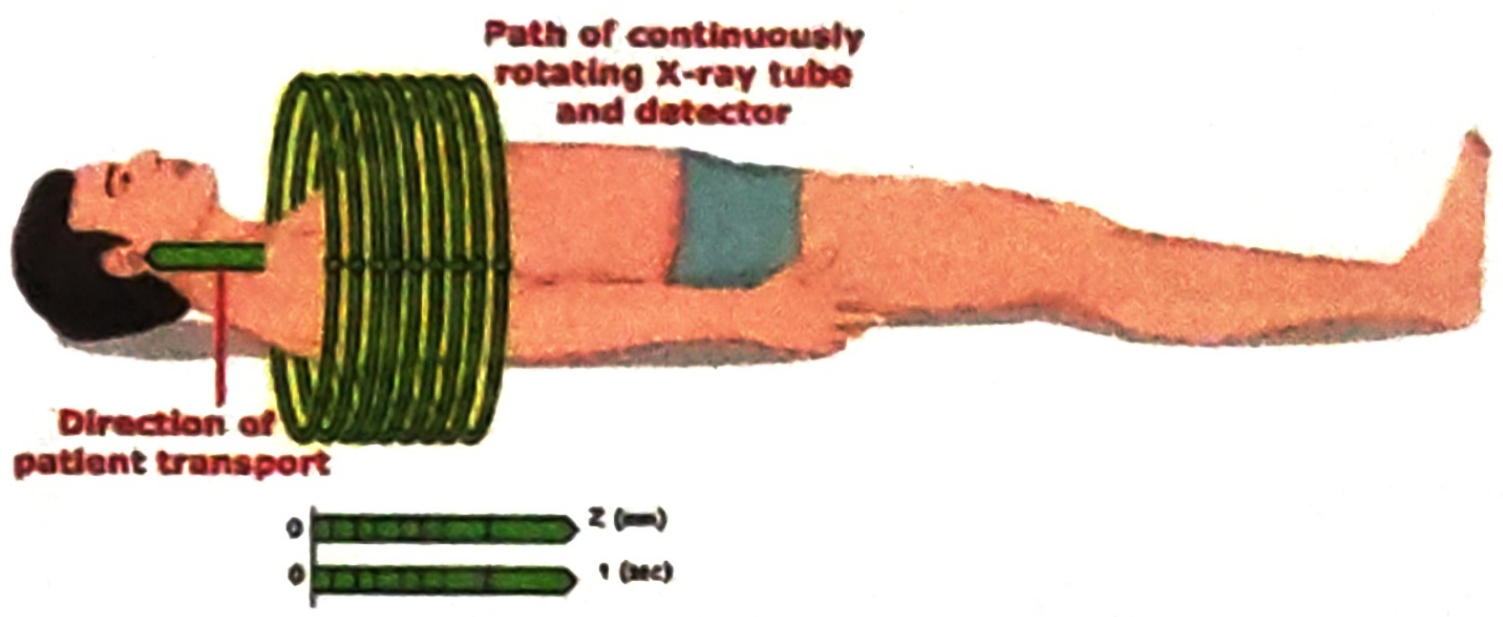

Spiral/ Helical CT

→ Multidetector CT (MDCT):

- Have multiple detectors behind the patient (for better and faster imaging)
- Have cone beam of X-ray
- Used for cardiovascular imaging



Multidetector CT

NOTE:

→ IOC for Pulmonary Thrombo embolism → CT angiography (MDCT with contrast)

→ IOC for acute aortic dissection

- CT angiography (MDCT with contrast)
- Transesophageal echocardiography (if patient is unstable)

https://t.me/Latestneetpgnotes

PrepLadder

→ Plain MDCT is used for coronary calcification scoring (AKA Agatston scoring)

→ HRCT (high resolution CT scan):

- Uses thin slices (1-3 nm)
- Uses bone algorithm software (helps to increase sharpness of image)

NOTE:

→ HRCT is the IOC for ILD

→ HRCT is the IOC for Bronchiectasis

→ HRTC is used in CT cisternography (technique used to investigate CSF rhinorrhea)

→ HRCT is used in fractured temporal bone (Cause ear outside chain disruption leading to conductive hearing loss)

Dual energy/ dual source CT scan:

→ Used to characterize the type of kidney stone

→ To differentiate coronary stent vs Coronary Calcification

→ To obtain virtual non – contrast CT scan

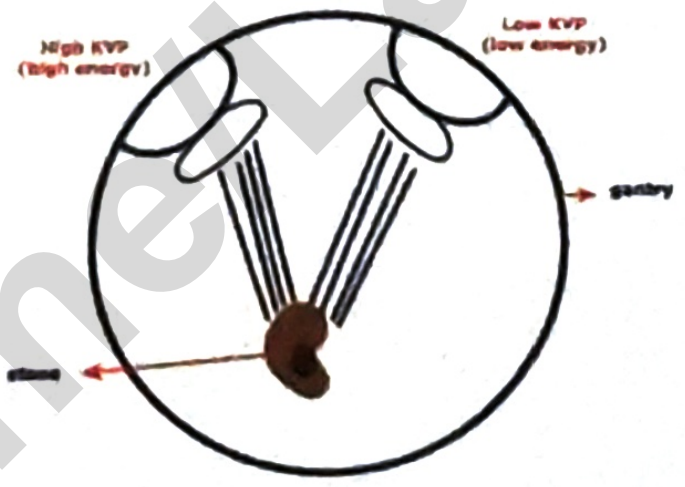

Dual energy/ dual source CT scan

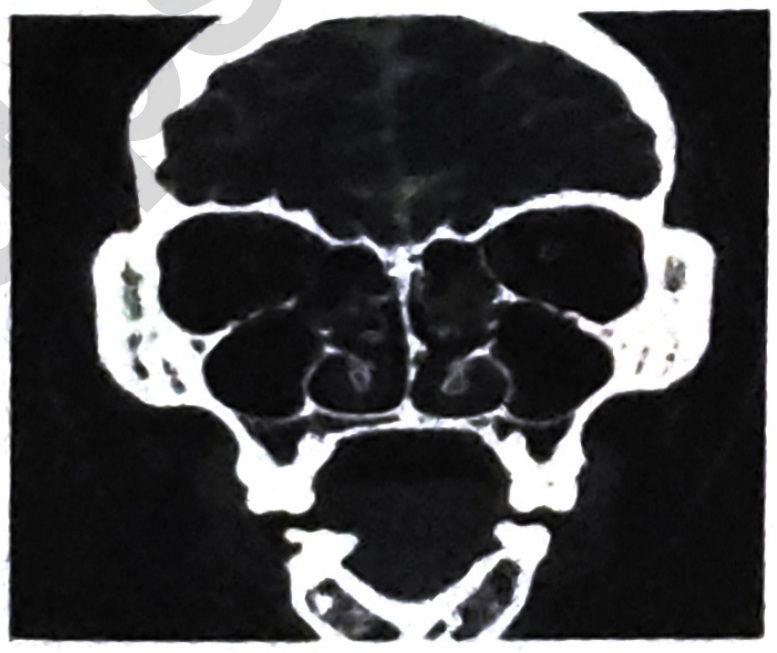 CT-Cisternography → CSF Rhinorrhea	Dual Energy CT

https://t.me/Latestneetpgnotes

PrepLadder

CT – Urography

MR – Urography

Planes of CT:

1) Sagittal Plane – divides body into right and left halves
2) Coronal plane – divides body into anterior and posterior halves
3) Axial plane – divides body into upper and lower parts

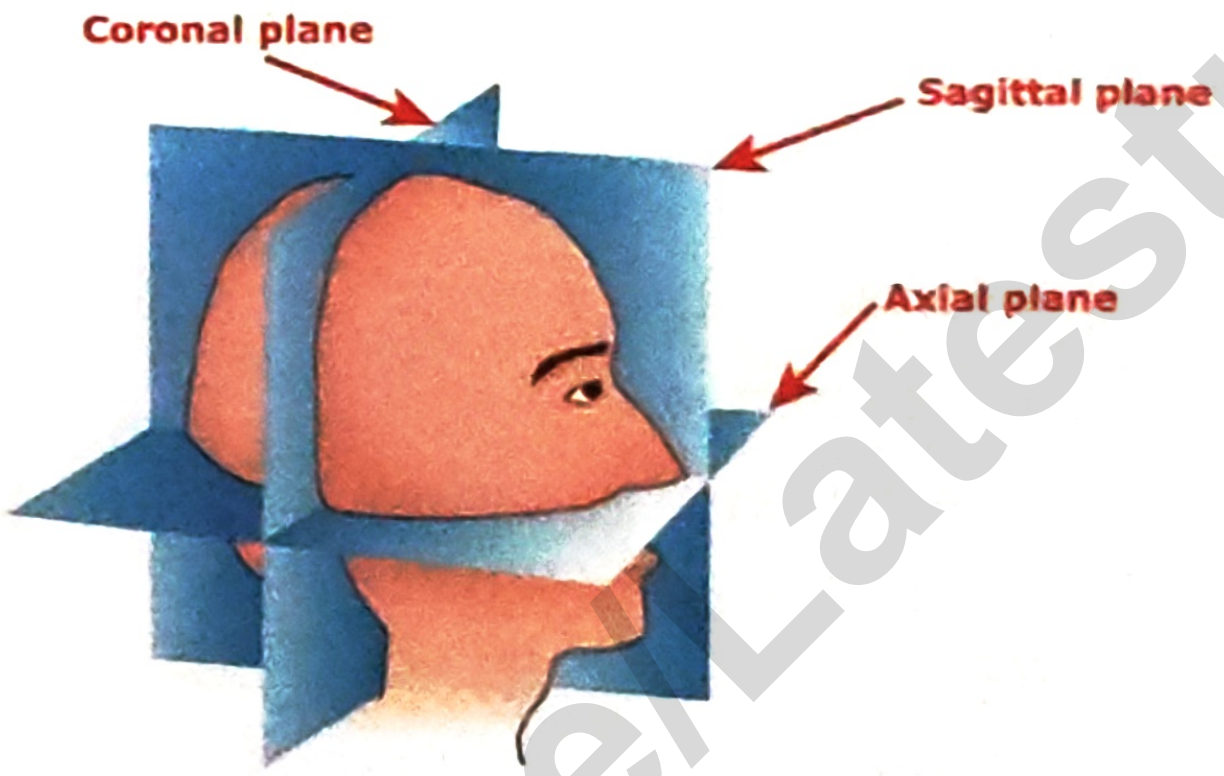

Scout film:

→ Tell which body part is imaged and how slices are taken from that area.



Scout film

https://t.me/Latestneetpgnotes

PrepLadder

NOTE:

In CT scan,

- → Outer gray matter appears white
- → Inner white matter appears black
- → Sulcal spaces appear hypodense

Normal anatomy on CT scan at different level of skull 00:30:30

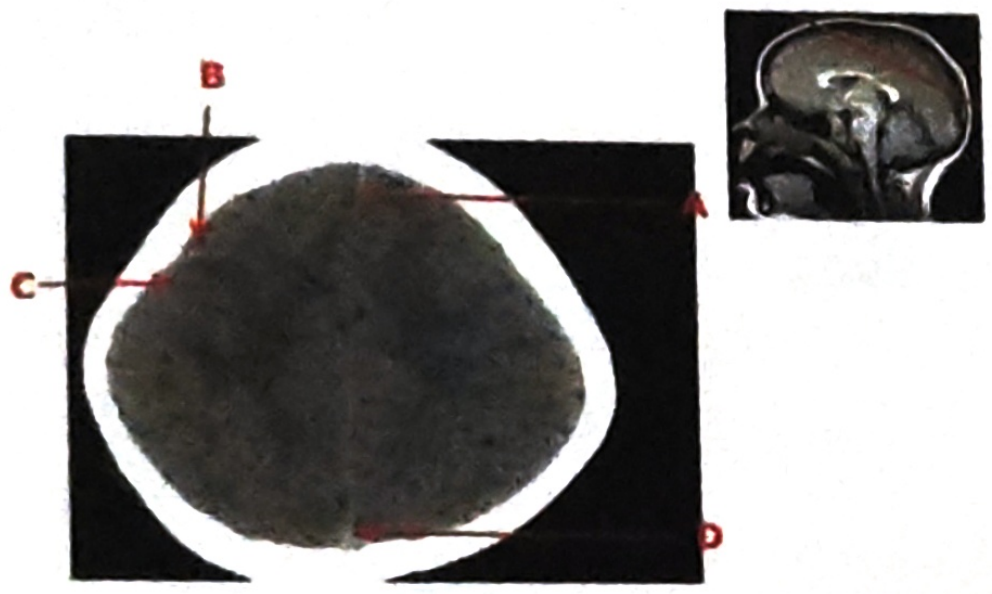	A – Anterior Falx B – Sulcal spaces C – Gray mater D – Posterior Falx
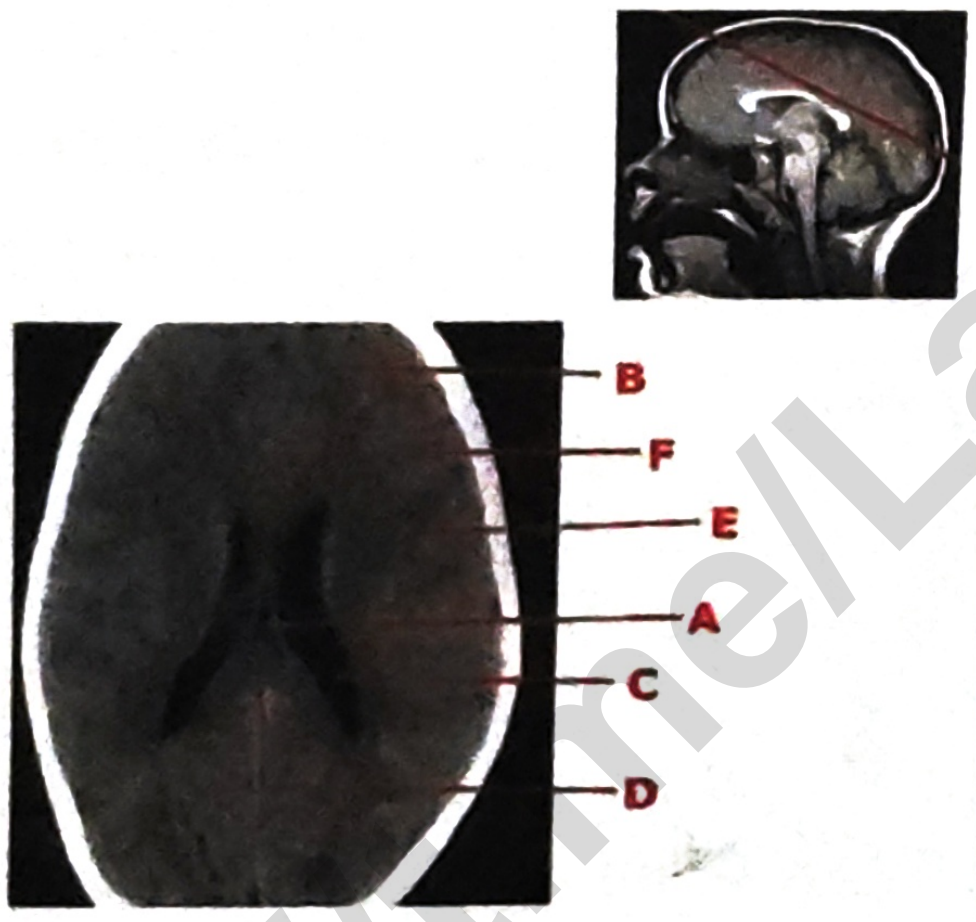	A – Fornix B – Gray mater C – Ventricles D – Splenium of Corpus callosum E – White mater F – Genu of Corpus callosum
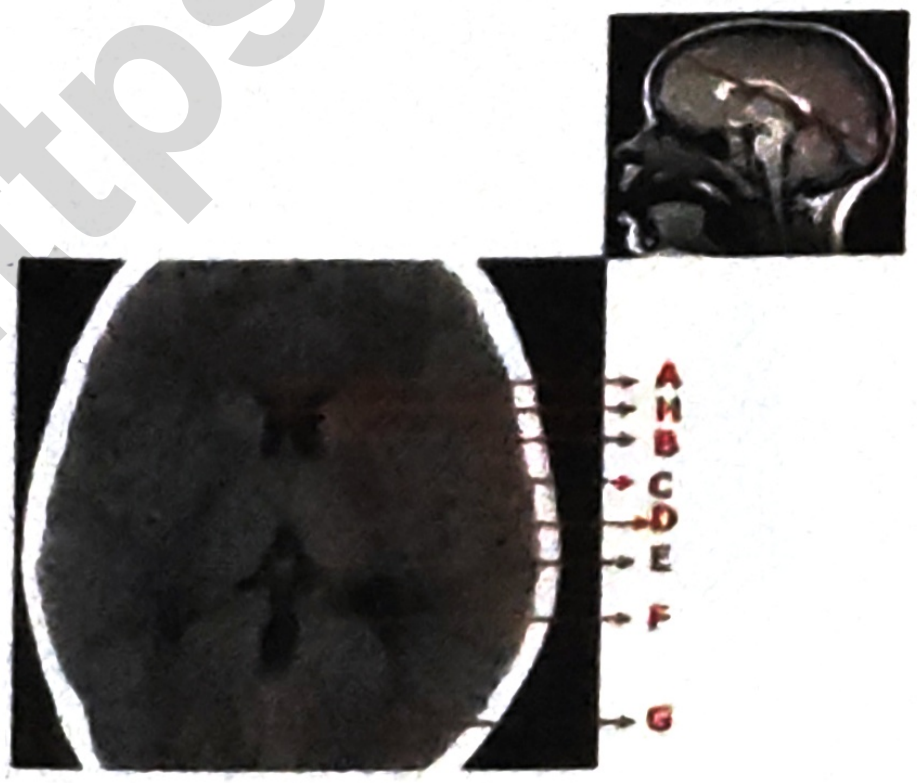	A – Genu of corpus callosum B – Lateral ventricle C – Lentiform nucleus D - Thalamus E – Pineal gland F – Choroid plexus G – Posterior Falx H – Caudate nucleus

https://t.me/Latestneetpgnotes

PrepLadder

For more free ebooks and notes, visit

https://t.me/Latestneetpgnotes

Or click this page to join

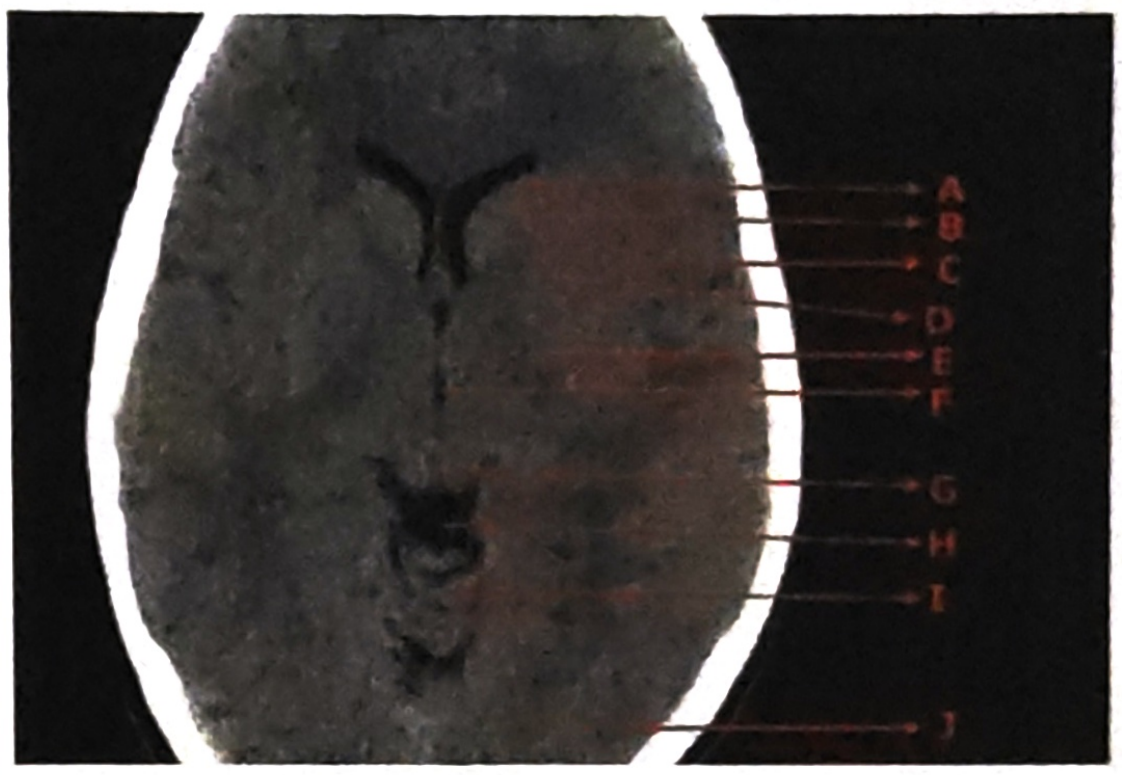	A – Frontal horn of lateral ventricle B – Caudate nucleus C – Anterior limb of internal capsule D – Lentiform nucleus E – Posterior limb of internal capsule F – Third ventricle G – Quadrigeminal cistern H – Vermis I – Occipital lobe J – Mid brain/ corpora Quadrigemina
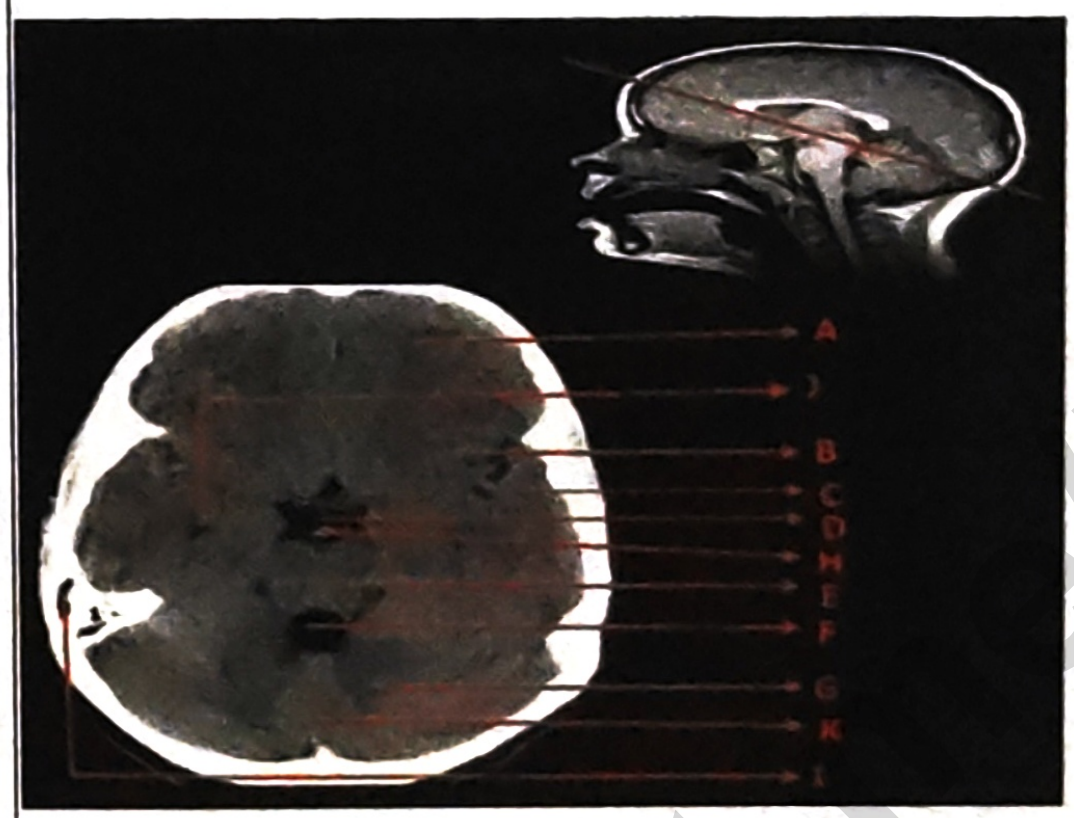	A – Frontal lobe B – Sylvian fissure C – Insula D – Prepontine cistern E – Pons F – 4th ventricle G – Cerebellum H – Basilar artery I – Mastoid air cell J – Temporal Horn of lateral ventricle K – Cerebellar Vermis

Cistern

00:43:17

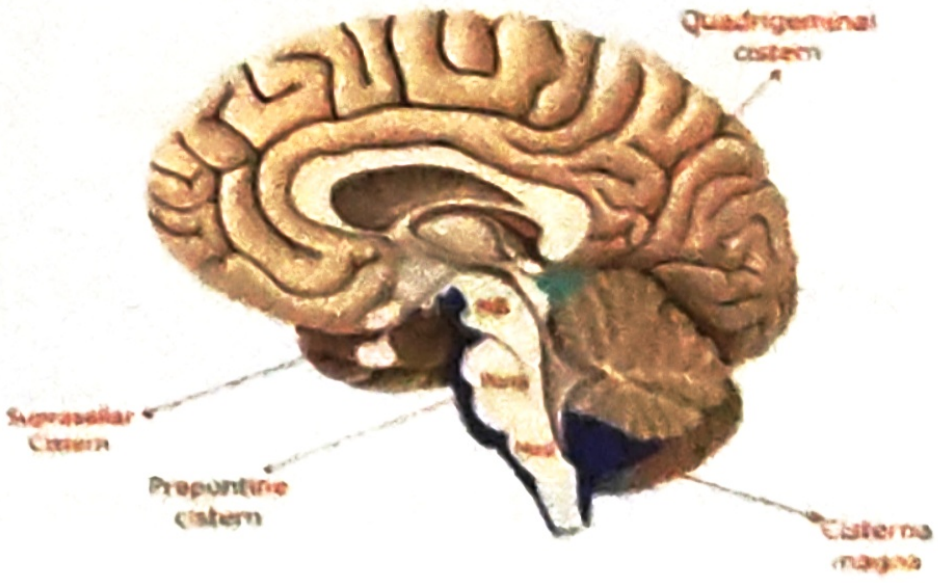

https://t.me/Latestneetpgnotes

PrepLadder

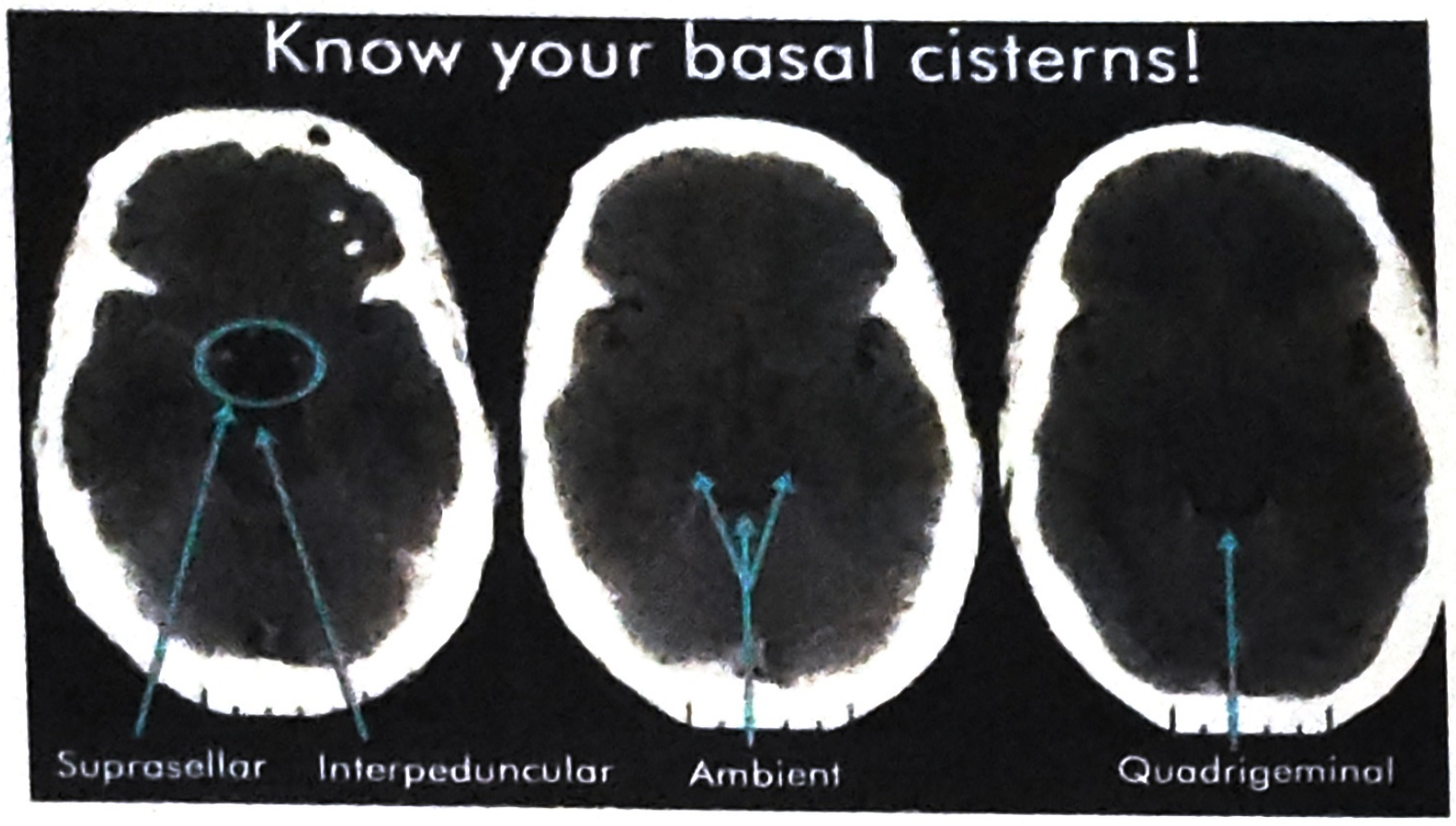

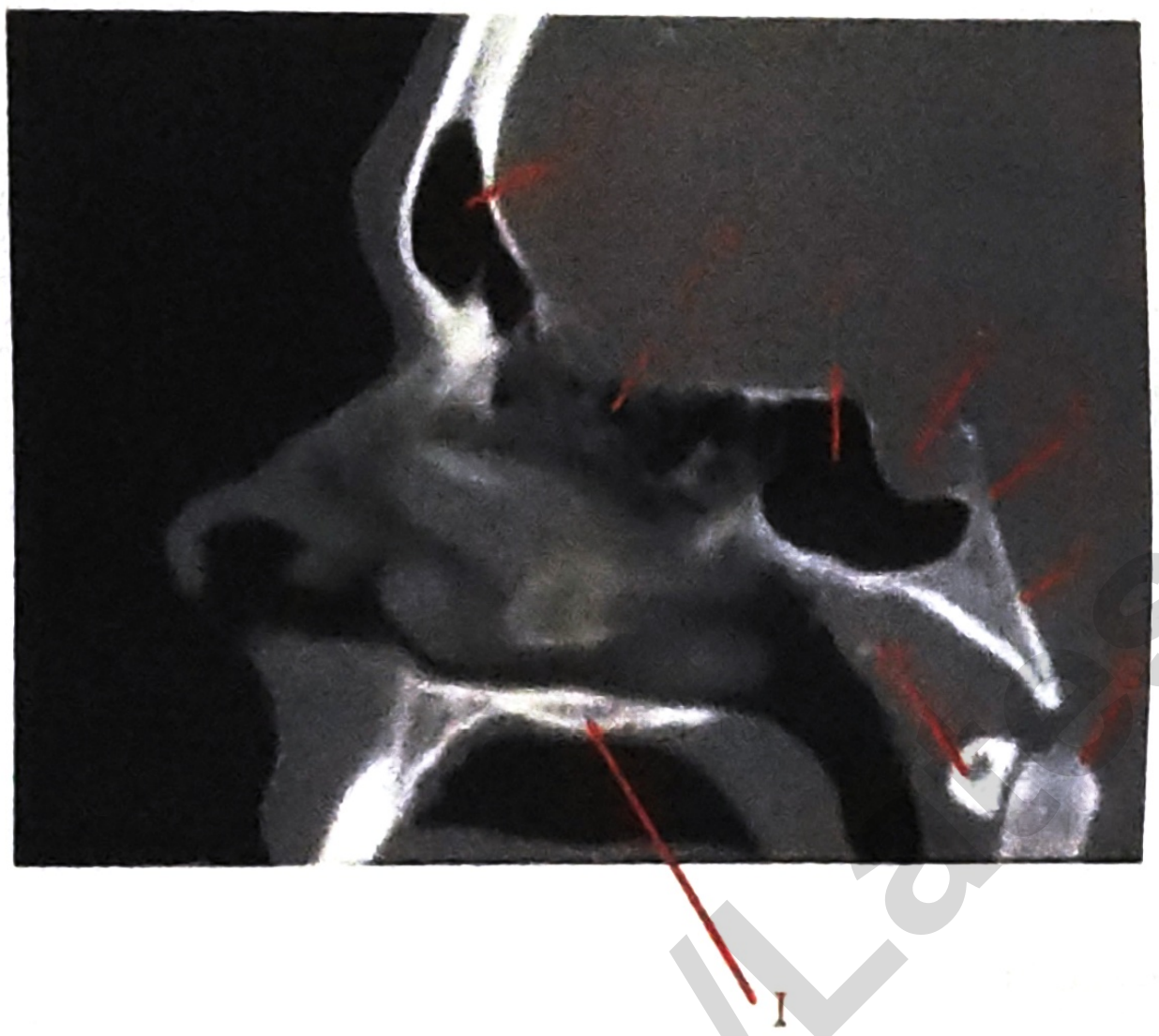

A – Frontal sinus
B – Ethmoidal sinus
C – Sphenoid sinus
D – Sella
E – Dorsum sella
F – Clivus
G – Dens of Axis
H – Atlas

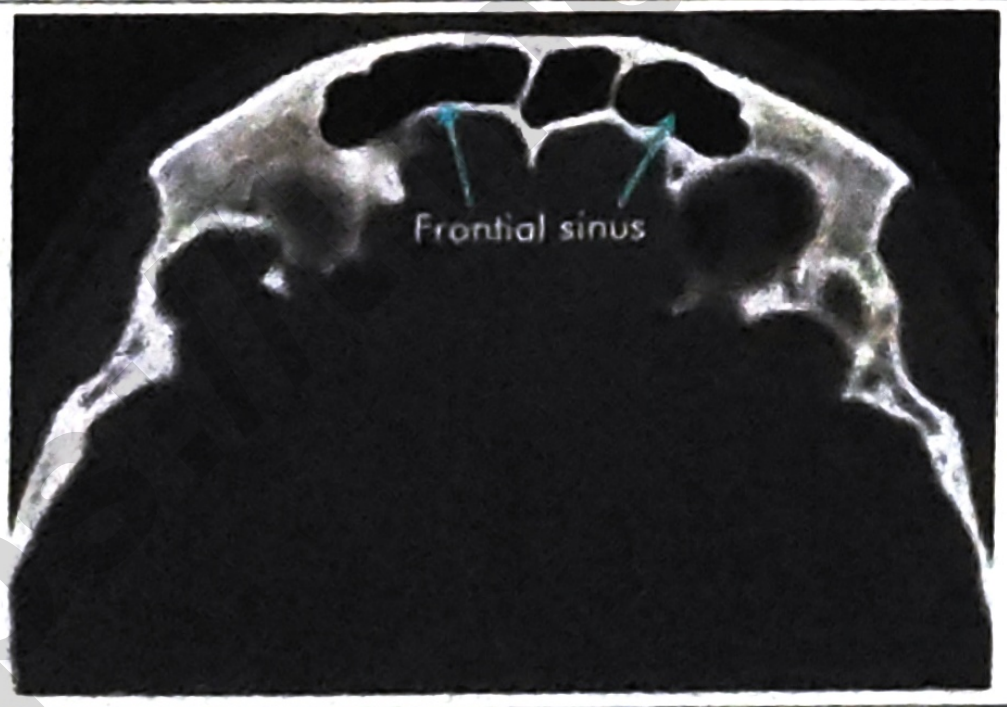

Normal frontal sinus
– Contains air inside that appears hypodense on CT

CT scan at the level of frontal Bone

→ Subperiosteal abscess in frontal sinusitis is Pott's puffy tumor

https://t.me/Latestpgnotes

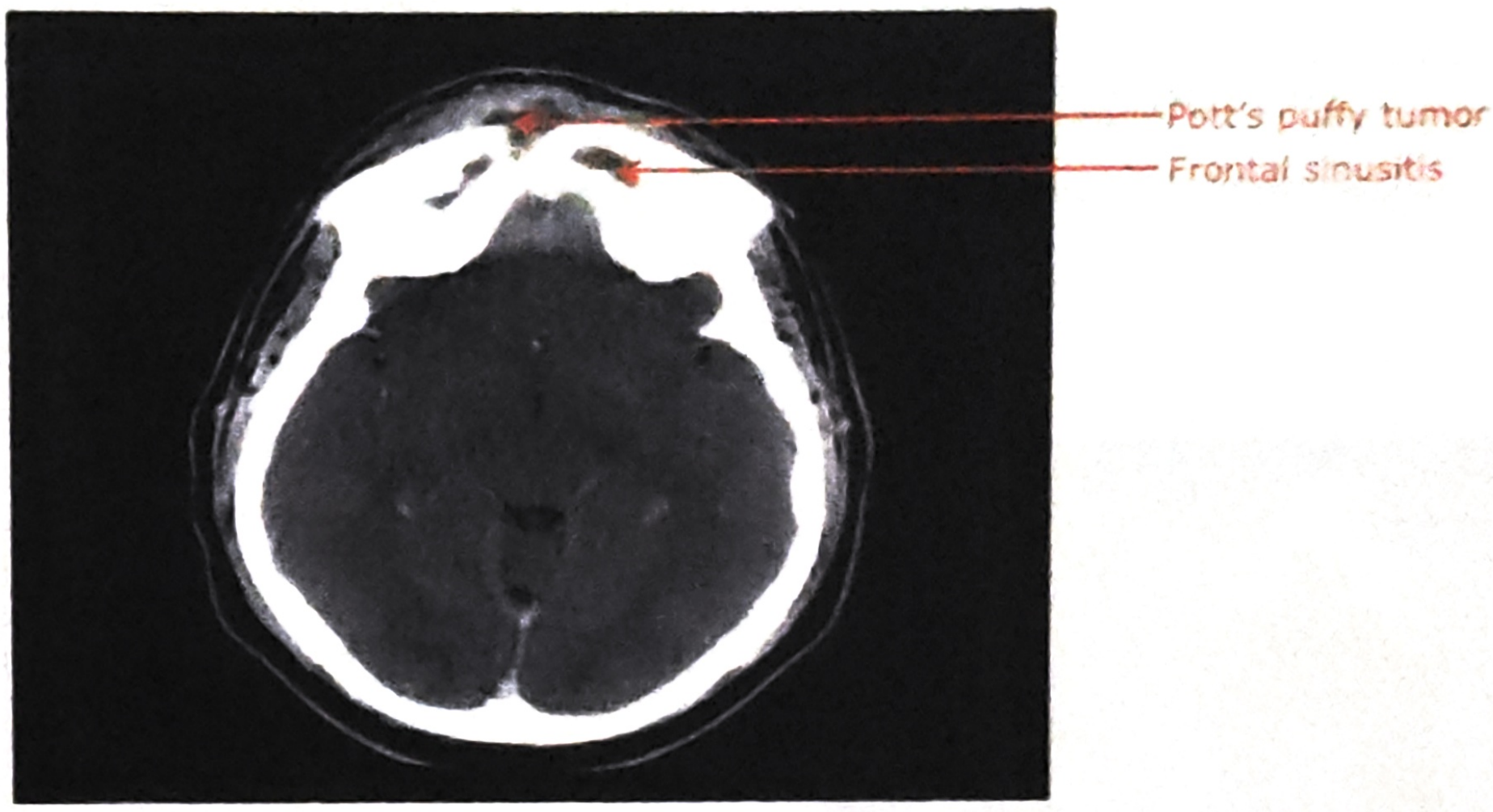

Frontal Sinusitis

CT at the level of roof of orbit

00:47:20

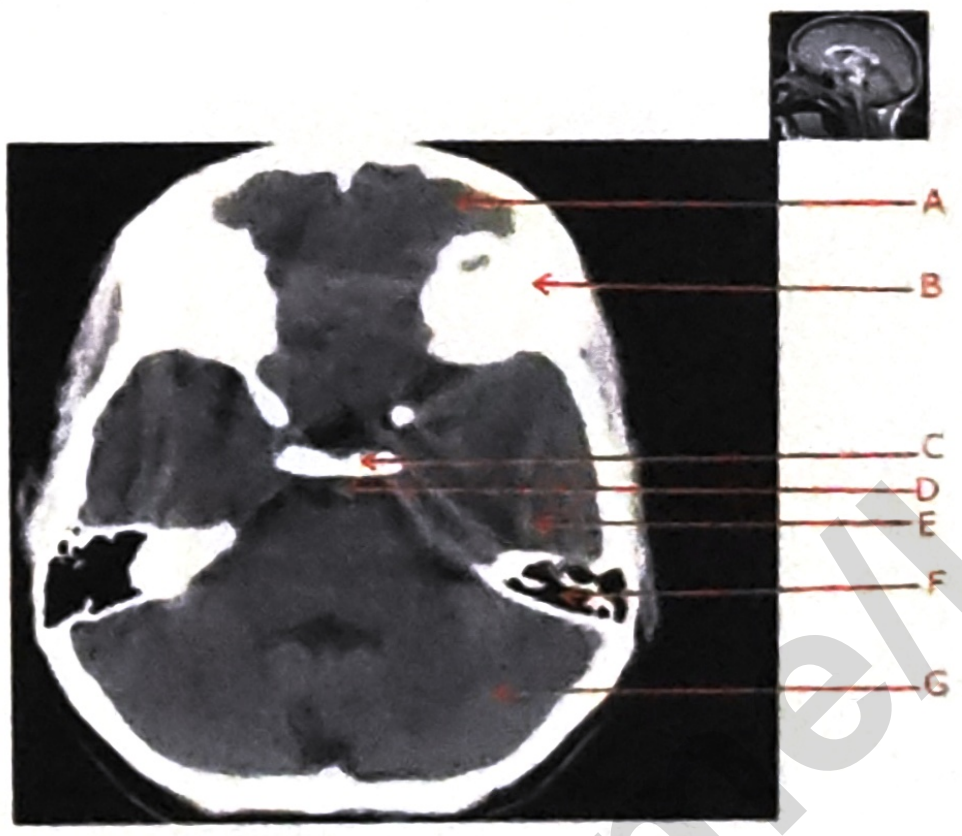

A – Frontal lobe
B – Roof of orbit
C – Dorsum sella
D – Basilar artery
E – Temporal lobe
F – Mastoid air cells
G – Cerebellar hemisphere

CT – Through the orbit

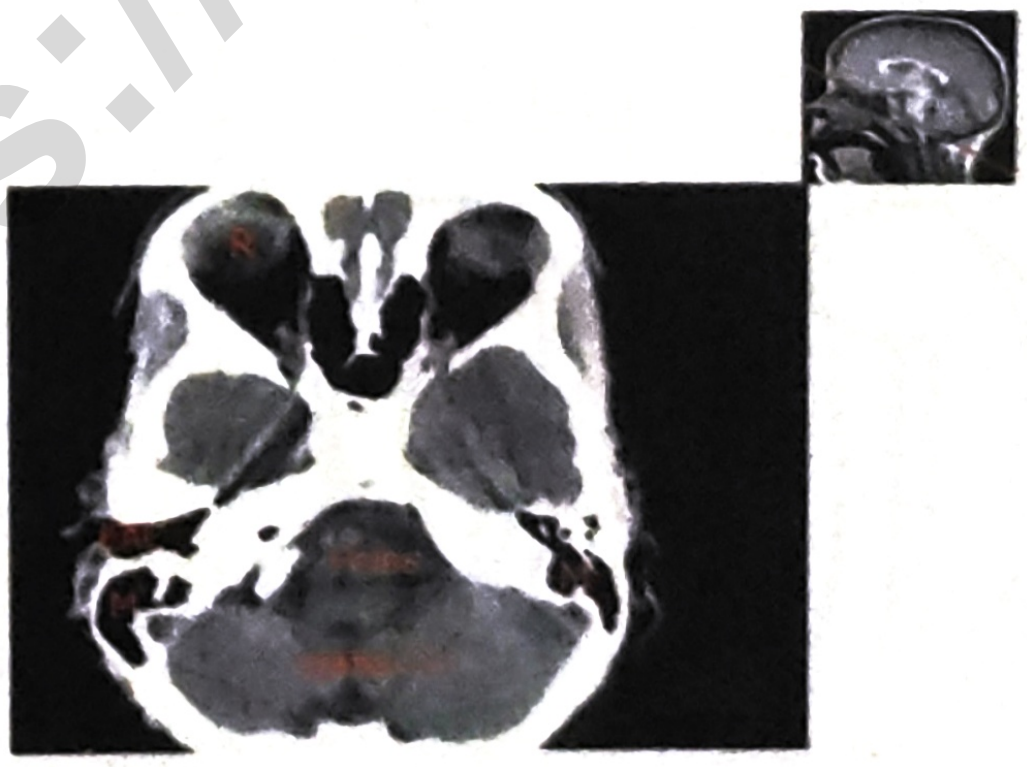

Normal CT – Through the orbit

https://t.me/Latestneetpgnotes

PrepLadder

CT scan at the level of orbit:

→ Coco Cola bottle appearance of extraocular muscle due to its fusiform Enlargement of medial Rectus & Inferior rectus

- Thyroid Ophthalmopathy

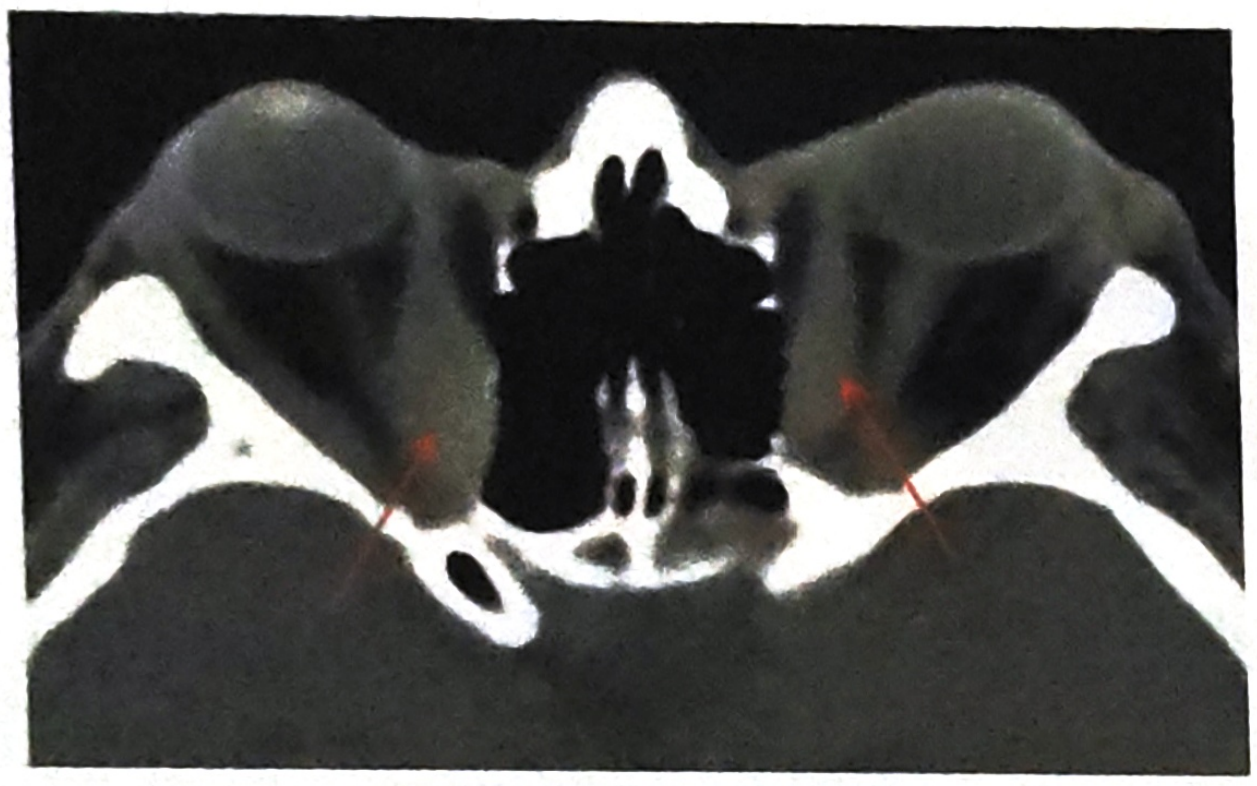

CoCo-Cola bottle Sign

CT scan with metallic object in orbit:

→ IOC for ocular metallic foreign body is CT scan

→ MRI is contra – indicated

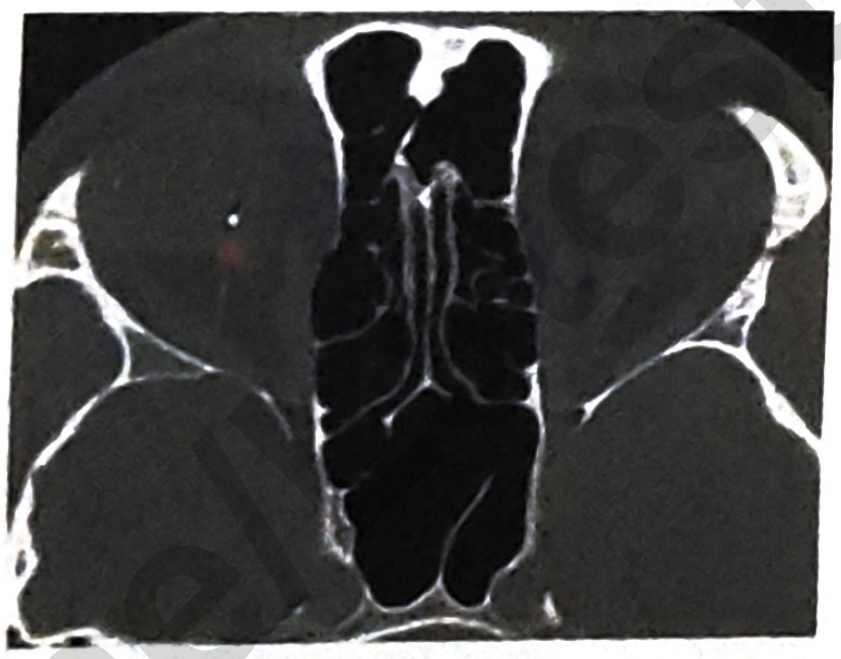

Foreign body in the eye

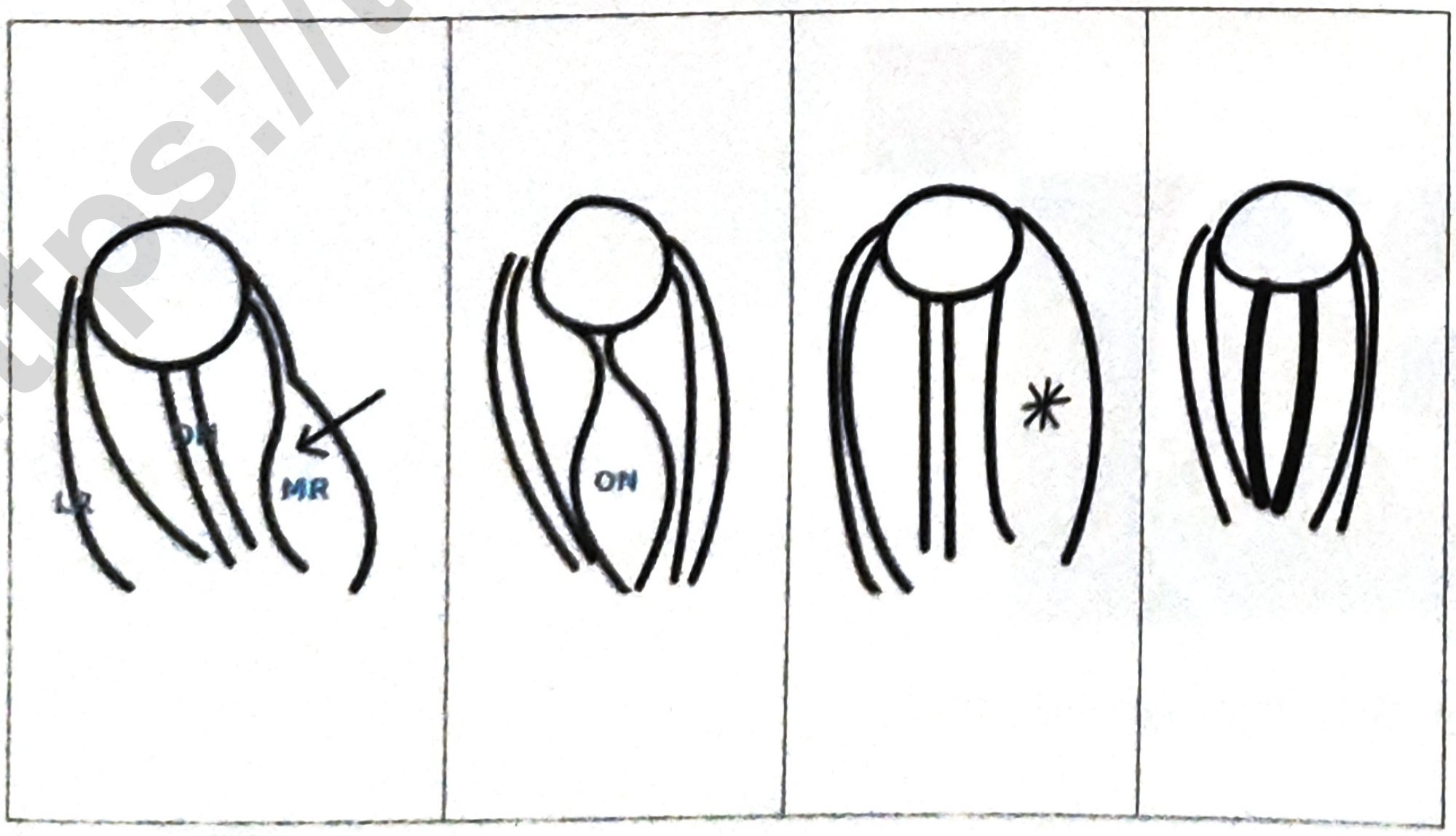

https://t.me/bestneetpgnotes

PrepLadder

Fusiform Enlargement of Medial Rectus Coca Cola bottle appearance of MR, IR ↓ Thyroid Ophthalmopathy	Fusiform Enlargement of Optic Nerve ↓ Optic Nerve Glioma (Associated with NF-1)	Orbital Pseudotumor	Tram track appearance of Optic Nerve ↓ Optic Nerve sheath meningioma

Intra – orbital calcification

→ It is a feature of Retinoblastoma

→ IOC of Retinoblastoma - MR

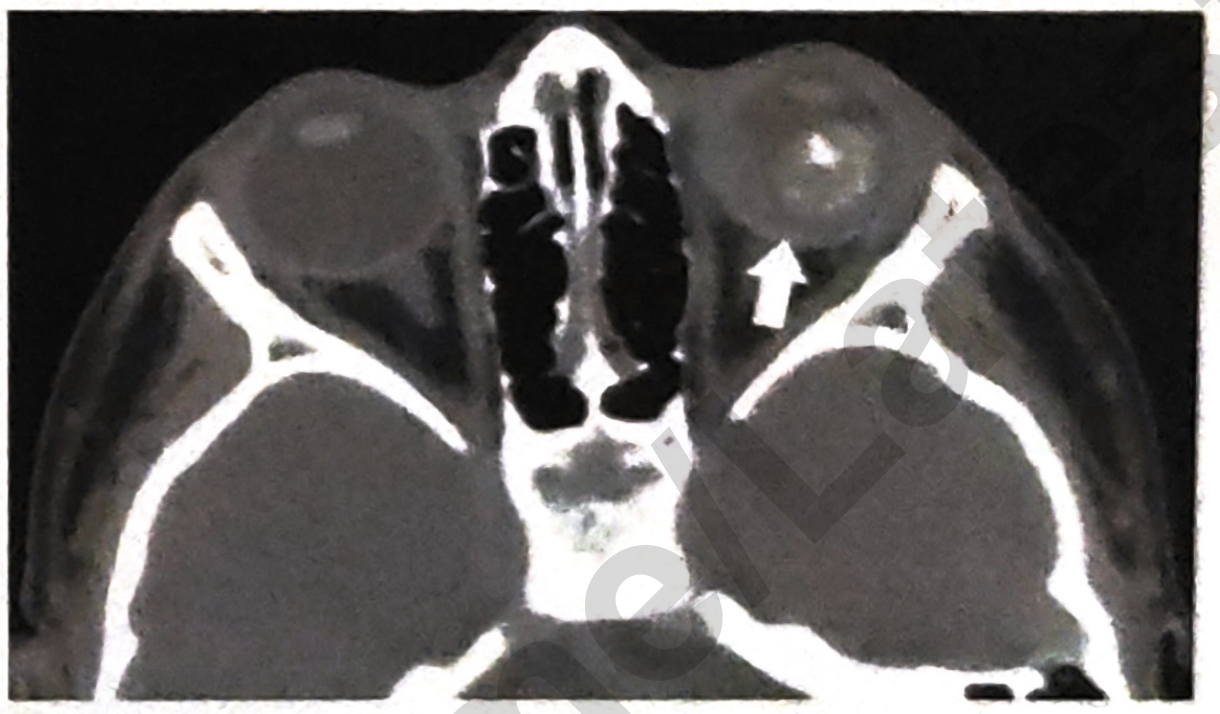

Intra – orbital calcification

Note:

Vitreous Hemorrhage

DDX

→ Diabetes

→ Eales disease

Ethmoidal sinus

→ Onodi cells: - These are posterior ethmoidal air cells closely related to optic nerve

https://t.me/Latestneetpgnotes

PrepLadder

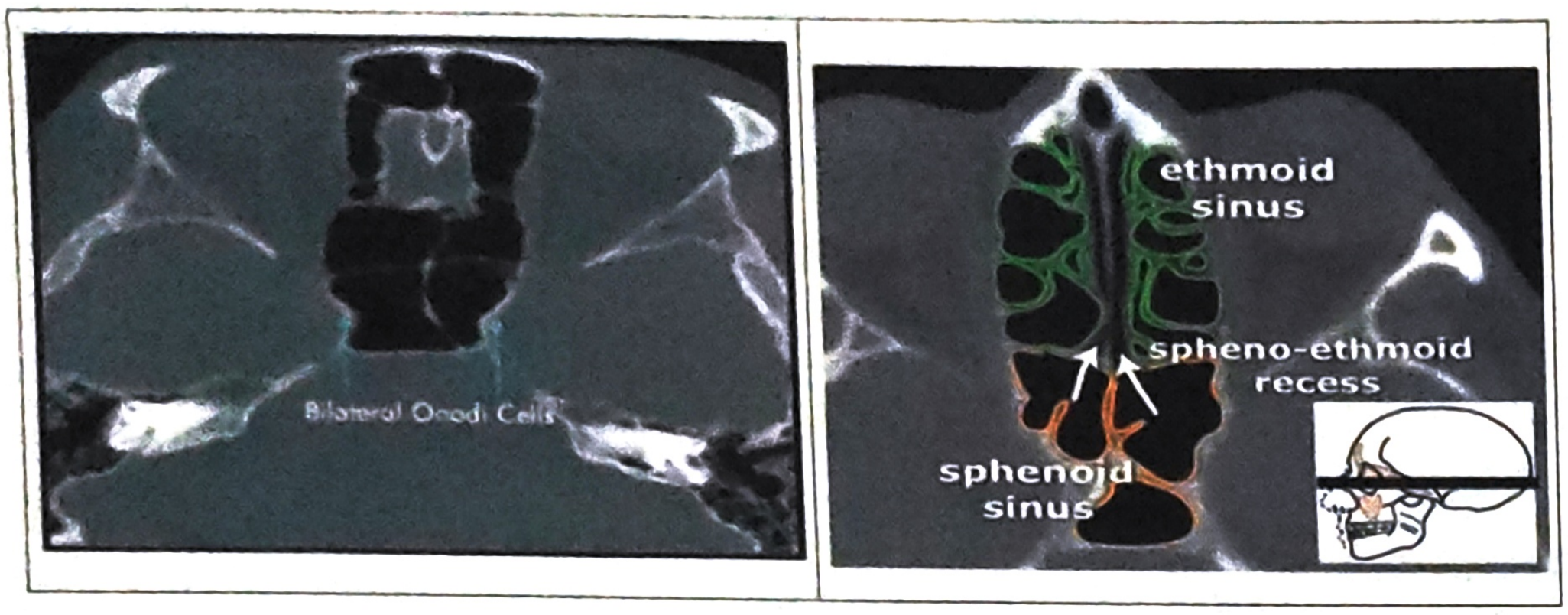

Agar nasi cells:

→ These are Anterior most anterior ethmoidal cells

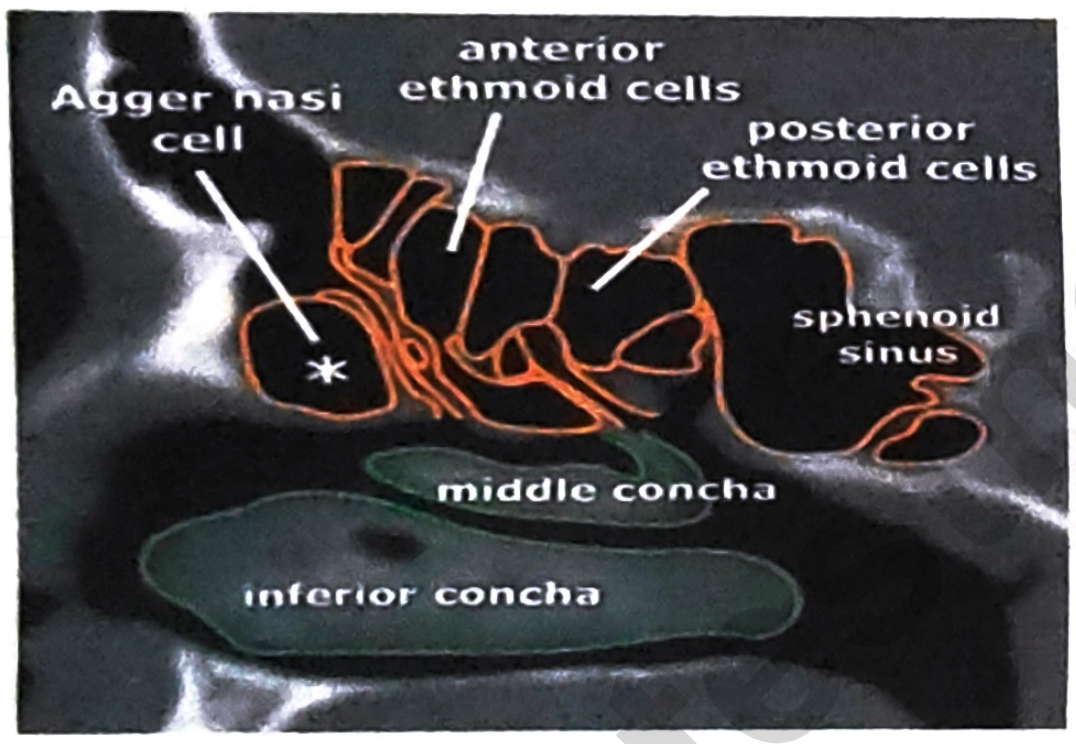

Agar nasi cells

Haller cells:

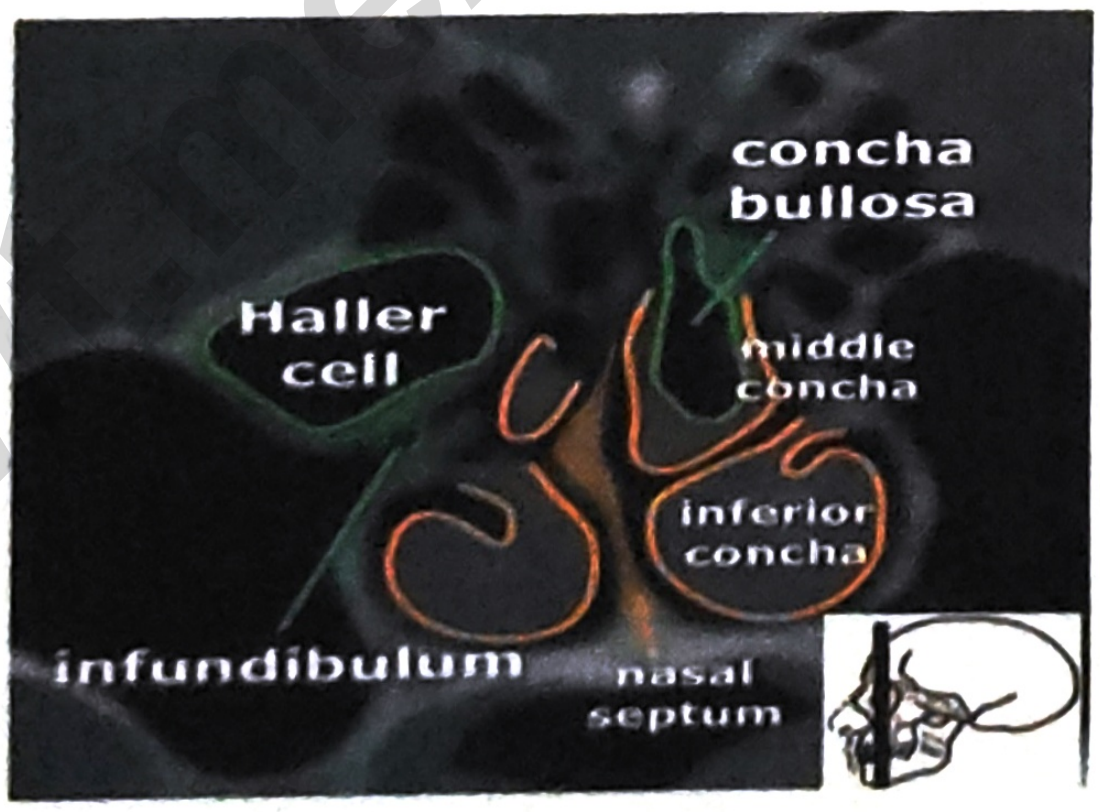

- These are infra – orbital ethmoidal cells
- It is infero- medial to floor of orbit

Note:

→ Infection of haller cells can lead to orbital cellulitis

https://t.me/Latestpgnotes

PrepLa

Allergic fungal sinusitis

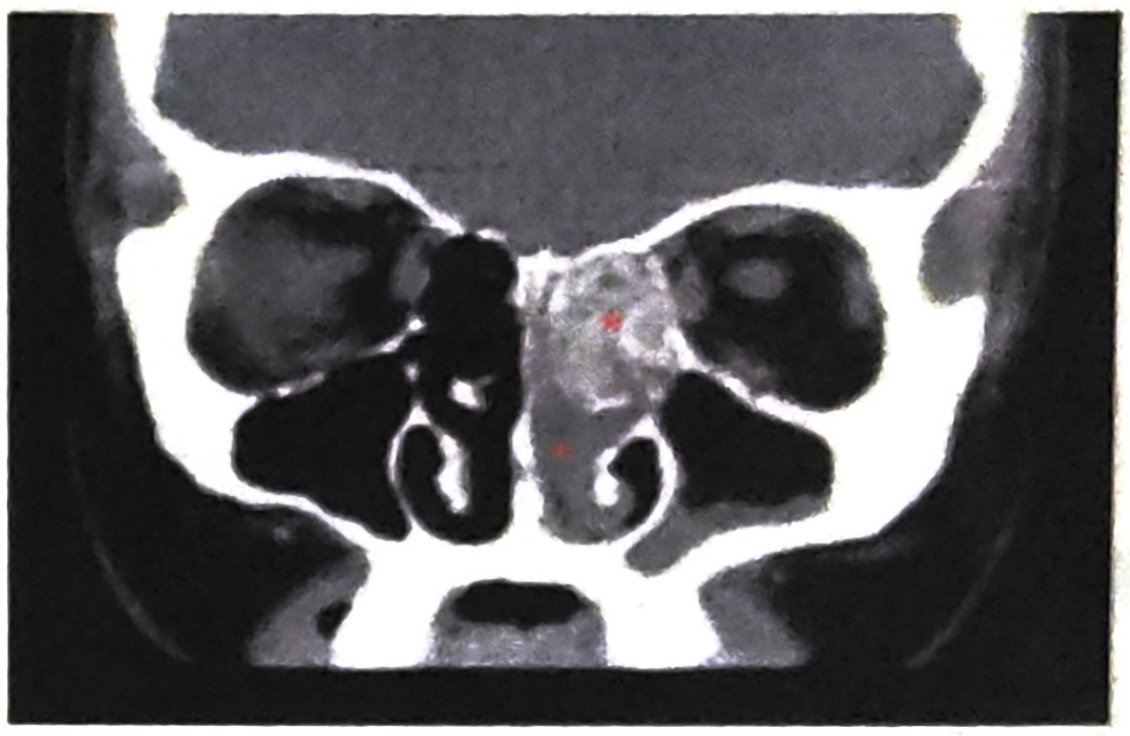

Double Density Sign

CT Scan at their level of Nose & maxillary Sinus

MASTOIDITIS

→ Infection of mastoid hair cells.

→ Contrast study – showing Lateral sinus thrombosis

– GRIESINGER SIGN

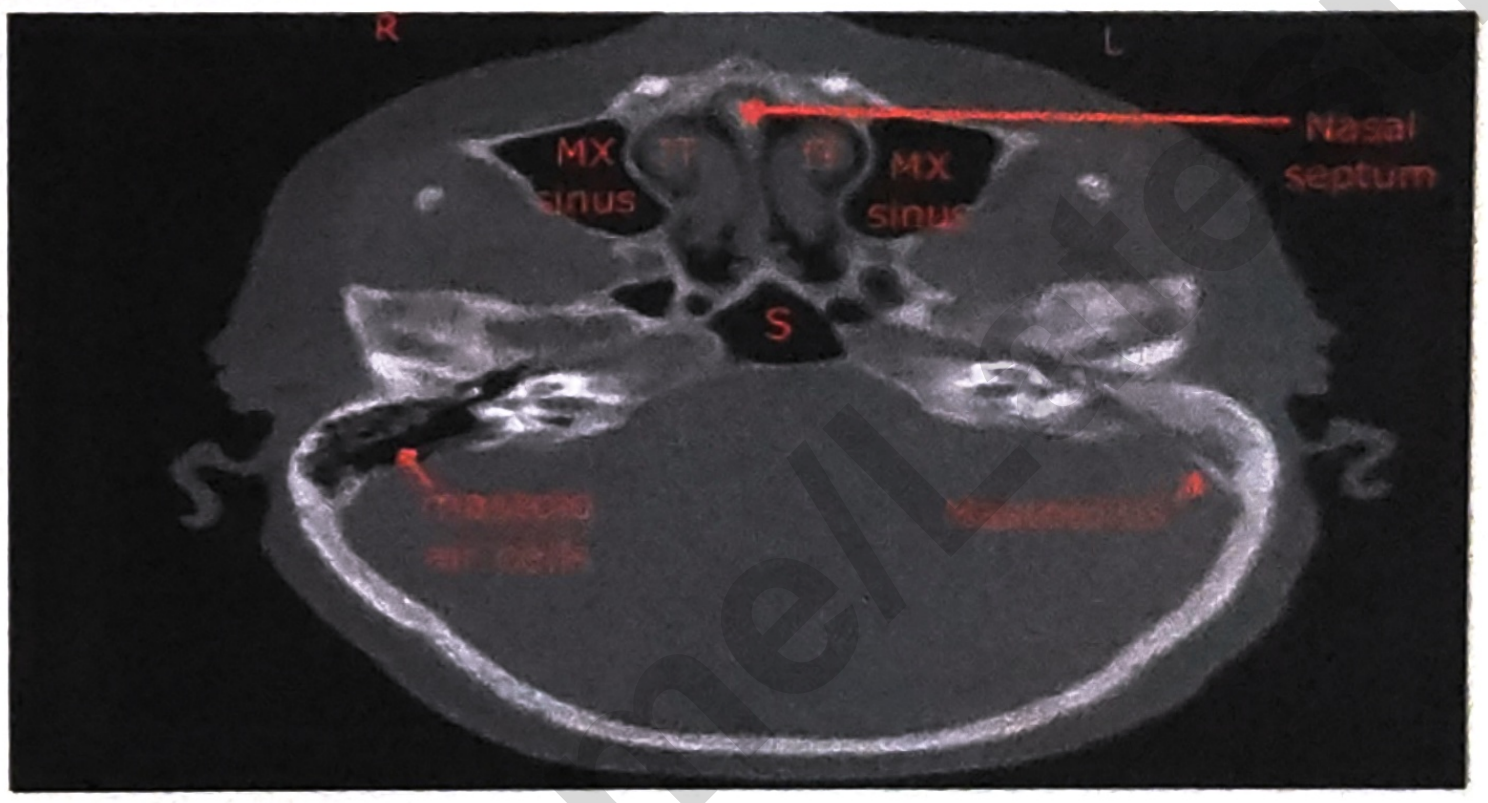

Juvenile Nasopharyngeal Angiofibroma 00:59:11

→ Anterior bowing of posterior wall of Maxillary sinus is known as Holman miller sign / Antral sign

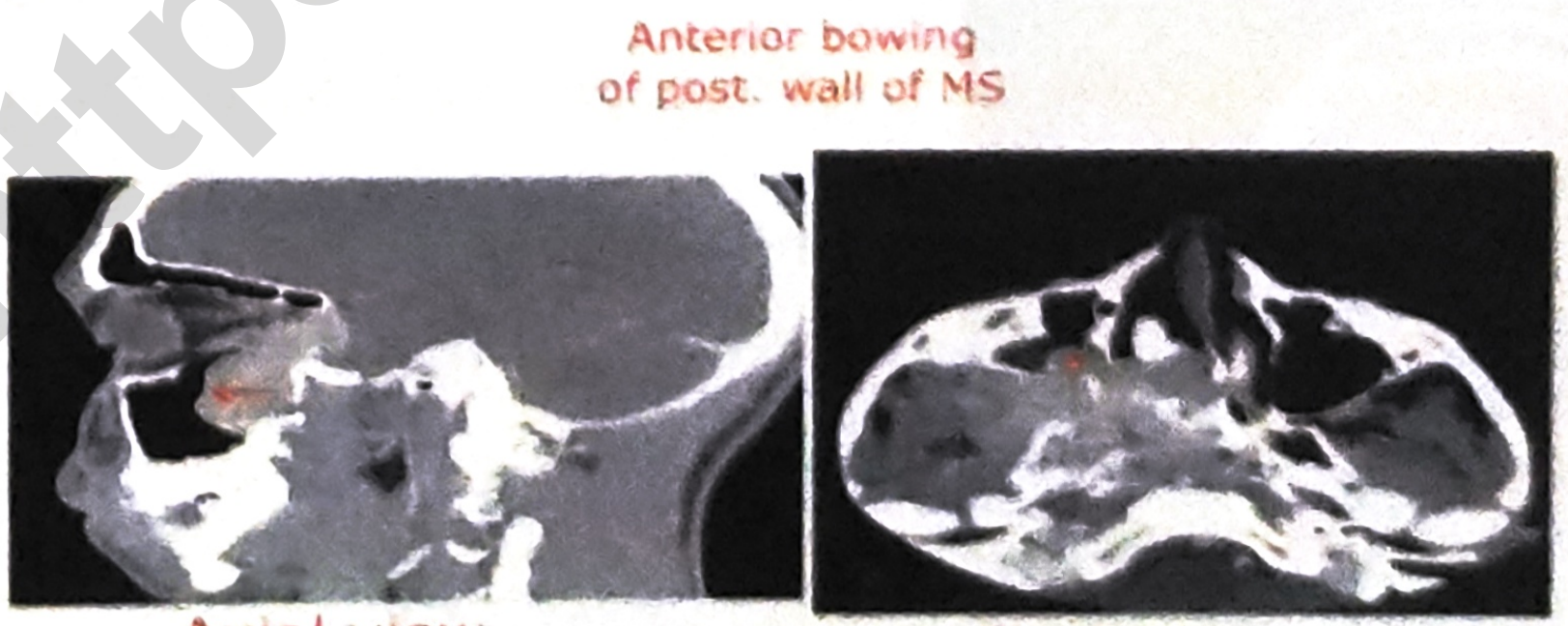

Axial view

Sagittal view

https://t.me/Freeneetpgnotes

PrepLadder

→ Sites which normally have calcification without any pathology

- Choroid plexus (Occipital horns of lateral ventricles)
- Pineal gland and sometimes falx

Chorid Plexus and Pineal Gland Calcifications

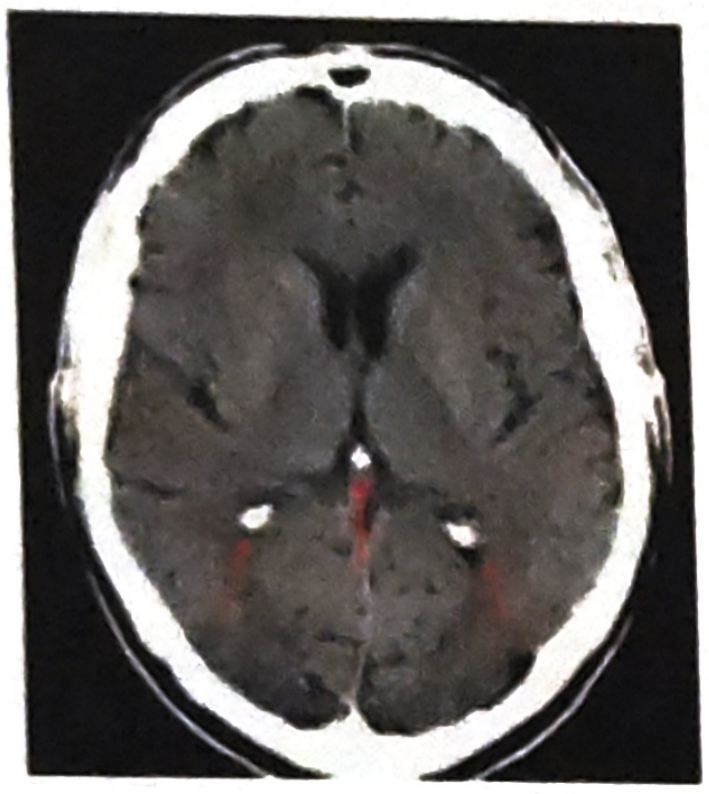

NOTE:

→ IOC for paranasal air sinuses - CT scan

→ IOC for calcification - CT scan

→ IOC for air anywhere - CT scan

→ Example:

1) Pneumocephalus
2) Pneumothorax
3) Pneumomediastinum
4) Pneumoperitoneum
5) Paranasal air sinuses
6) Mastoid air cells

Note:

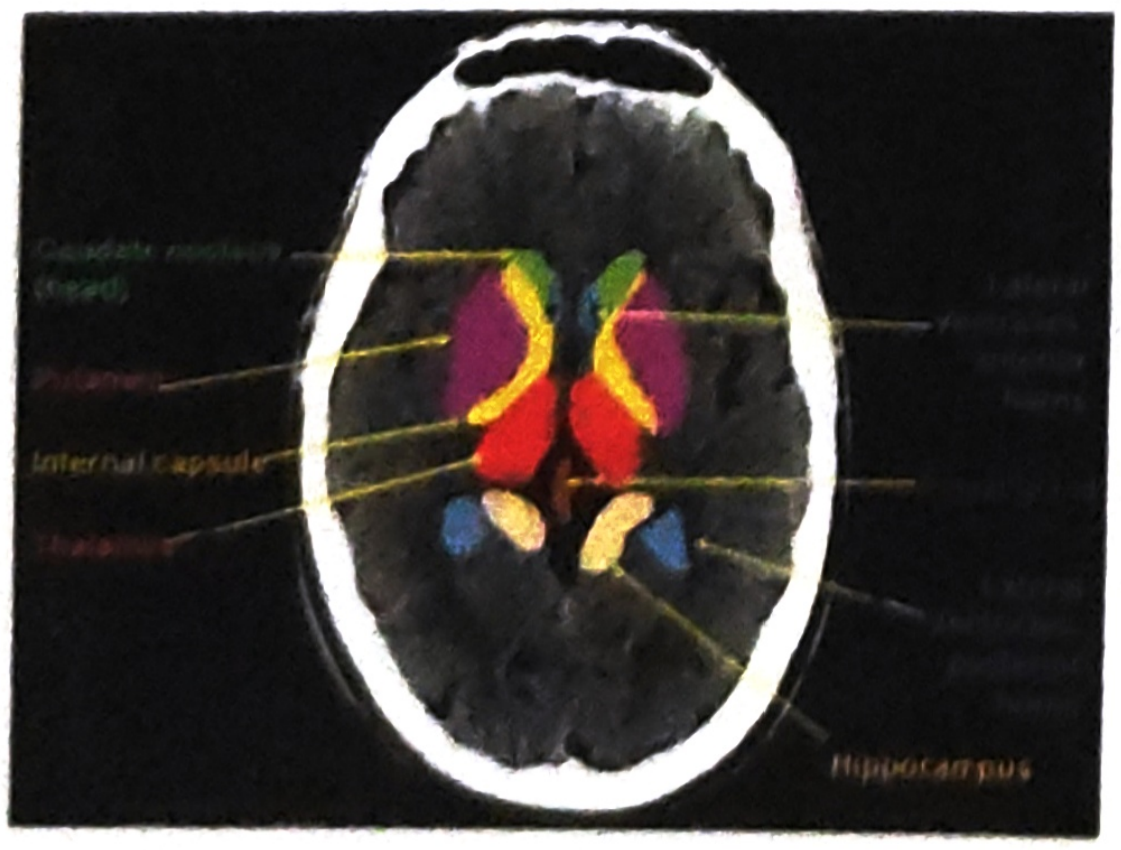

https://t.me/Latestneetpgnotes

PrepLad

Chapter 7

CT SCAN PART – 2

NOTE:

→ IOC for Head trauma - NCCT

→ IOC for stroke / CVA – NCCT

Abdominal trauma →

→ IOC – CECT

→ Initial Investigation → Fast (USG)

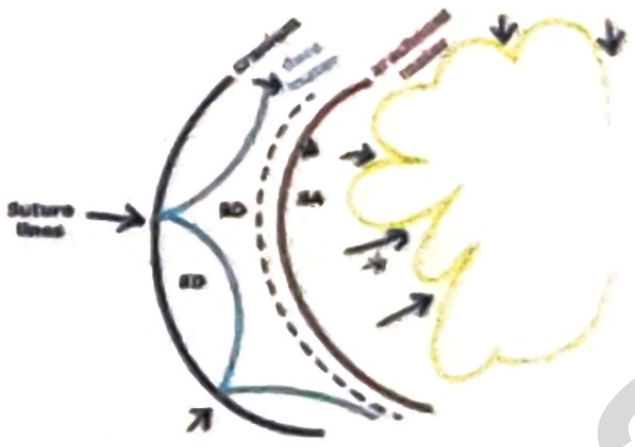

Epidural Hematoma

00:01:29

→ AKA Extradural hematoma

→ Biconvex / lentiform hyperdensity seen

→ Does not cross suture.

→ Happens due to # of pterion (H shaped suture)

→ Due to rupture of middle meningeal artery

→ Causes UNCAL HERNIATION

→ Cause brain stem hemorrhages called Duret Hemorrhage

→ Cause Ipsilateral 3rd nerve palsy

→ Has lucid interv

EDH- swirl sign

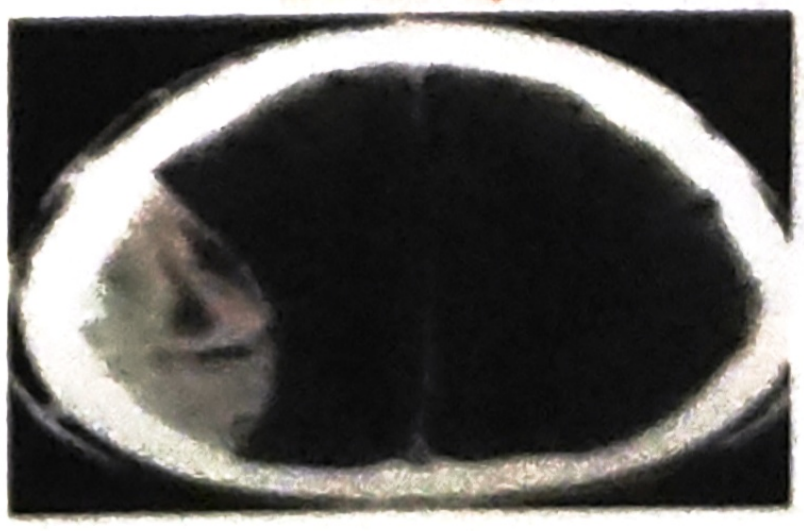

https://t.me/Latestneetpgnotes

PrepLadder

Note:

Swirl Sign

→ Hypodense areas within hyperdense EDH

→ Suggestive of active bleeding

Hematoma evolution on CT

00:08:15

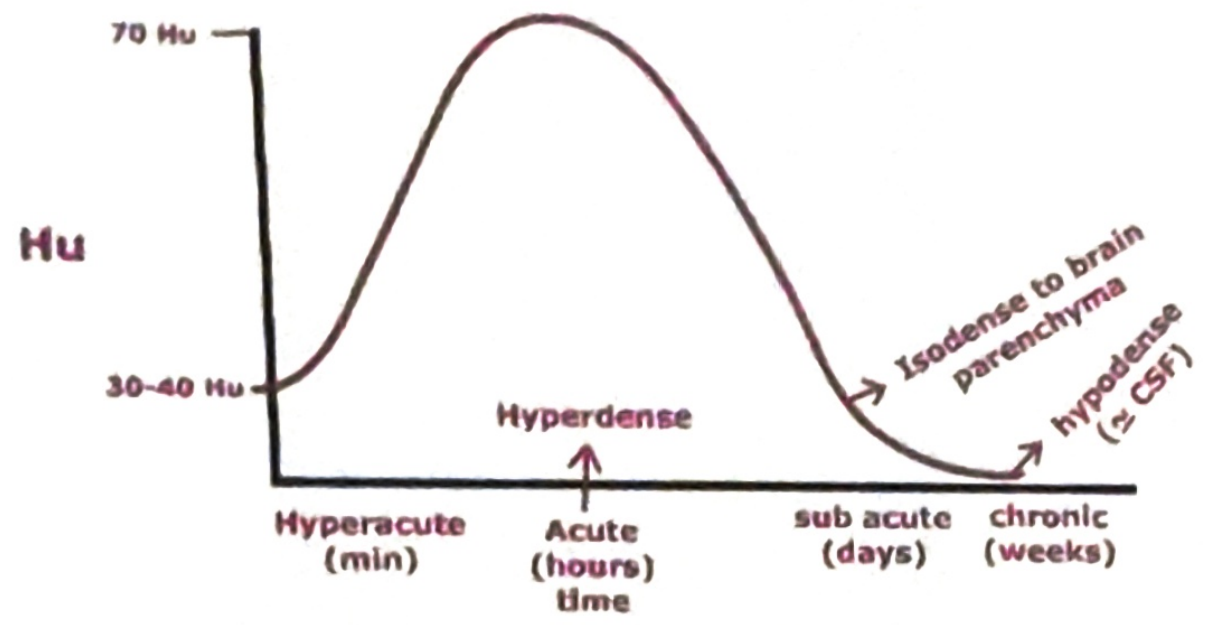

Subdural Hematoma

00:12:50

→ Concavo – convex or crescentic shaped.

→ Cross suture line, does not cross midline

→ Happens due to rupture of Bridging Veins

→ Seen with

- Chronic old trauma
- Cortical atrophy
- Alzheimer's ds
- Punch Drunk syndrome
- Battered Baby syndrome/ Shaken Baby syndrome

  (BBS also has metaphyseal corner #)

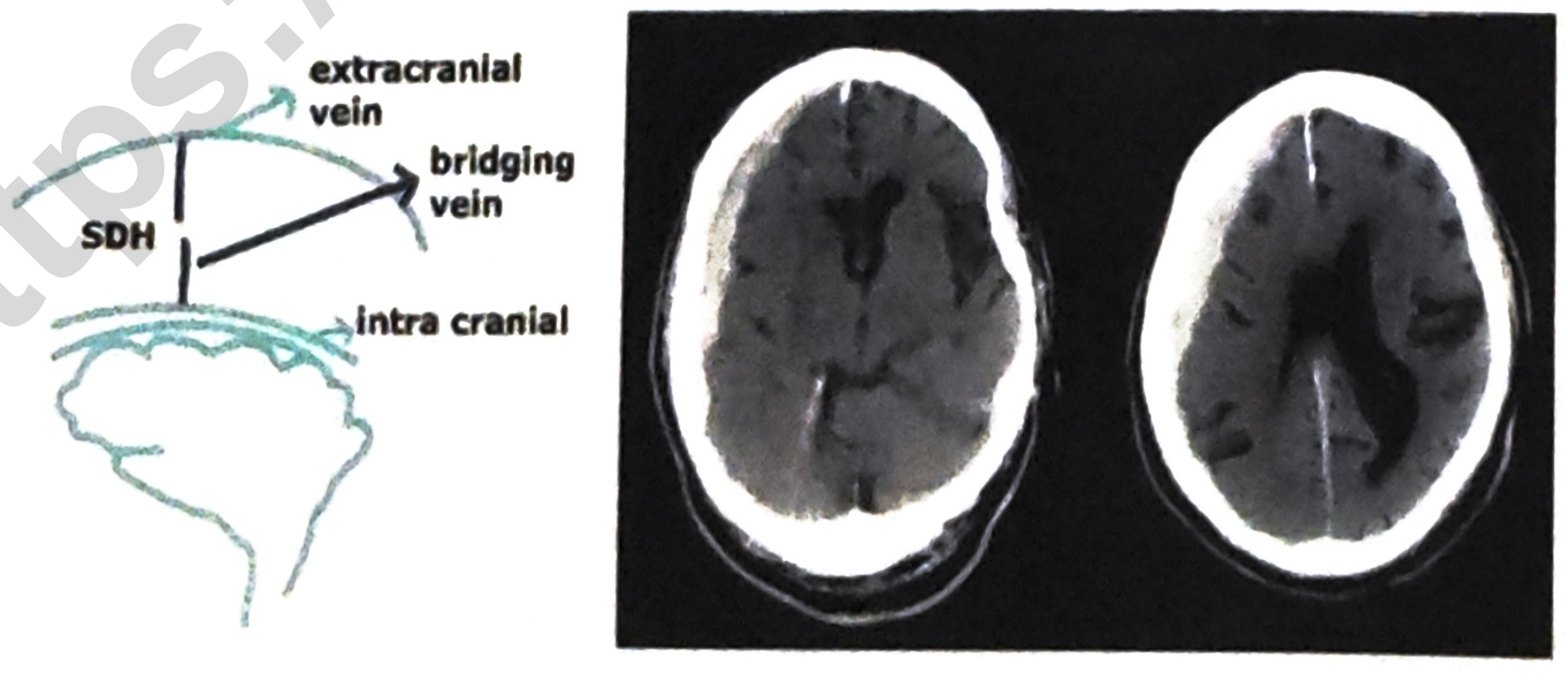

Subdural Hematoma

https://t.me/Latestneetpgnotes

PrepL

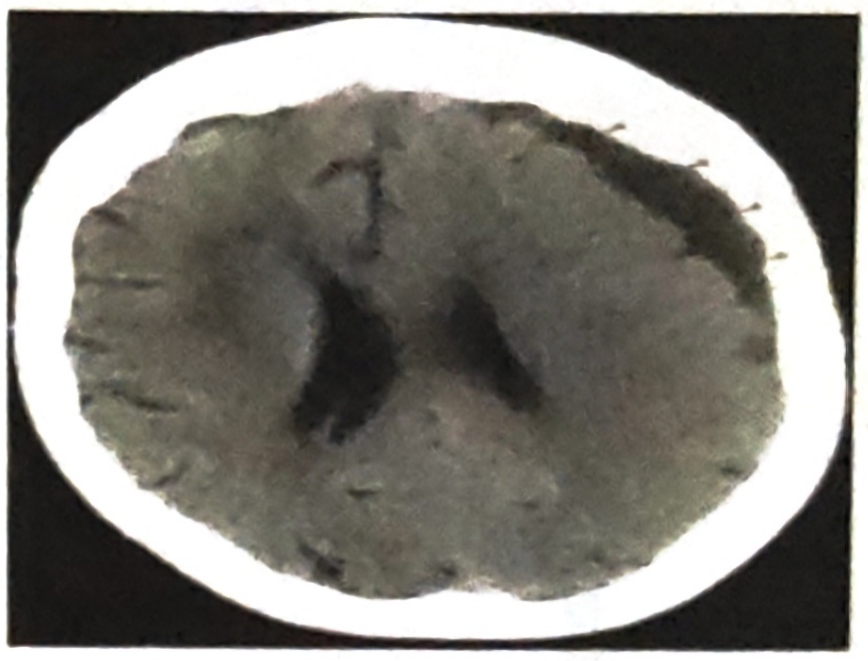

Chronic Subdural Hematoma

Subarachnoid Hemorrhage 00:18:15

→ MCC of subarachnoid hemorrhage is: TRAUMA

→ MCC of spontaneous SAH is due to rupture of BERRY ANEURYSM

→ Classical complaint pts come with is THUNDER CLAP HEADACHE "Worst Headache of life"

→ Shows Hyper density in:

- Sylvian fissure
- Basal cisterns
- Sulcal spaces
- Anterior interhemispheric area

→ IOC for Acute SAH - NCCT

→ IOC for Chronic SAH - MRI.

→ IOC to know the cause of SAH - 4 VESSEL ANGIOGRAPHY – (for that contrast infected into 2 ICA and left vertebral artery.)

NOTE:

→ Acute SAH – CT-Angiography

→ MR – Angiography → For screening of Berry Aneurysm

Intra parenchymal hemorrhage 00:24:36

→ Most common site of hypertensive bleed is putamen

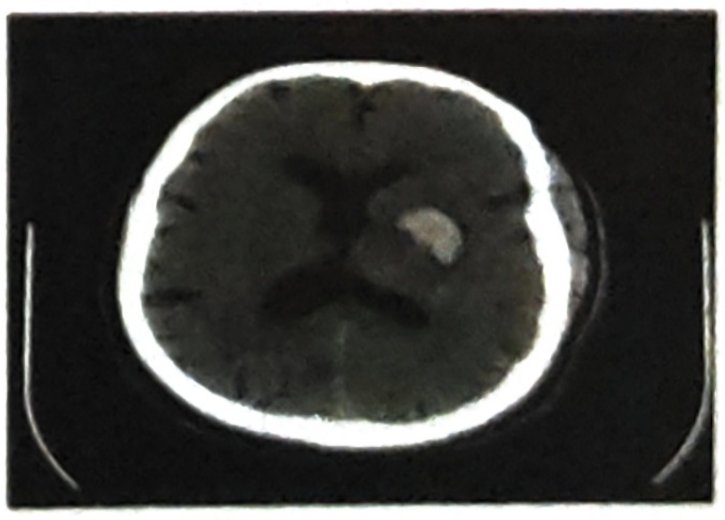

Intra parenchymal hemorrhage

https://t.me/Latestneetpgnotes

PrepLadder

Intraventricular bleed:

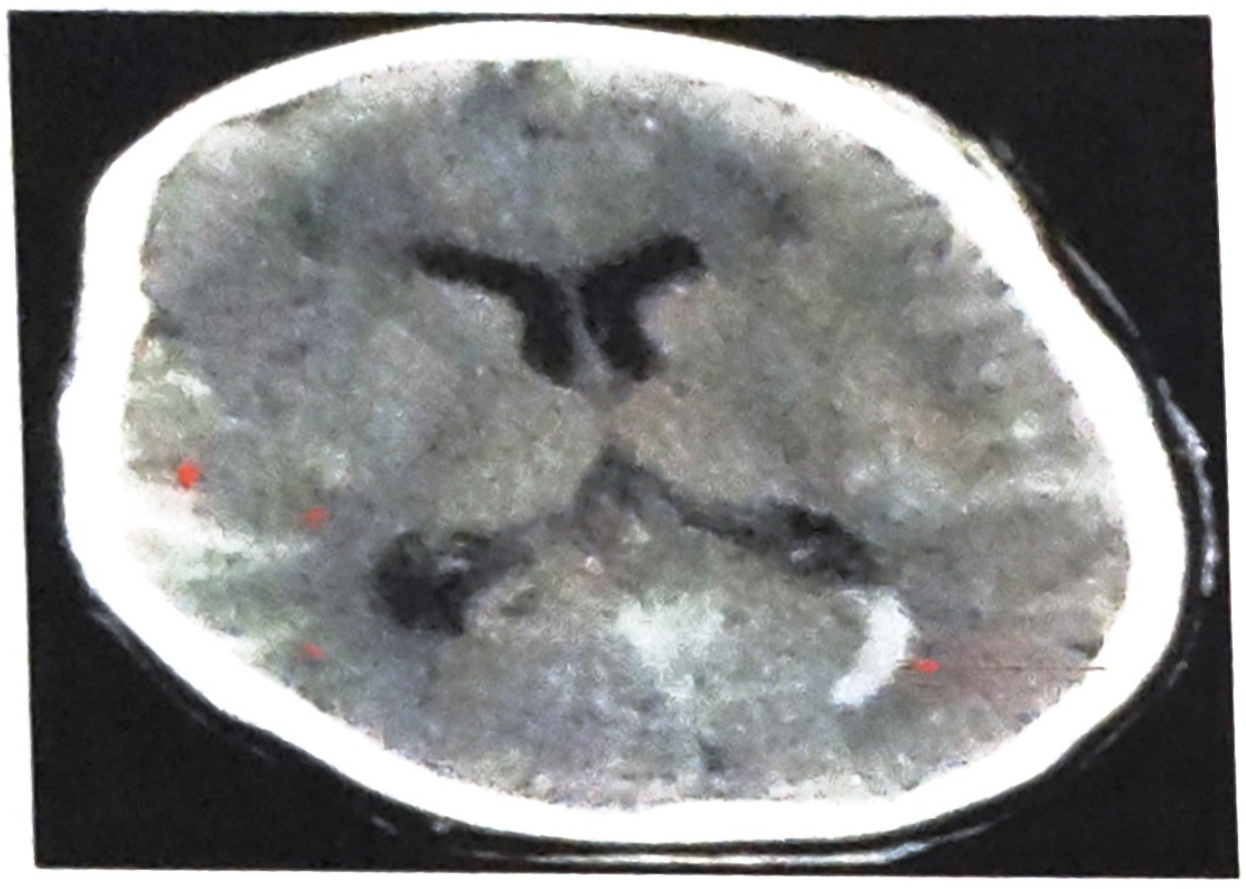

Intraventricular bleed – Occipital horn of lateral ventricle

Stroke

00:25:45

→ IOC for stroke - NCCT

→ IOC for acute infarct/ ischemic - MRI (Diffusion weighted MRI)

Stroke / Hemiplegia /CVA
↓
NCCT
↓
- Hyperdense → Hemorrhagic stroke
- Hypodense/Normal → Ischemic stroke/acute infarct → MRI (Diffusion weighted MRI)

Radiological signs of acute infract on CT scan

→ Hyperdense MCA

→ Sylvian Dot Sign

→ Obscuration of lentiform nucleus

→ Absent in insular ribbon sign

https://t.me/Latestneetpgnotes

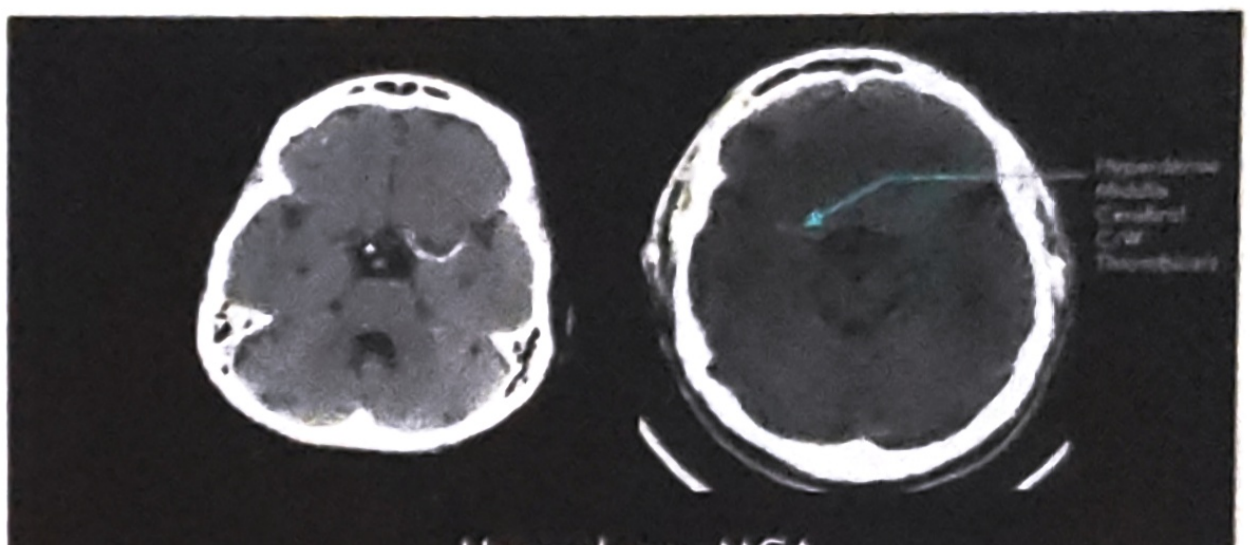

Hyperdense MCA

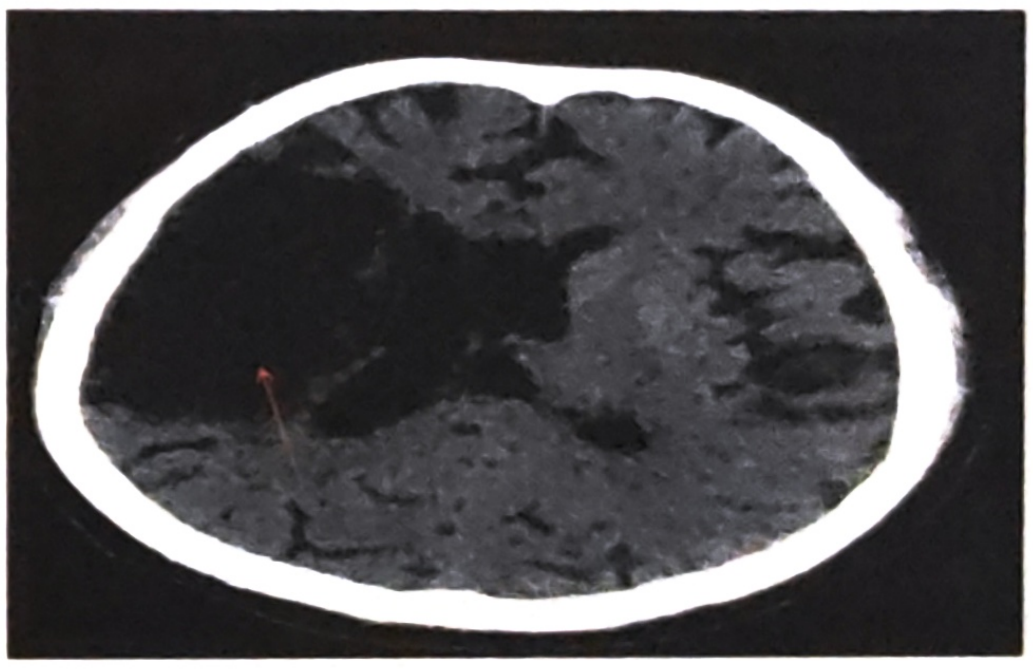

MCA infarct

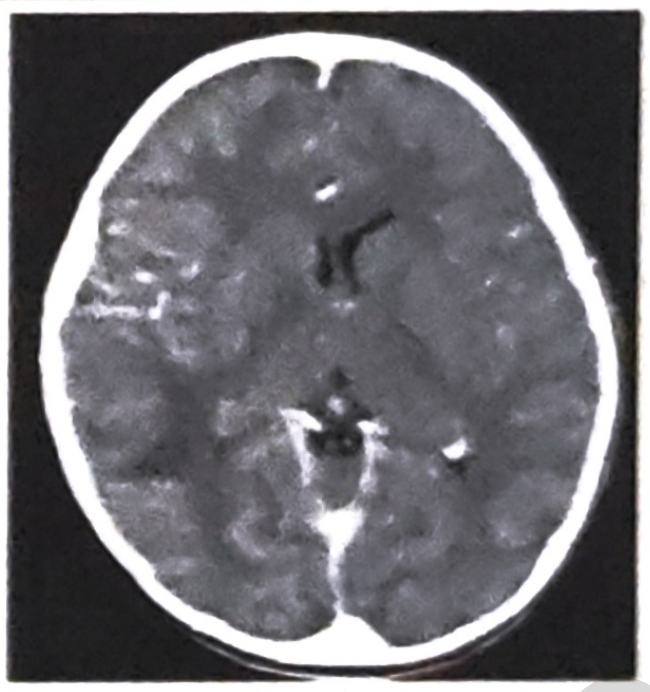

CECT

Superior Sagittal Sinus Thrombosis

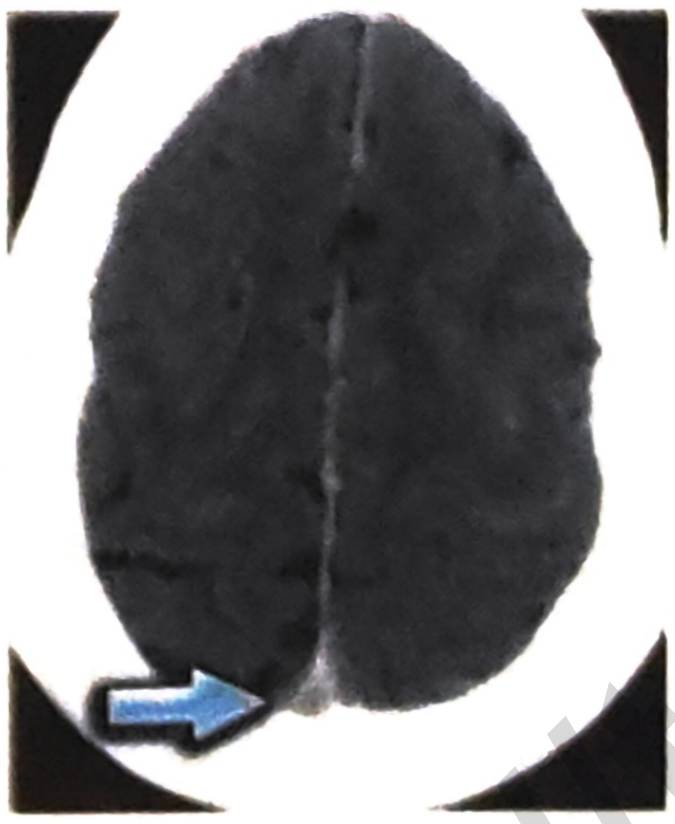

NCCT – Delta Sign

CECT – Empty Delta Sign

CT Anatomy of Neck & Mediastinum

00:34:26

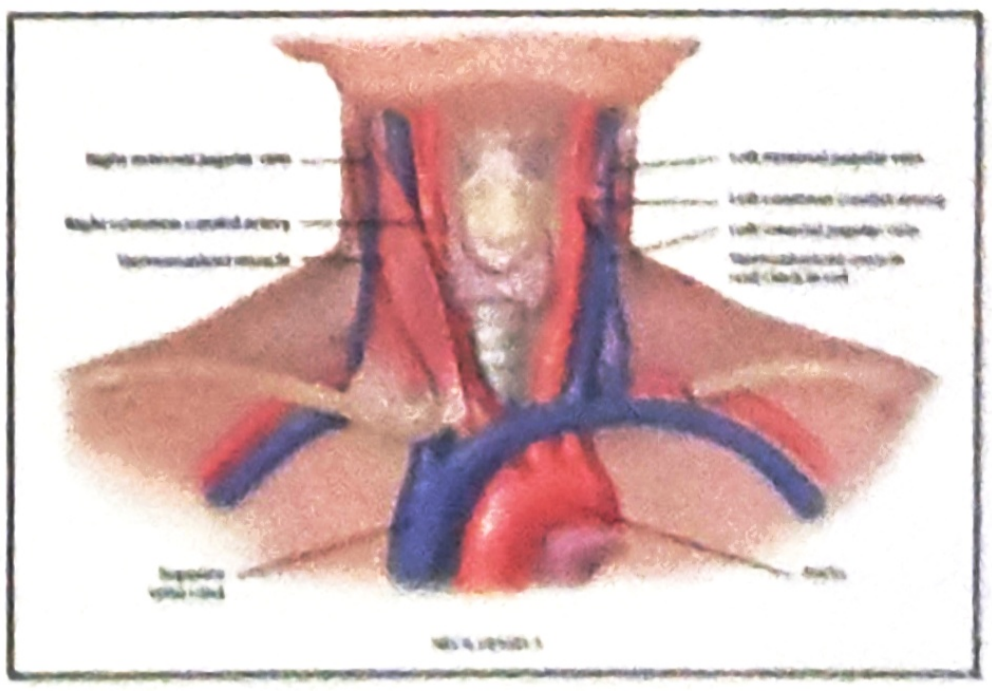

https://t.me/Latestneetpgnotes

PrepLadder

CT at the level of neck:

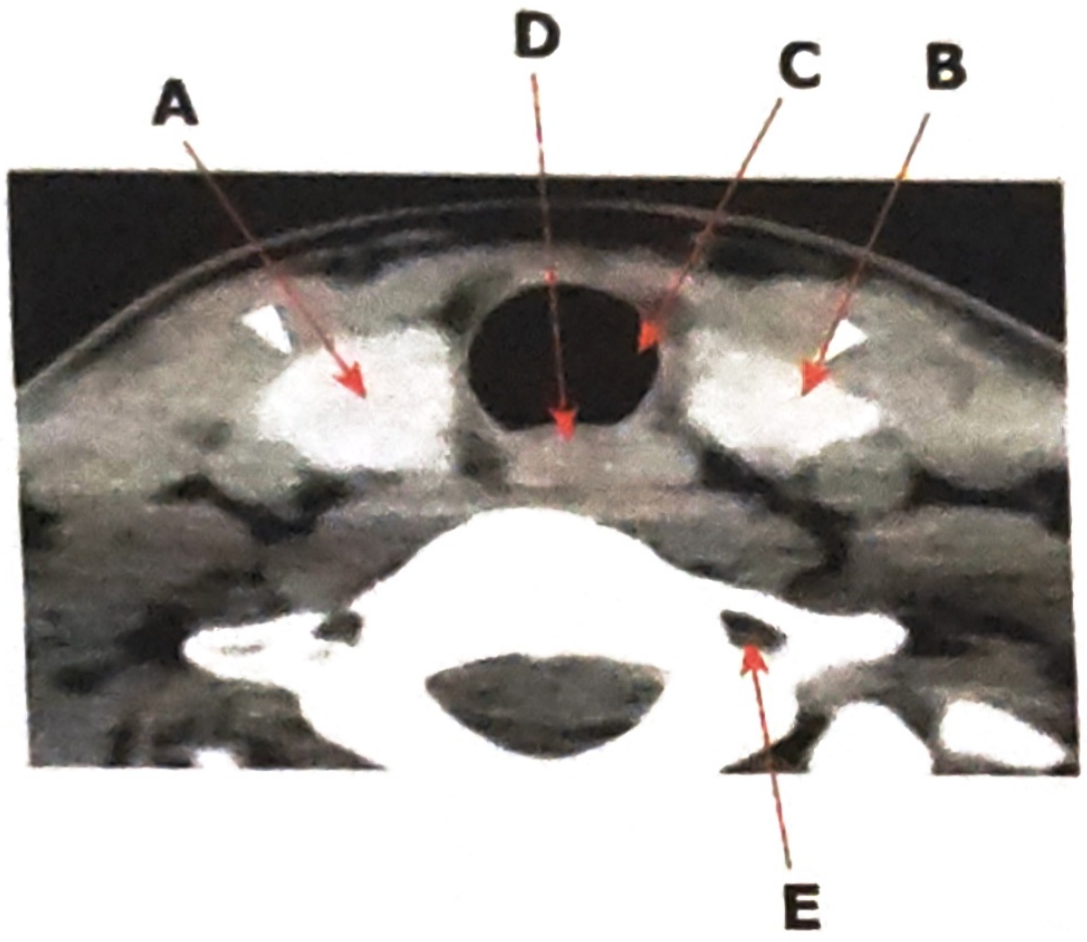

A – Right lobe of thyroid

B – Left lobe of thyroid

C – Trachea

D – Esophagus

E – Foramen transversarium (vertebral artery passes)

Most hyper dense soft tissue at the level of neck – Thyroid

CT-Neck

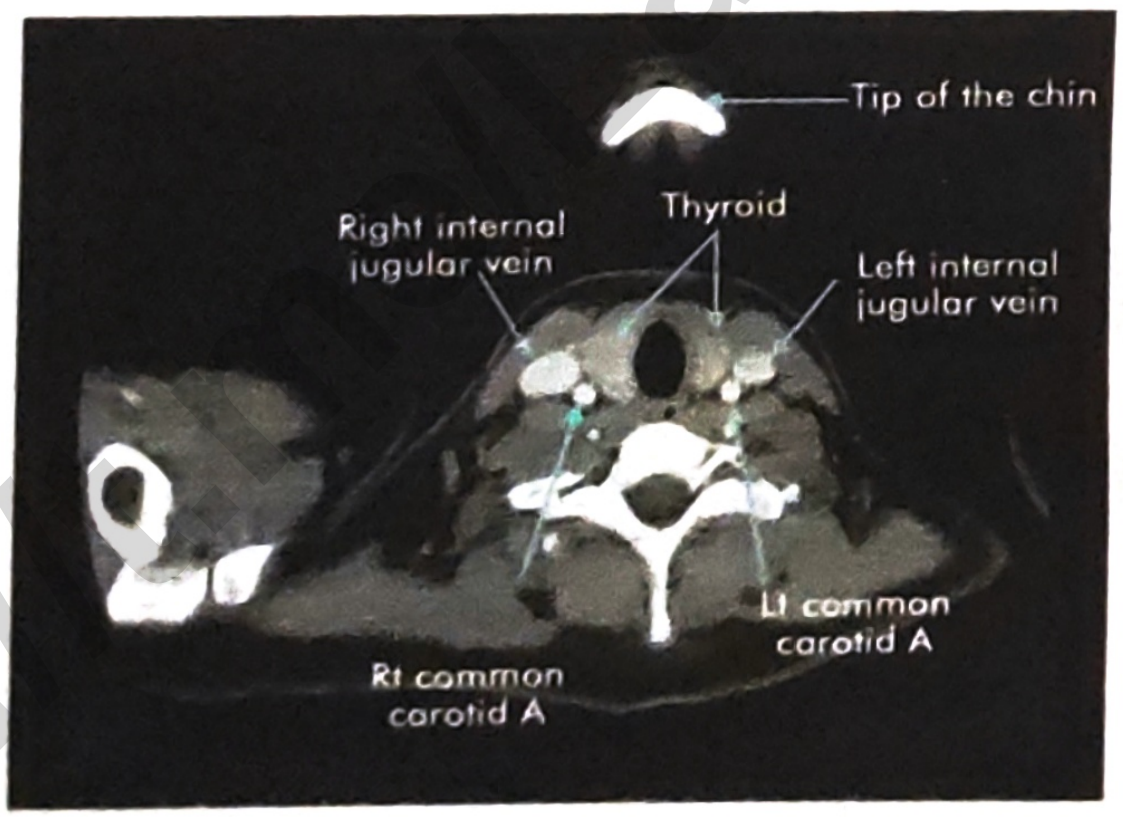

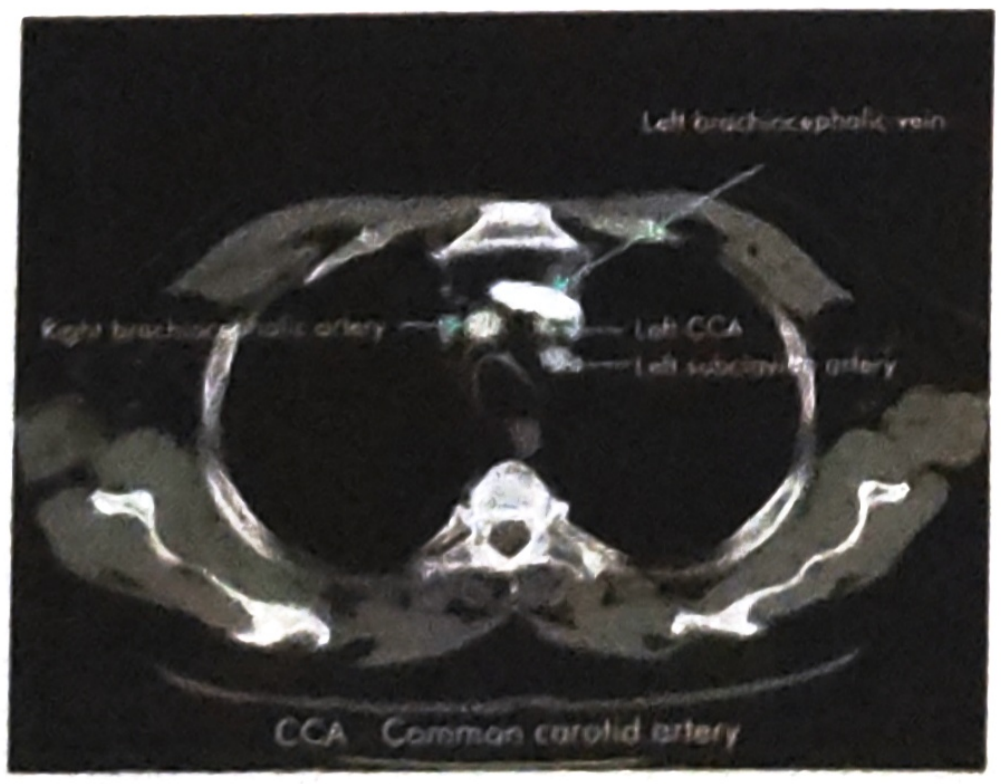

CT mediastinum region

At the level of Arch of aorta
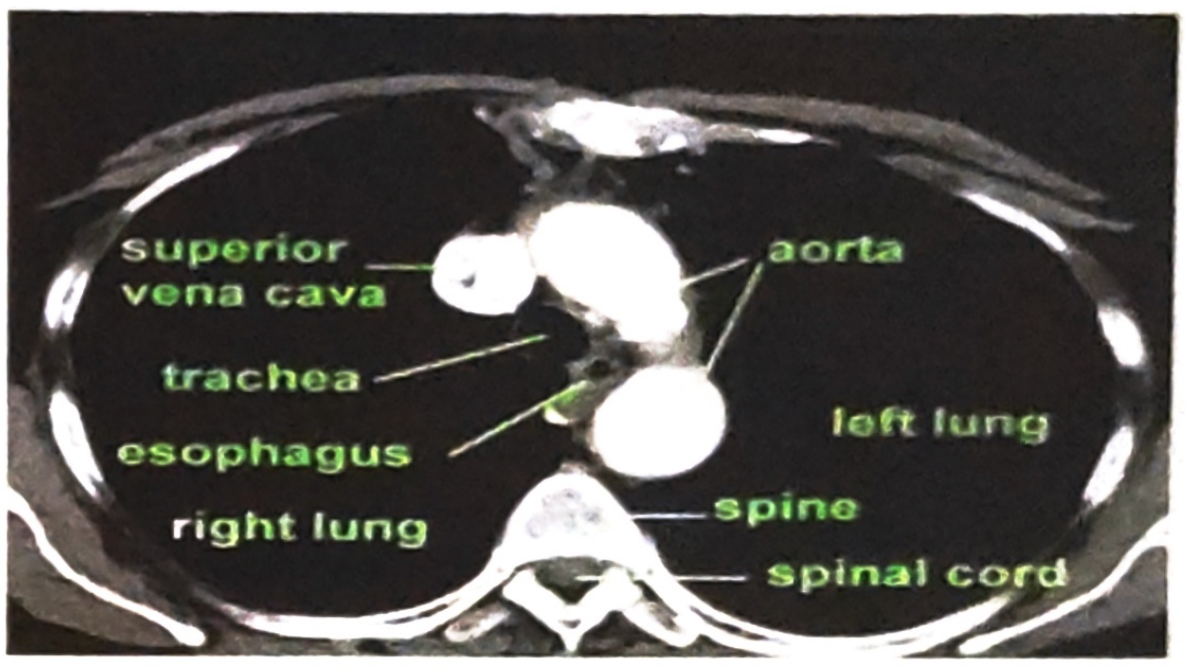
Below the Arch of aorta
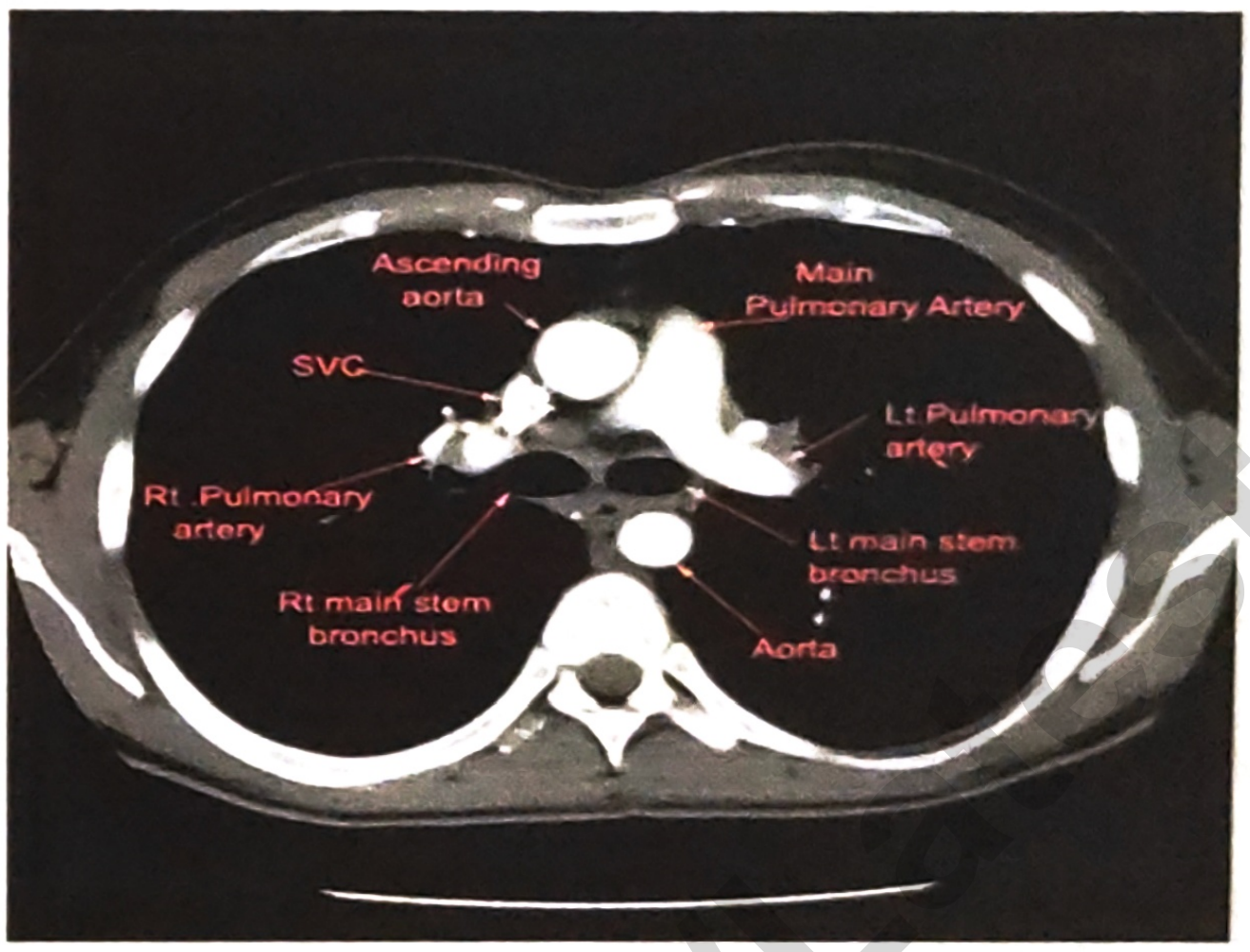

Aortic dissection

- → M/C site of aortic dissection is ascending aorta
- → Intimal flap with double lumen is seen
- → IOC for acute aortic dissection → CT angiogram (stable pt.)
  → TEE (unstable pt.)
- → IOC for Chronic aortic dissection – MRI

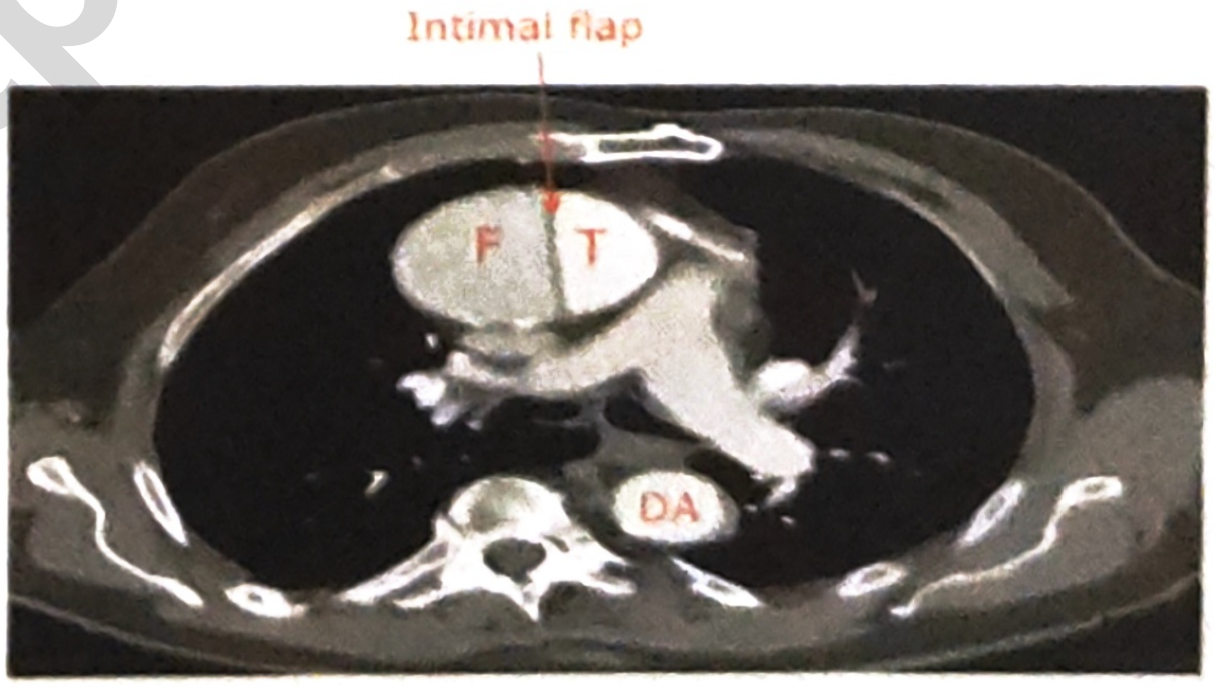

Aortic dissection

PrepLadder

CT at the level of Heart

- Left atrium is the posterior most chamber (If LA is hypertrophied esophagus gets indented)
- Right ventricle is the anterior most chamber (if RV is hypertrophied Retrosternal space gets obliterated)

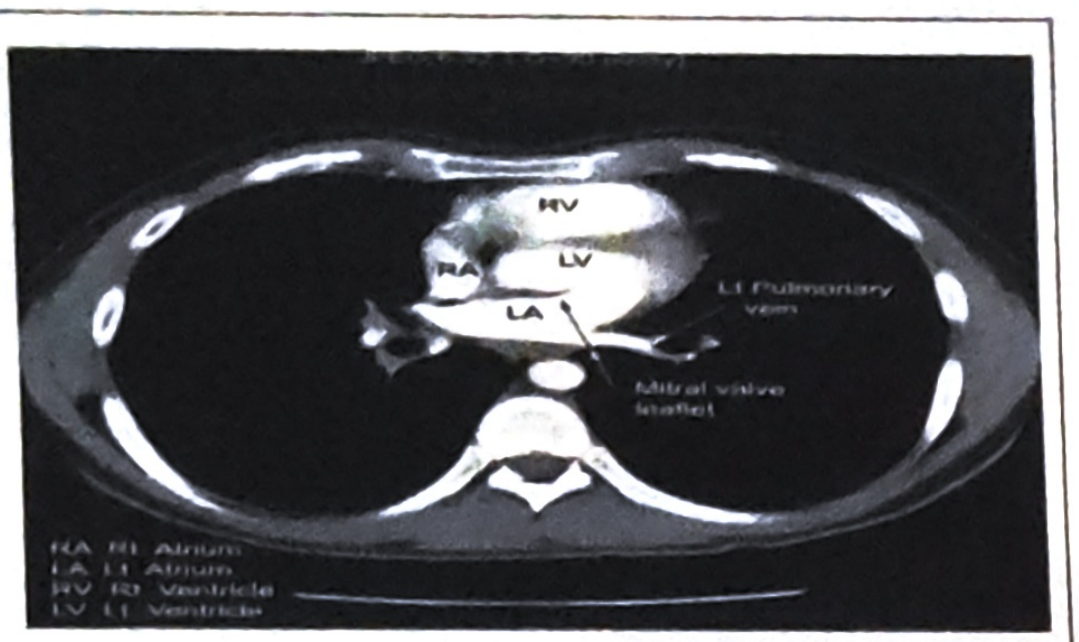

CT at the level of Heart

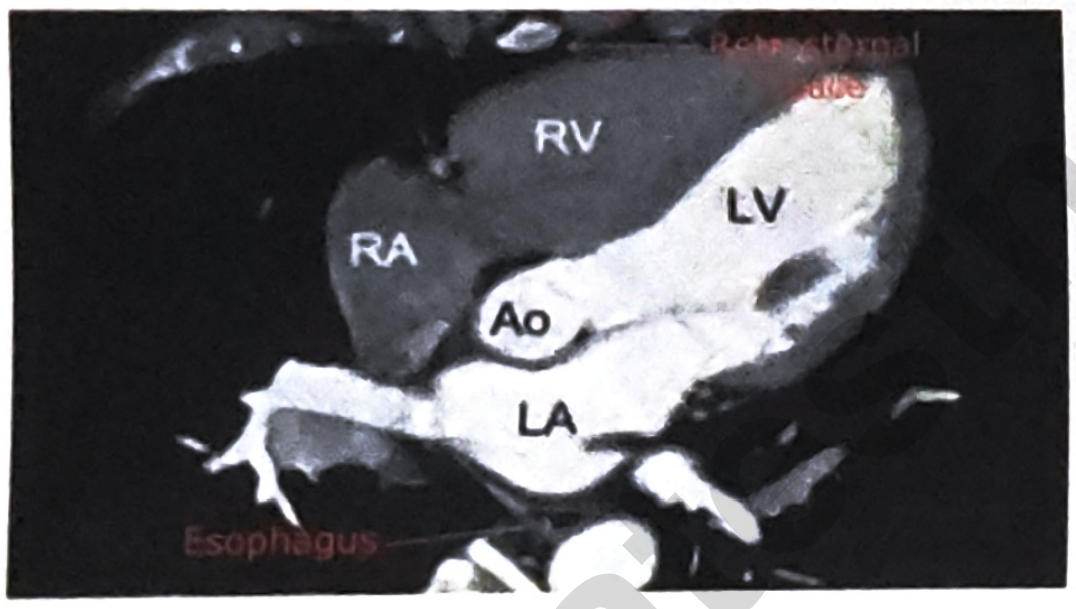

CT at the level of Heart

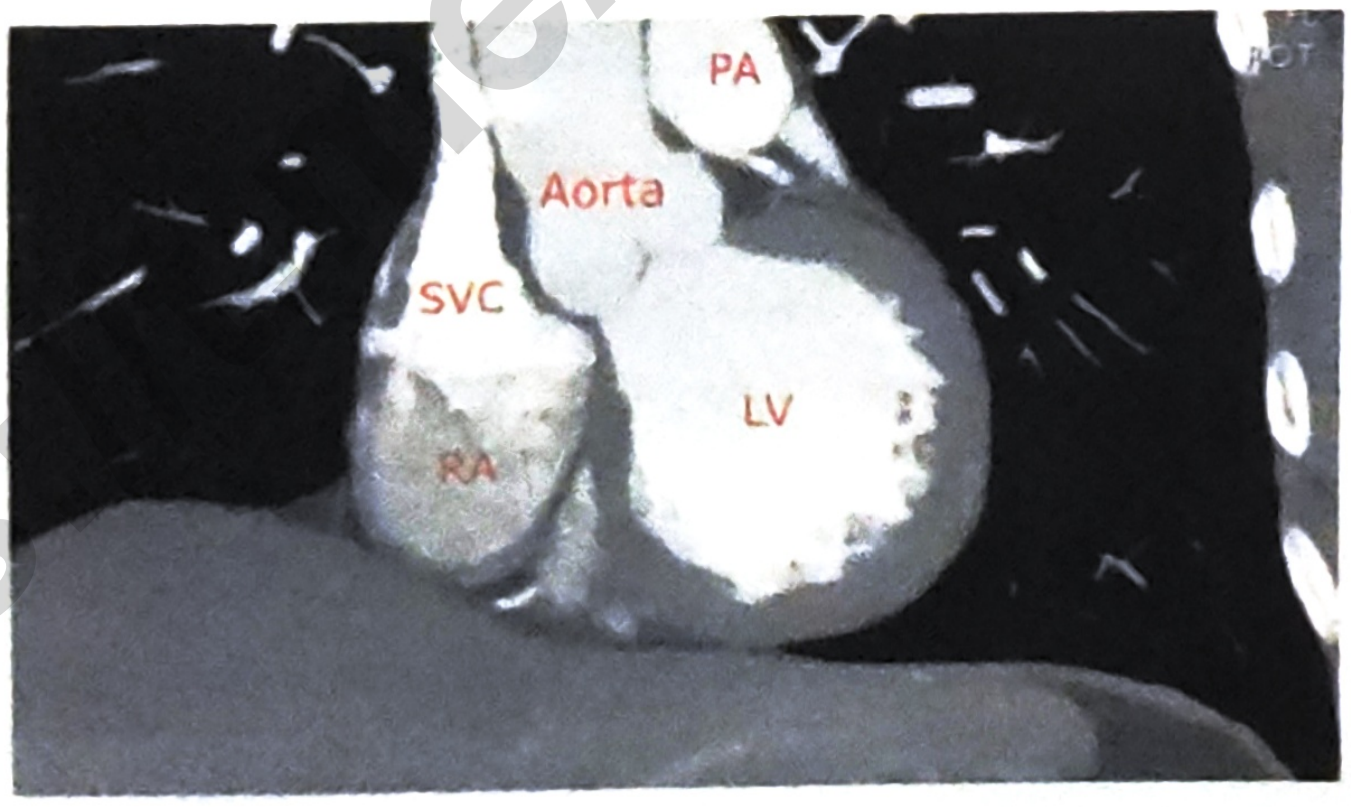

Coronal CT of Heart

Windowing in CT Scan 00:45:40

→ Post processing of CT scan images

→ To see the important/ required structure better

https://t.me/Latestneetpgnotes

PrepLa

Lung window

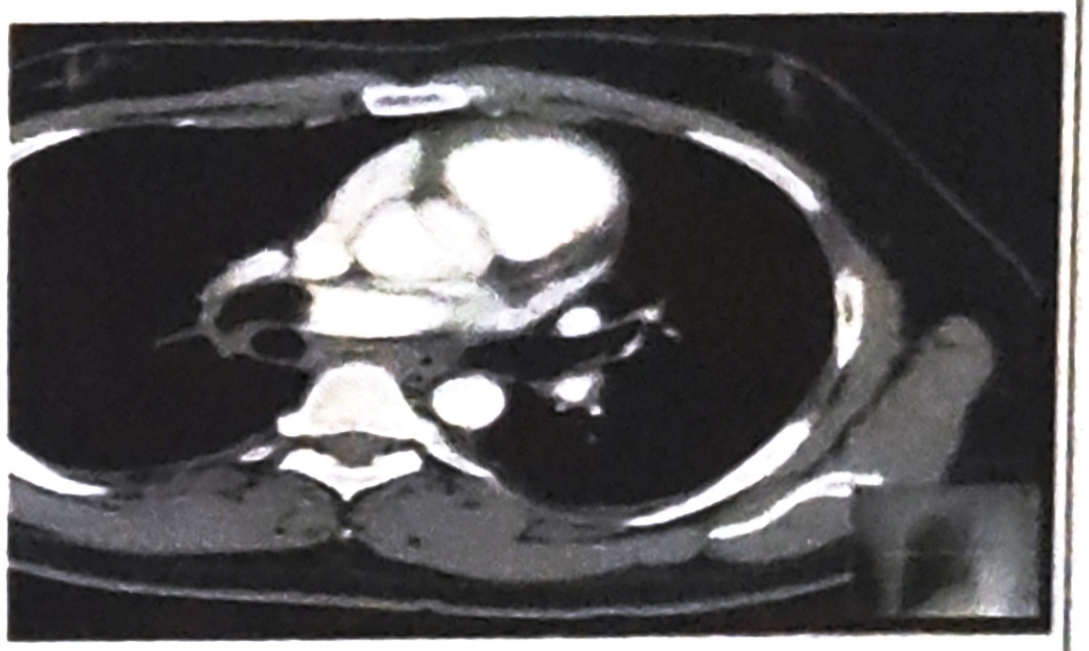

Mediastinal window

Lung window

Azygous Lobe

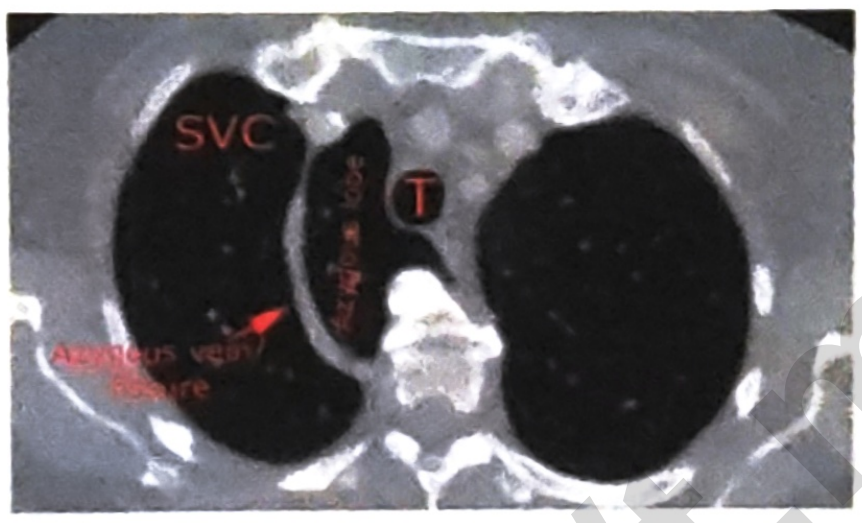

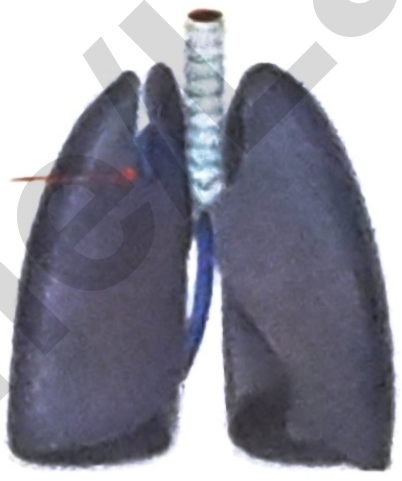

Pneumothorax

→ Air inside the pleural cavity

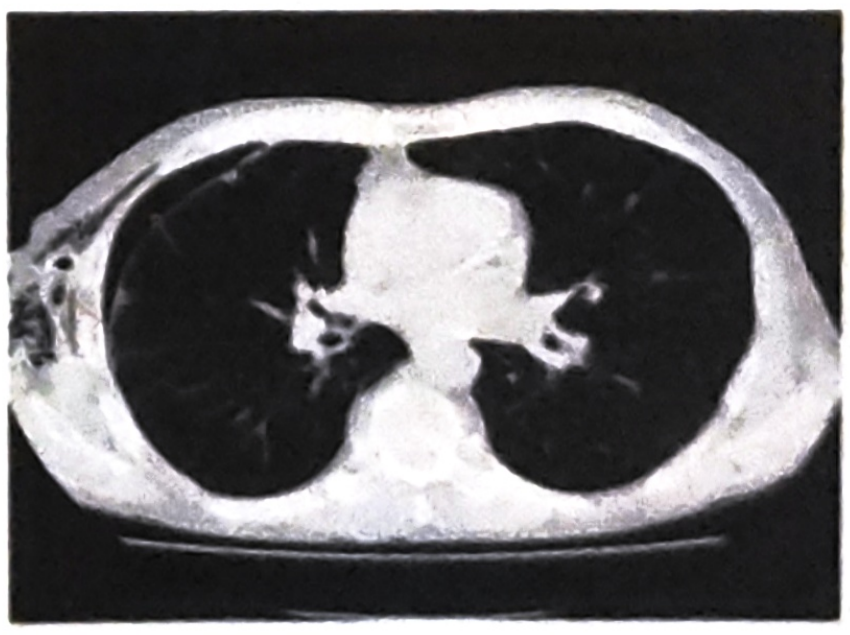

Pneumothorax

https://t.me/latestneetpgnotes

PrepLadder

Coronal CT - Abdomen

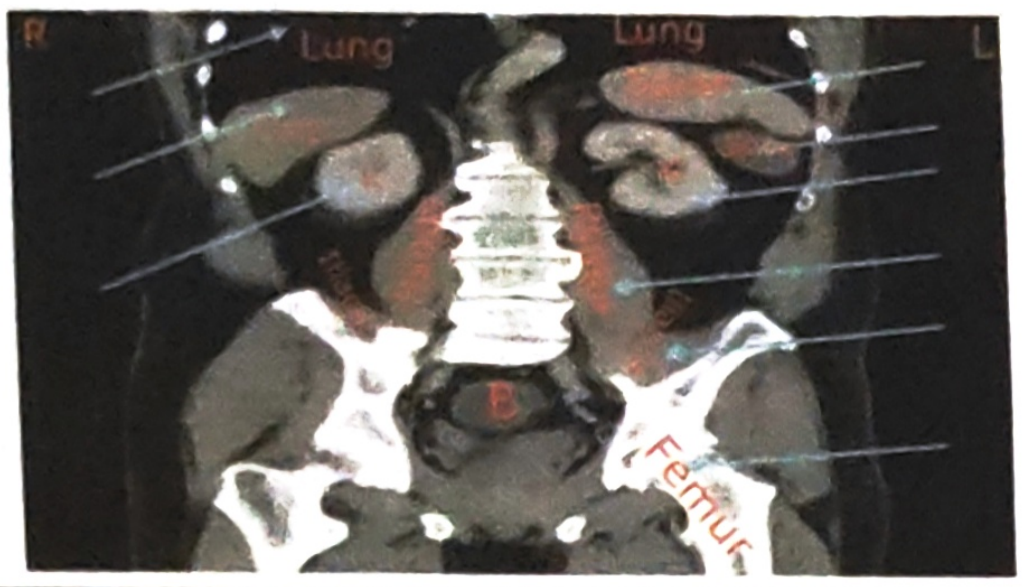

CT abdomen: (NORMAL) – AXIAL

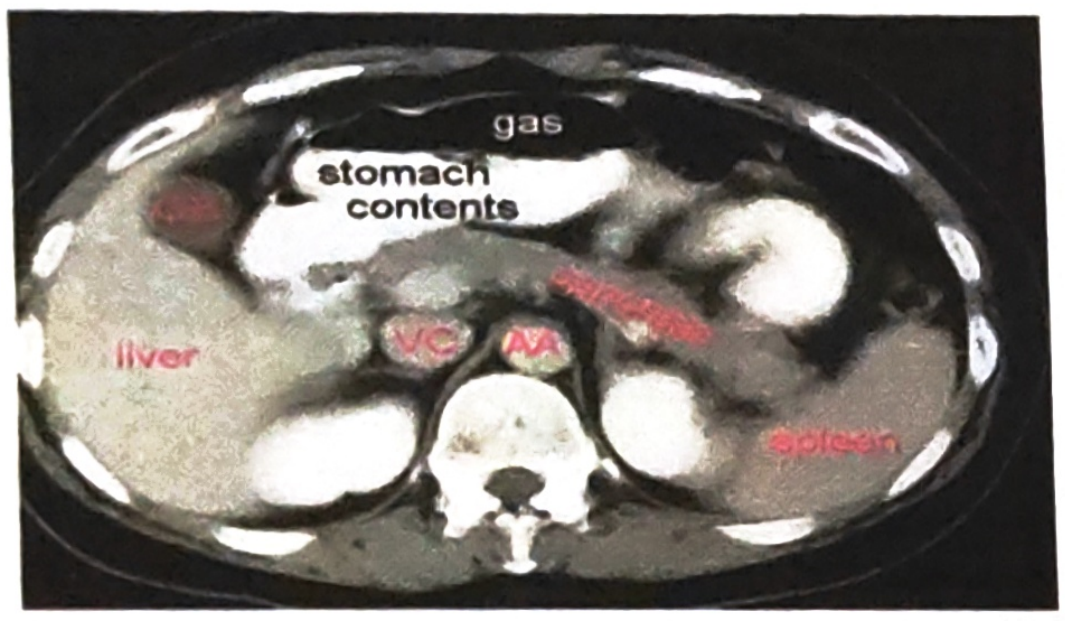

CECT of Abdomen:

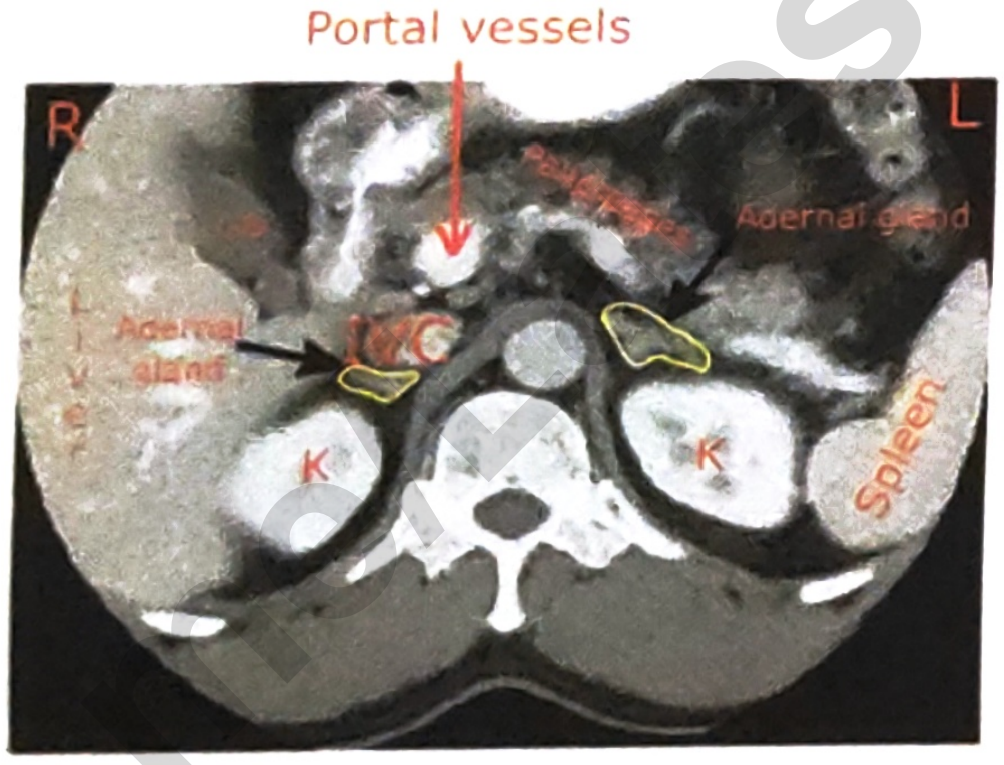

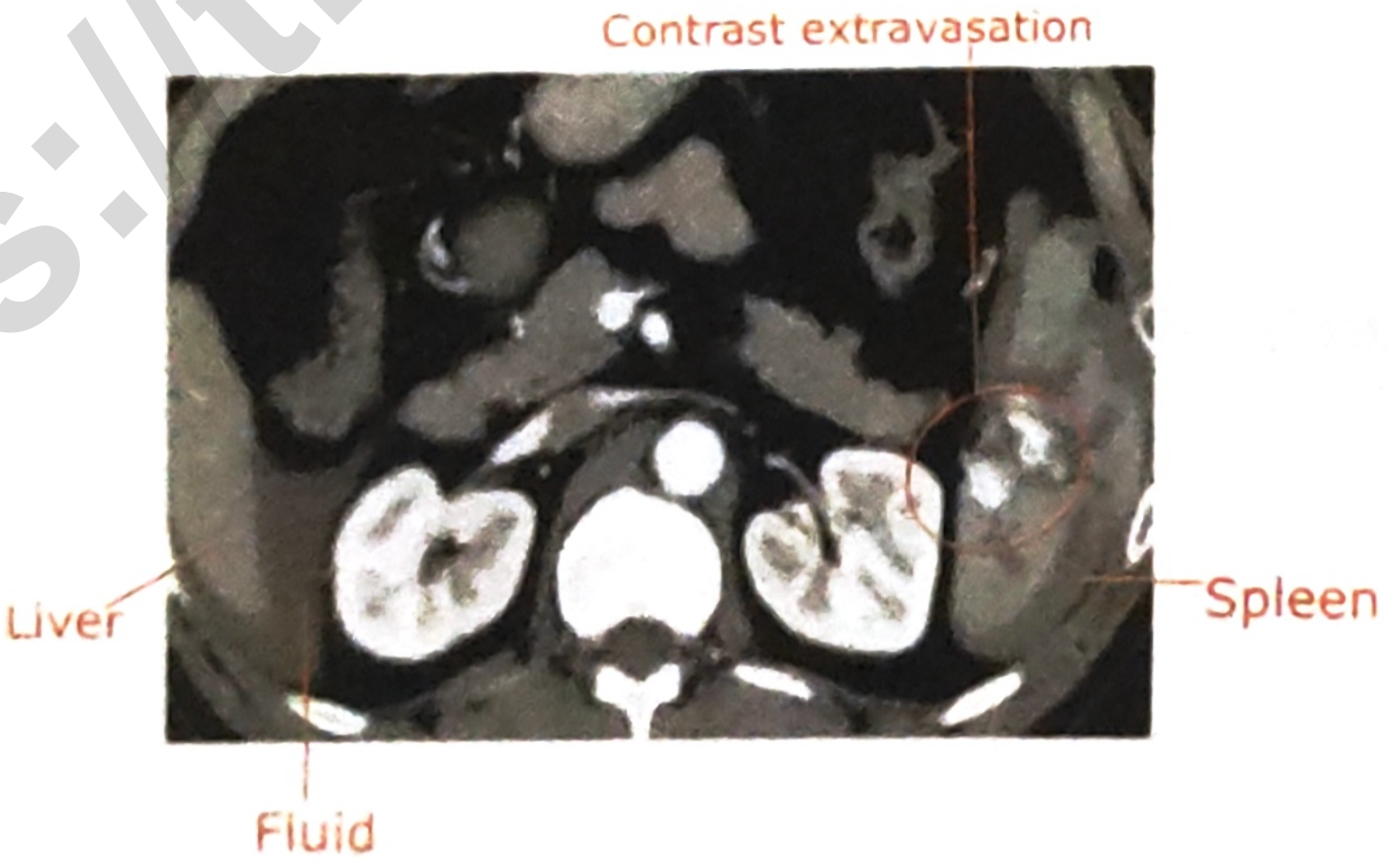

Extravasation of contrast from spleen suggestive of active bleeding from spleen

https://t.me/postneetpgnotes

PrepLa

Polo mint sign

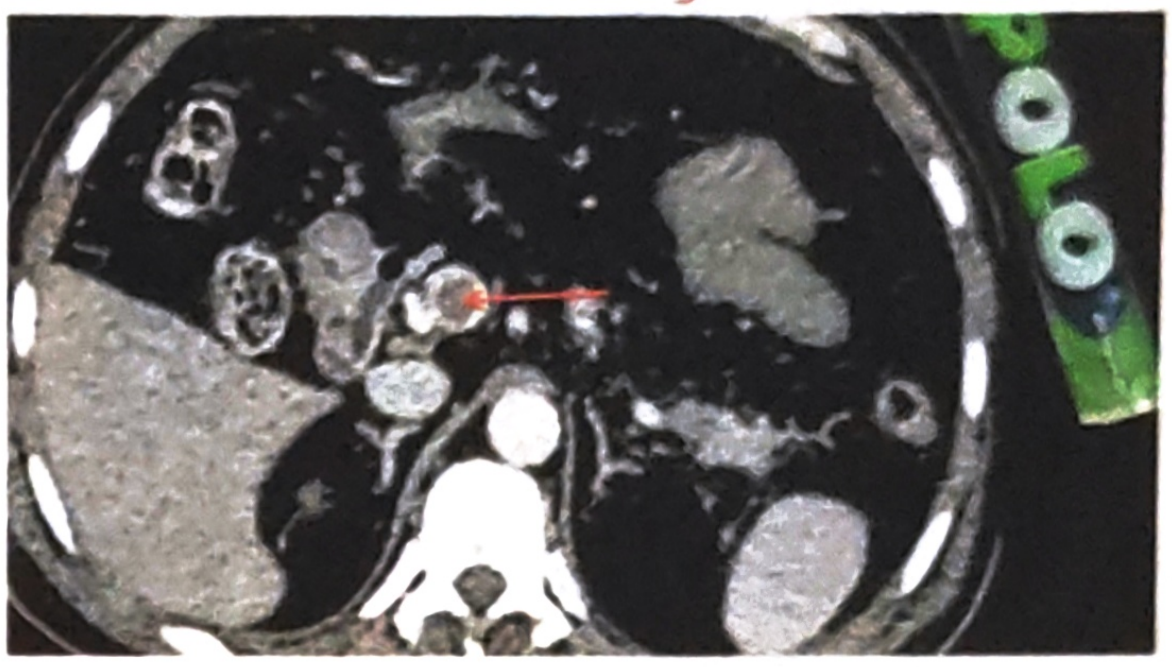

Note:

→ In venous thrombosis we can see a filling defect known as "POLO MINT SIGN"

→ IOC for abdominal is CECT

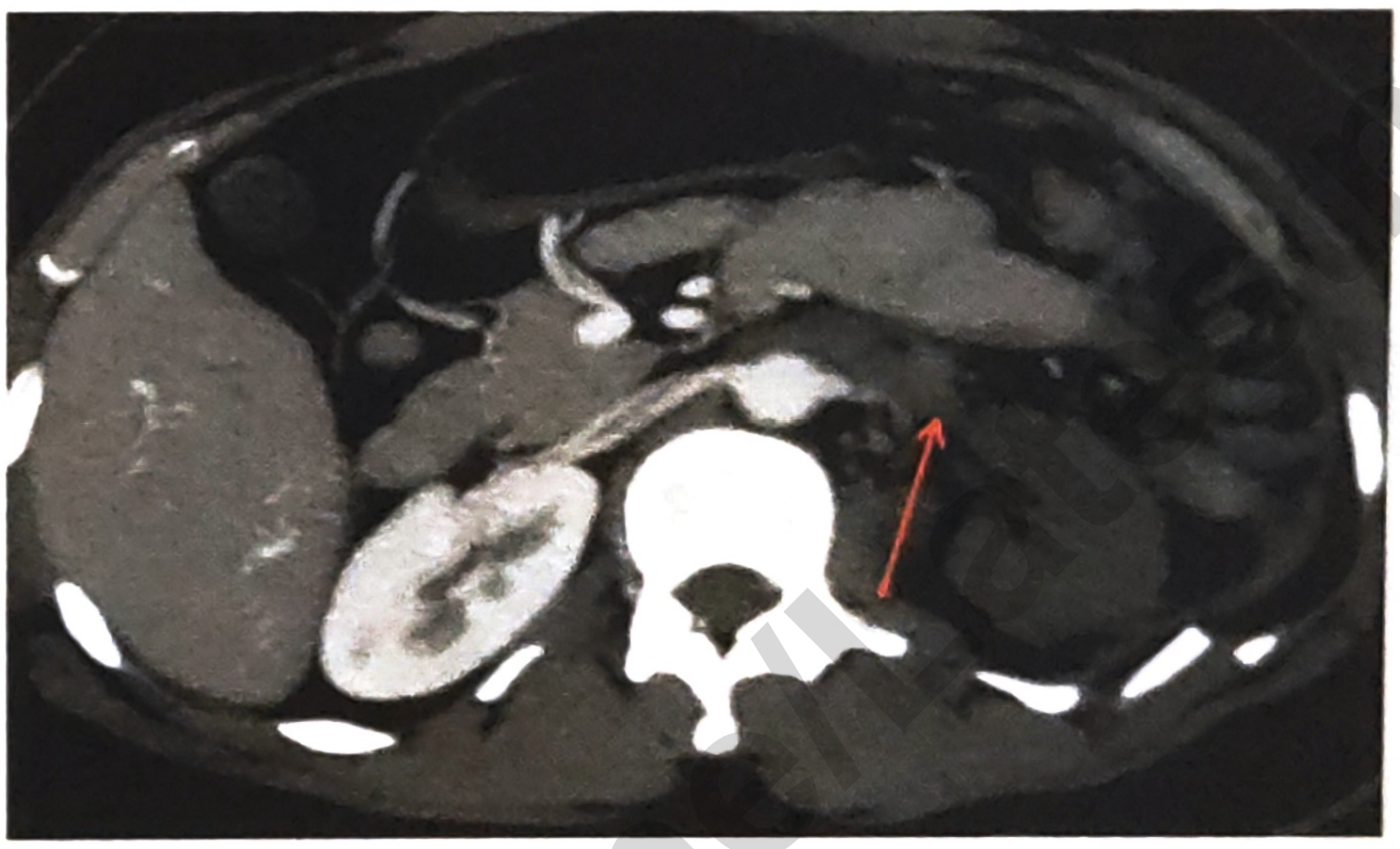

Renal pedicle injury

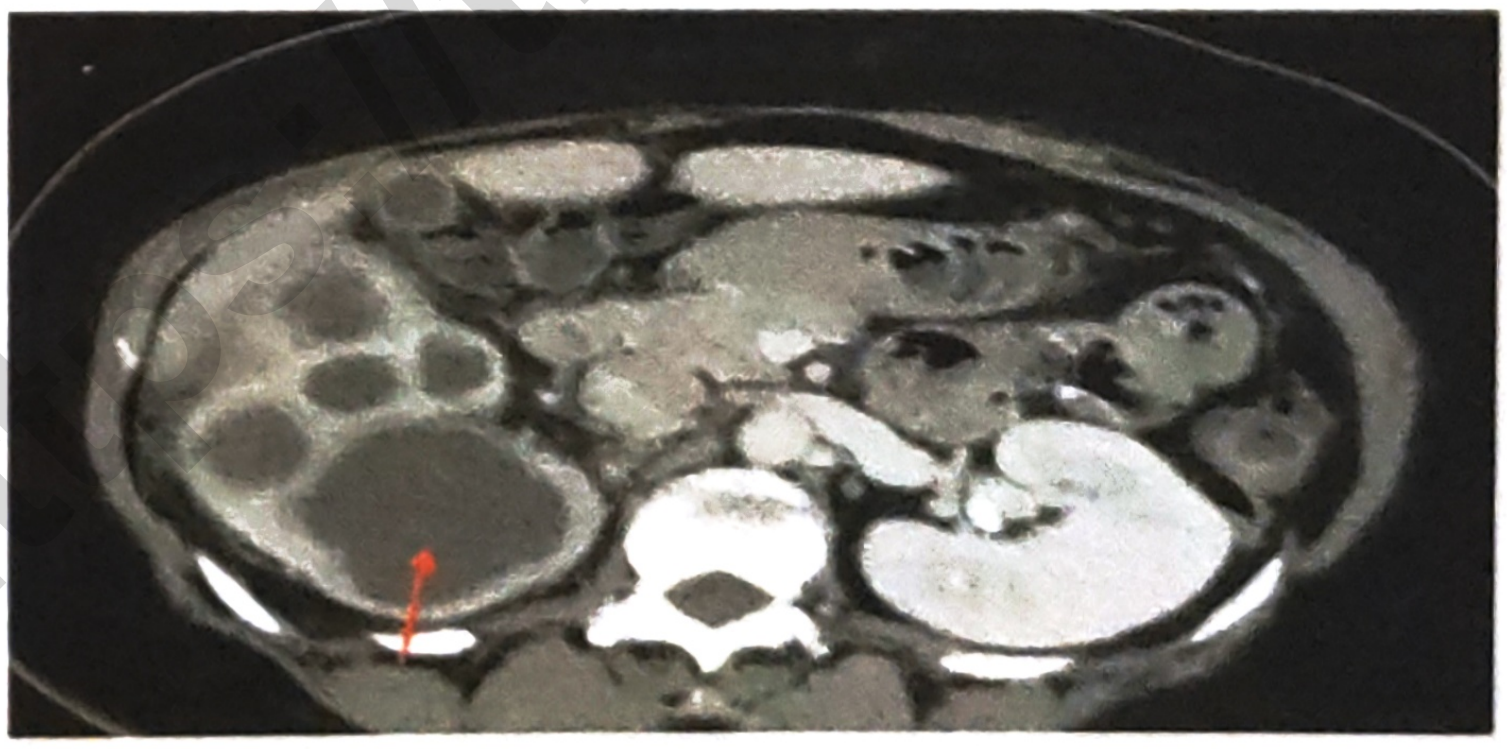

Bear paw sign

https://t.me/neetpgnotes

PrepLadder

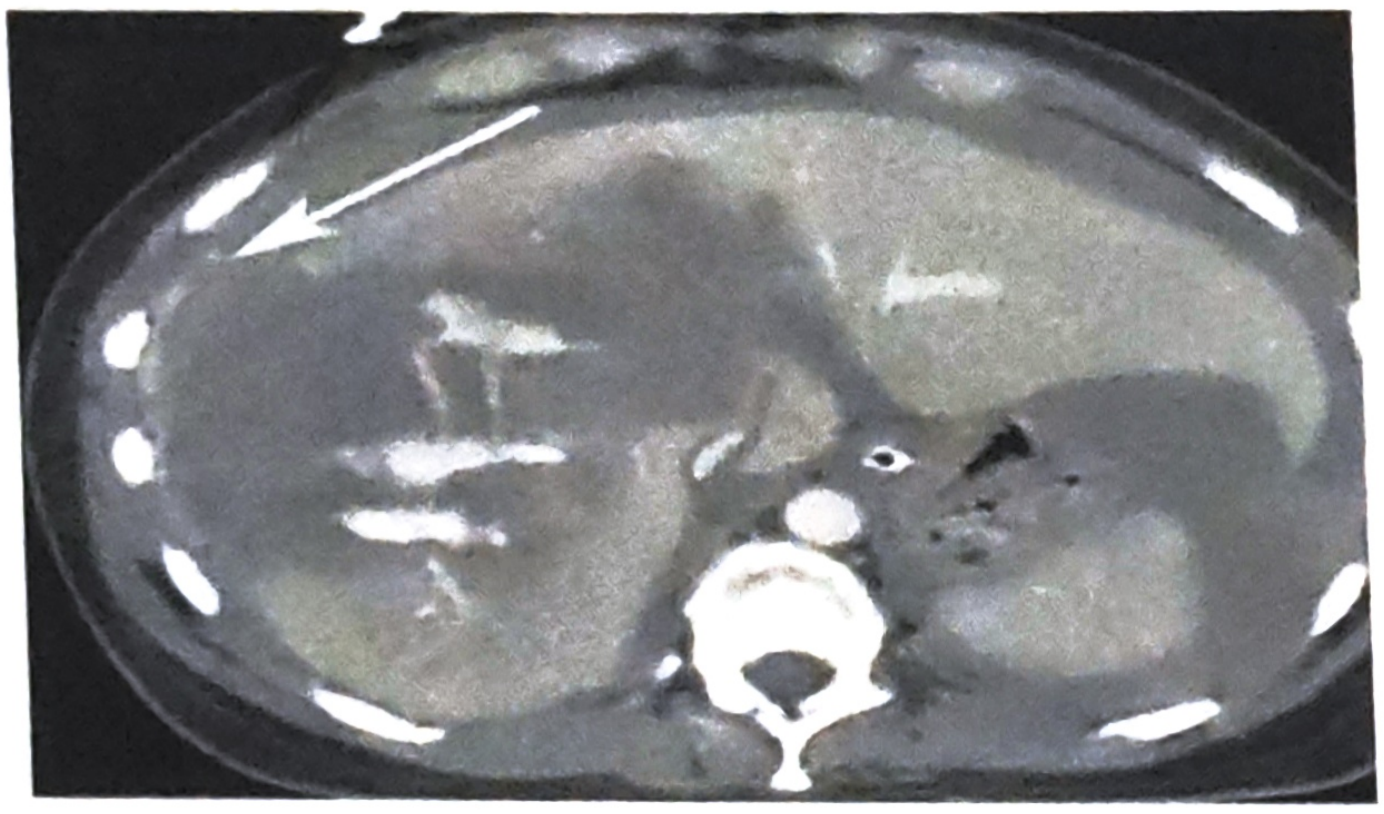

Bear claw sign

Note:

→ Bear Claw sign – Hepatic laceration

→ Bear Paw sign – Xanthogranulomatous pyelonephritis

CT at the Level of pelvis 00:58:41

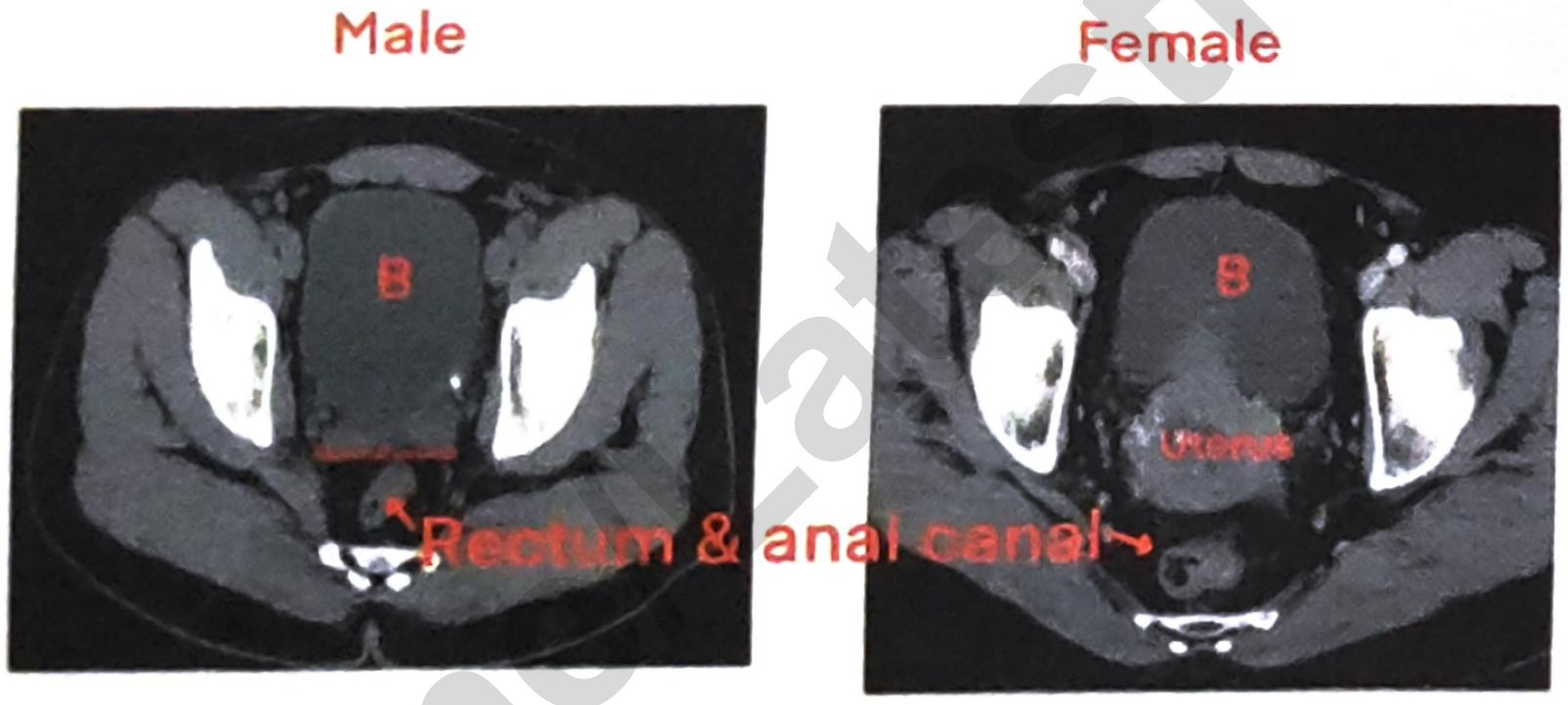

00:59:20

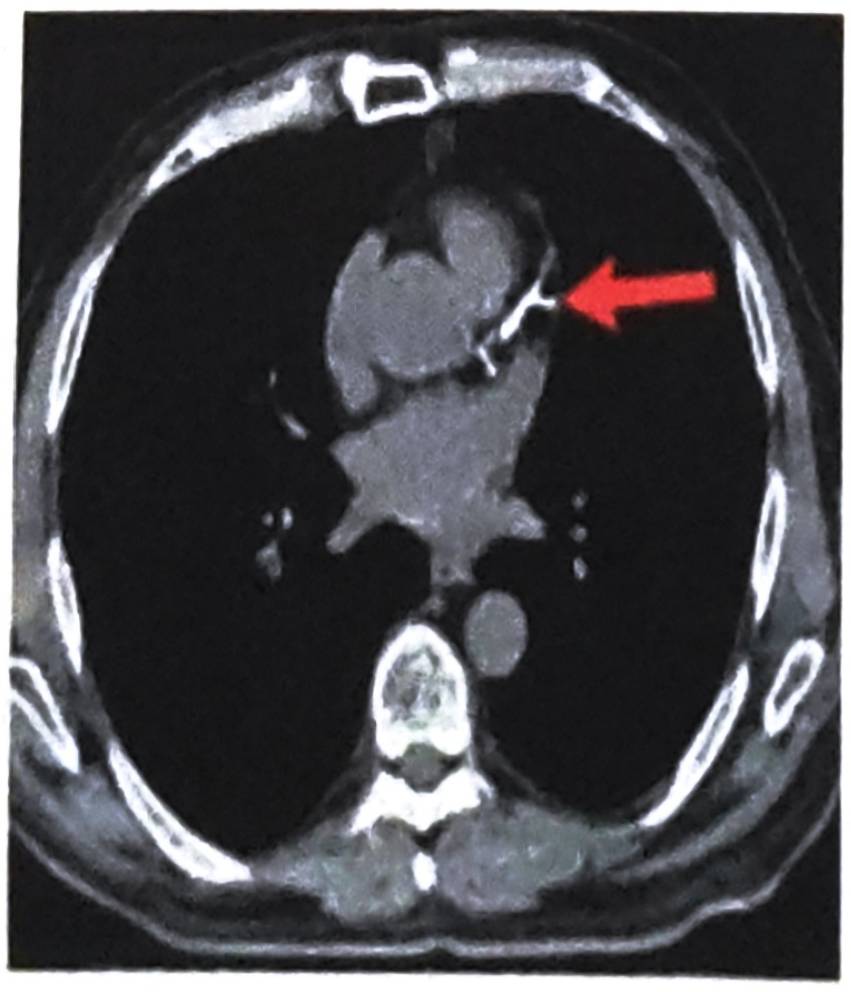

Agatston scoring system:	Coronary Calcification
→ AKA coronary calcium scoring → It uses MDCT → A score of › 400 – high risk for coronary artery disease within 5 years. → Usually cardiac CT done in Mid-Diastole	

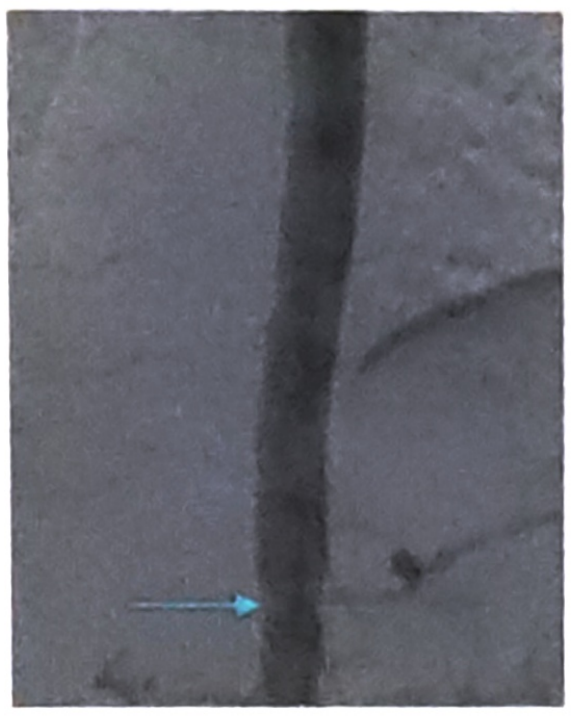	Digital subtraction/ Catheter Angiography → X-ray procedure → Pre-contrast image & Post-contrast Image is digitally subtracted → Gives contrast opacified vessels
	CT Angiography → Bones – white → Vessels – contrast opacified

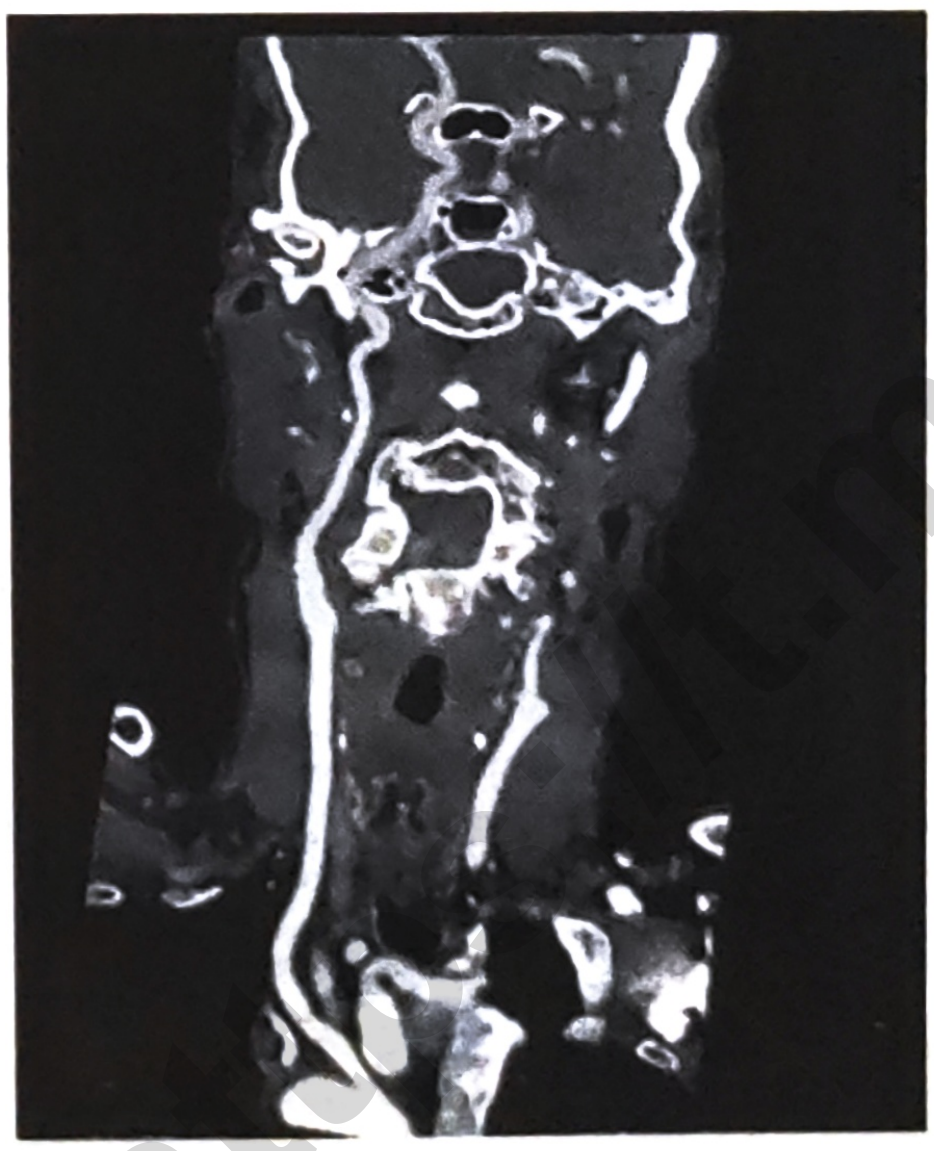 CT Angiography	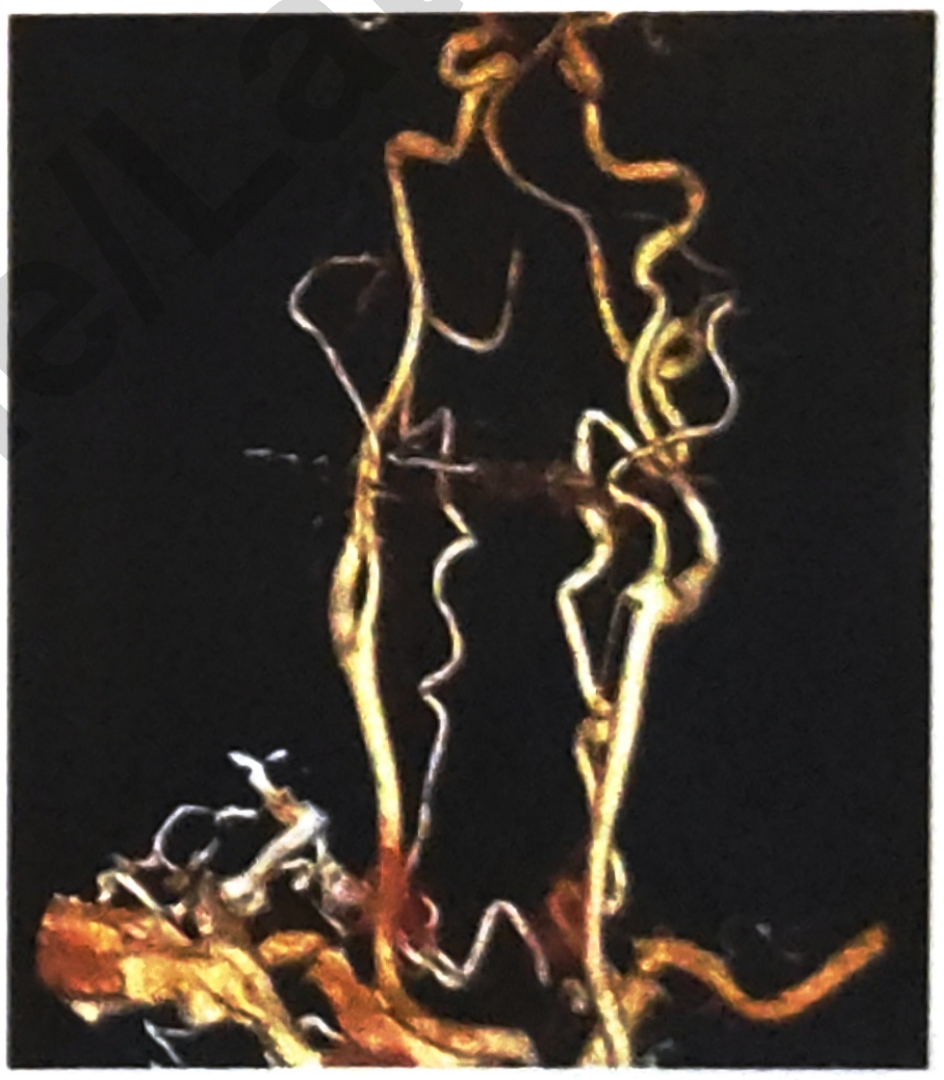 3D - CT

http://t.me/Latestneetpgnotes

PrepLadder

Digital subtraction Angiography	CT Angiography	MR Angiography

Virtual Bronchoscopy	Bronchoscopy
→ 3D CT/ Non invasive	→ Invasive
→ Cannot give biopsy specimens	→ Can take biopsy specimens
→ Post stenotic areas can be evaluated	→ Post stenotic areas are difficult to evaluate

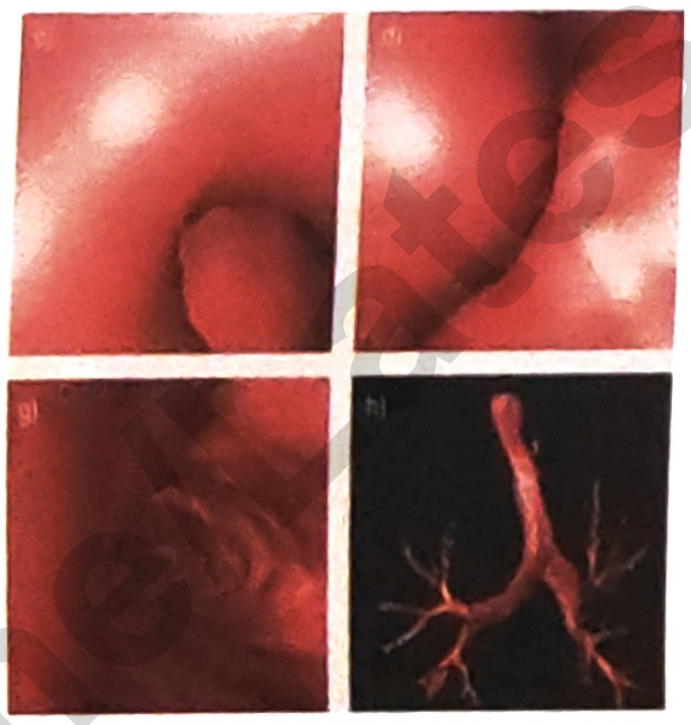

Virtual Bronchoscopy

Note:

This 3D technique is also used to view colon.

	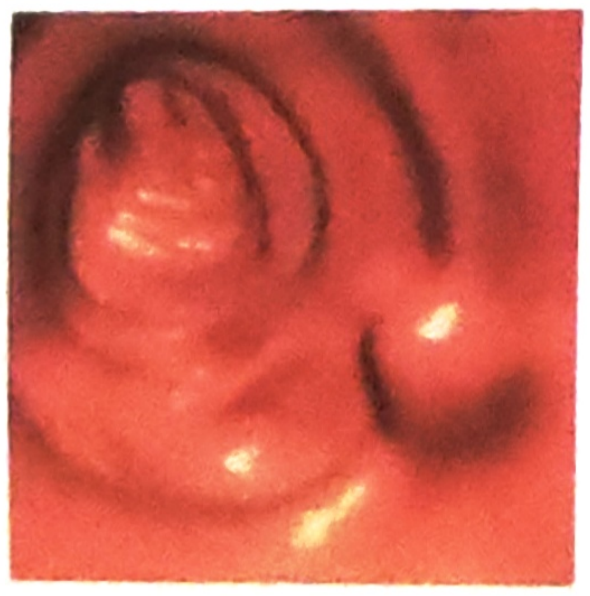	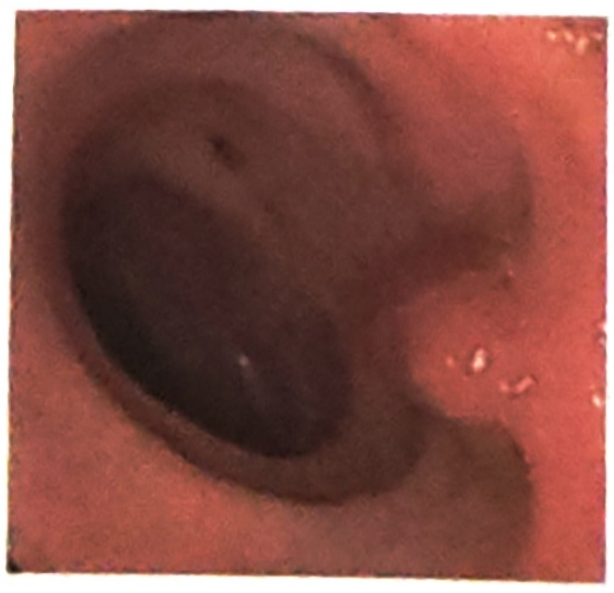
3D-CT	CT-Colonoscopy	Colonoscopy

https://t.me/latestpgnotes

Prep

Chapter 8

ULTRASOUND – Part 1

→ Ultrasound is not an electromagnetic wave but a Sound wave

00:00:20

Advantages	Disadvantage
• Non ionizing	• Operator dependent
• Portable	
• Cheap	
• Easily available	
• Real time imaging	
• Safe in pregnancy	

→ Medical USG – Pioneered by John wild

→ Obstetric USG – Given by Ian Donald

→ Velocity of USG in human tissues – 1540 m/s

→ Diagnostic USG uses sound wave of frequency 2-20 MHZ (i.e. increased frequency = better image resolution)

https://t.me/Latestneetpgnotes

PrepLadder

Principle of ultrasound

00:05:32

→ Works on Pulse-Echo principle

- Probe sends the acoustic pulse and the reflected echo is imaged

Transducer/ Probe

00:06:30

→ USG Uses Piezo electric effect

- Conversion of electrical energy into sound energy and vice versa.

→ Ultrasound probe / transducer – has Piezoelectric crystal which is made up of Lead zirconate titanate

→ Transmitter and receiver of sound.

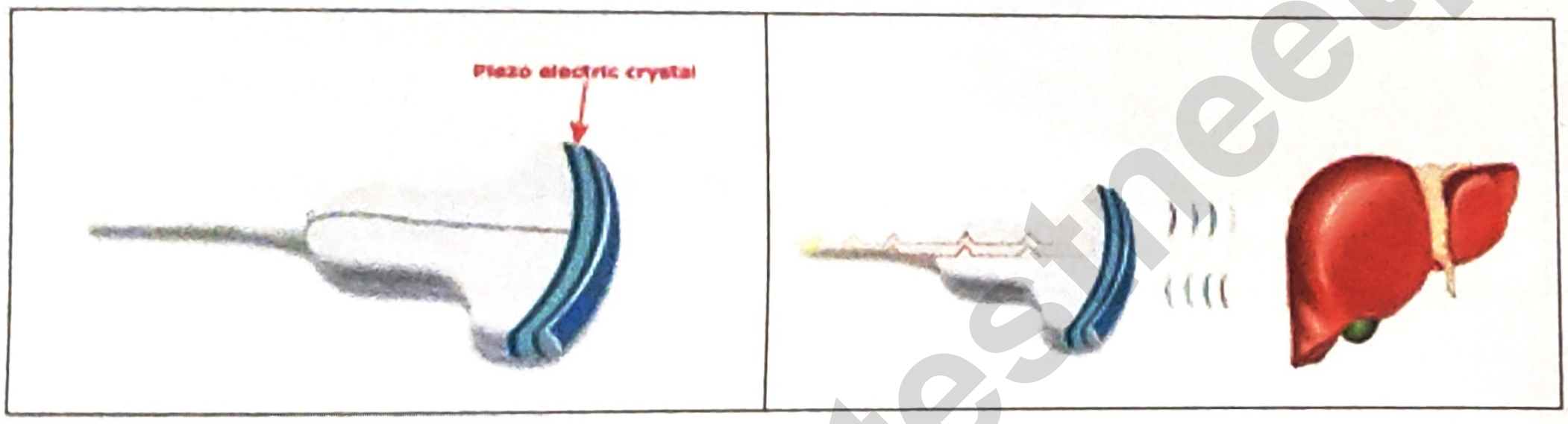

Types of probe /Transducers

→ Linear/Rectilinear probe

→ Curvilinear

→ Phase Array Probe

→ Endocavitary probe

- Endovaginal probe - Pelvic
- Endorectal - prostrate
- Transesophageal - heart

→ Intravascular probe

→ Real time 3D/4D doppler probe

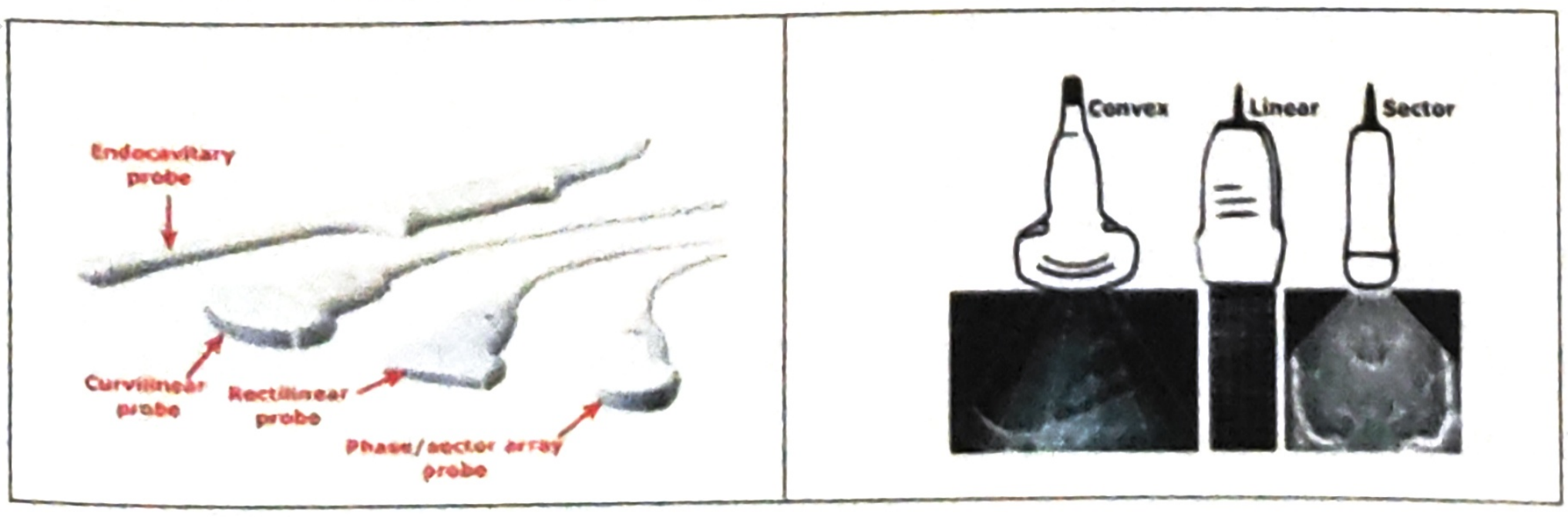

https://t.me/Latestneetpgnotes

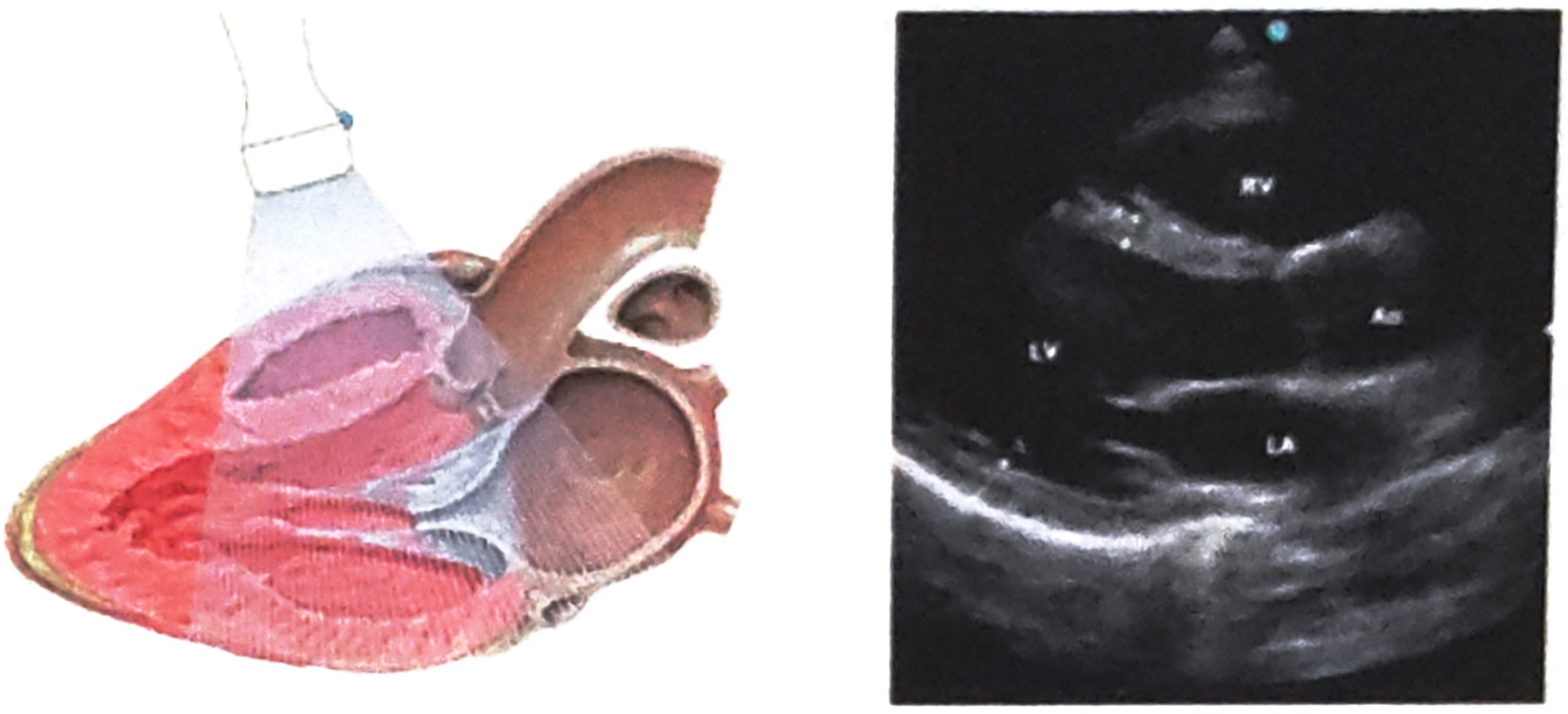

Phase array probes (Echocardiography)

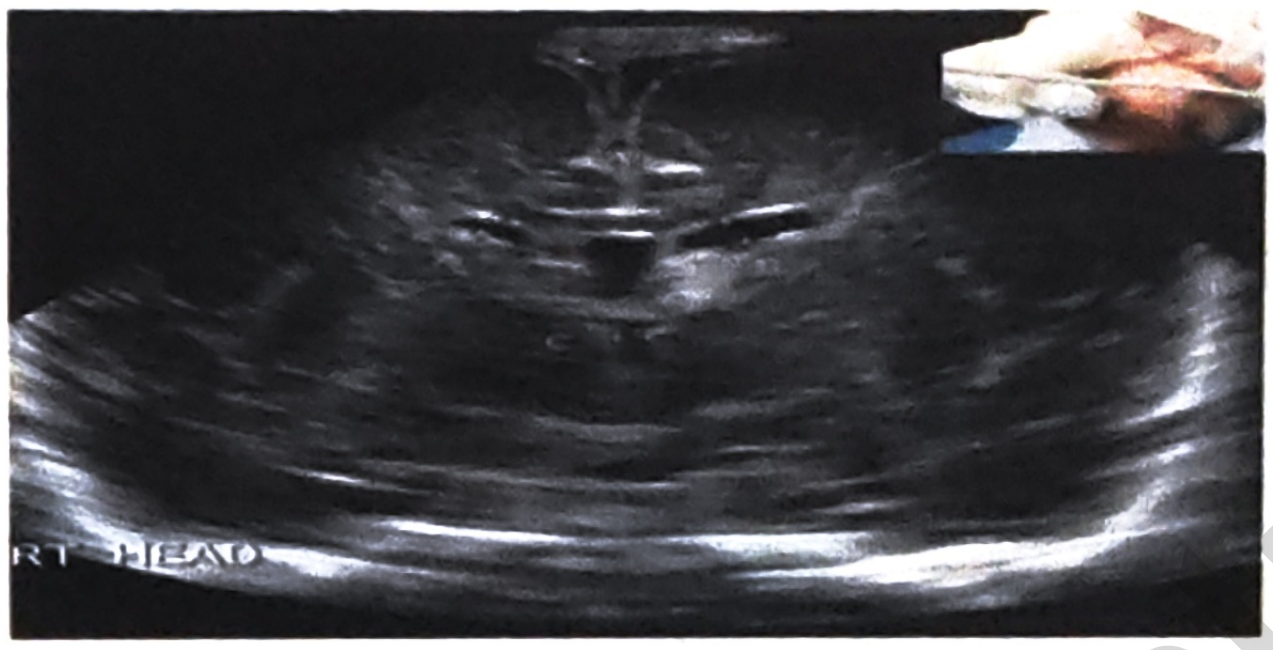

Neurosonogram

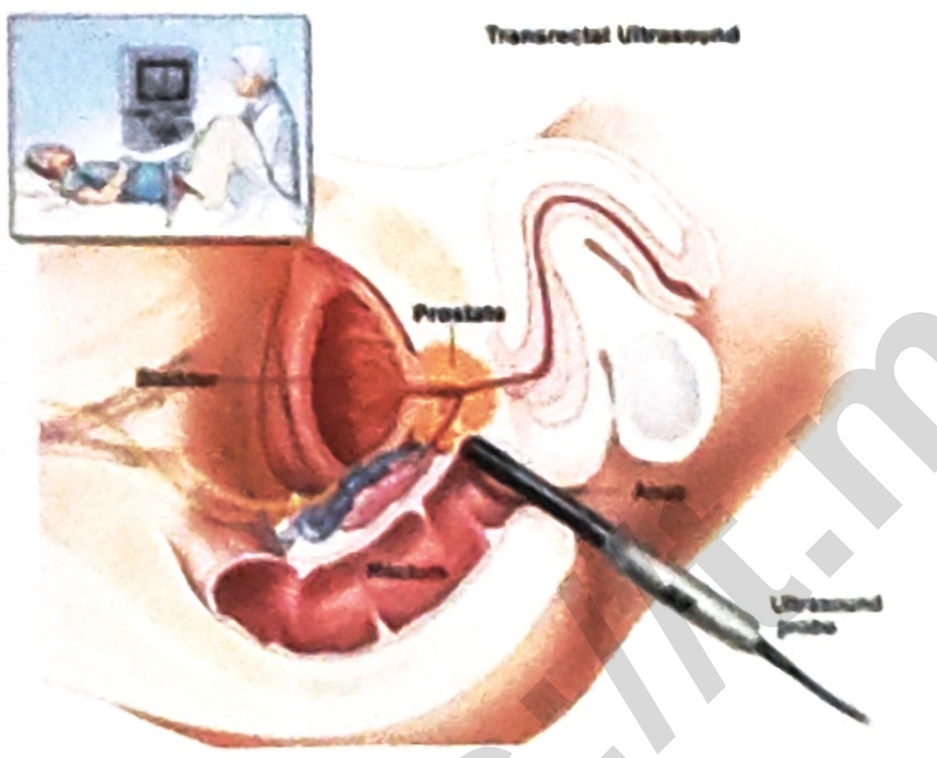

Transrectal Ultrasound

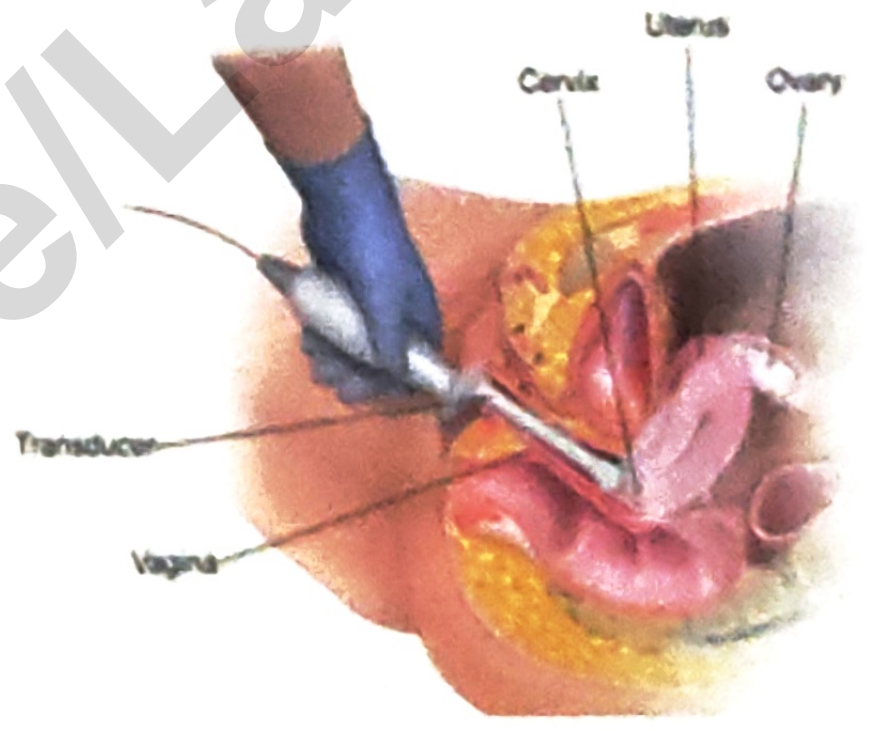

Transvaginal Ultrasound

Note:

TVS (Transvaginal sonography)

- IOC for Ectopic pregnancy
- Biudder must be empty before doing TVS

https://t.me/Latestneetpgnotes

PrepLadder

For more free ebooks and notes, visit

https://t.me/Latestneetpgnotes

Or click this page to join

Note:

Transesophageal Echocardiography

→ Used to view Chamber of heart

→ Aortic Dissection in unstable patient

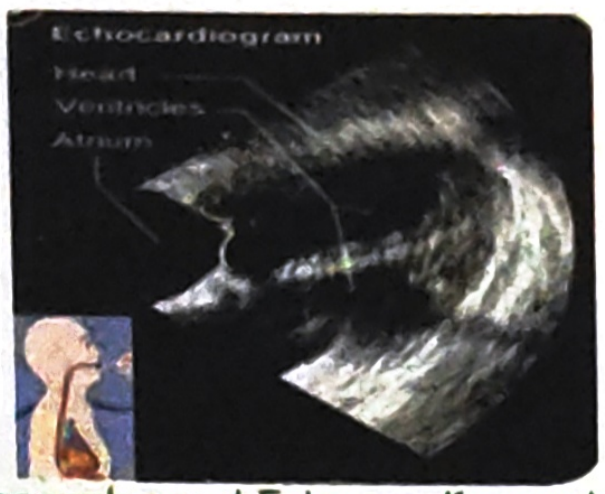

Transesophageal Echocardiography

Different types of Probes / transducers

00:16:09

Curvilinear probe	Linear probe	Endocavitary probe
• 3-5 MHz (Low frequency) • Greater wavelength • Greater penetration • Poor resolution • Used for imaging deep Structures e.g. kidney, ovary, fetal parts etc.	• 10-12 MHz (high. Frequency) • Low wavelength • Poor penetration • Good resolution • Used for superficial structures e.g. thyroid, breast, scrotum etc.	• 7- 10 MHz (Good frequency) • Good resolution • No problem of penetration • TVS , TRUS , TEE

→ Endoscopic Ultrasound (EUS)

- Uses frequency of 20 MHZ
- Very good resolution
- Divides gut wall into 5 layers
  - Mucosa → Hyperechoic
  - Muscularis mucosa → Hypoechoic
  - Submucosa → Hyperechoic
  - Muscularis propria → Hypoechoic
  - Serosa → Hyperechoic

- EUS is the IOC for local invasion or T staging of early esophageal cancer

  (IOC for Advanced esophageal Carcinoma - CECT)

https://t.me/Latestpgnotes

Prep

Endoscopic Ultrasound

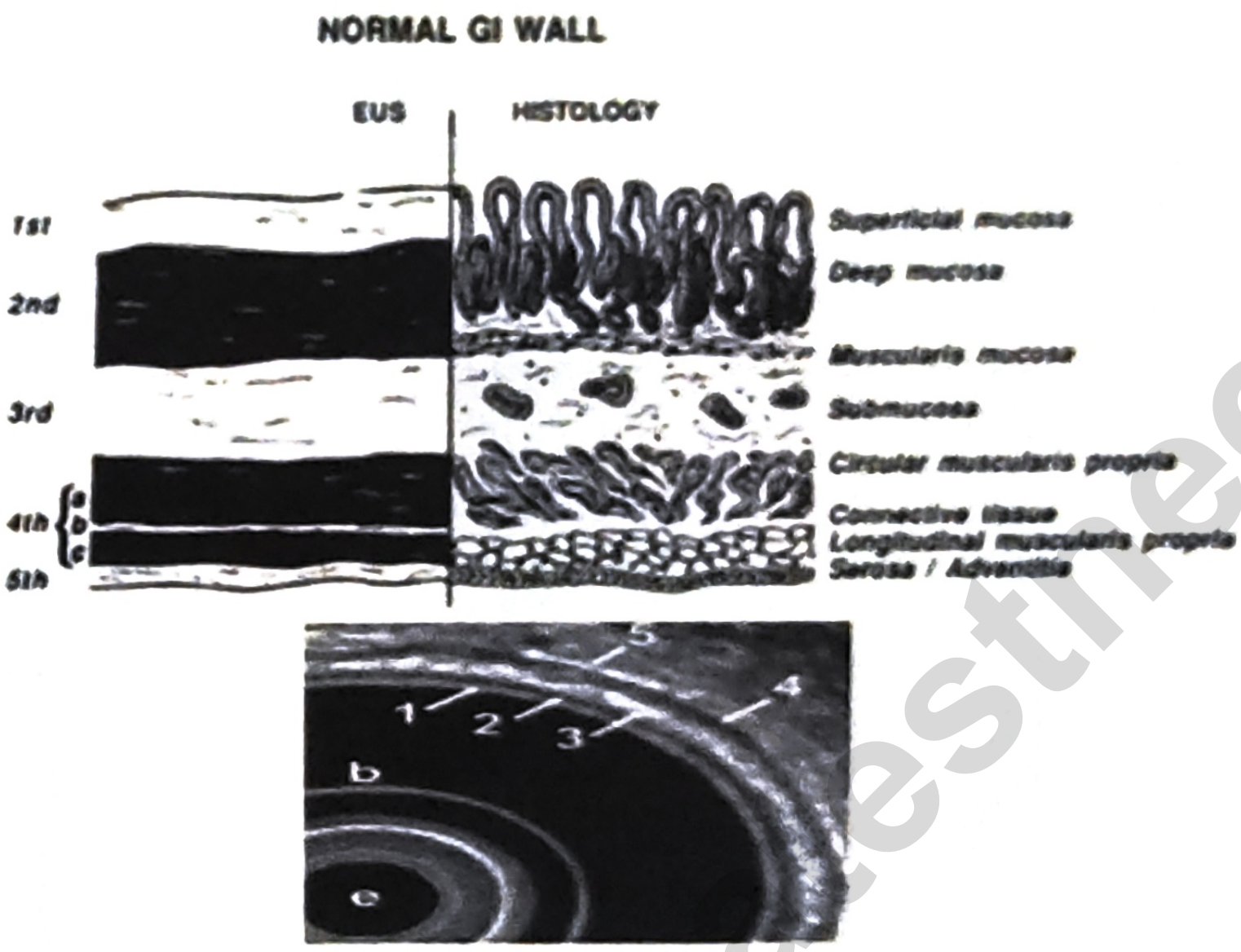

EUS Images of Stomach layers

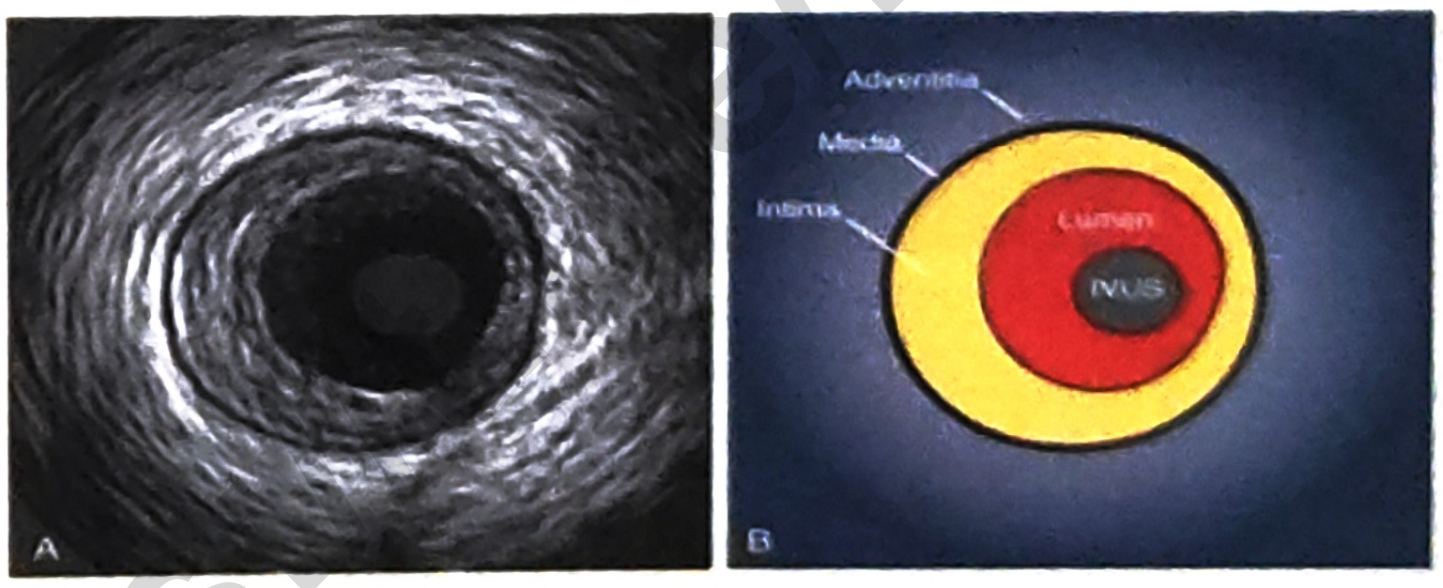

Intravascular Ultrasound

Indicators on Ultrasound

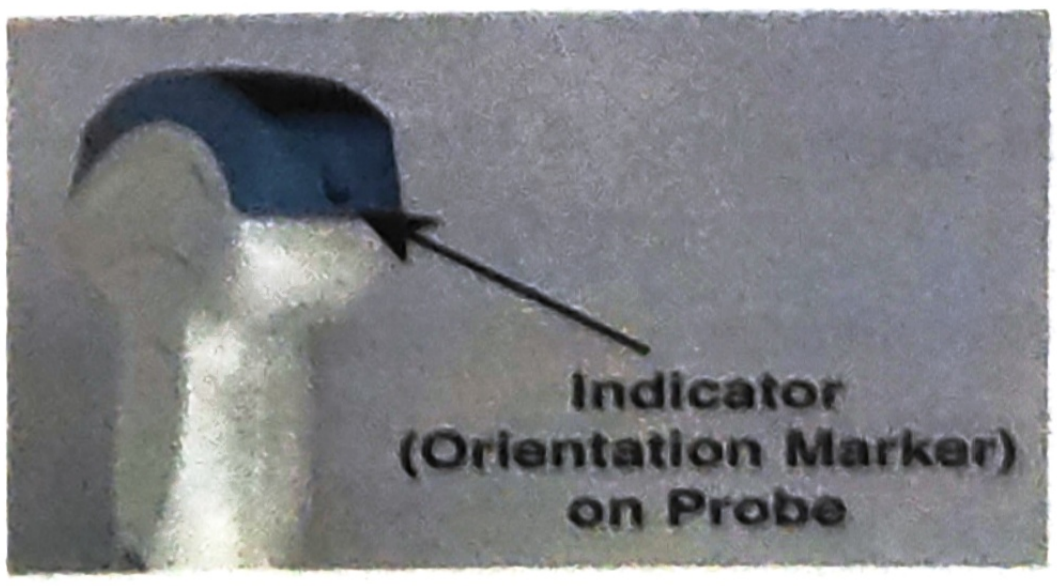

PrepLadder

LONGITUDINAL	
	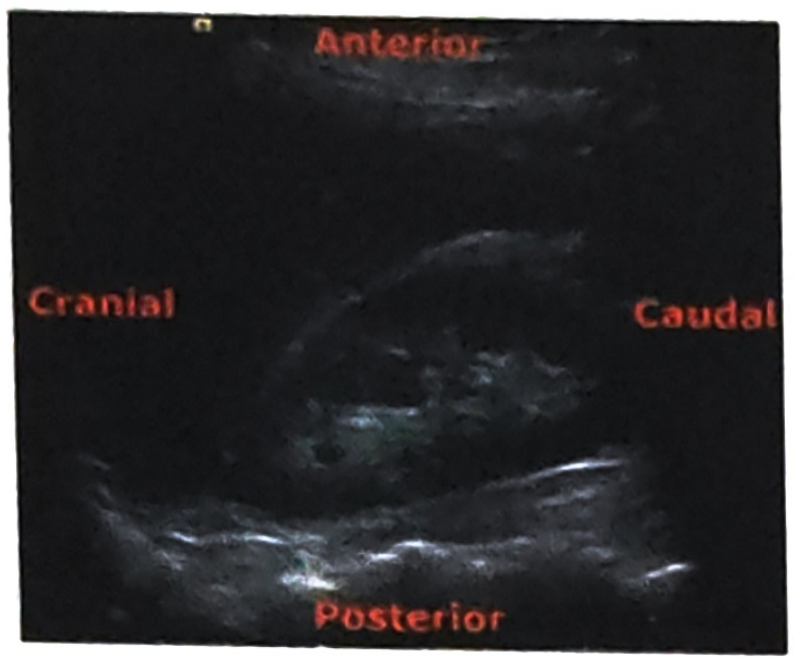
TRANSVERSE	

Note:

→Cine Loop – Motion ultrasound images

→Cardiac Myxoma

– M.C primary cardiac tumor

– M.C location – Left Atrium

→M.C primary cardiac tumor in children – Rhabdomyoma

Modes of USG

1) A mode (Amplitude mode)

→Sound waves hit different parts of eyeball and it produces different amplitude

→By measuring the distance between Amplitudes – the distance between individual structures & the entire axial length of the eyeball can be measured

https://t.me/LatestPgnotes

PrepLadder

→ Used for

- Ophthalmology
- Orbital Biometry
- Midline displacement of the brain in Trauma & brain tumors

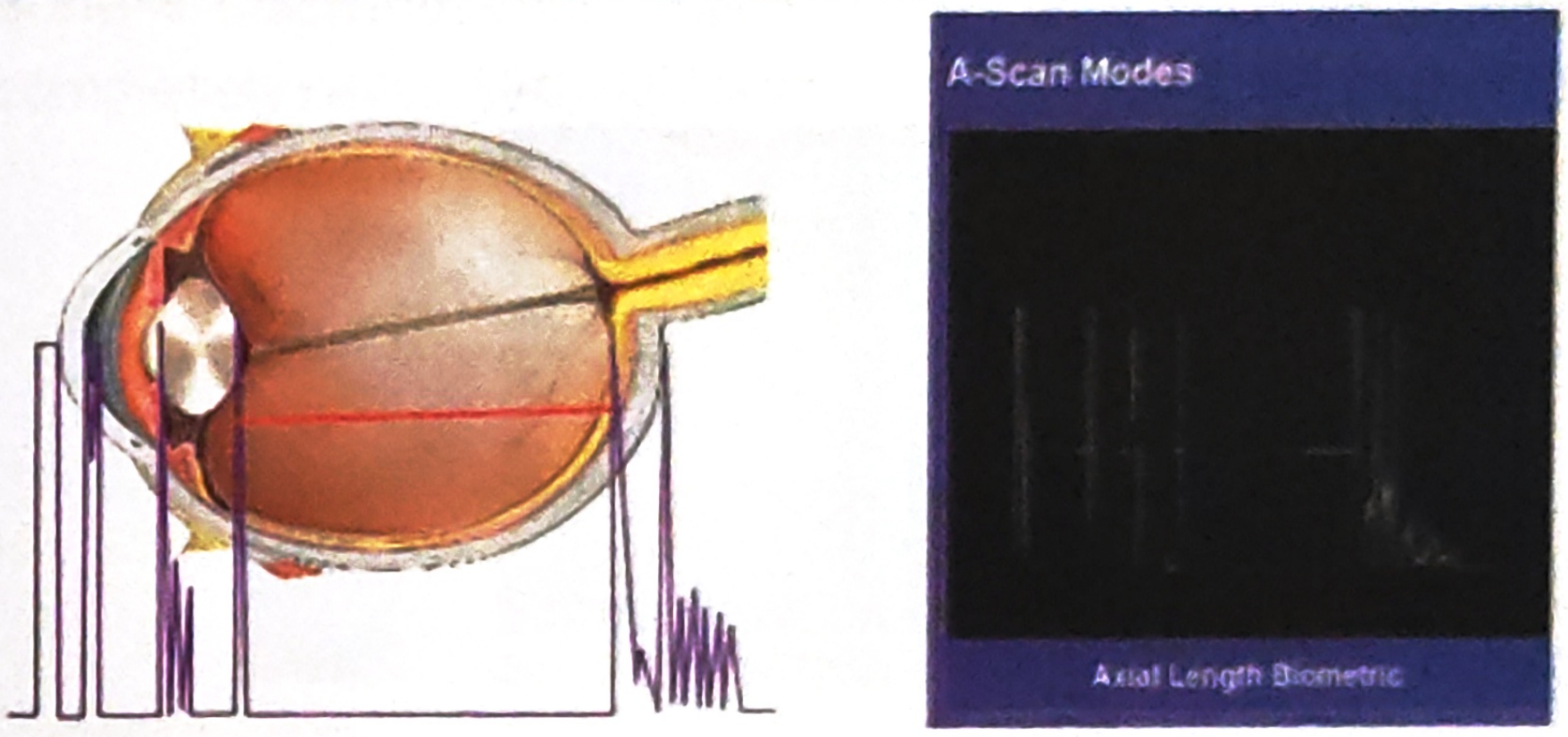

Axial length of the eyeball

2) B mode (Brightness mode)

→ Used in all routine application



Retinal detachment – B Mode scan

3) M mode (Motion mode)

→ Gives excellent resolution of motion patterns displaying time on X axis

→ Uses

- Evaluation of Cardiac valve motion
- Echocardiography
- Lung movements / Pneumothorax

https://t.me/bestneetpgnotes

PrepLadder

Normal Lung sliding

→ Shimmering of the ling sliding looks like sand in the beach known as Sea shore sign.

Absent Lung sliding

→ No movements of lungs noted leading to the formation of Barcode/ Stratosphere sign

→ Suggestive of Pneumothorax

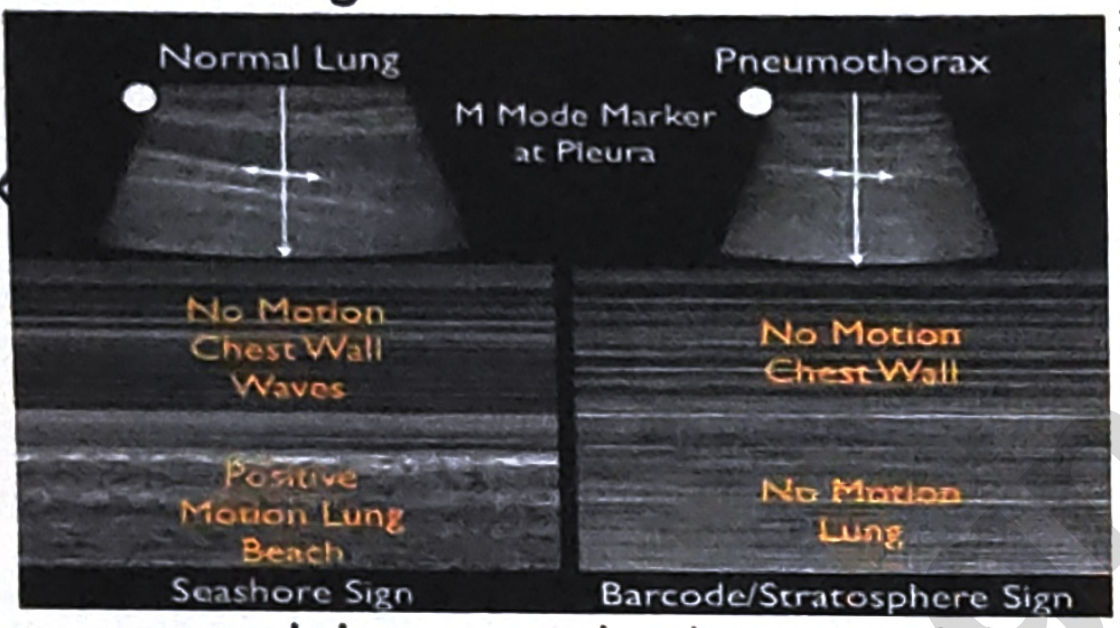

Note:

Lung point

→ Transition point between normal lung and abnormal lung sliding

→ Pathognomonic finding of pneumothorax

USG appearances 00:35:40

Anechoic	Hypoechoic	Isoechoic	Hyperechoic
Cyst with clear fluid • Simple Cysts • Gall bladder • Urinary bladder	Cyst with Turbid fluid • Muscle • Abscess • Thyroid malignancy	• Resembles surrounding Parenchyma	• Hemangioma • Lipoma • Bone • Ca+2 • Air

https://t.me/latestneetpgnotes

Posterior Acoustic shadowing

→ Seen with

- Air – Gives dirty shadow (Most waves are reflected allowing some waves to pass through)
- Bone & Calcifications - Gives dark clean shadow (Waves are completely reflected)

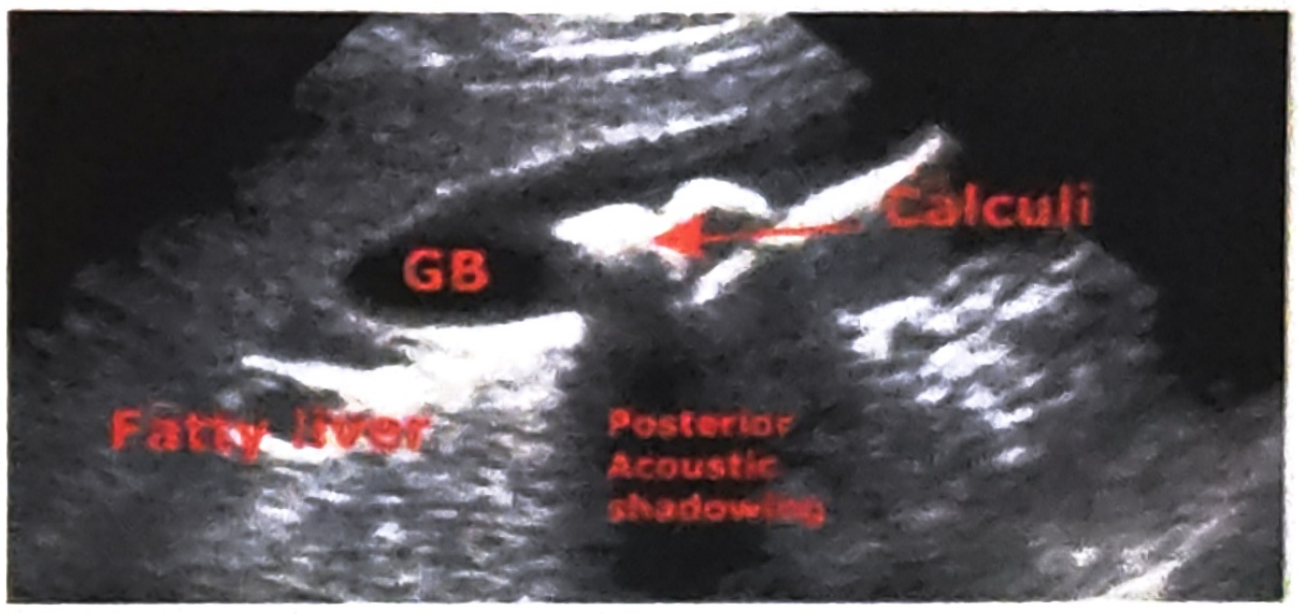

Cholelithiasis

Breast cyst

→ Posterior acoustic enhancements are seen with Cystic lesions

→ Allow the waves to easily pass through

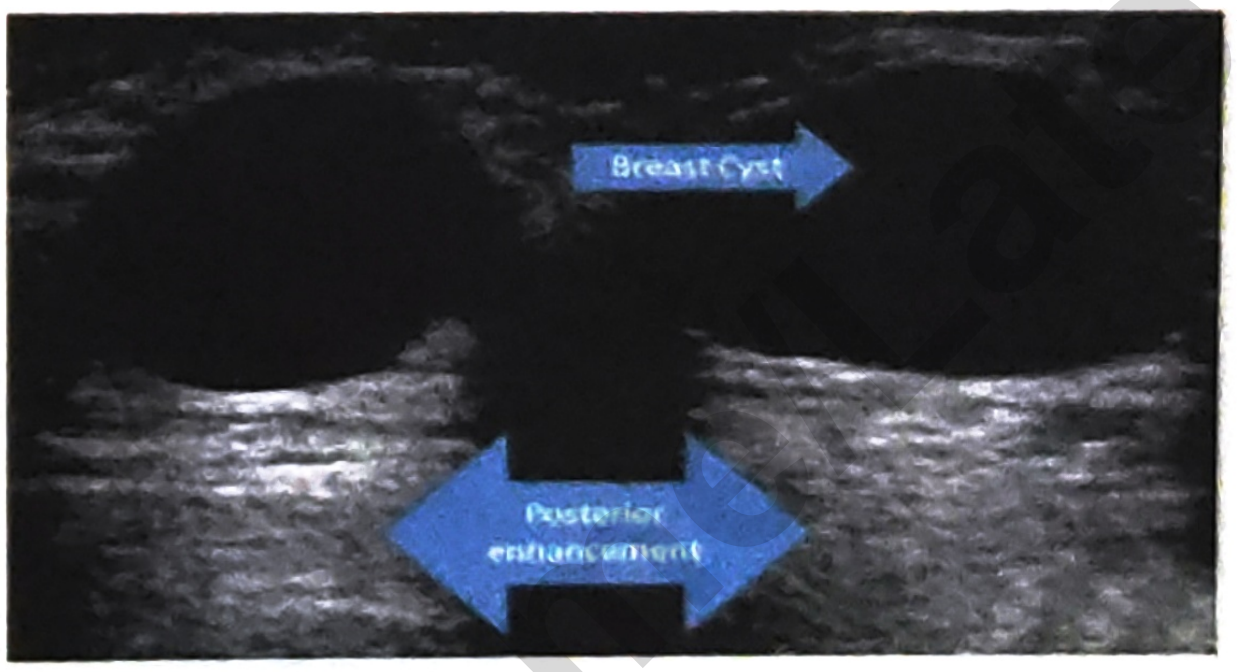

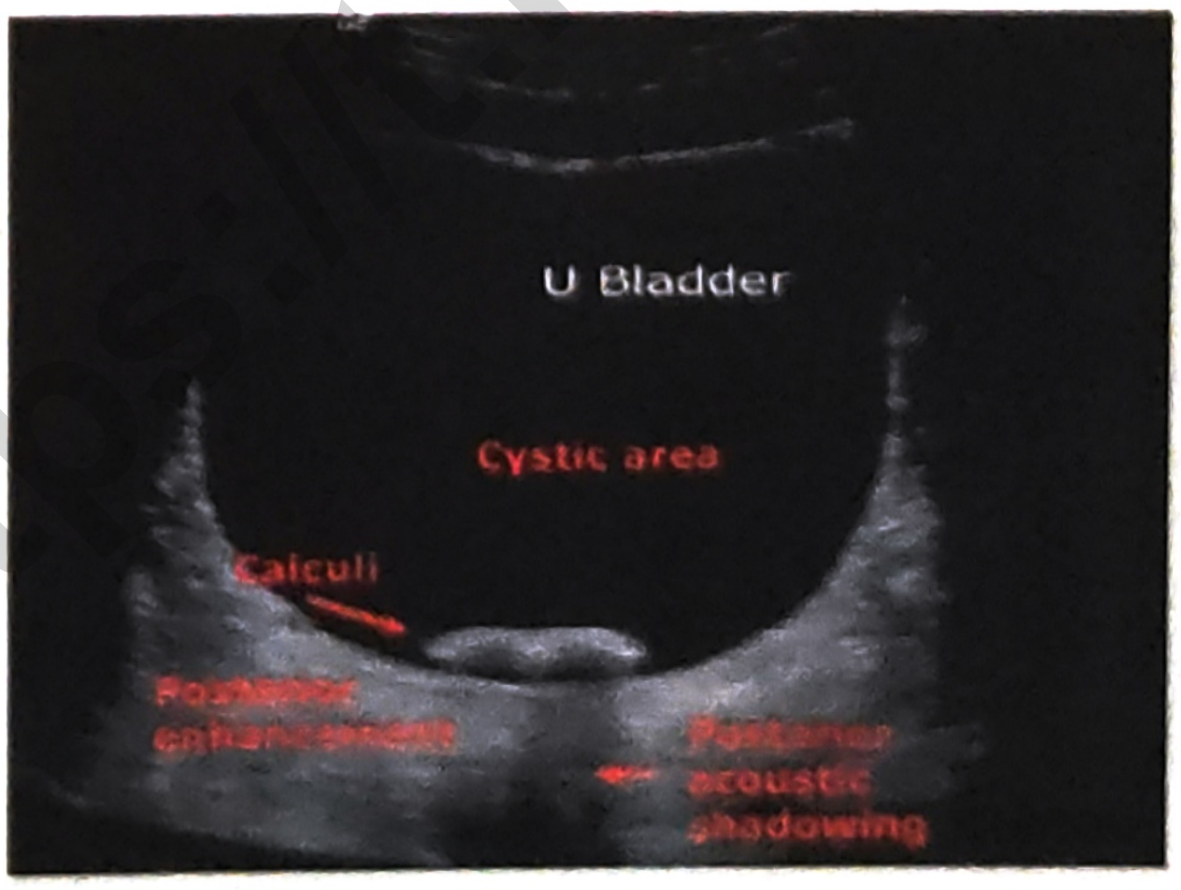

Vesical calculi

https://t.me/Latestneetpgnotes

PrepLadder

Emphysematous Pyelonephritis

→Air is Hyperechoic on USG

Emphysematous Pyelonephritis

Thyroid malignancy in Ultrasound

→Irregular

→Hypoechoic

→Taller than wide

→Punctate microcalcification



Thyroid gland

Ultrasound Scrotum

00:46:40

Normal USG - Scrotum

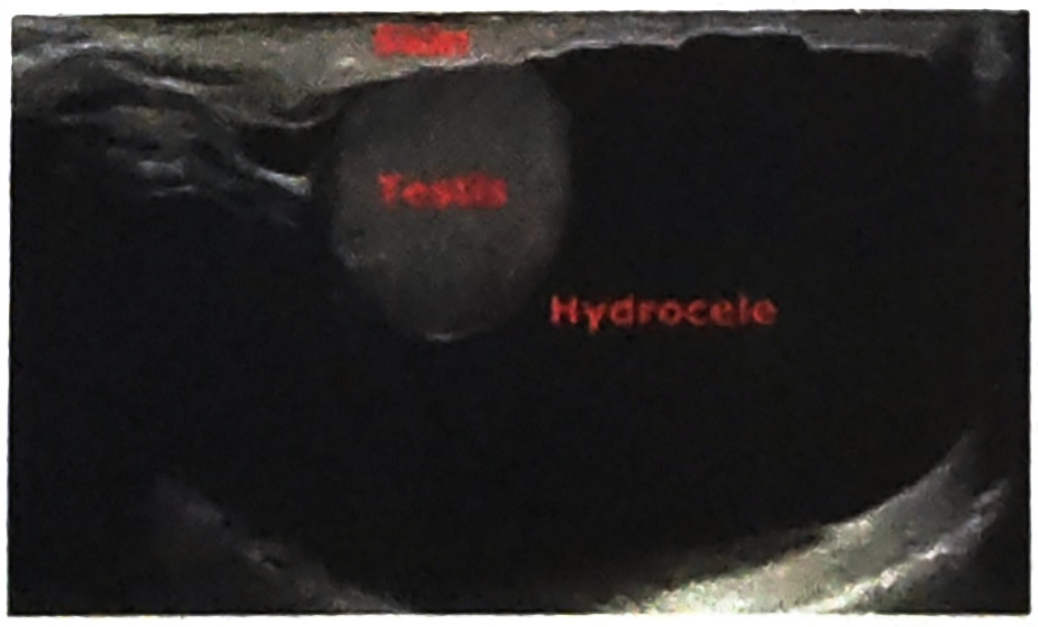

Hydrocele

Note:

→Hydrocele – Anechoic fluid collection

→Hernia – Peristaltic movement of bowel loops are seen

https://t.me/neetpgnotes

Acute Appendicitis

In Ultrasound

- →Blind ending, Tubular, aperistaltic, non-compressible luminal diameter > 7mm
- →Target Sign – Hyperechoic mucosa surrounded by edematous wall of bowel.

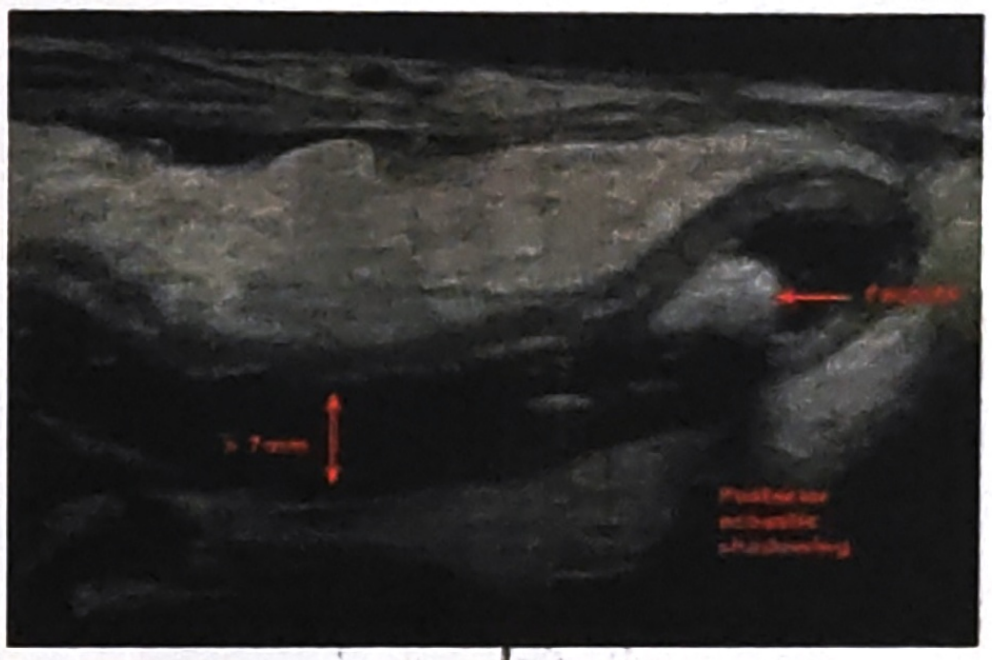

Sagittal view

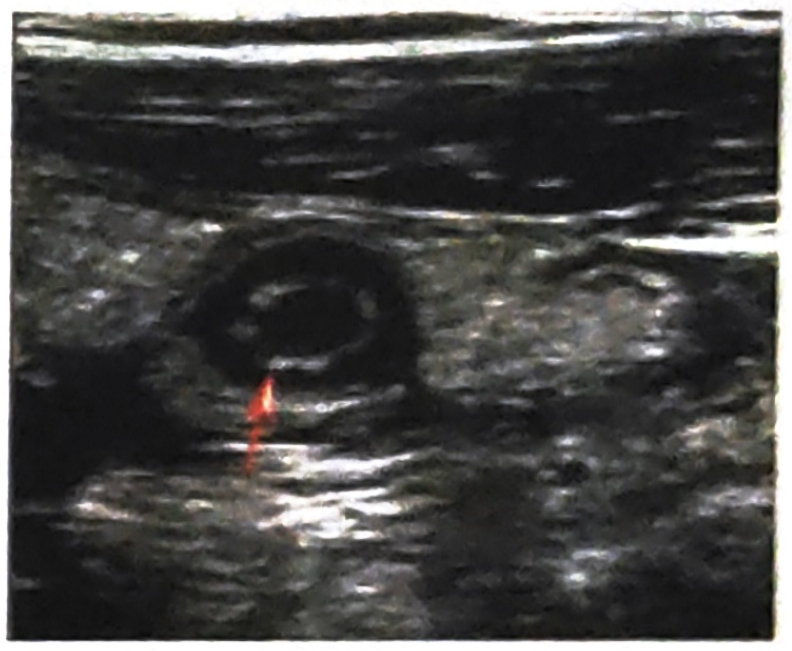

Transverse view – Target sign

Note:

Acute Appendicitis

- →IOC in children – Ultrasound
- →IOC in Adults – CECT

In CECT

- →More sensitive than USG
- →Luminal diameter > 6mm
- →Thickened inflamed soft tissue at base of appendix separating appendix from the contrast filled cecum – Cecal bar sign
- →Contrast entering the appendix tapers down and does not fill the entire length of the lumen due to mucosal edema - Arrow head sign

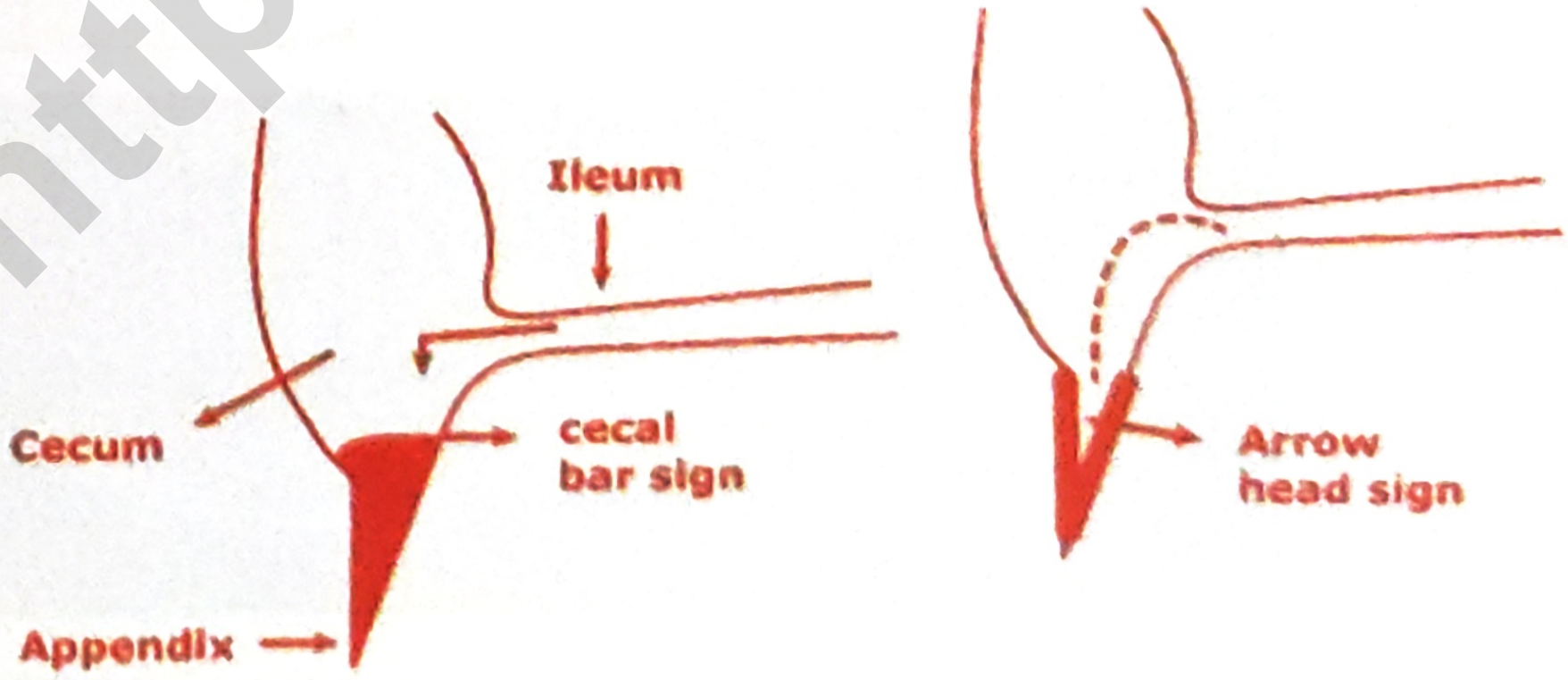

https://t.me/Latestneetpgnotes

PrepLadder

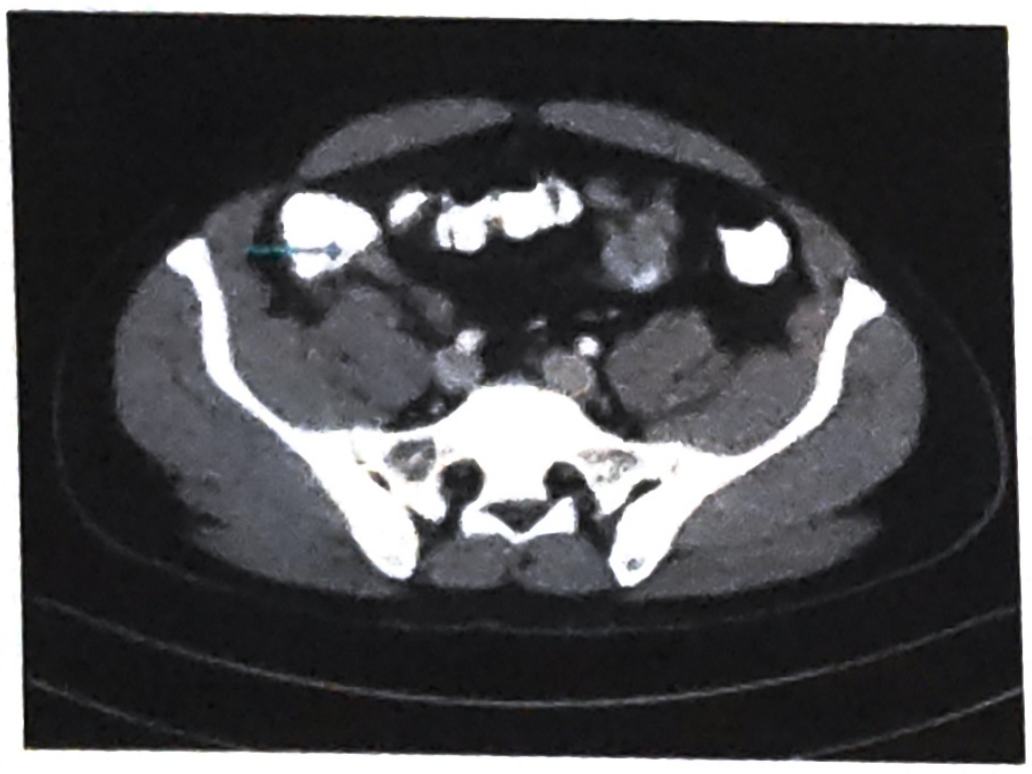

Cecal Bar Sign

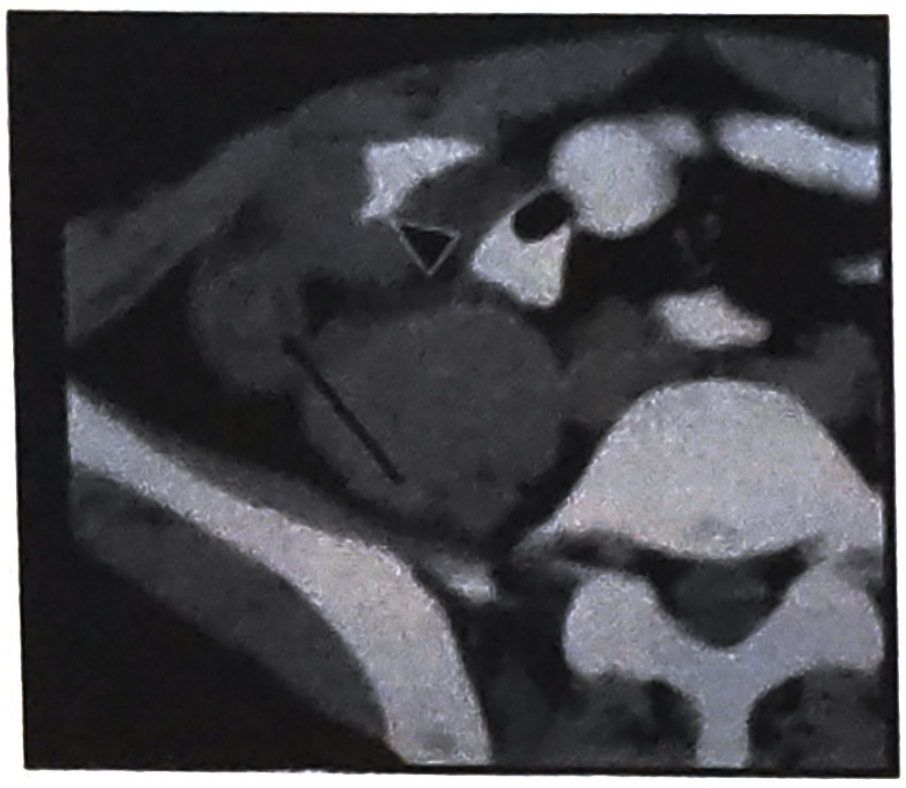

Arrow Head Sign

https://t.me/Latestneetpgnotes

Chapter 9

ULTRASOUND – Part 2

Various pathologies on Ultrasound 00:00:16

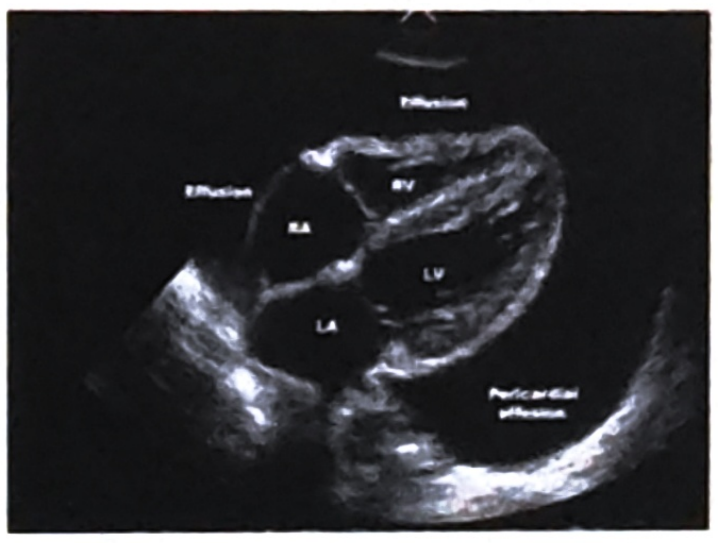

Pericardial effusion

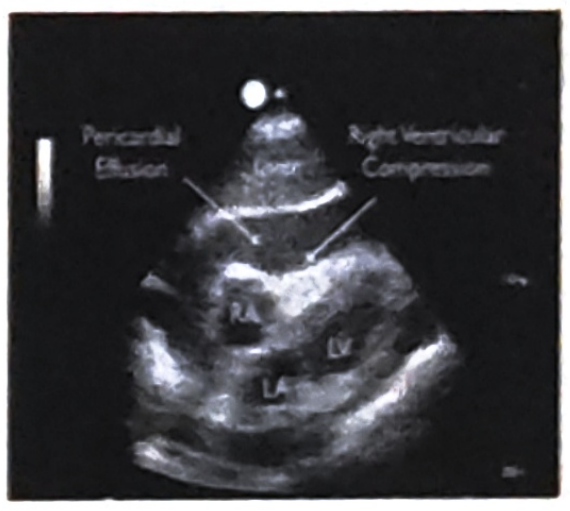

Cardiac tamponade

Note:

→Pericardial effusion: Anechoic fluid collection around the heart

→Cardiac Tamponade : Anechoic fluid collection + Collapse of the chambers of heart

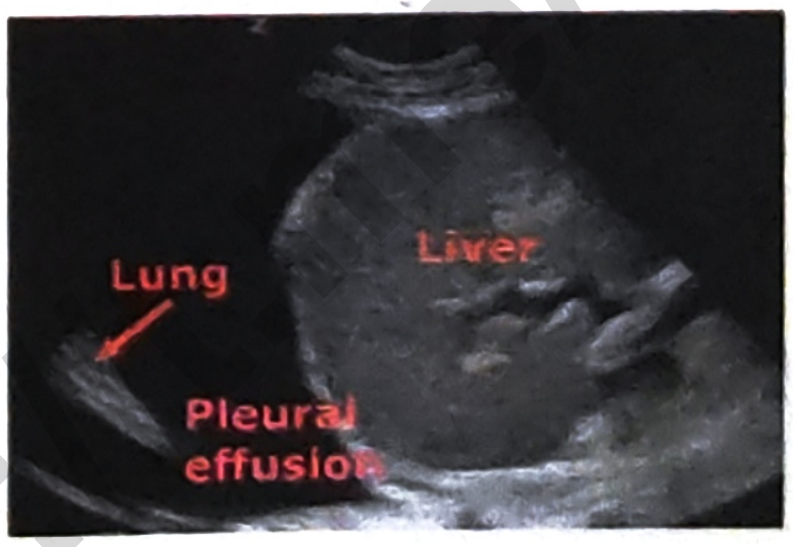

Pleural effusion

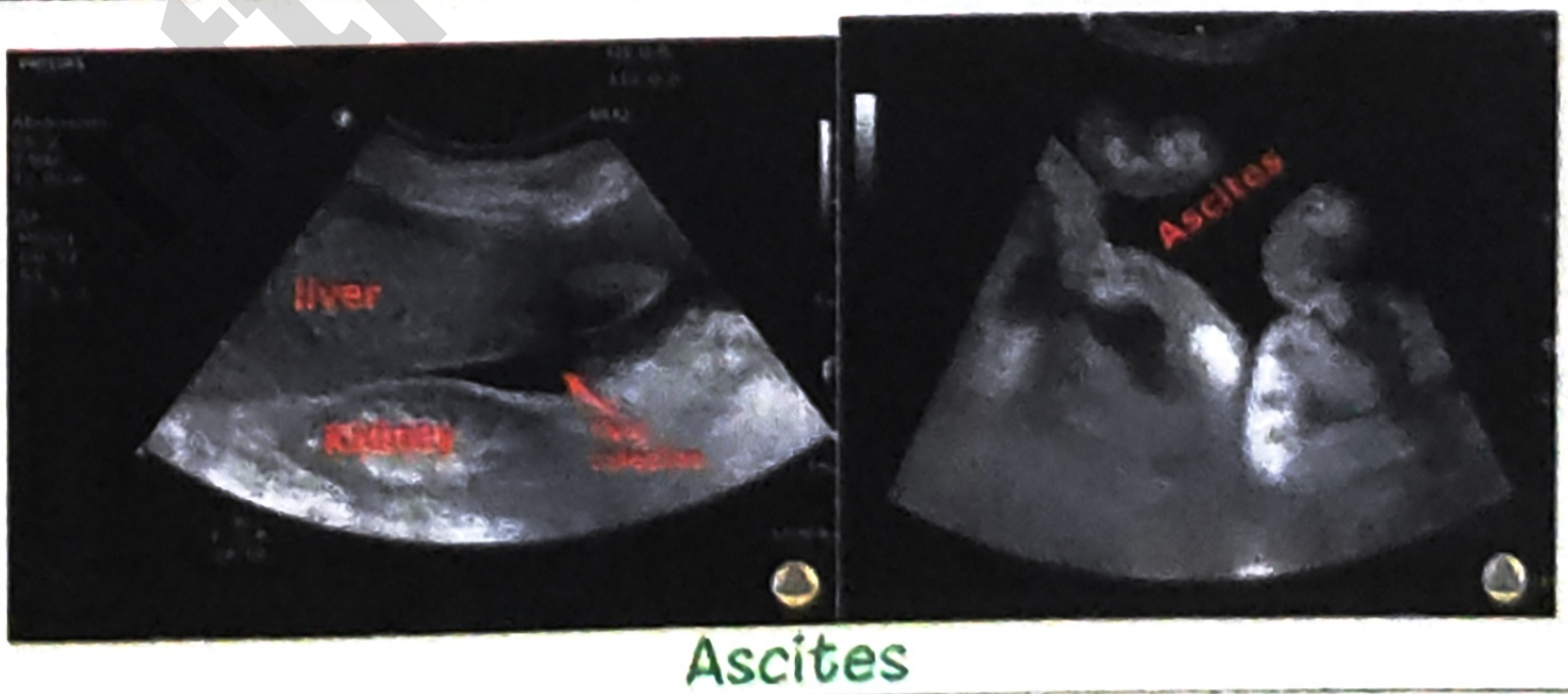

Ascites

https://t.me/Latestneetpgnotes

PrepLadder

Note:

→ Most sensitive View for fluid collection after Trauma

- Right Lumbar View

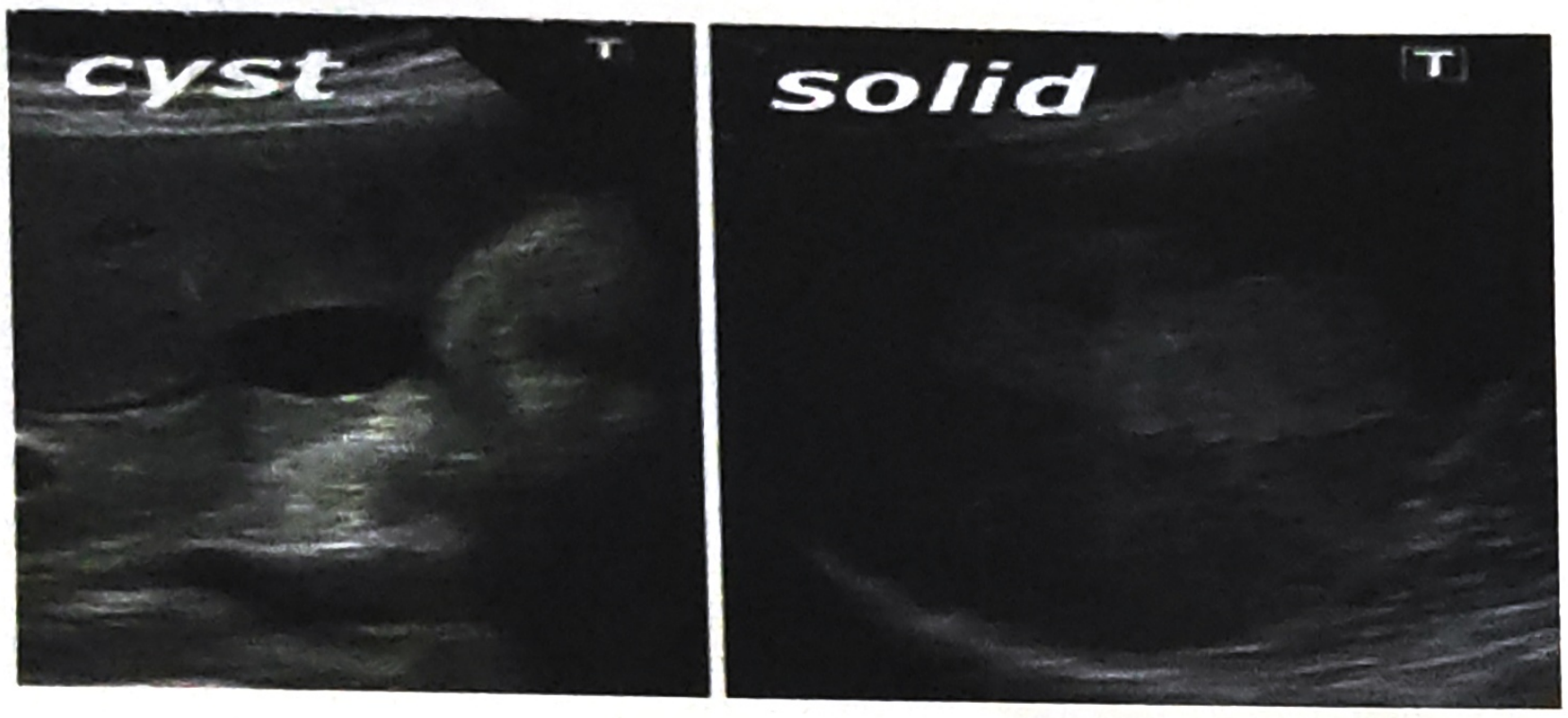

Cyst Vs Solid

Note:

Ultrasound

→ IOC for

- Minimal pleural effusions
- Ascites
- Hydrocele
- Hydronephrosis
- Breast abscess
- Differentiate solid Vs cyst lesions

Cholelithiasis 00:04:48

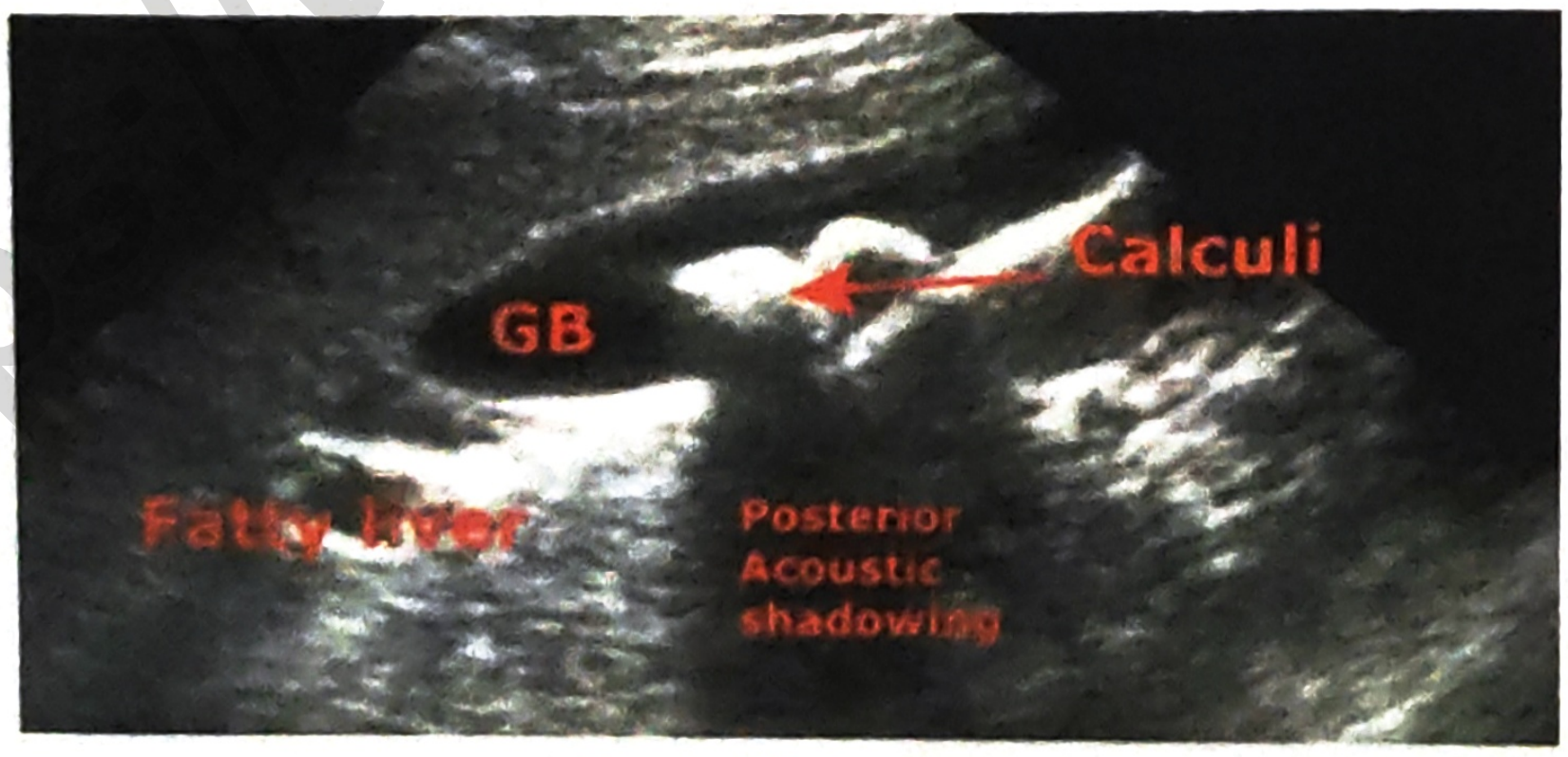

Cholelithiasis

→ Fat & Calculi - Hyperechoic on USG

http://t.me/Latestneetpgnotes

Cholecystitis

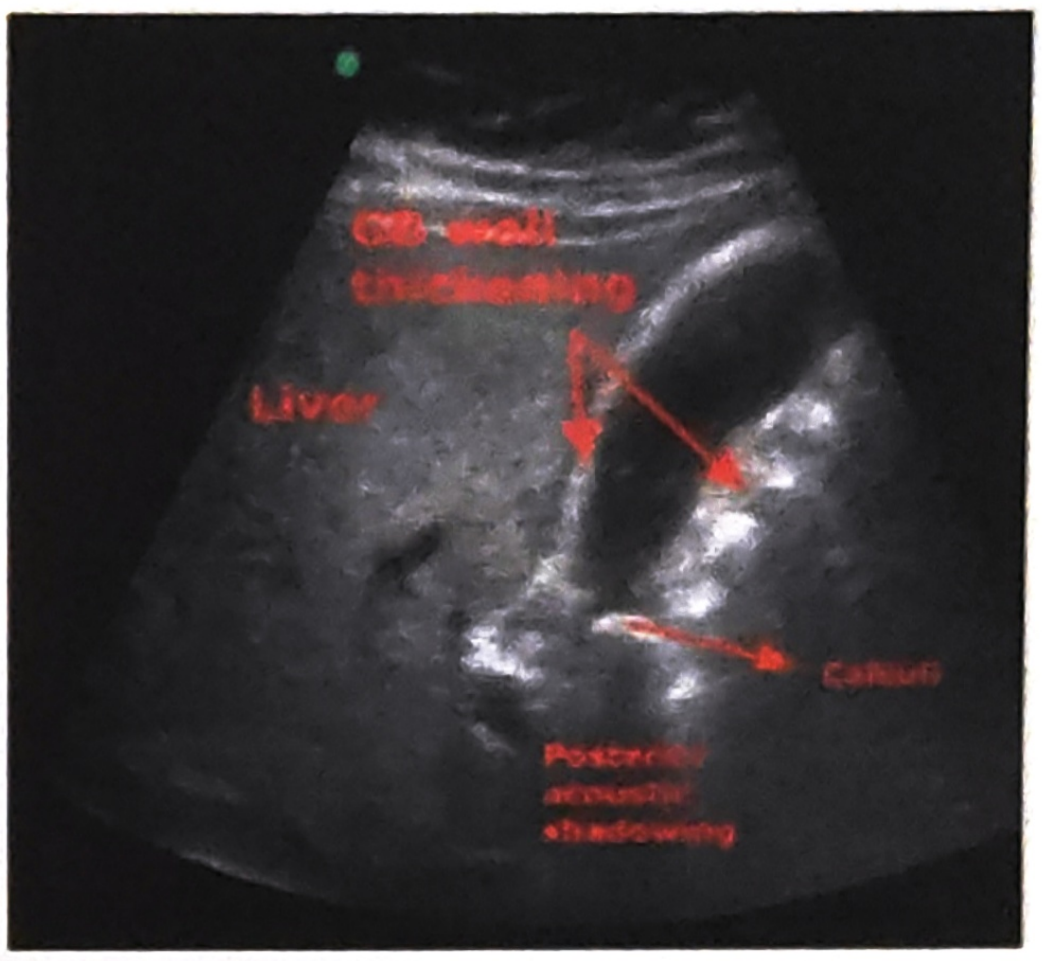

Cholecystitis

Note:

→ IOC for Acute Cholecystitis – Ultrasound

Chronic calcific cholecystitis

→ Wall- echo-shadow sign (WES sign)

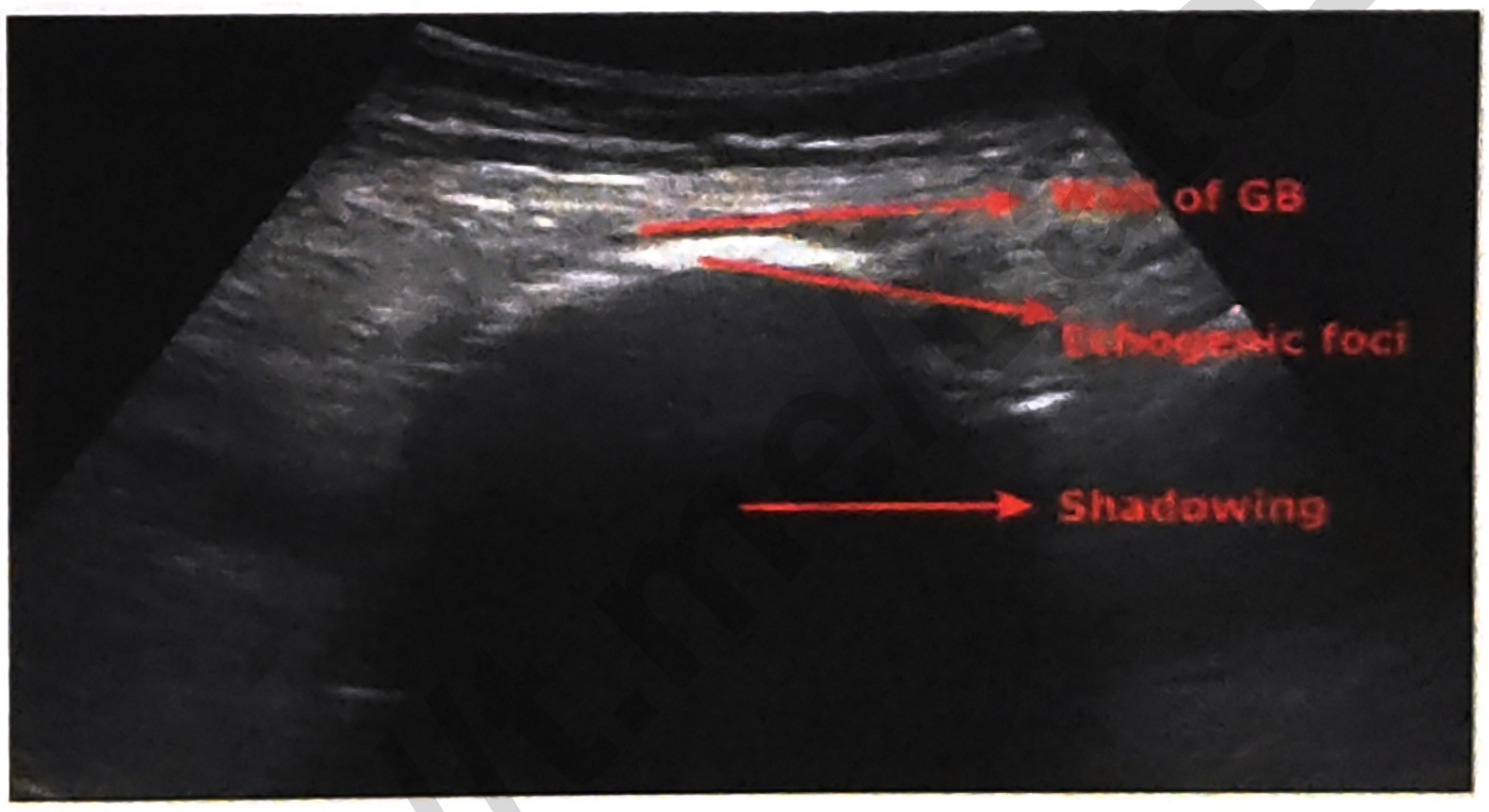

Wall- echo-shadow sign (WES sign)

Acute Cholecystitis	Chronic Cholecystitis
→ Luminal Distension	→ Fibrosis & Shrunken Gall Bladder
→ Both anterior & posterior wall can be seen	→ Posterior wall is obscured by Acoustic shadowing

https://t.me/...stneetpgnotes

PrepLadder

GB adenomyomatosis

→ Comet tail artifacts

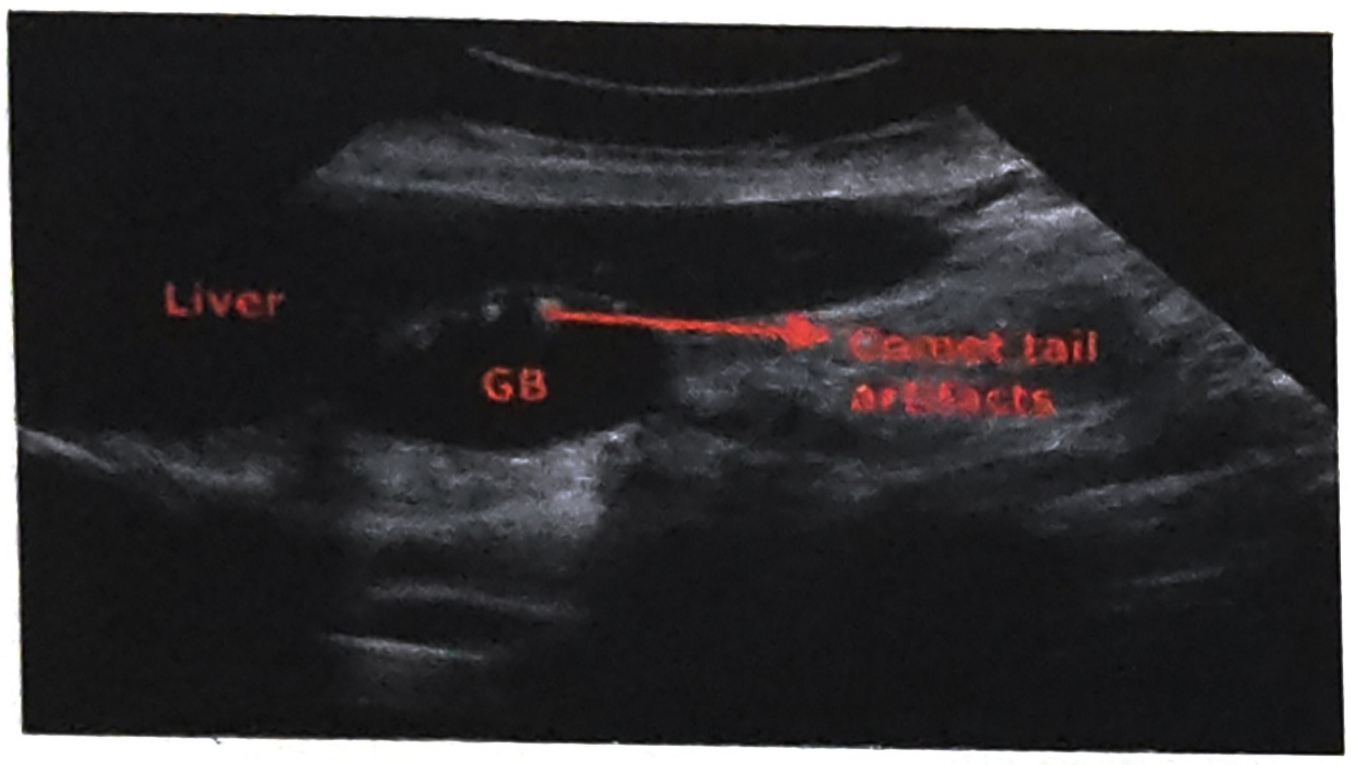

GB adenomyomatosis

FAST (Focused Assessment with Sonography for Trauma) 00:10:30

Abdominal Trauma
↓
FAST/ E-FAST (INITIAL INVESTIGATION)
↓
- (-) Hemoperitoneum
- (+) Hemoperitoneum
  ↓
  Check for Vitals
  ↓
  - Stable → CECT (IOC)
  - Unstable → Emergency Laparotomy

FAST Views

1) Subxiphoid/ Subcostal View → Pericardial collection
2) Right Lumbar view → Perihepatic collection/ Morrison pouch
3) Left Lumbar view → Perisplenic collection
4) Pelvic/ Suprapubic view → Pelvic hematoma

https://t.me/Latestneetpgnotes

Normal Rt Lumbar View

Fluid Collection in Rt Lumbar View

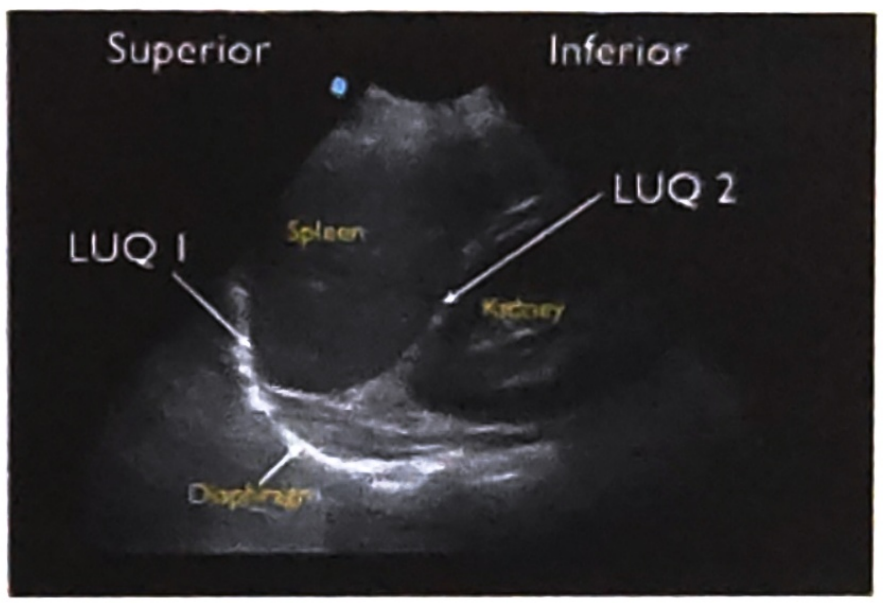

Normal Lt Lumbar View

Fluid Collection in Lt Lumbar View

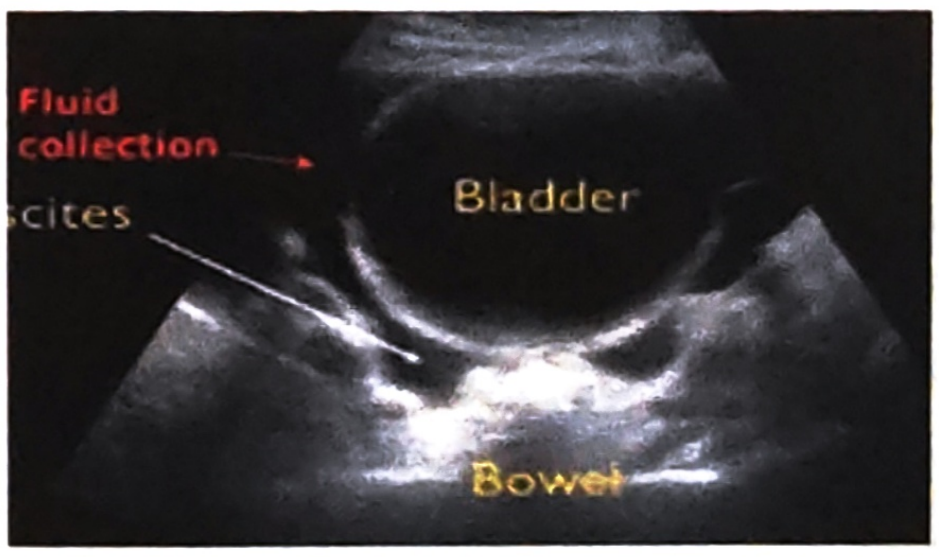

Male - Suprapubic view

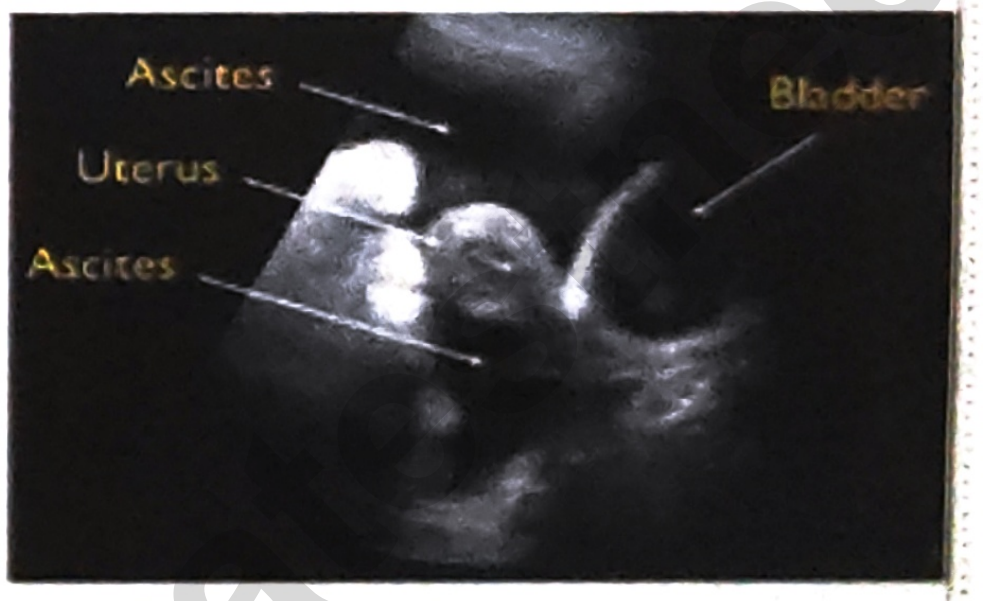

Female - Suprapubic view

Note:

→ First view taken during FAST – Based on the site of injury but usually sub-xiphoid view.

E-FAST (Extended FAST) 00:18:46

→ 4 Views of FAST + Anterior Chest views

FAST	E-FAST
→ Evaluate • Hemoperitoneum • Pericardial effusion	→ Evaluate • Hemoperitoneum • Pericardial effusion • Hemothorax • Pneumothorax

https://t.me/Latestpgnotes

PrepLadder

E-FAST

Note:

→POCUS – Point of care Ultrasound

→BLUE – Bedside Lung Ultrasound in Emergency

→FALLS – Fluid Administered Limited by lung Sonography

→RUSH – Rapid Ultrasound in Shock & Hypotension

Tissue harmonic imaging (THI) 00:23:48

→Difference in propagation velocity of sound through fat & tissues produces phase aberrations causing distortion, noise & clutter

→THI decreases the phase aberrations

→Harmonics are integral multiples of original frequency, the second harmonic is generally needed

→Uses

- ↓se artifacts
- ↓se clutter, noise & improve resolution

3D USG

→Uses Volumetric data

→Used to assess

- Fetal facial features
- Uterine anomalies
- Polydactyly

3D USG

4D USG

→Real time acquisition of 3D data

Note:

→IOC for Uterine anomalies – MRI

https://t.me/Latestneetpgnotes

Ultrasound Elastography

→ Evaluates stiffness of the tissue by color coding.

→ Evaluates by 2 methods

- Strain elastography – Physical compression used (for superficial lesion / soft & elastic tissue)
- Shear wave elastography – High intensity acoustic impulse used (for deep lesion / Hard fibrotic tissue)

→ Ultrasound Elastography used for

- Fibroscan – Progression of Chronic Liver Disease to Cirrhosis
- Breast mass / Thyroid mass
- Cervical ripening
- Guide FNAC / Biopsies

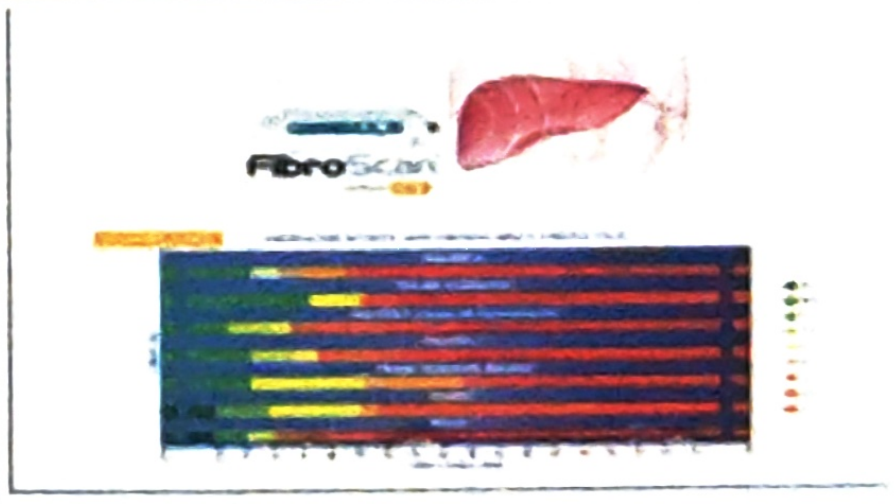

Fibroscan

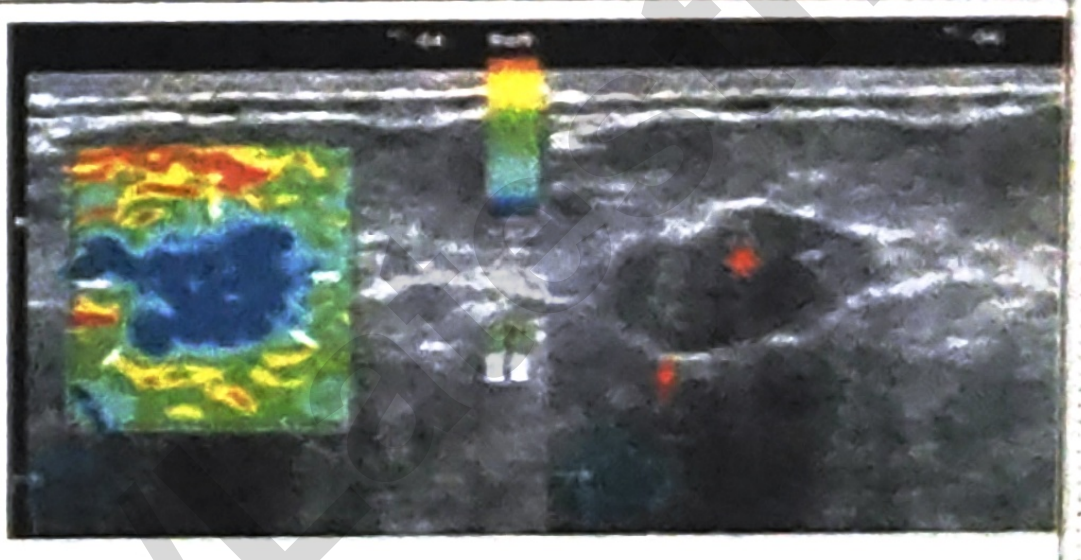

Ultrasound Elastography

https://t.me/neetpgnotes

PrepLadder

For more free ebooks and notes, visit

https://t.me/Latestneetpgnotes

Or click this page to join

Chapter 10

ULTRASOUND – Part 3

Color Doppler

00:00:16

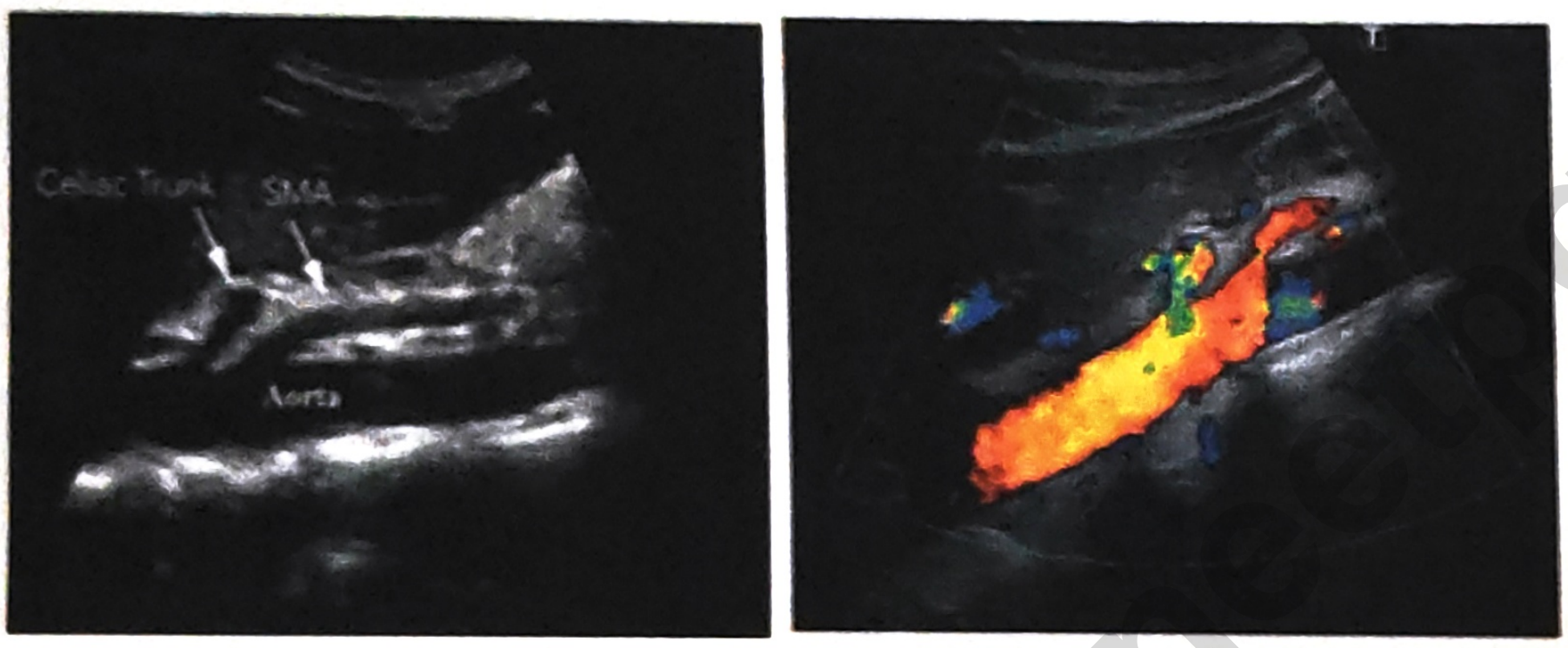

→ It is based on the principle of frequency shift

→ Color coding on color doppler is based on direction of flow

- Flow TOWARDS the probe – RED
- Flow AWAY from probe – BLUE

→ Intensity of color depends on velocity of flow

→ Doppler shift is the difference between incident frequency & reflected frequency

→ Ideal doppler angle should be 0 degree(Never 90°)

→ In practice 45-60° is the optimal doppler angle

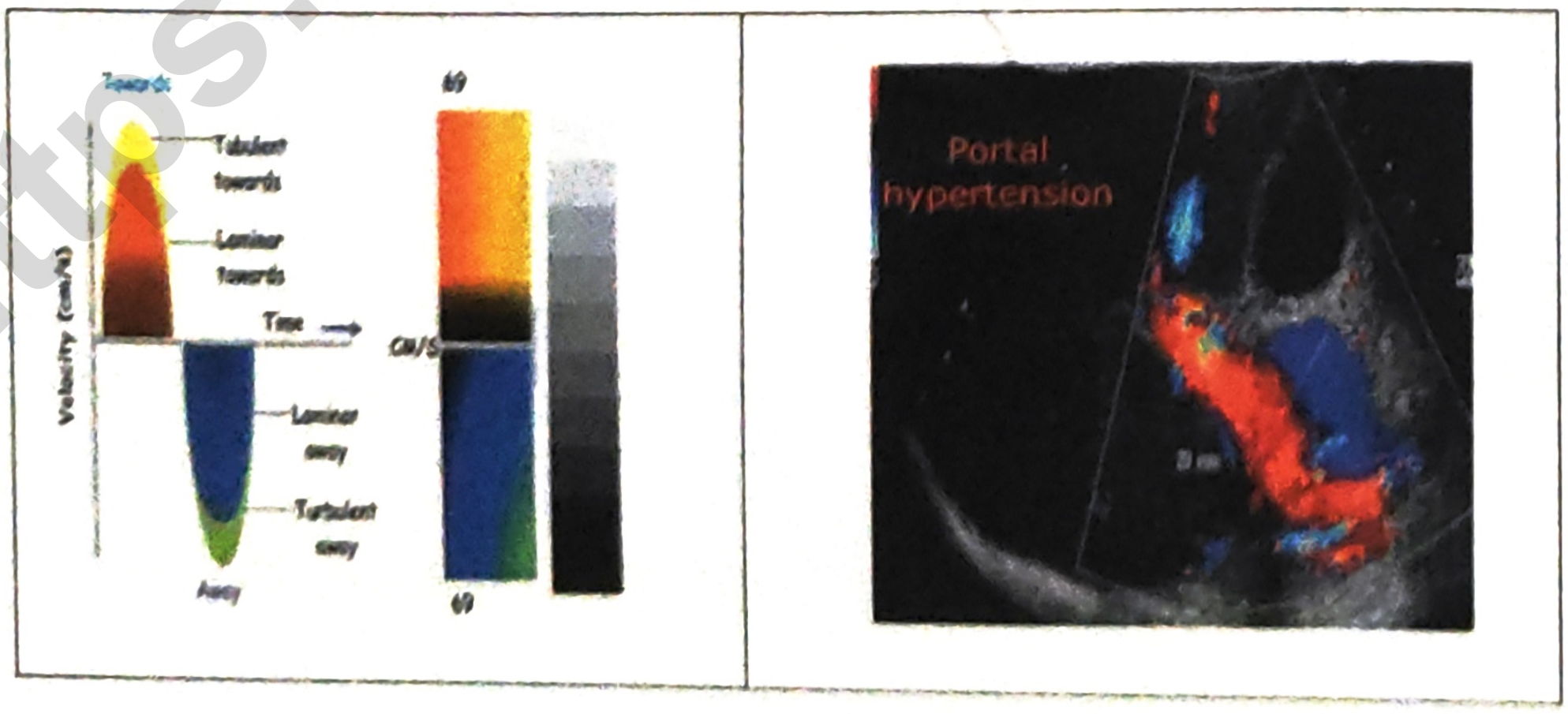

https://t.me/Latestneetpgnotes

Winking sign

- →It is the normal compressibility of veins
- →Arteries do not compress by probe due to high pressure & thick wall but veins get compressed

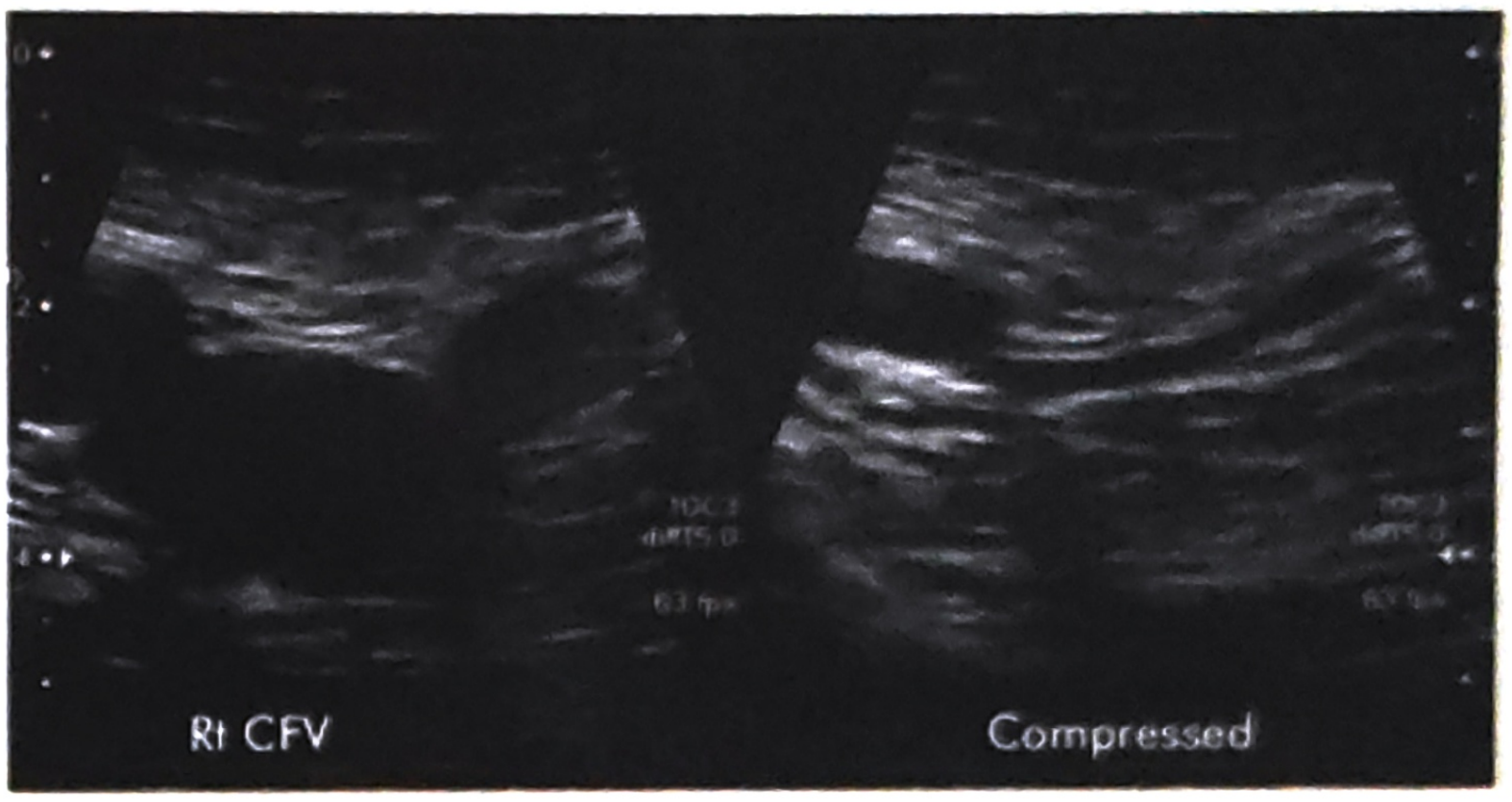

Winking sign

Absent winking sign

- →Lack of compressibility of veins – seen in DVT

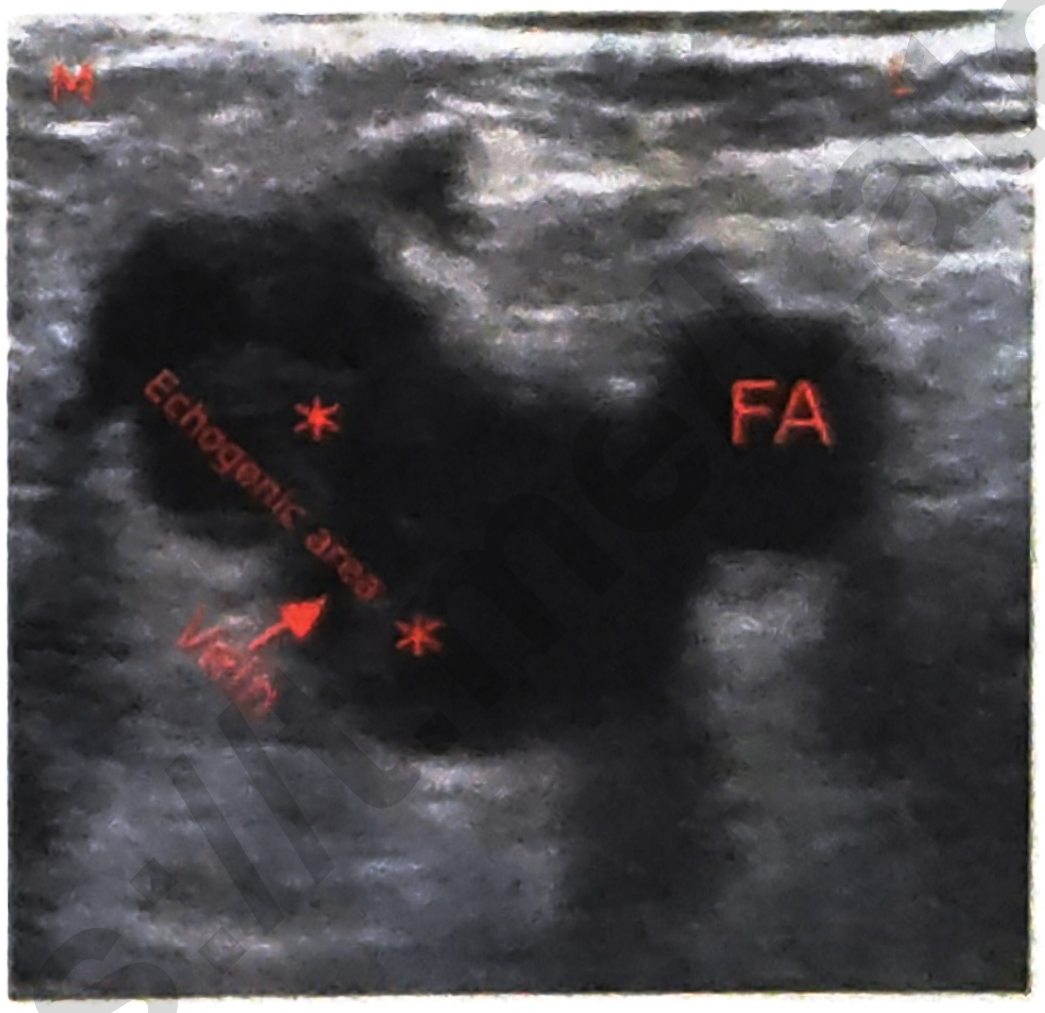

DVT – absent winking sign

Duplex scanning

- →It is a B mode real time USG & Pulsed Doppler
- →Color flow imaging giving 2D visual display of moving blood over a gray scale image
- →IOC for DVT } Duplex Scanning
- →IOC for PVD } Duplex Scanning

https://t.me/bestneetpgnotes

PrepLadder

Power doppler

→ Directional assessment is not done

→ Color display is based on amplitude of returning echoes

→ High intensity for low flow volume

Spectral Doppler:

00:15:21

→ Demonstrates the characteristics of flow -its direction and waveform and provides quantitative assessment of flow

→ Example: Peak Systolic velocity & End Diastolic Velocity

Spectral doppler		
Arteries		Veins
High Resistance (Peripheral arteries)	Low Resistance (Visceral arteries)	
→ Extremities • Femoral A. • External carotid A • Brachial A.	→ Brain arteries • ICA • CCA • VA → Renal arteries, Hepatic arteries	
→ Shows Triphasic pattern 	→ Shows Monophasic pattern with Pulsatility 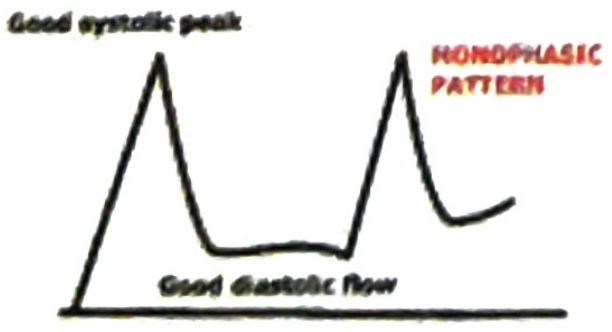 	→ Shows Monophasic pattern with Phascity 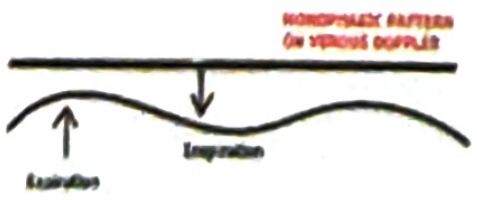

Umbilical artery Doppler

00:20:58

→ Normal umbilical artery

- Shows Good systolic and good diastolic velocity above baseline
- Umbilical artery S/D ratio < 3
- Umbilical artery S/D ratio < S/D ratio of fetal MCA

https://t.me/Latestneetpgnotes

PrepL

→ Abnormal umbilical artery

- If diastolic flow decreases, absent or reverses (OR)
- If S/D ratio of UA increases (OR)
- If S/D ratio of UA > S/D ratio of fetal MCA

All these suggest IUGR or impending fetal demise

If S/D ratio of UA > 3.5 –

- < 34 weeks: Rx – Steroid
- > 34 weeks: Terminate the pregnancy

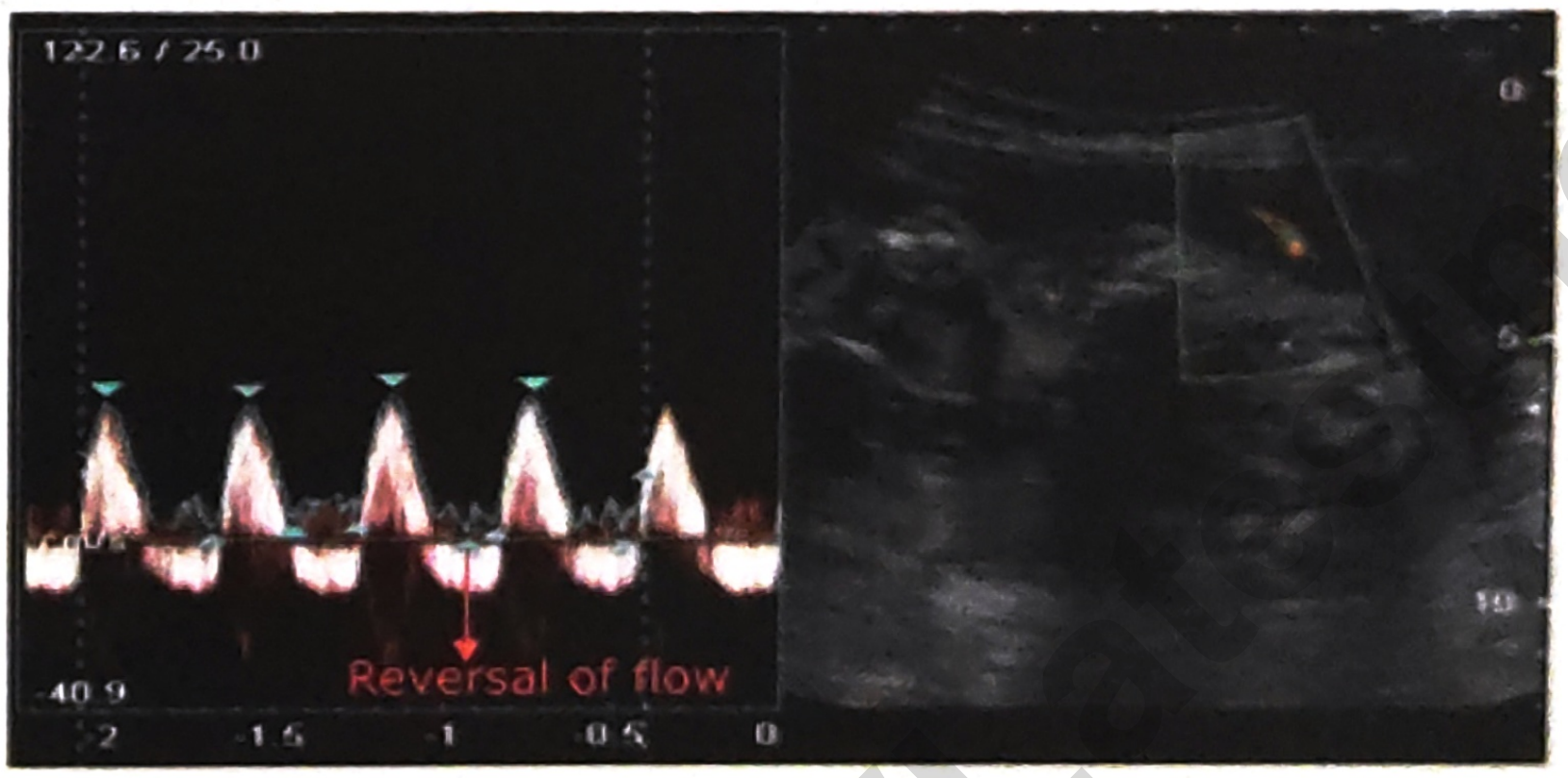



Umbilical artery Doppler

Uterine artery doppler

00:26:11

→ Normal Uterine artery

- Shows good systolic flow
- Absent diastolic notching beyond 22 weeks of Gestation
- Good diastolic flow above base line

https://t.me/Latestpgnotes

PrepLadder

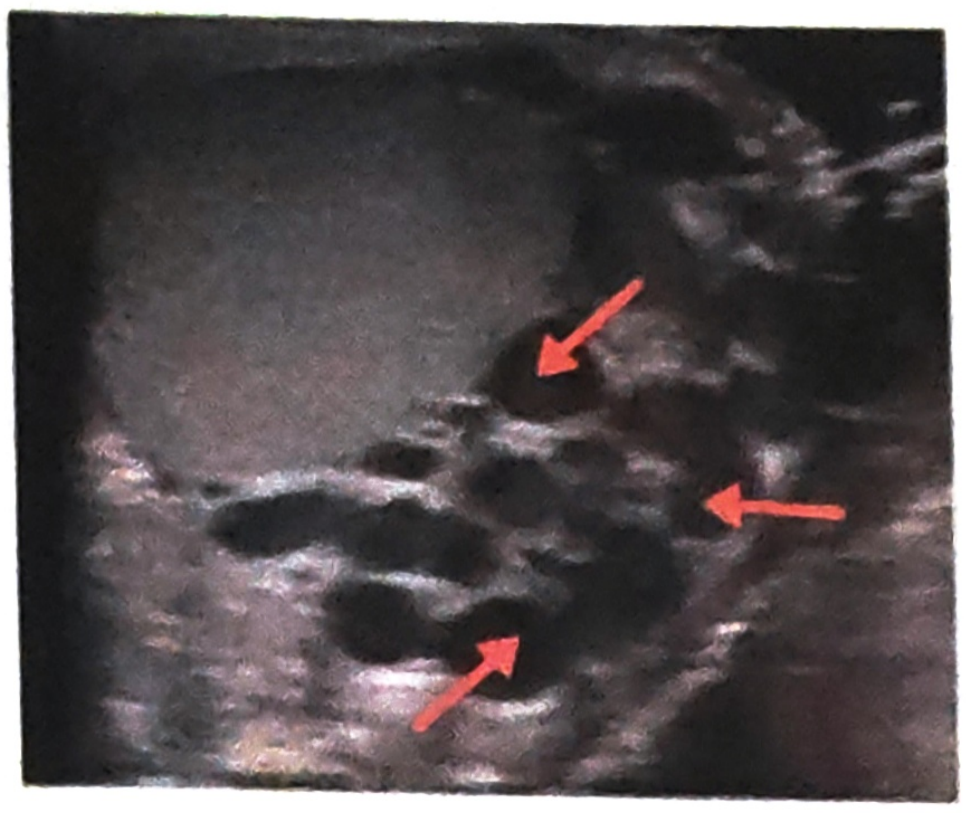

Varicocele

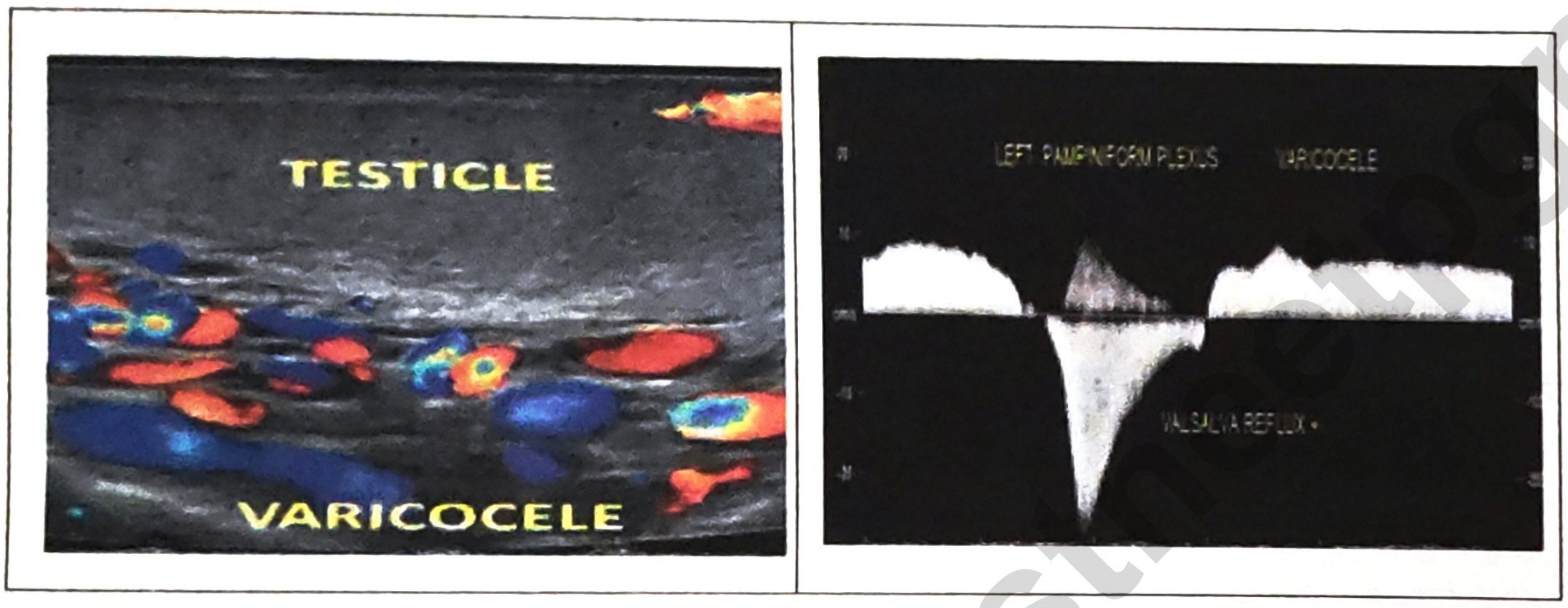

Testicular cancer



Testicular cancer

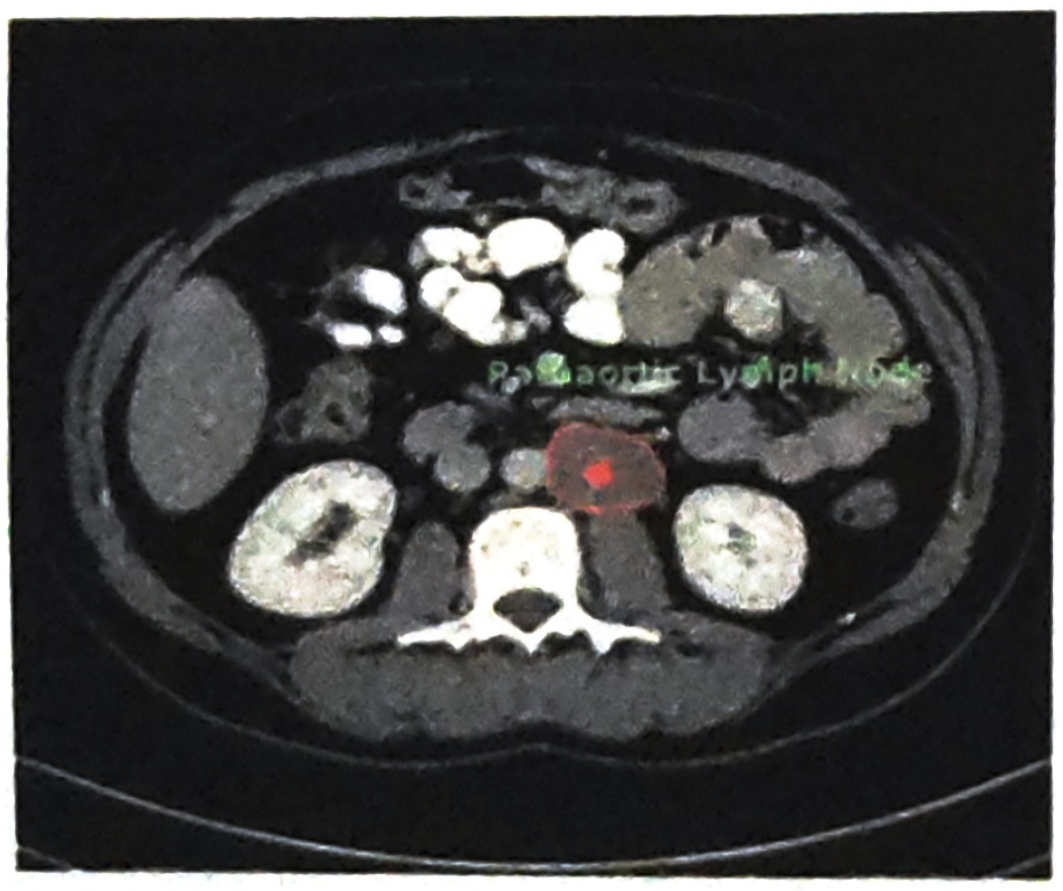

Lymphatic spread of Testicular cancer

https://latestmedpgnotes

Testicular microlithiasis

→ Multiple, punctate, Hyperechoic foci

Testicular microlithiasis

Gynecological Ultrasound

00:37:04

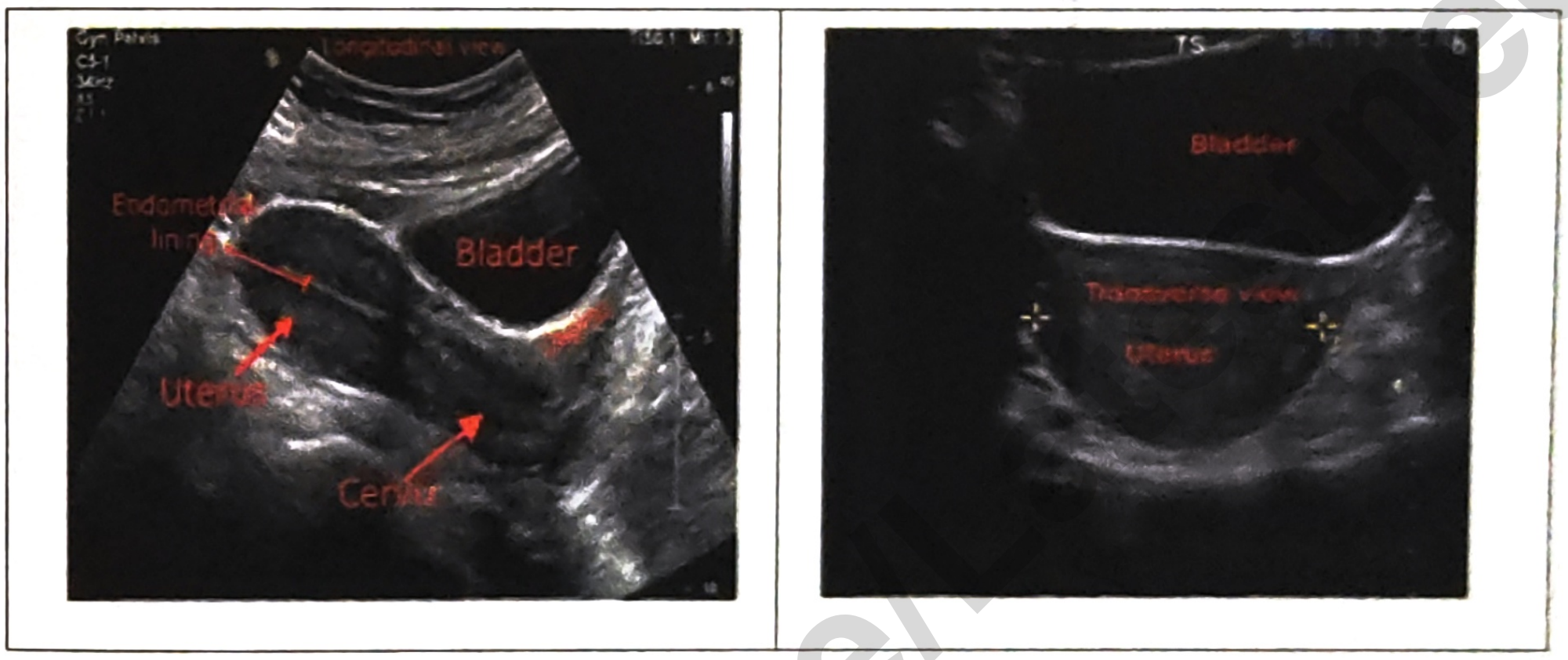

Endometrial thickness

→ It depends on whether the patient is of reproductive age or postmenopausal and at what point in the menstrual cycle is being examined.

→ In premenopausal patients during

- Menstruation: 2-4 mm
- Early proliferative phase (day 6-14): 5-7 mm
- Secretory phase: 7-16 mm

→ In postmenopausal patients ET usually < 5 mm

https://t.me/neetpgnotes

PrepLadder

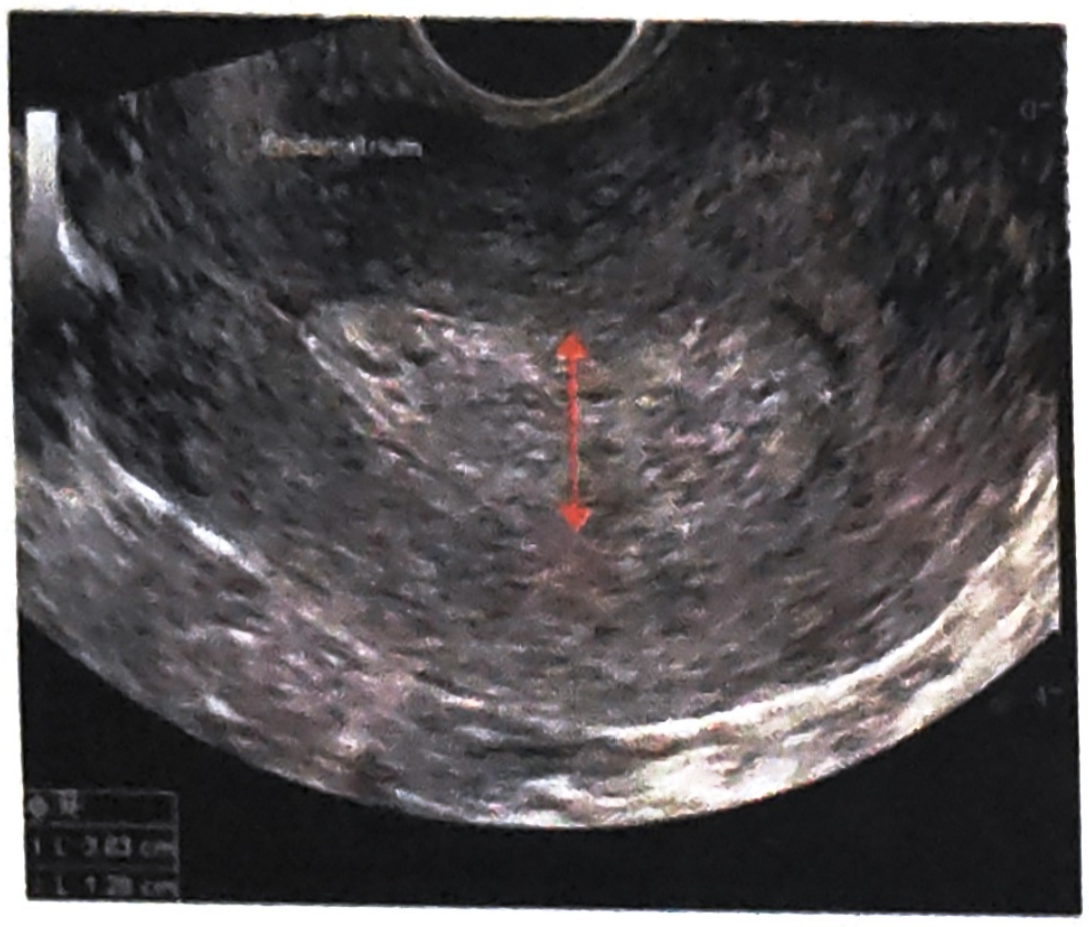

Endometrial thickening

FOCAL ENDOMETRIAL THICKENING	DIFFUSE ENDOMETRIAL THICKENING
→ Endometrial Polyp	→ Secretory phase
→ Endometrial Carcinoma	→ Endometrial Hyperplasia
→ Submucosal Fibroid	→ Endometrial Carcinoma

Sonohysterogram 00:40:30

→Inject saline into-endometrial cavity to differentiate Focal or Diffuse Endometrial thickening

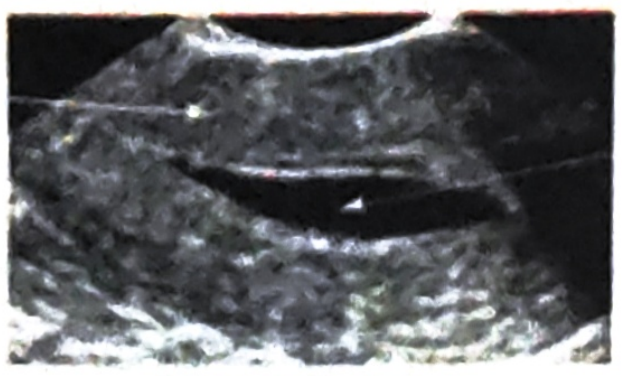

Normal uterus

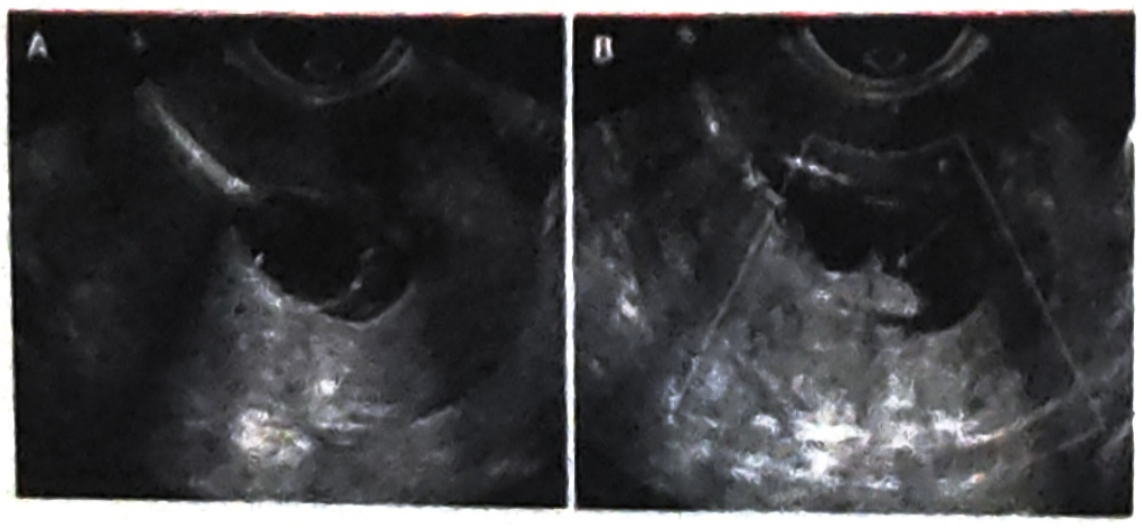

Sonohysterogram

https://t.me/Latestneetpgnotes

Endometrial polyp

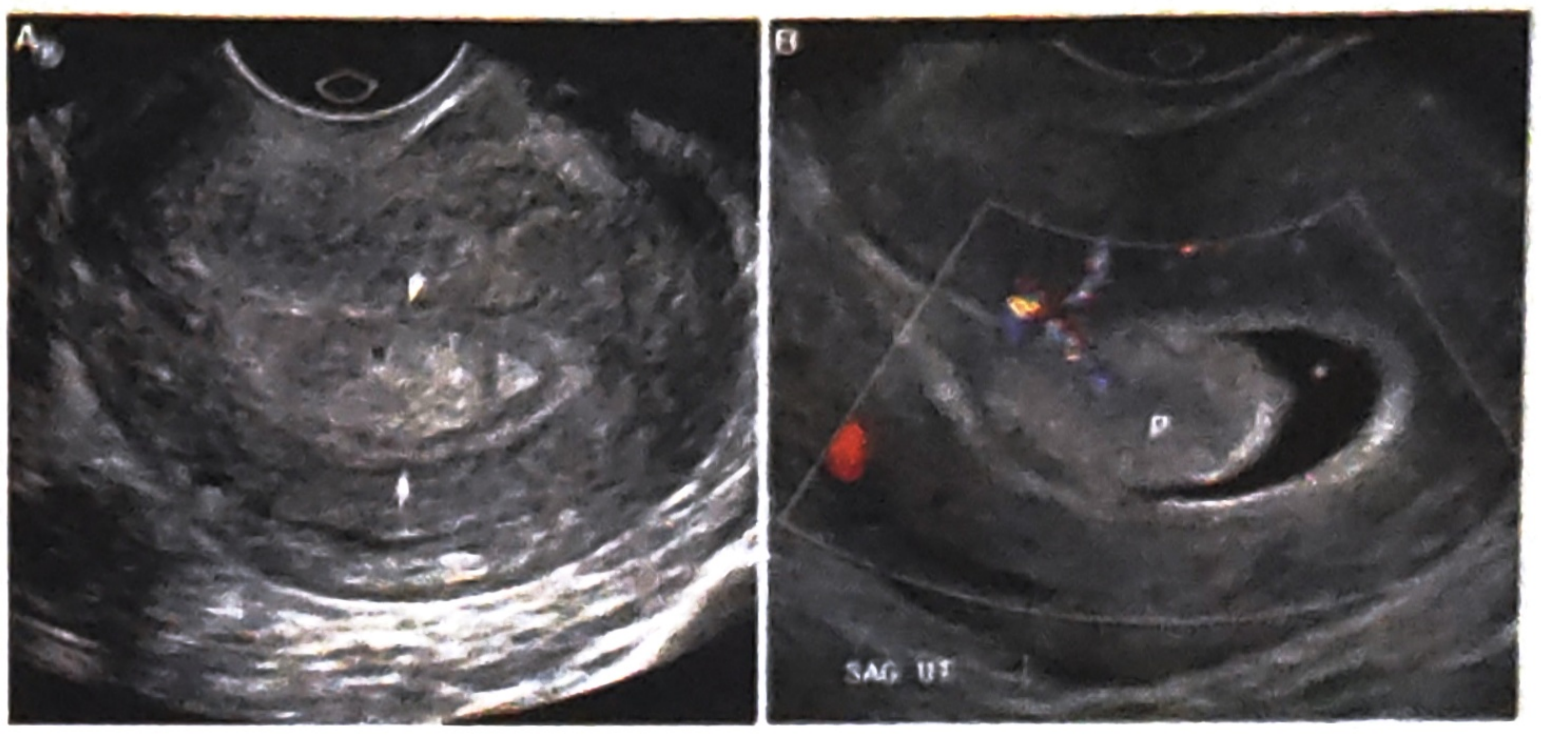

Pedicle vessel/ feeding artery sign

→ Appears as endometrial thickening as the endometrial polyp fills the endometrial cavity

→ may be surrounded by endometrial fluid

→ Best time of examination - postmenstrual.

→ Usually solitary homogeneous and echogenic lesion

→ Interrupted mucosa sign

→ a stalk to the polyp may either be thin- (i.e. pedunculated) or broad-based

→ pedicle artery sign: a single feeding vessel may be seen extending to the polyp on color Doppler imaging

Uterine fibroids

00:44:09

→ Leiomyomas are usually hypoechoic

→ can show calcification and cystic areas

→ A fibroid which is progressively enlarging or of very large size, MRI should be performed to rule out Uterine Sarcoma.

https://t.me/Latestneetpgnotes

PrepLadder

Adenomyosis

00:45:21

→Pelvic MRI is the modality of choice to diagnose and characterize adenomyosis.

→The most easily recognized feature is thickening of the junctional zone ≥12 mm, either diffusely or focally (normal junctional zone thickness is up to ~5 mm)

→Ultrasound Findings-Enlarged Uterus, Thick Myometrial cystic spaces

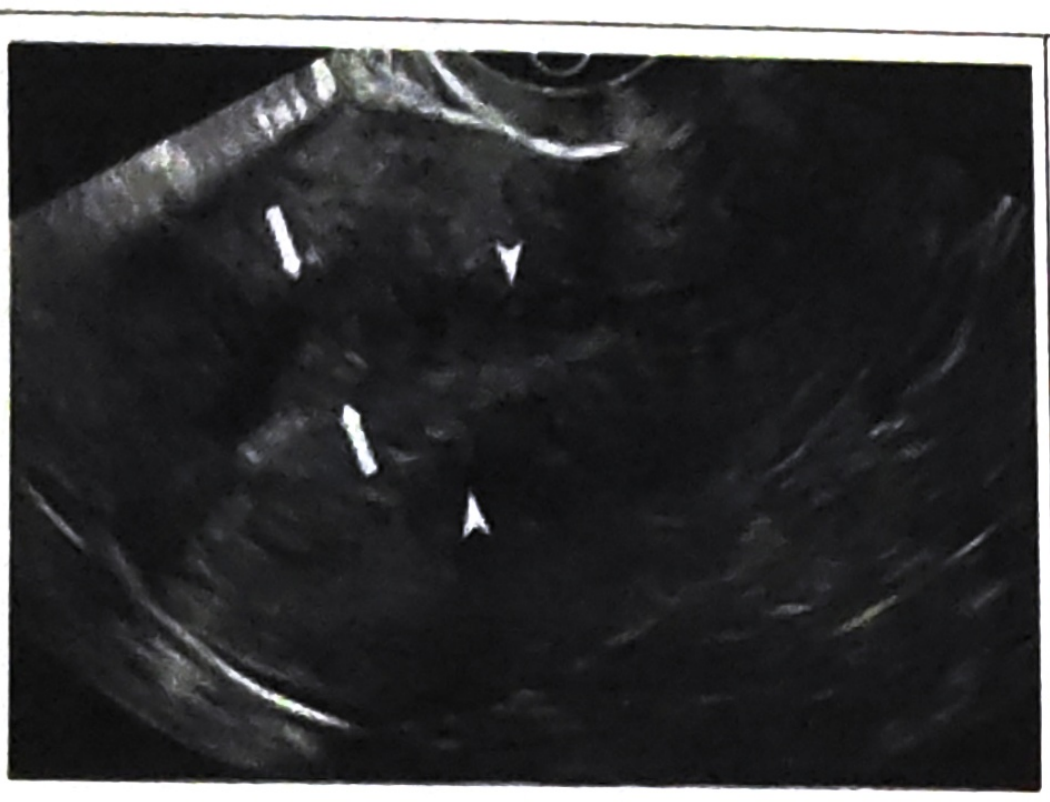	
Adenomyosis - Ultrasound	Adenomyosis – MRI

Endometrial thickening

00:47:46

→Endometrial hyperplasia

→Tamoxifen therapy

→Endometrial Carcinoma

Note:

Postmenopausal Bleeding

↓ Endometrial thickness › 5 mm → ↓ Endometrial Carcinoma

↓ Endometrial thickness ‹ 5 mm → ↓ Endometrial Atrophy

https://t.me/Latestnotes

Poly cystic ovarian syndrome 00:48:48

→Follicle Number Per Ovary>20

→Ovarian Volume >10 ml

→hyperechoic central stroma

→peripheral location of follicles (string of pearls sign)

→follicles of similar size measuring 2-9 mm

→presence of a single multi follicular ovary is sufficient to provide the sonographic criterion for PCOS

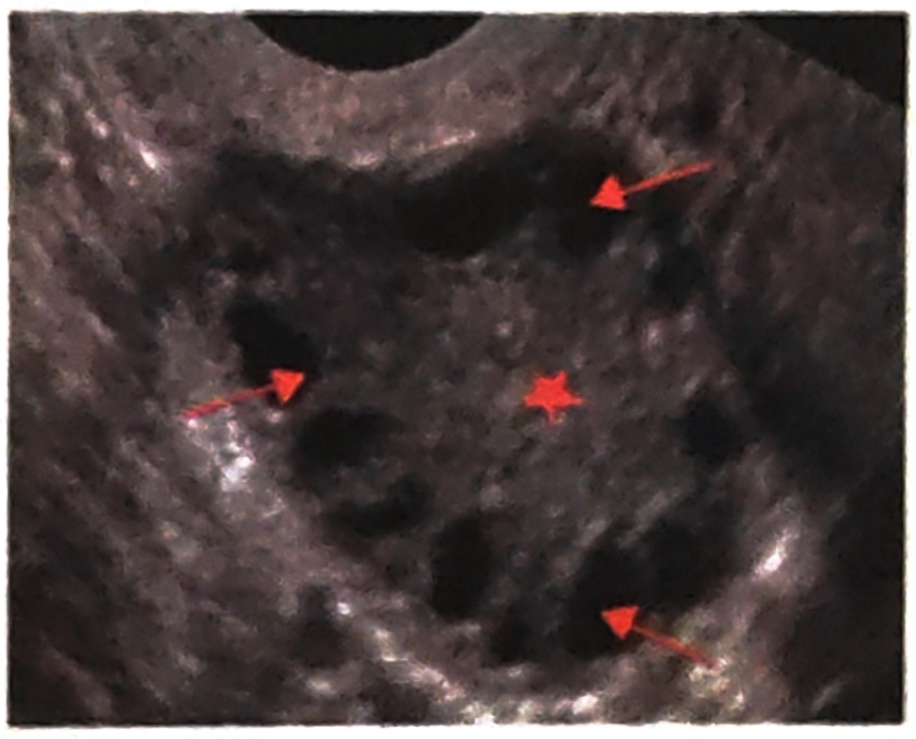

String of pearls sign

Ovarian hyperstimulation syndrome

→Seen in Ovulation Induction Therapy/ In Vitro fertilization

→bilateral symmetric enlargement of ovaries

→multiple cysts of varying sizes, giving the classic spoke-wheel appearance

→Vasoactive peptides – Capillary leak

→Loss of intravascular fluid – Third space collections

→associated ascites and pleural and pericardial collections

→Hemoconcentration

→Oliguria

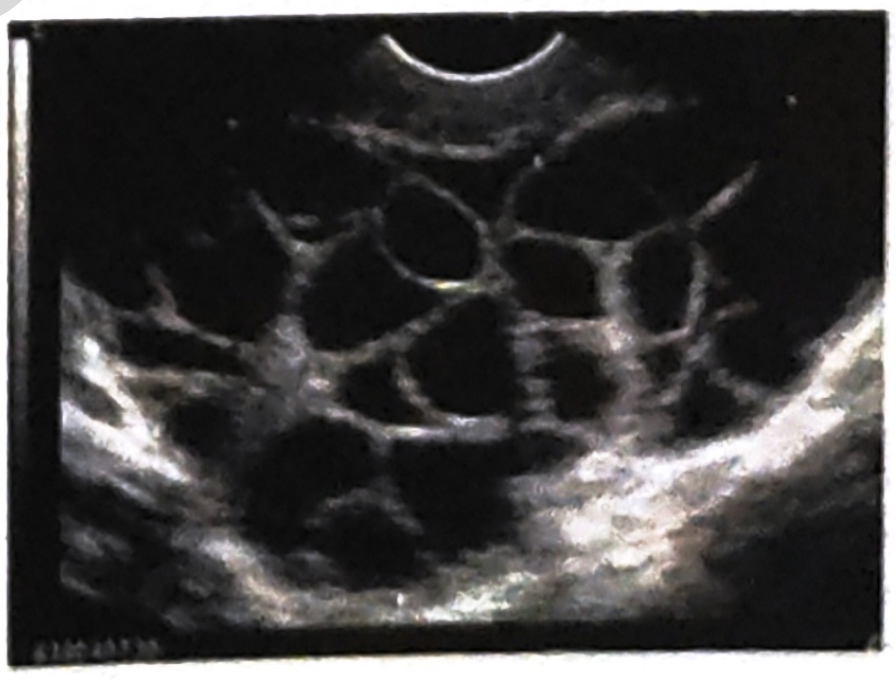

Ovarian hyperstimulation syndrome

https://t.me/Latestneetpgnotes

PrepLadder

Simple Ovarian Cyst

00:52:42

→ Unilocular Anechoic cystic lesion

→ Posterior acoustic enhancement

→ Thin smooth walls with no solid component and no internal vascularity

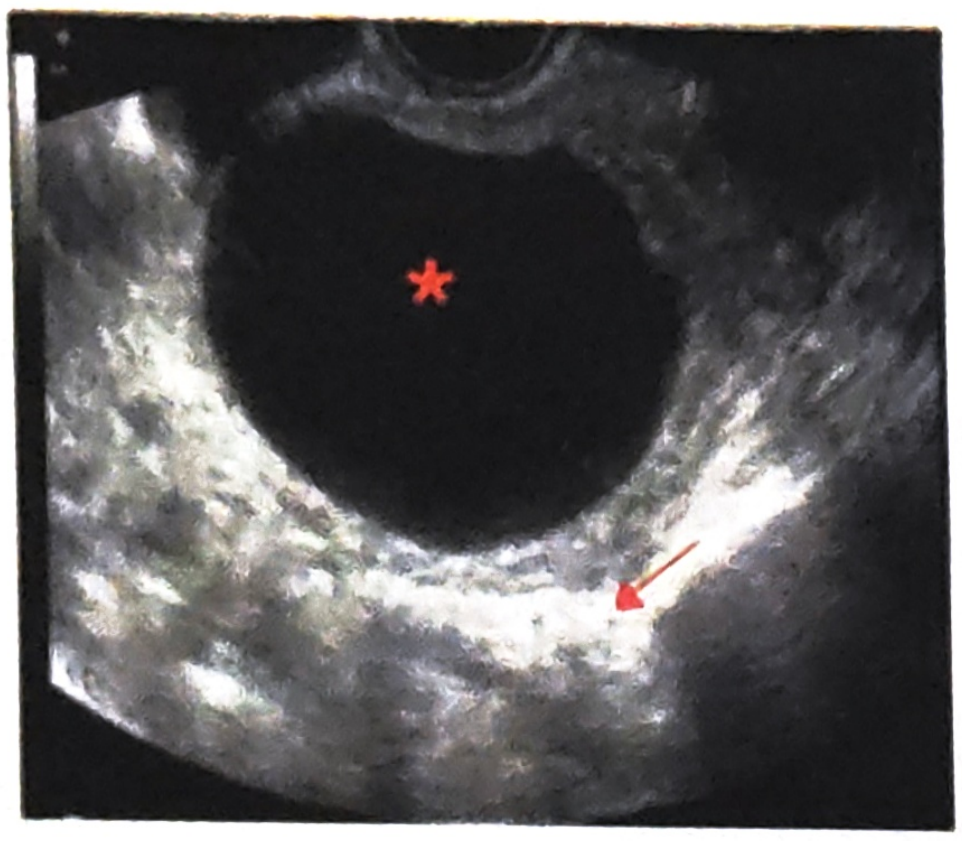

Simple Ovarian Cyst

Hemorrhagic Ovarian cyst

→ Reticular or lacy internal echoes due to fibrin strands

→ Solid cystic appearing with No internal flow on doppler

→ Resolves on Follow up imaging

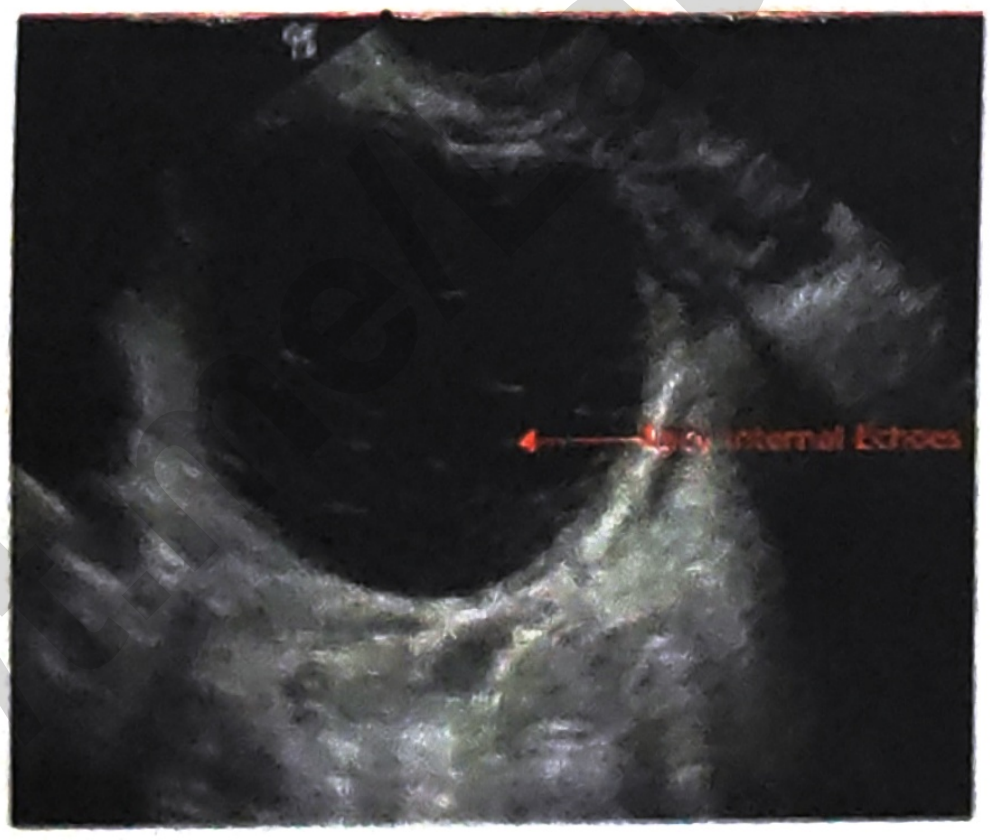

Hemorrhagic Ovarian cyst

Mature cystic teratoma/ Ovarian Dermoid

00:54:35

→ Hypoechoic cystic mass

→ Contains calcifications

→ Rokitansky Nodules

→ Fat-Fluid Level

→ Bright on T1 and loses signal on Fat saturation images

https://t.me/neetpgnotes

PrepLadder

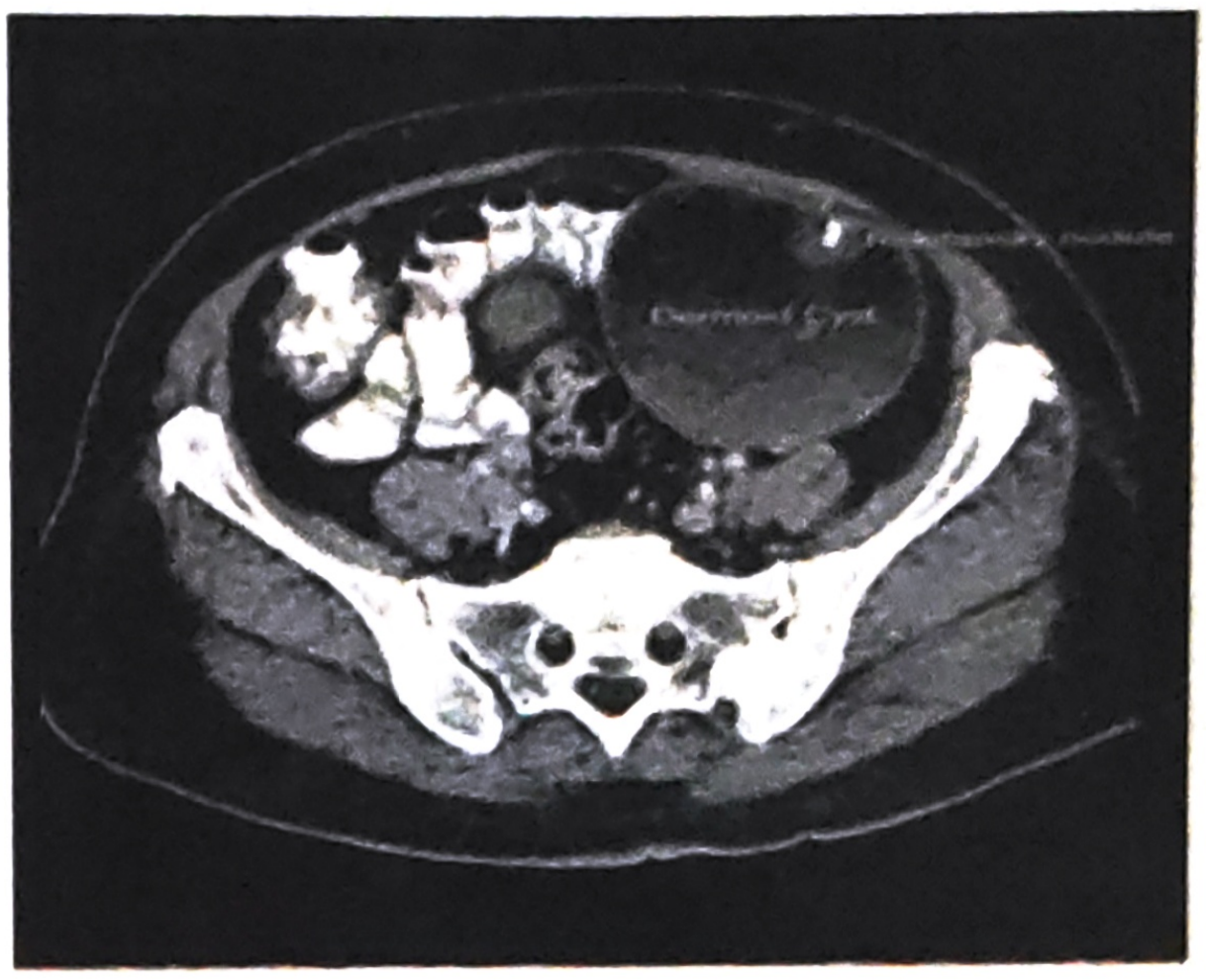

Ovarian Dermoid – CT scan

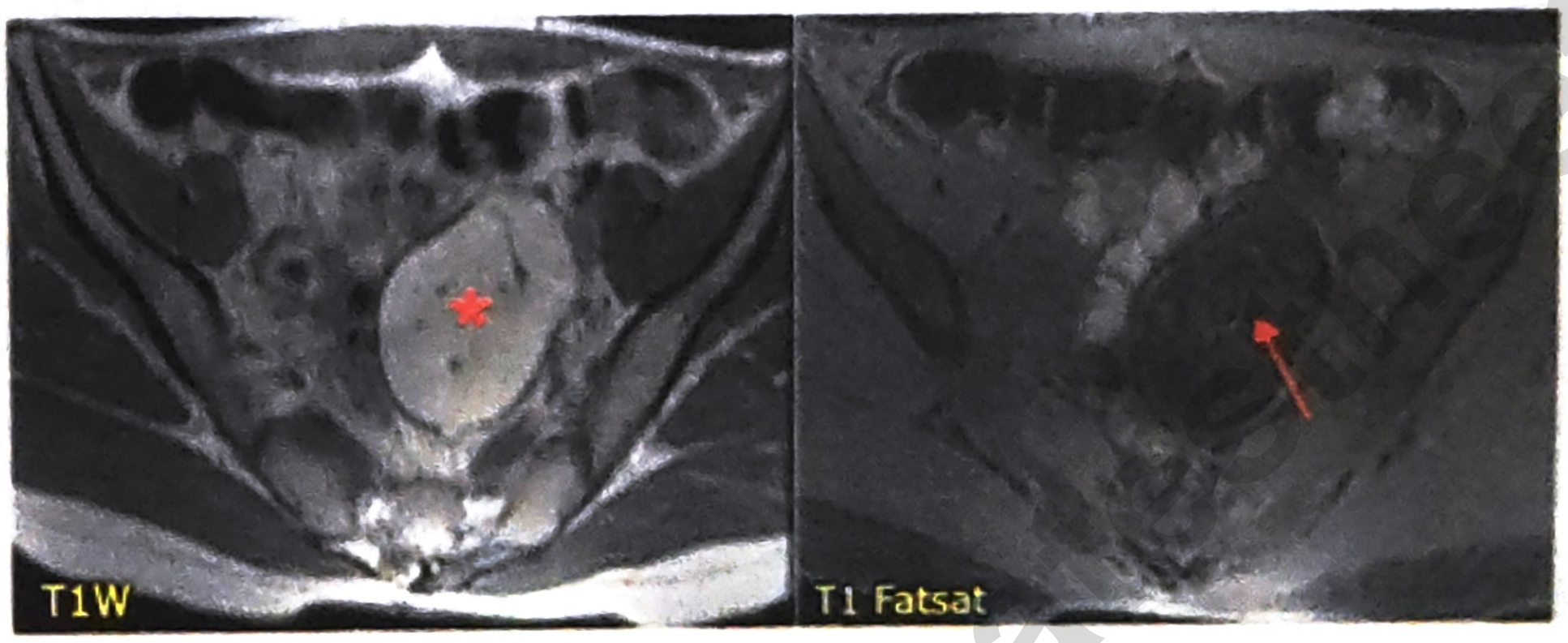

Ovarian Dermoid - MRI

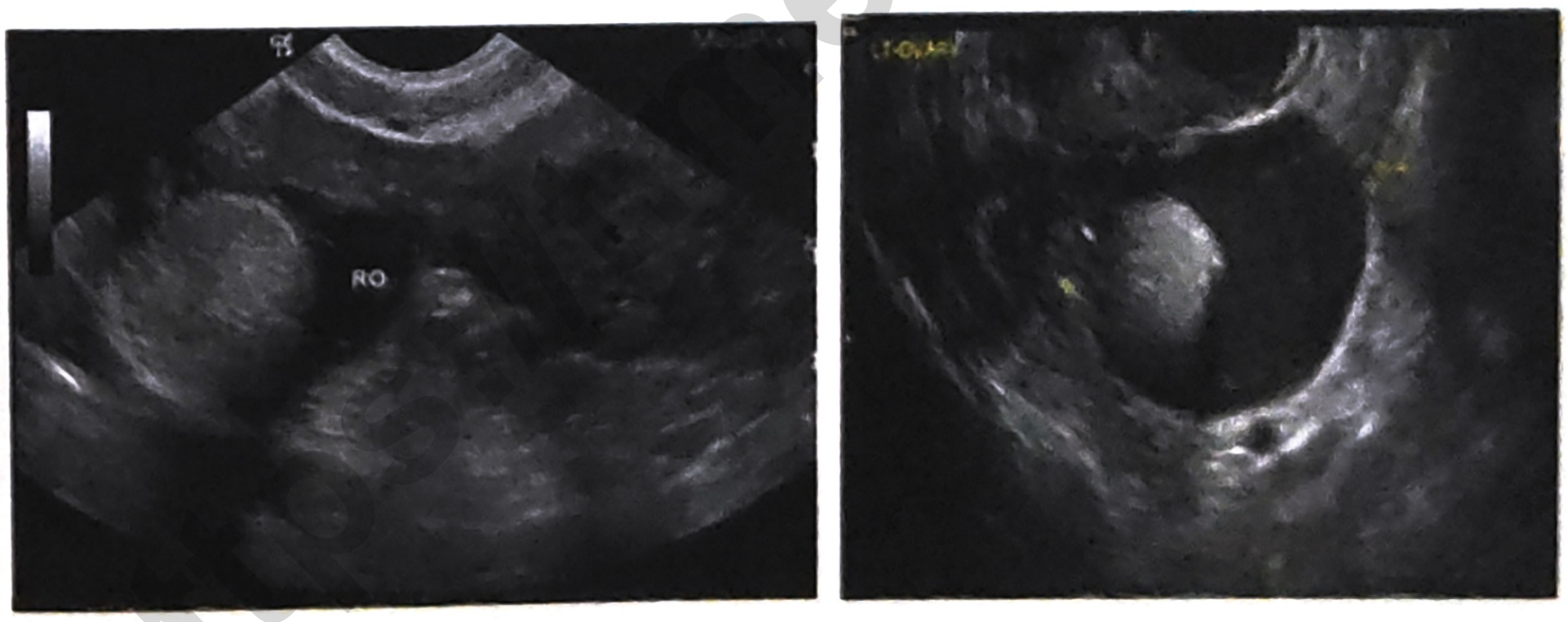

Ovarian Dermoid - Ultrasound

https://t.me/Latestpgnotes

Ovarian Torsion

00:57:05

- →Enlarged Ovary >4 cm
- →Variable Echogenicity
- →Pelvic free fluid
- →Underlying ovarian lesion may be a possible lead point
- →Absent ovarian Venous flow-more common
- →Absent Arterial flow -less common
- →Whirlpool sign of twisted vascular pedicle.

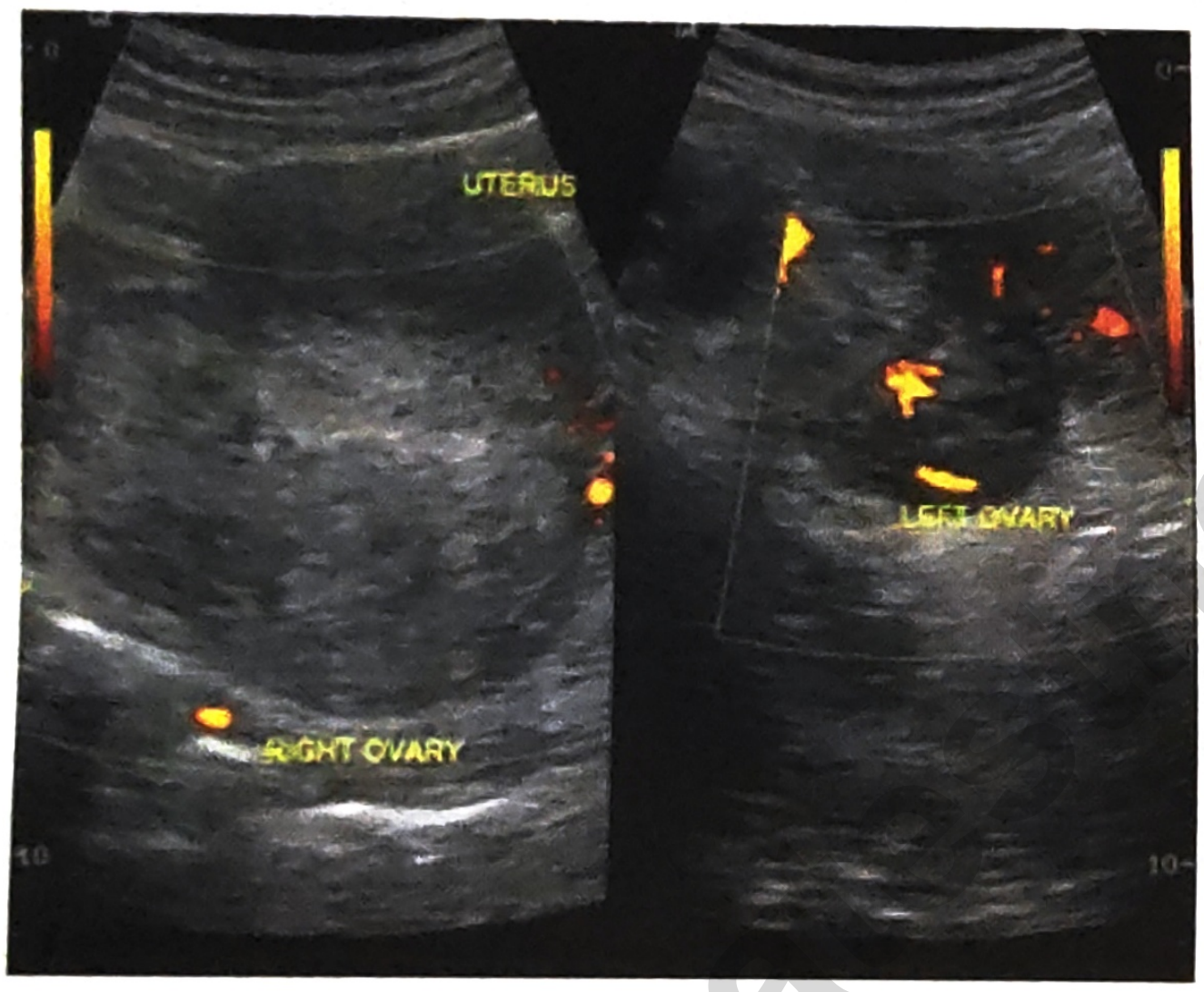

Ovarian Torsion

https://t.me/LatestNeetpgnotes

PrepLa

Chapter 11

Obstetric Ultrasound

MOLAR PREGNANCY 00:00:21

→ Bulky uterus with Echogenic Intrauterine mass

→ Multiple cystic area in Antenatal scan

- "SNOW STORM APPEARANCE"

→ HYDATIFORM MOLE/ MOLAR PREGNANCY

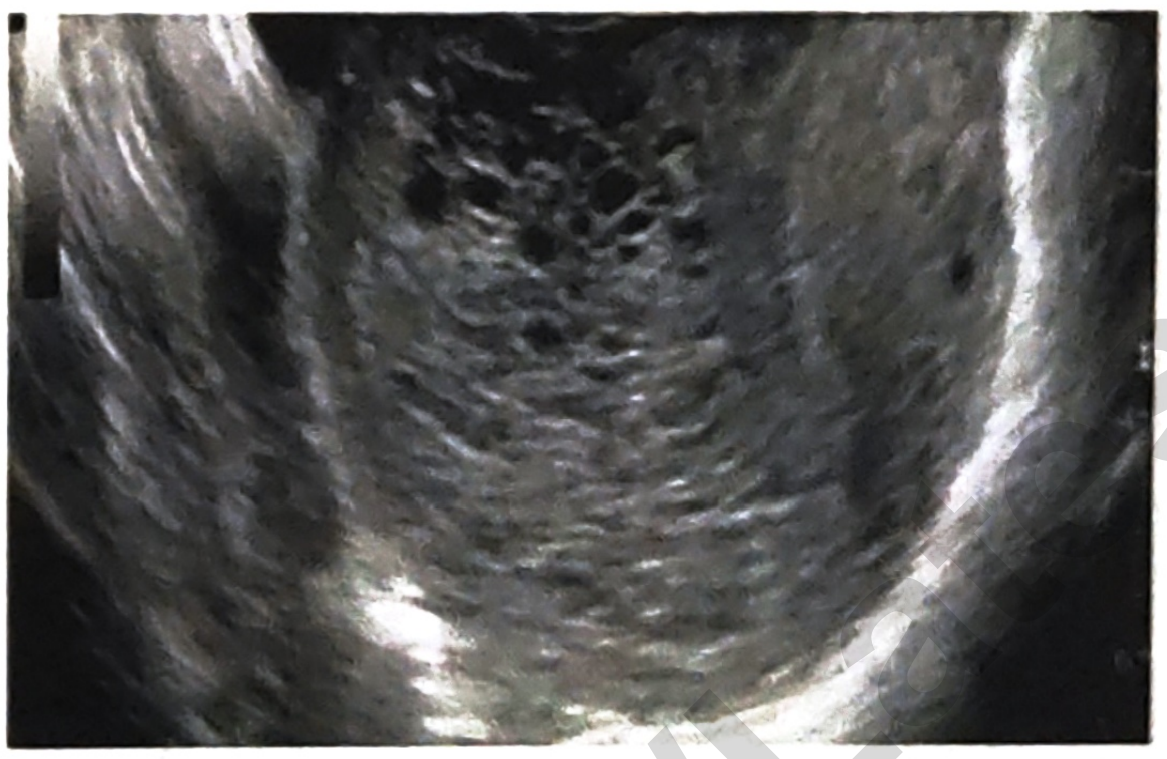

HYDATIFORM MOLE/ MOLAR PREGNANCY

Note:

→ Complete Mole – No fetal parts

→ Incomplete Mole – Some Fetal part can be seen.

ECTOPIC PREGNANCY 00:01:30

→ Reproductive age female with Lower Abdominal pain

↓

- Transvaginal ultrasound
  - Complex adnexal cyst with peripheral echogenic ring – Ectopic Tubal Ring/ Bagel sign
  - Empty uterine cavity, pseudogestational sac.

https://t.me/Lastneetpgnotes

PrepLadder

- Color Doppler
  - Ring of fire appearance
- Free fluid in pelvic cavity/ pouch of Douglas
- Hemoperitoneum – Ruptured Ectopic pregnancy

	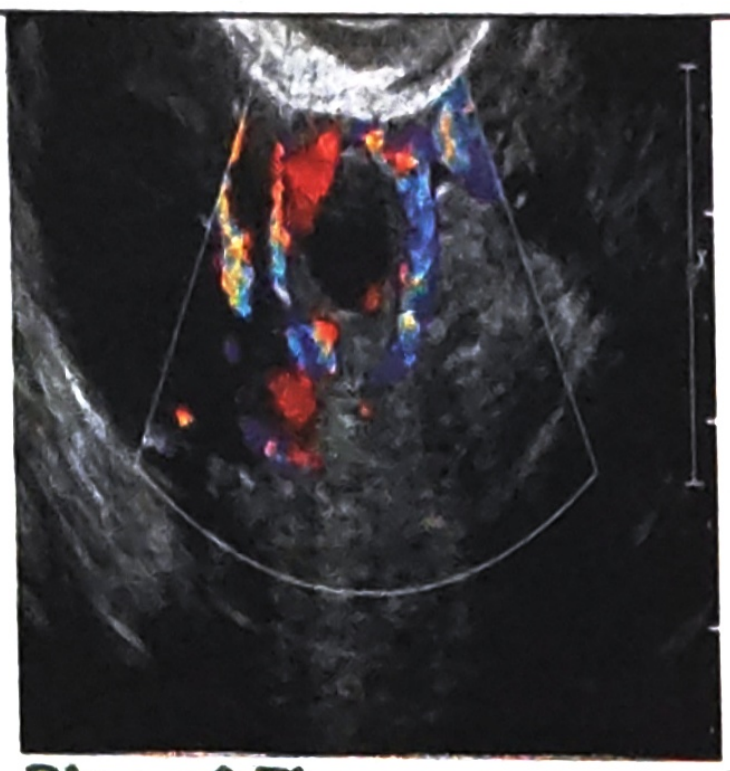
Bagel Sign	Ring of Fire appearance

Note:

- Bagel Sign/ Ectopic Tubal Sign → Unruptured Ectopic pregnancy
- Ring of fire appearance → also in corpus luteal cyst.

DDX of Ectopic pregnancy

- Acute appendicitis
- Corpus Luteal cyst.

Ectopic Pregnancy	Corpus Luteal cyst
→ Adnexal mass located adjacent to Ovary.	→ Surrounded by Normal Ovary
→ Bimanual examination – Move separately from Ovary	→ Bimanual examination – Move along with Ovary
→ β-Hcg elevated	→ β -Hcg will not be elevated

First Trimester Ultrasound 00:06:27

→ For Dating of Pregnancy and Viability

→ for Number and Abnormalities of the embryo

→ To look for Placental Abnormalities

→ Evaluating for Ectopic Pregnancy

https://t.me/Latestneetpgnotes

Second and third trimester scan — 00:07:00

- → Detecting fetal anomalies
- → Evaluating amniotic fluid
- → Determining fetal position

Note:

TIFFA SCAN

- → TARGETED IMAGING FOR FETAL ANOMALIES
- → Done in second trimester usually between 18-22 weeks to look for any congenital anomalies

Appearance of structures in pregnancy — 00:07:56

Sequence	Transvaginal Sonography	Transabdominal Sonography
Gestational Sac (Earliest/First sign)	4-4.5 weeks	5-5.5 weeks
Yolk sac (First Definitive sign of Intrauterine pregnancy)	5-5.5 weeks	6-6.5 weeks
Embryo/Fetal Pole	6-6.5 weeks	7-7.5 weeks
Fetal Cardiac Activity	7-7.5 weeks	8-8.5 weeks

Signs of Gestational Sac — 00:11:29

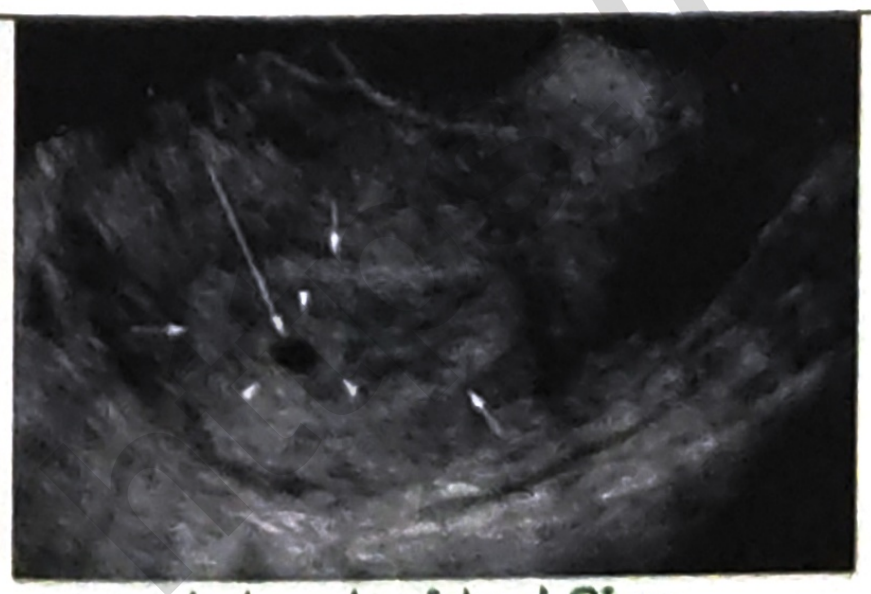

Intradecidual Sign

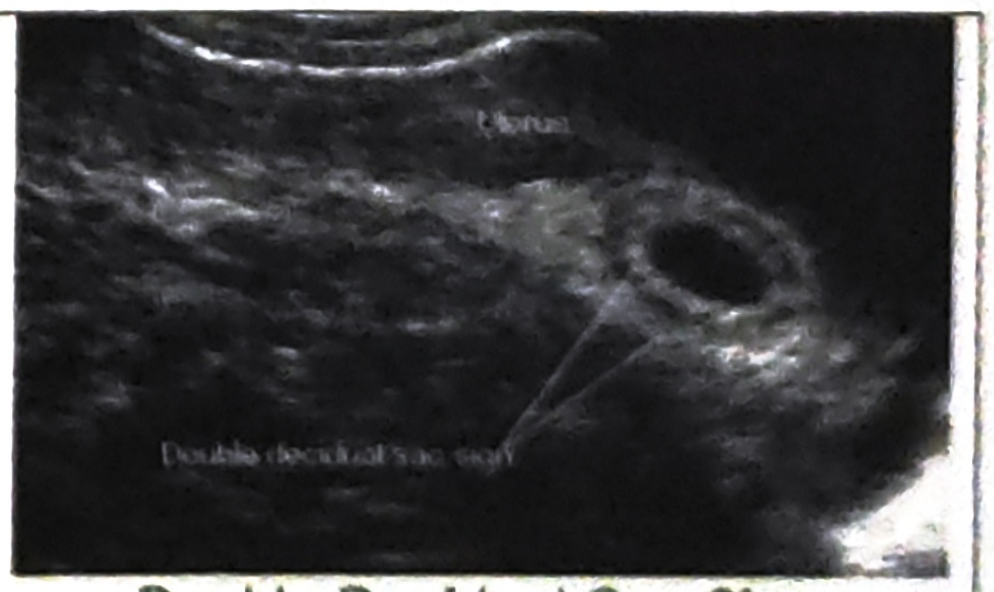

Double Decidual Sac Sign

INTRADECIDUAL SIGN

- → Eccentric Round fluid collection(gestational sac) with an echogenic rim located within a thickened decidua

/t.me/Latestneetpgnotes

PrepLadder

DOUBLE DECIDUAL SAC SIGN

→ Useful feature on early pregnancy ultrasound to indicate the presence of an early intrauterine pregnancy (IUP) when the yolk sac or embryo is still not visualized.

→ Two concentric rings surrounding an anechoic gestational sac consisting of Decidua Parietalis lining the uterine cavity and Decidua Capsularis lining the gestational sac

→ Where the two adhere is the decidua basalis, and is the site of future placental formation.

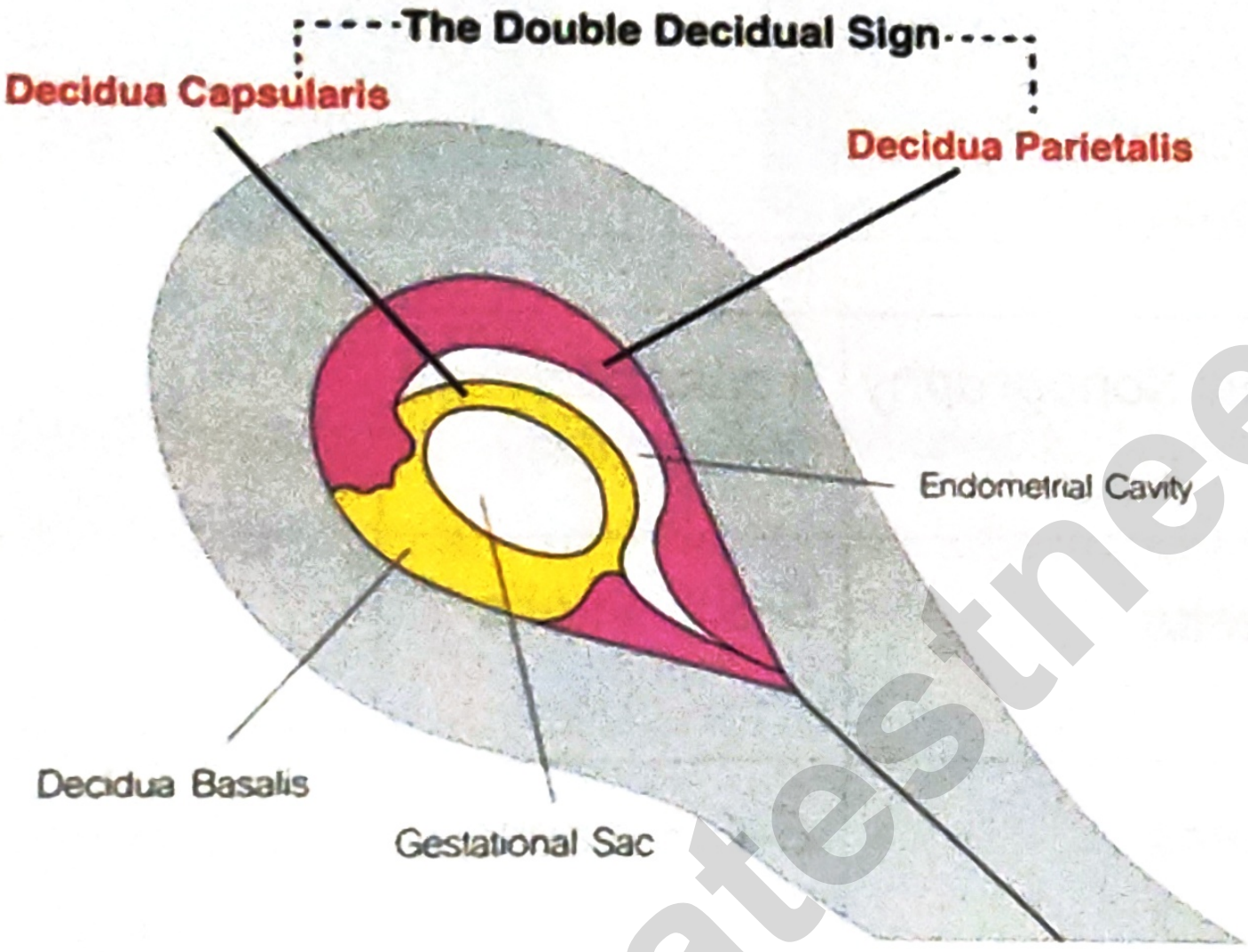

Anembryonic pregnancy/ Missed abortion

- MSD >25mm without Yolk sac or embryo

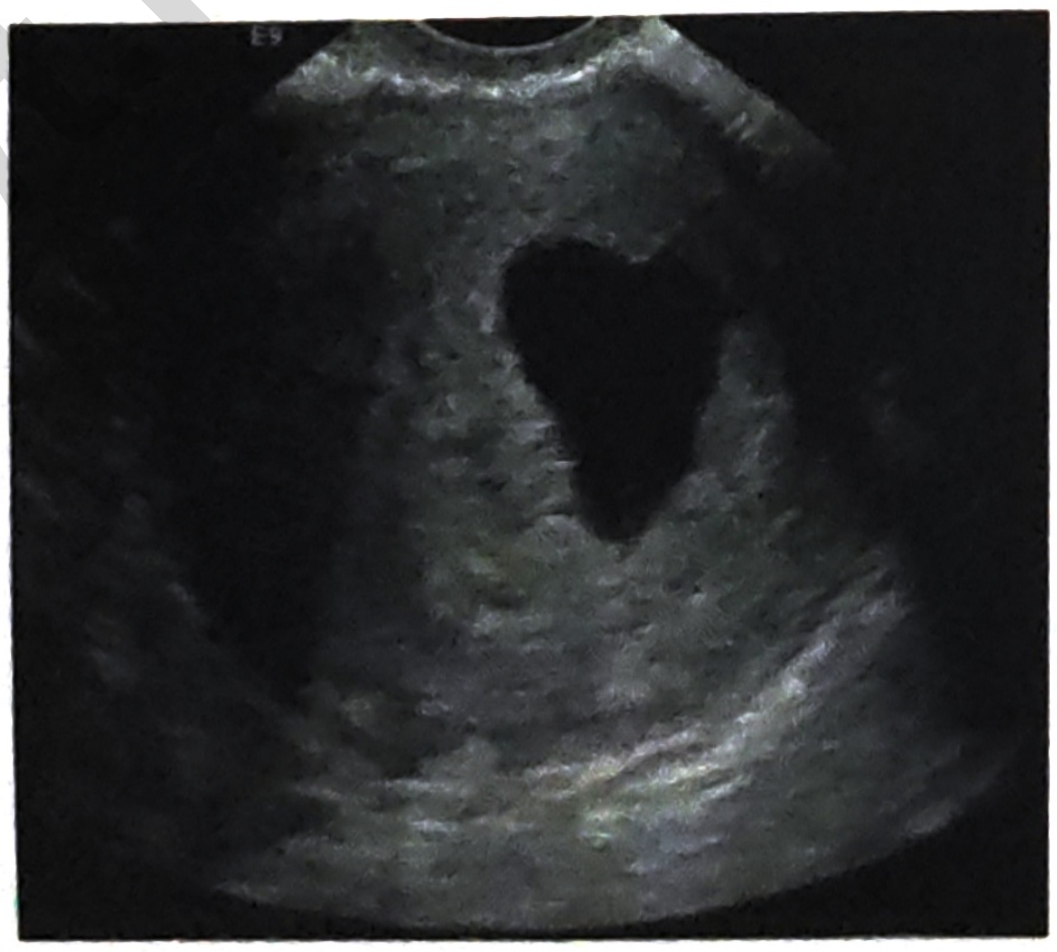

Anembryonic pregnancy

https://t.me/Latestneetpgnotes

Yolk sac
00:15:11

- → Yolk sac is the first anatomical structure identified within the gestational sac.
- → visualization is useful in distinguishing an intrauterine pregnancy (IUP) from a pseudogestational sac
- → Number of yolk sac is equal to number of amnion

Yolk sac

Double Bleb Sign

Double Bleb sign

- → visualization of a gestational sac containing a yolk sac and amniotic sac giving an appearance of two small bubbles with embryonic disc in between and is the earliest demonstration of embryo

Fetal pole/ Embryo

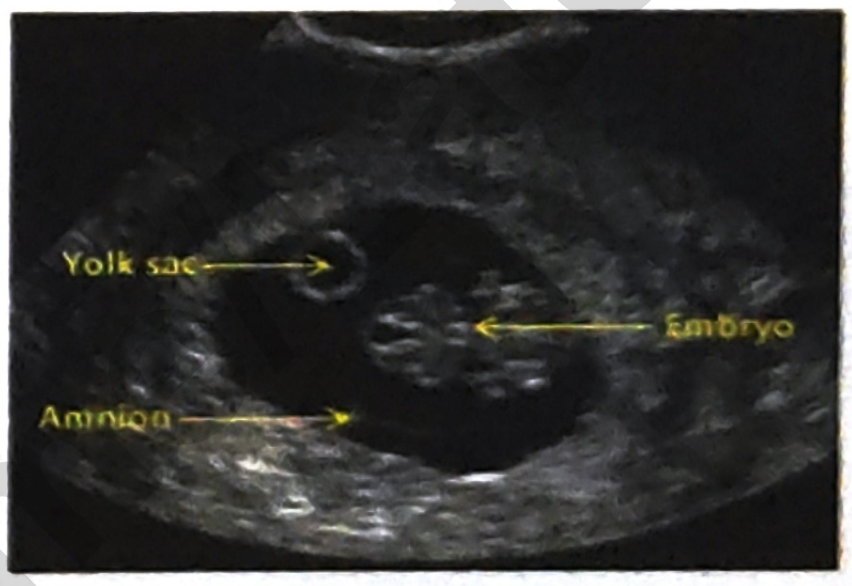

00:17:22

Missed Miscarriage/Missed Abortion/ Failed Early Pregnancy

- → CRL >7mm without Fetal Cardiac Activity
- → MSD >25mm without Yolk sac or embryo

Placenta

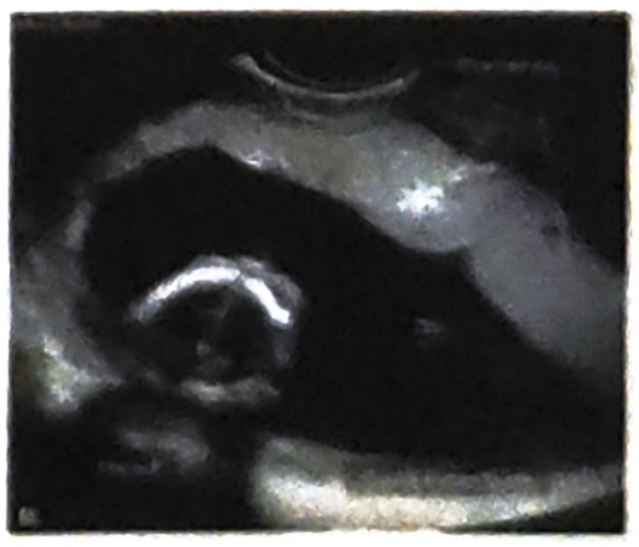

https://t.me/testneetpgnotes

Nuchal Translucency scan 00:18:51

→ Should be done between 11w-13 weeks + 6 days Period of Gestation

→ CRL should be 45-84 mm

→ Done in mid sagittal view in neutral flexion

→ Nasal tip and hard palate should be seen in same view

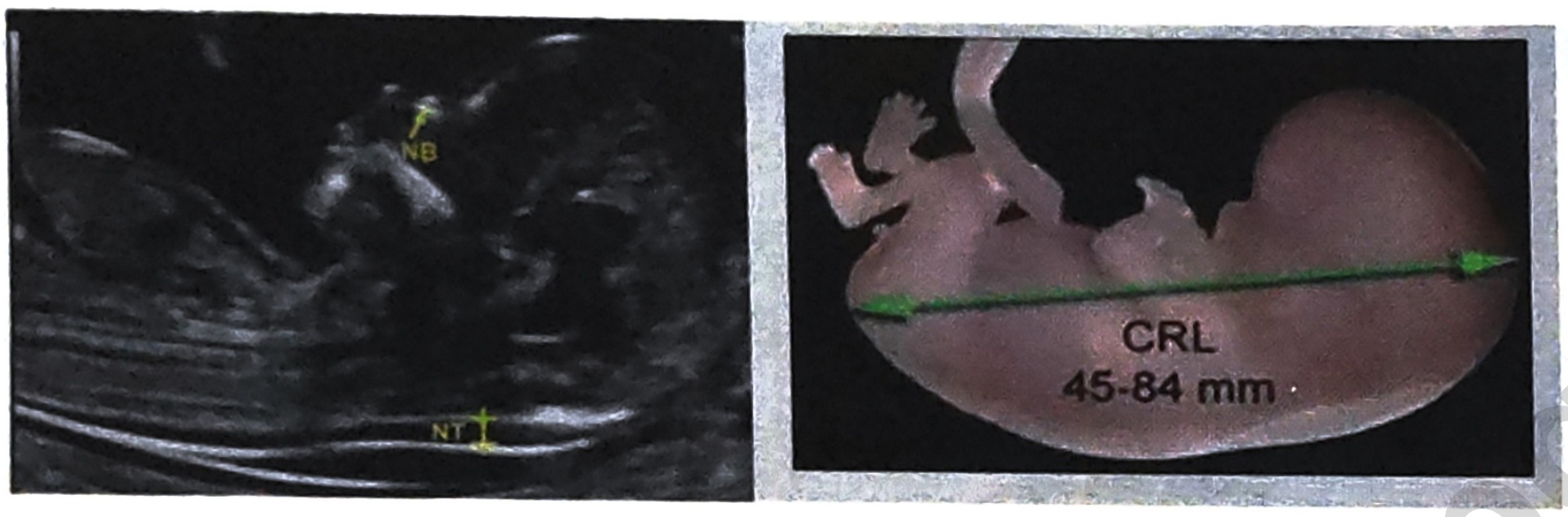

Note:

→ Normal Nuchal Translucency < 3 mm

→ ↑ Nuchal Translucency – Soft marker of Aneuploidy

Fetal Ductus Venous Doppler

Normal Ductus Venous Waveform

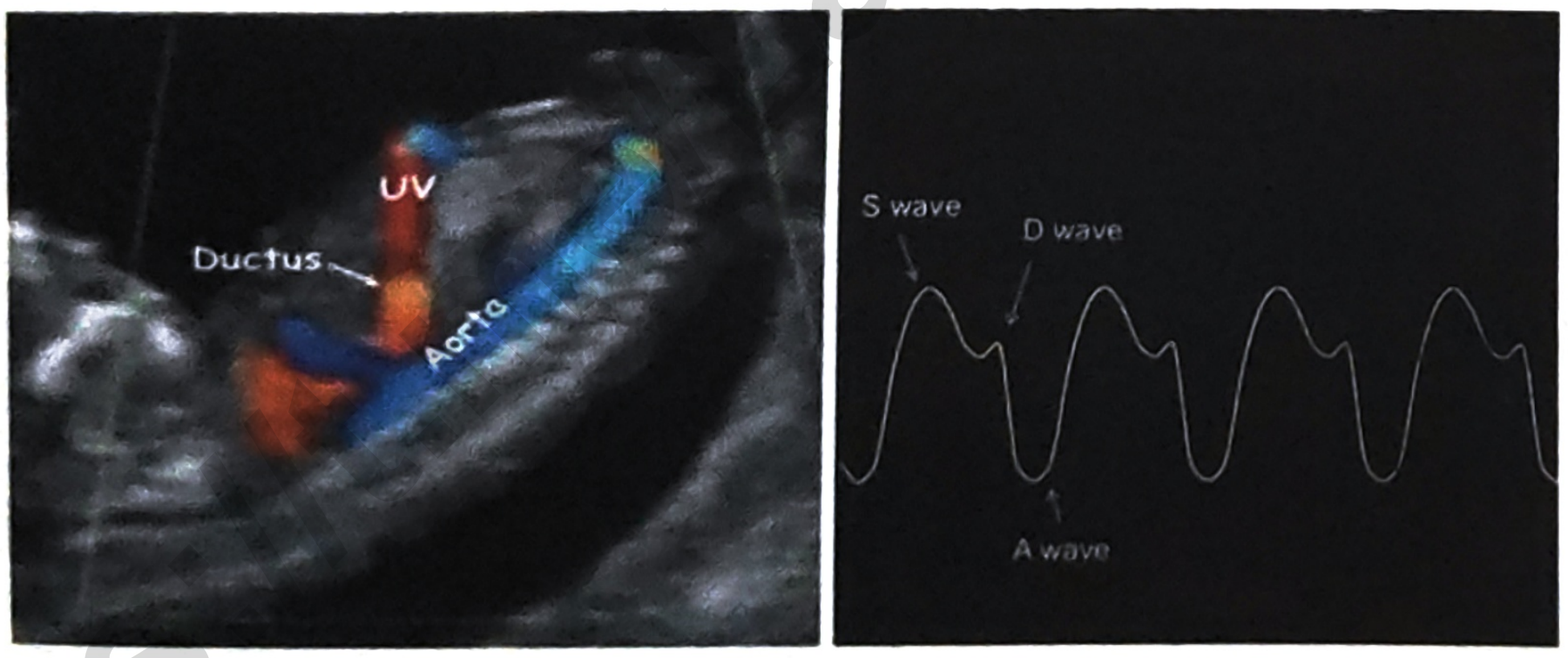

→ In a normal physiological situation flow should always be in the forward direction (i.e. towards the fetal heart).

S wave – Fetal Ventricular Systole

D wave – Fetal early Ventricular Diastole

A Wave – Atrial contraction

https://natestneetpgnotes

Abnormal Ductus Venous Waveform

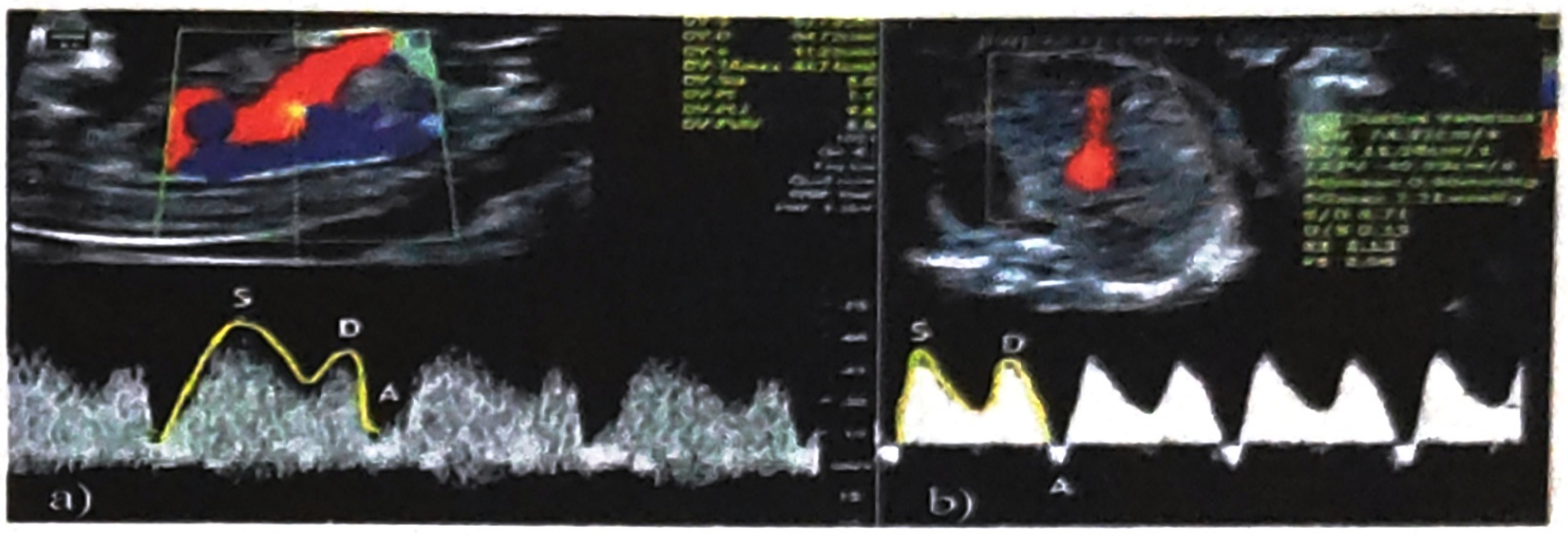

Normal — Reversal of A-Wave

Note:

→ In first Trimester – Aneuploidy

→ Second Trimester – IUGR

– Fetal cardiac Compromise

Nuchal Skin fold thickness scan

00:24:41

→ 2nd Trimester – 18-24 Weeks

→ › 6 mm – Soft marker of Aneuploidy

Nuchal Skin fold thickness scan

Soft Markers of Aneuploidy

→ Increased Nuchal Thickness › 6mm

→ Fetal ventriculomegaly › 10mm

→ Hypoplastic/absent nasal bone

→ Echogenic Intracardiac focus

→ Echogenic bowel

https://t.me/neetpgnotes

PrepLadder

Parameter	Significance
Crown –Rump Length (CRL)	Best parameter for gestational age in first trimester
Biparietal Diameter (BPD)	Best parameter for Gestational age in Second Trimester
Head Circumference(HC)	Used when shape of skull is variable instead of BPD
Femur Length (FL)	Best parameter for Gestational age in Third trimester
Abdominal Circumference (AC)	Best parameter for fetal growth

Crown rump length

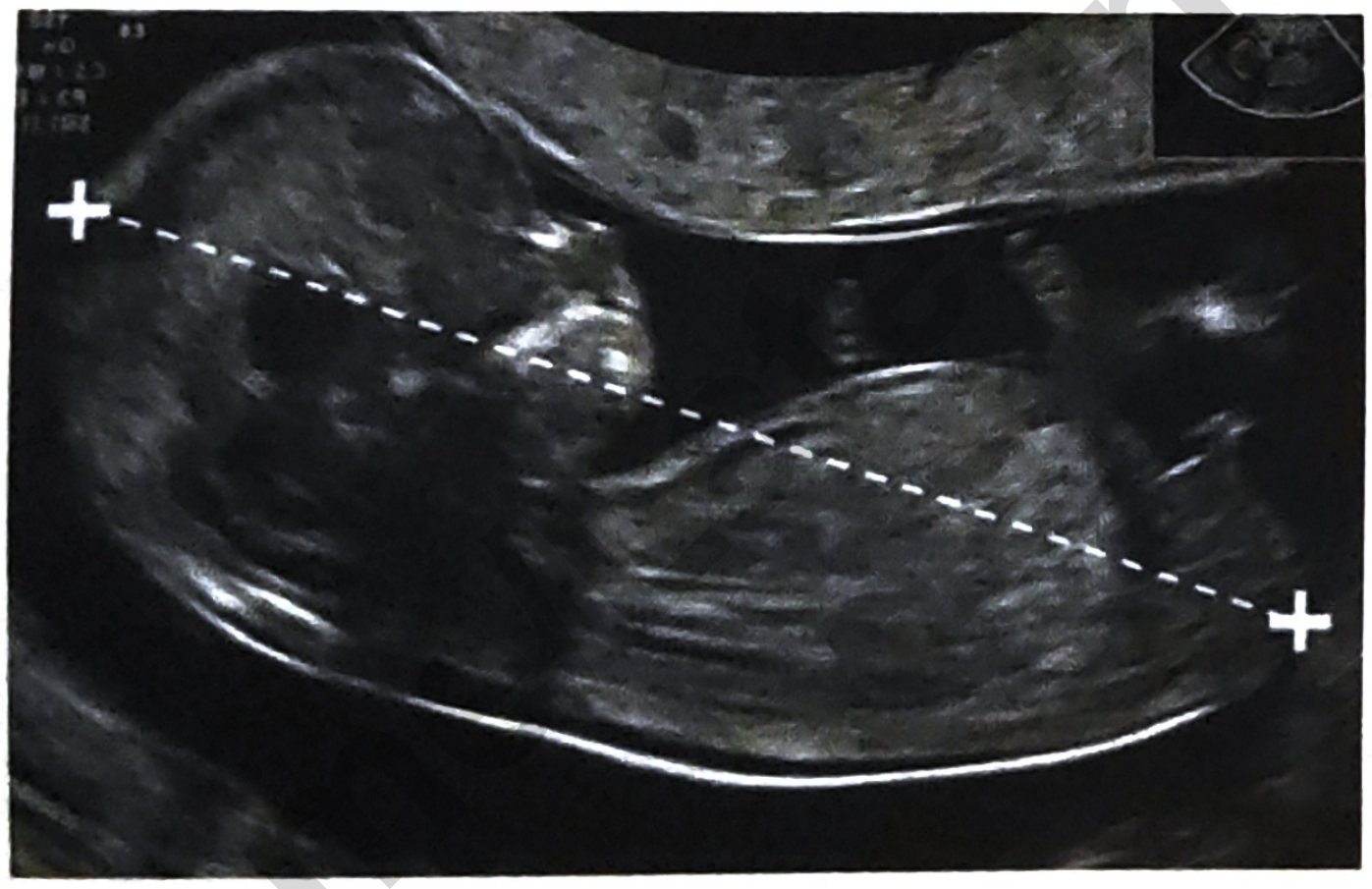

→ Largest Dimension of Embryo – Outer margin of Cephalic pole to rump of Embryo.

→ Excludes Yolk sac and extremities.

→ Primary measure of Gestational age between 6 weeks – 13 weeks + 6 Days (Till 84 mm)

→ The earlier the scan, the more accurate.

→ Cardiac activity should be present in an embryo with a CRL ≥ 7 mm.

Biparietal Diameter

→ Best Parameter for Gestational age between 14- 20 weeks in second Trimester

https://t.me/neetpgnotes

→ HC more reliable than BPD when shape of skull is variable like dolichocephaly or brachycephaly

→ BPD together with HC,AC, and FL are computed to produce an estimate of fetal weight

→ BPD measured on axial plane traversing thalami and cavum septum pellucidum

→ Cerebellum and orbits should not be there

→ Measure outer edge of near calvarial wall to inner edge of far calvarial wall in the widest part

→ Head circumference from outer aspect at same plane

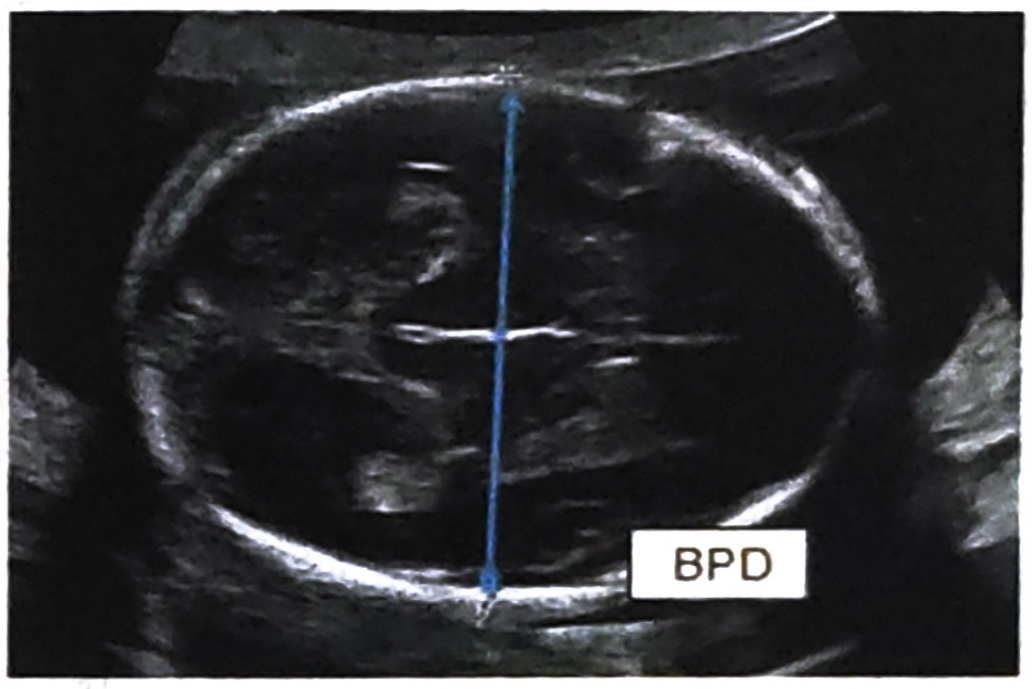

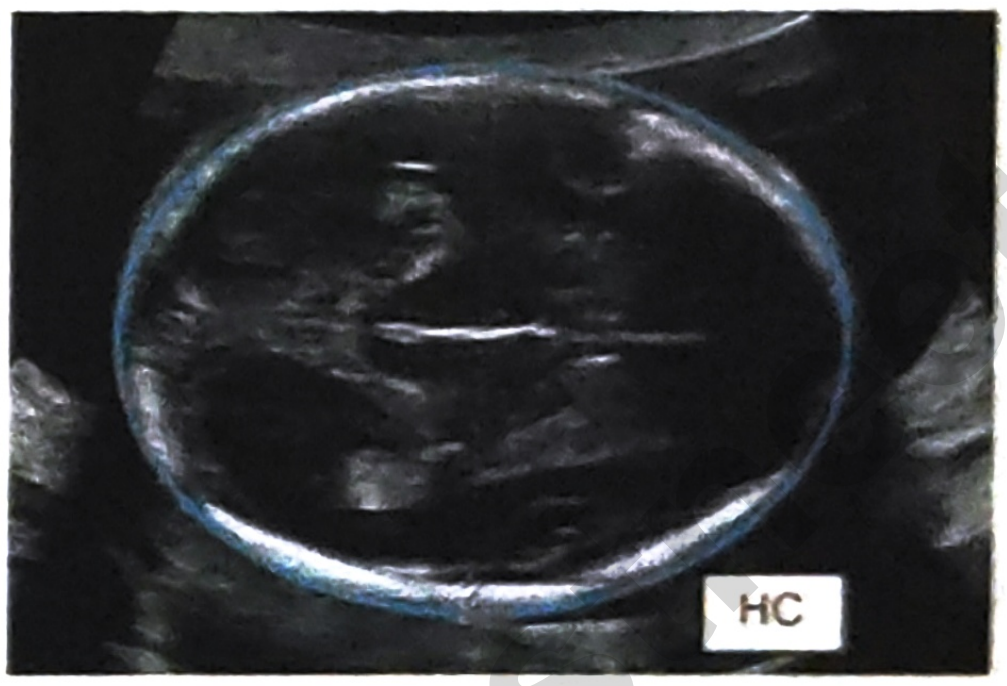

Transcerebellar Diameter (TCD)

→ Additional fetal biometric parameter

→ TCD in mm is considered roughly equivalent to gestational age in week

→ TCD is not significantly altered in presence of IUGR.

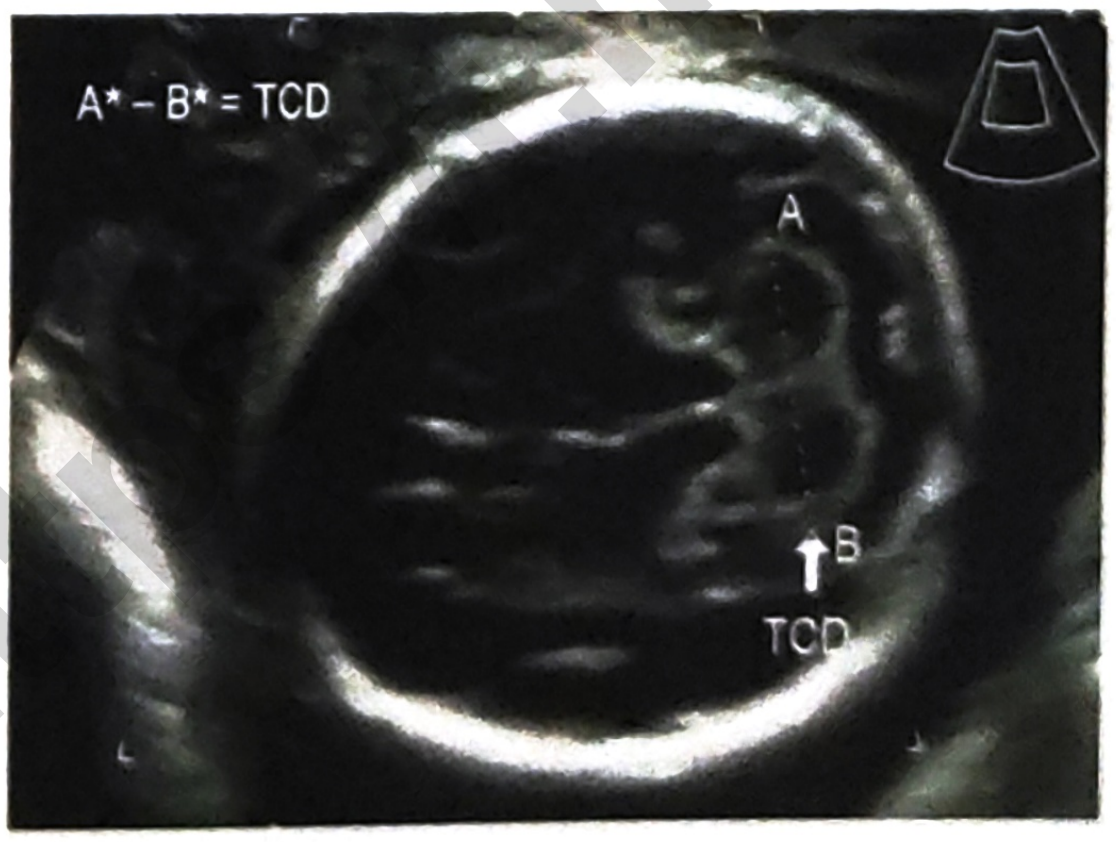

Transcerebellar Diameter

https://t.me/Latestpgnotes

PrepLadder

Femur length

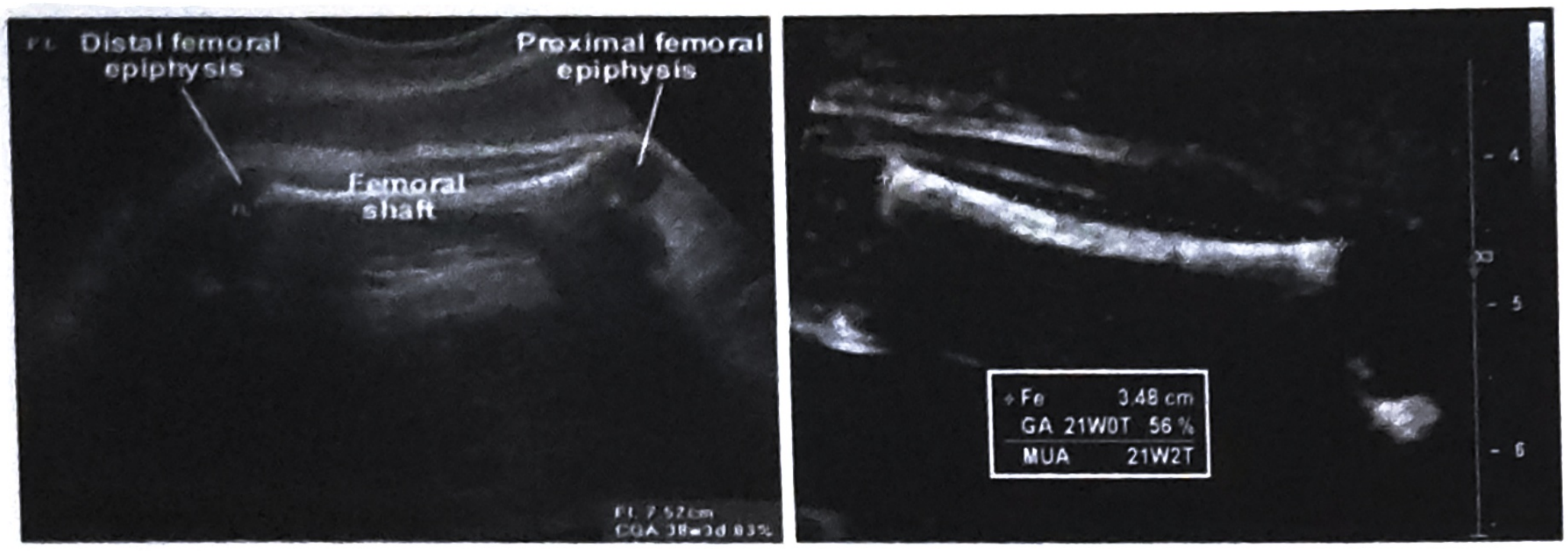

- → Best for Gestational Age in Third Trimester
- → Short femur can be normal or a soft marker of Aneuploidy /trisomy 21 or skeletal dysplasia
- → Calipers measure only ossified bone
- → Should not contain the femoral head

Note:

THANATOPHORIC DYSPLASIA

- → Telephone handle appearance of femur
- → Micromelia with bowed femur

Abdominal Circumference

- → Single best ultrasound marker for fetal growth for Macrosomia and IUGR
- → Less predictive for Gestational Age
- → Transverse section through upper abdomen
- → Should show fetal stomach, umbilical vein and portal sinus(hockey stick appearance)
- → Calipers on skin surface
- → Cord insertion and kidneys should not be seen

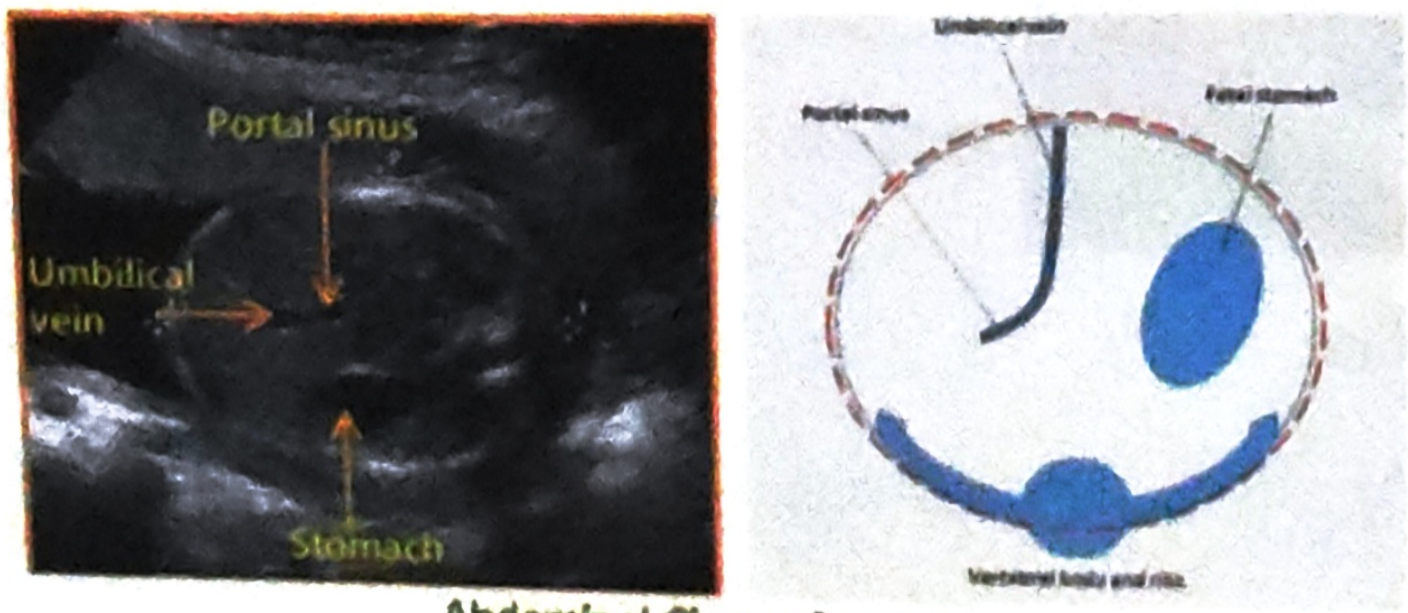

Abdominal Circumference

https://t.me/Latestneetpgnotes

λ Sign	T Sign
Thick intervening septa in between two Gestation.	Thin intervening septa in between two Gestation.
Dichorionic Diamniotic Twin	Monochorionic, Diamniotic Twin
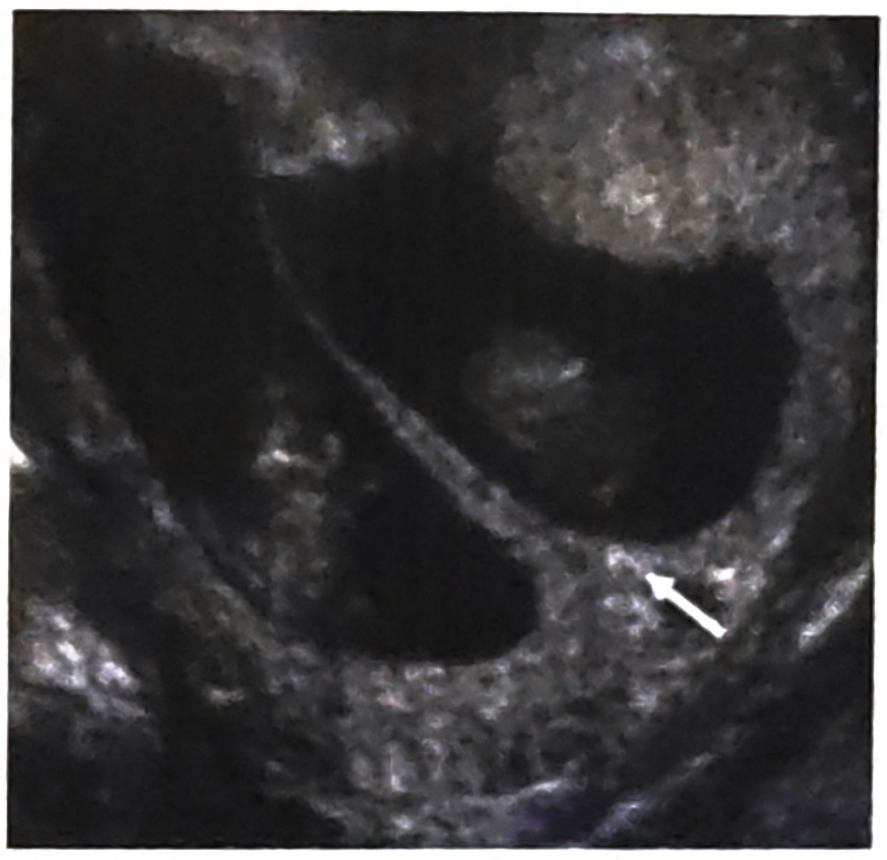	
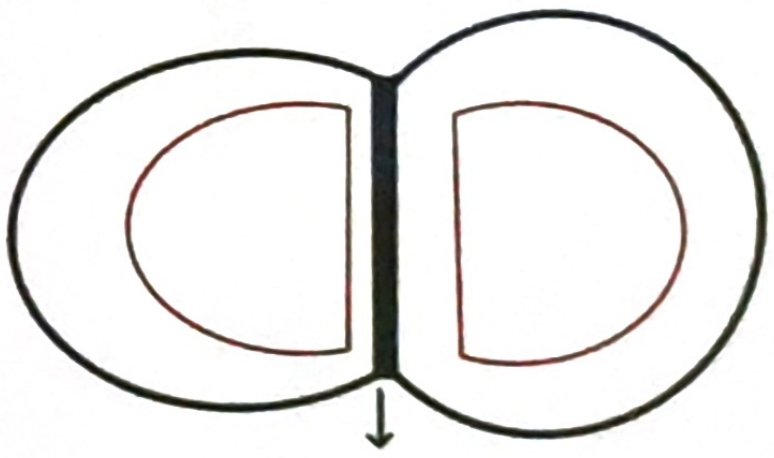 λSign→DC, DA	 → T sign ↓ MC,DA

https://t.me/Latestmetpgnotes

Posterior Urethral Valve

→ Prominence of posterior urethral valve with Distended Urinary bladder

→ "Key hole appearance"

Key hole appearance

PrepLadder

Intrauterine Death

00:40:32

Spalding Sign

→ Overlapping of Sutural Bones

→ Indicative of Intrauterine Death.

Robert Sign

→ Air within the great vessels & heart

→ Indicative of Intrauterine Death.

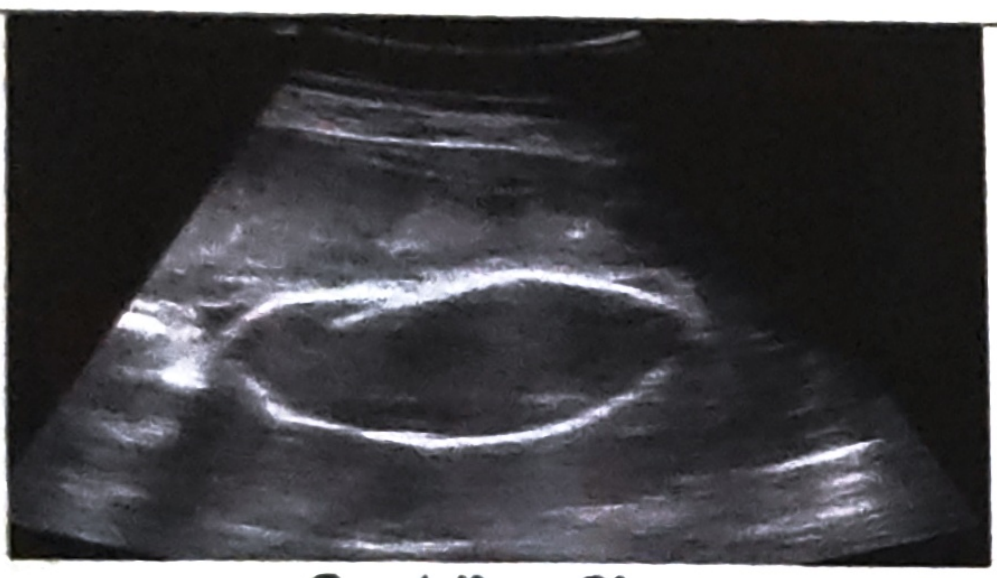

Spalding Sign

Robert Sign

Chambers of Heart

00:42:21

→ Identify the spine

→ Posterior most chamber – Left atrium

→ Anterior most chamber – Right ventricle

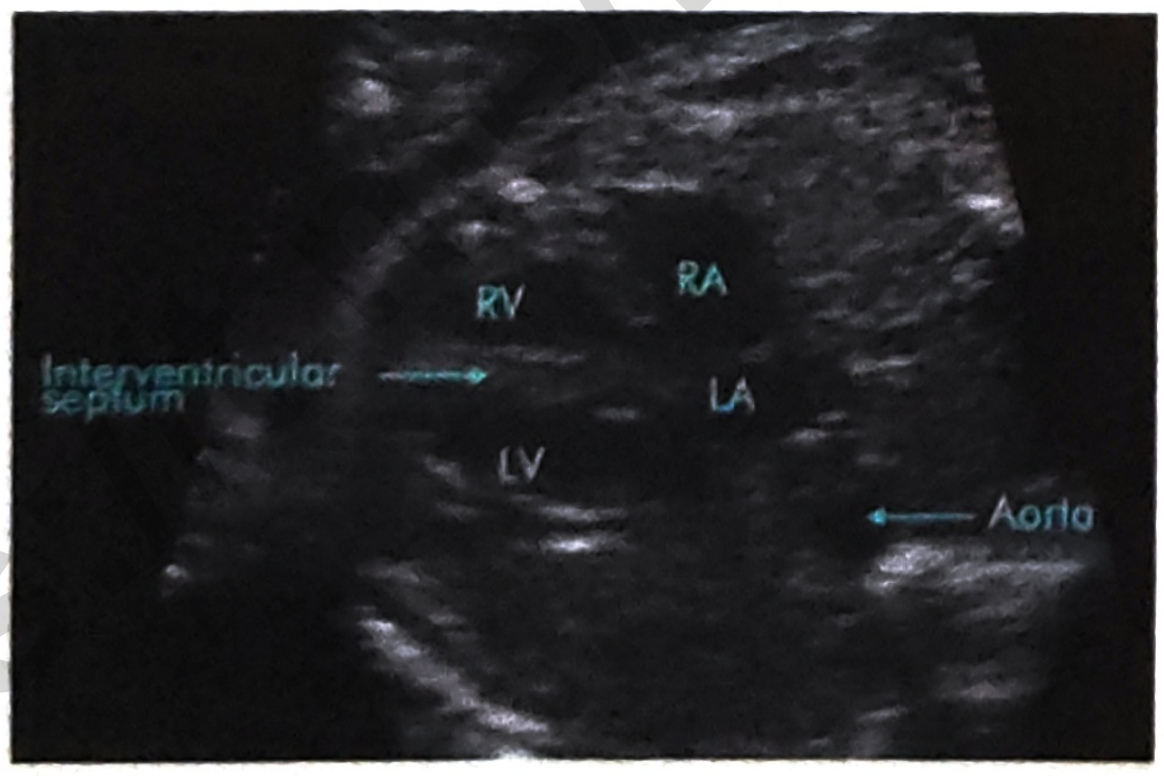

Chambers of Heart

Anencephaly

00:43:43

→ Earliest congenital anomaly

→ Can be Diagnosed as early as 10-11 weeks

→ Failure of closure of anterior neuropore.

→ Acrania – Absent skull vault.

→ Orbits appear superiorly – Frog eye appearance/ Mickey mouse appearance

Anencephaly

Encephalocele

→ Cranial defect

→ Brain & meninges herniate through Cranial defect

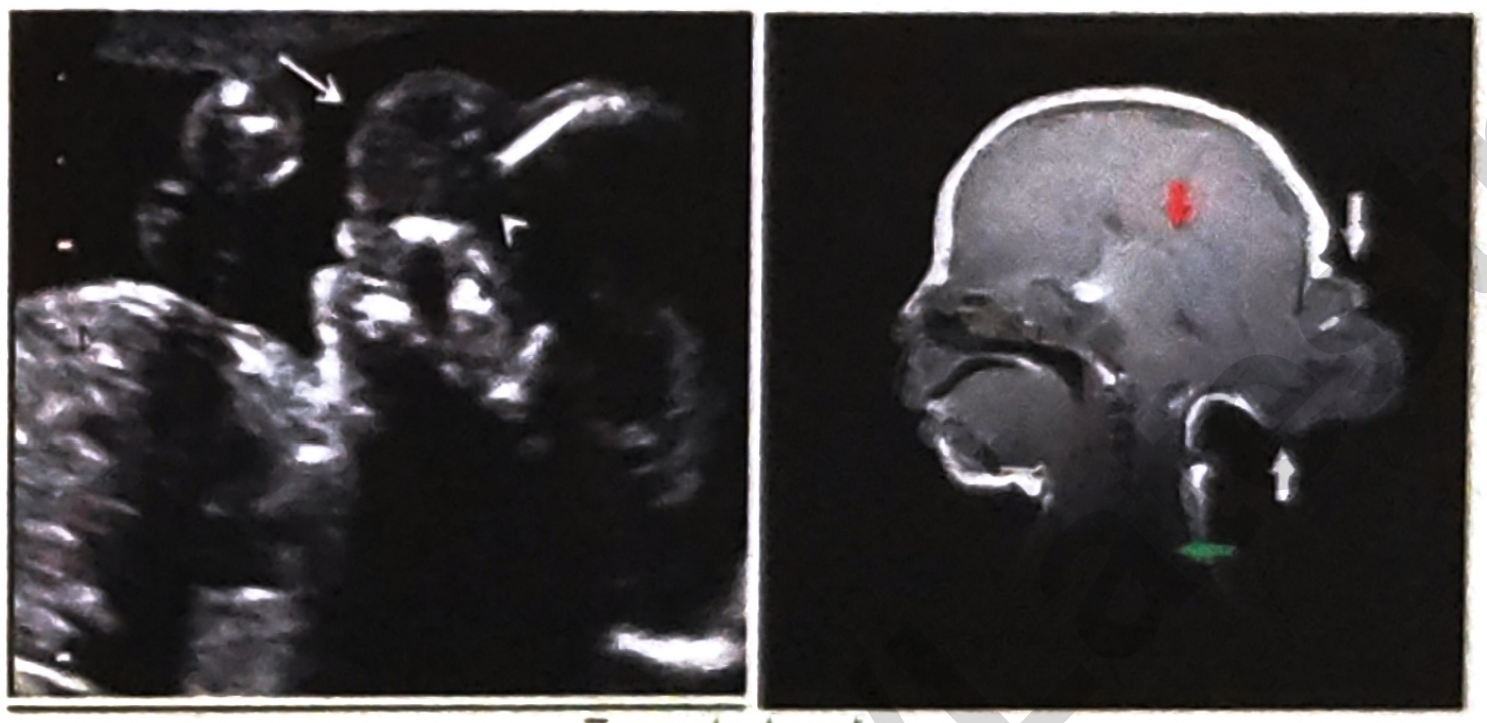

Encephalocele

Omphalocele Vs Gastroschisis 00:46:07

→ Usually Diagnosed in 2nd Trimester

Omphalocele	Gastroschisis
→ Herniation of Abdominal contents covered with Shiny membrane	→ Herniation of Abdominal contents without any covering
→ Umbilical cord – At the apex	→ Umbilical cord – Herniation located at the right of Umbilical cord.
→ Association with other congenital anomalies – More common	→ Association with other congenital anomalies – Less common

https://t.me/ neetpgnotes

PrepLadder

Omphalocele

Gastroschisis

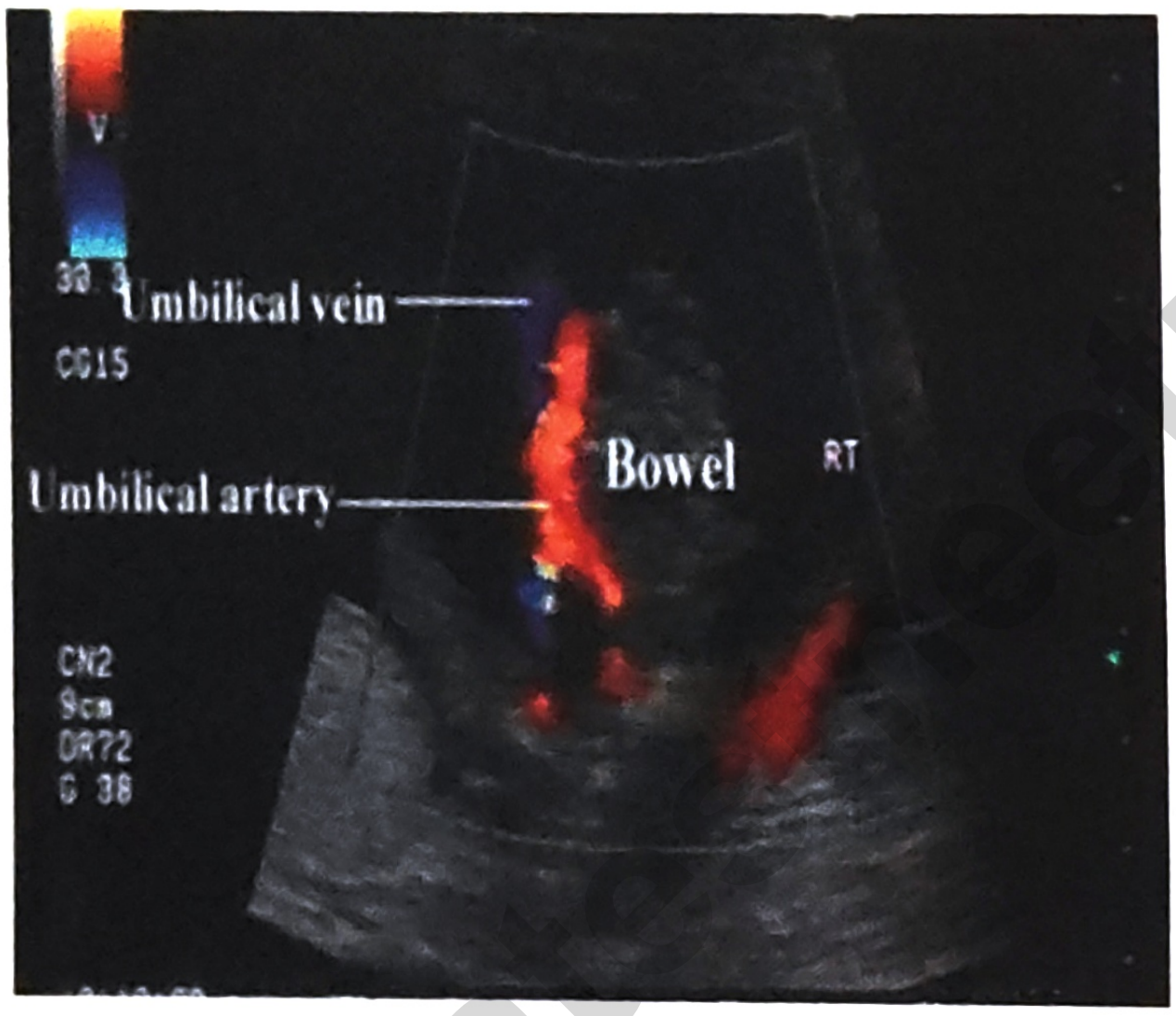

Gastroschisis

Spina bifida

00:47:55

- → Herniation of spinal cord contents through the Defect in spine.
- → Depending on the content, it is named as Meningocele or Myelomeningocele

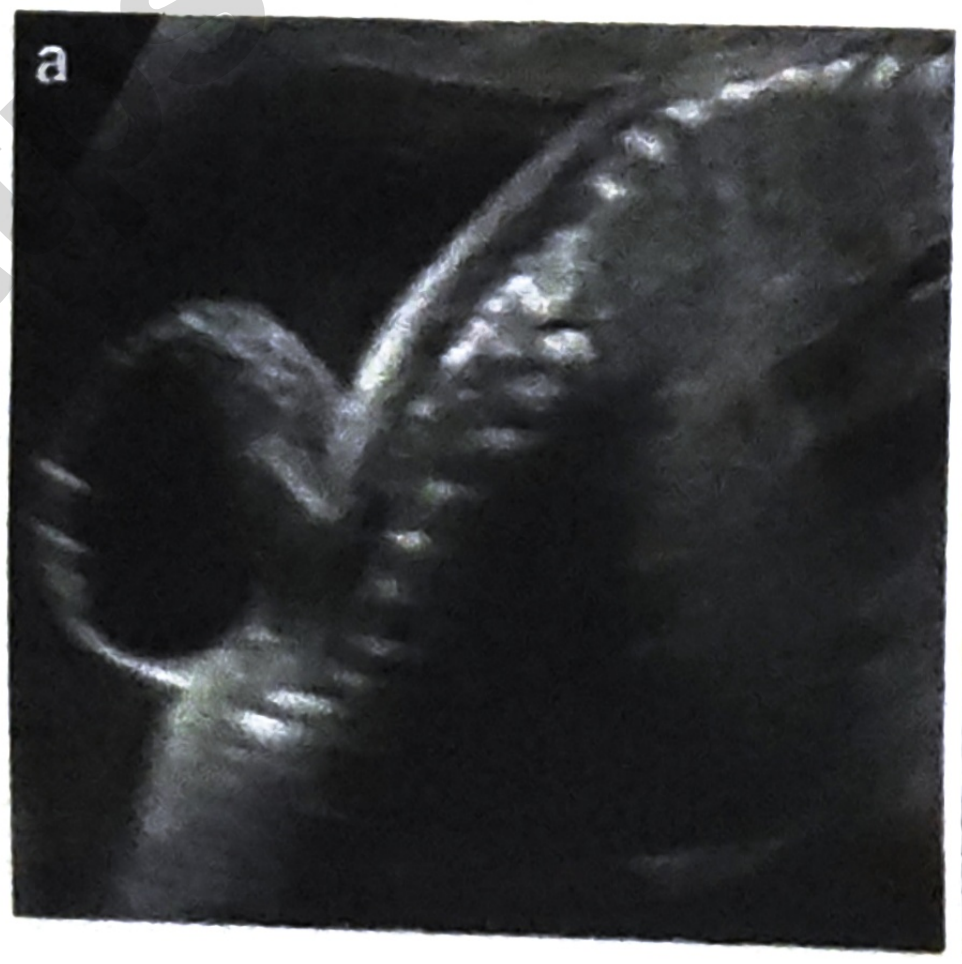

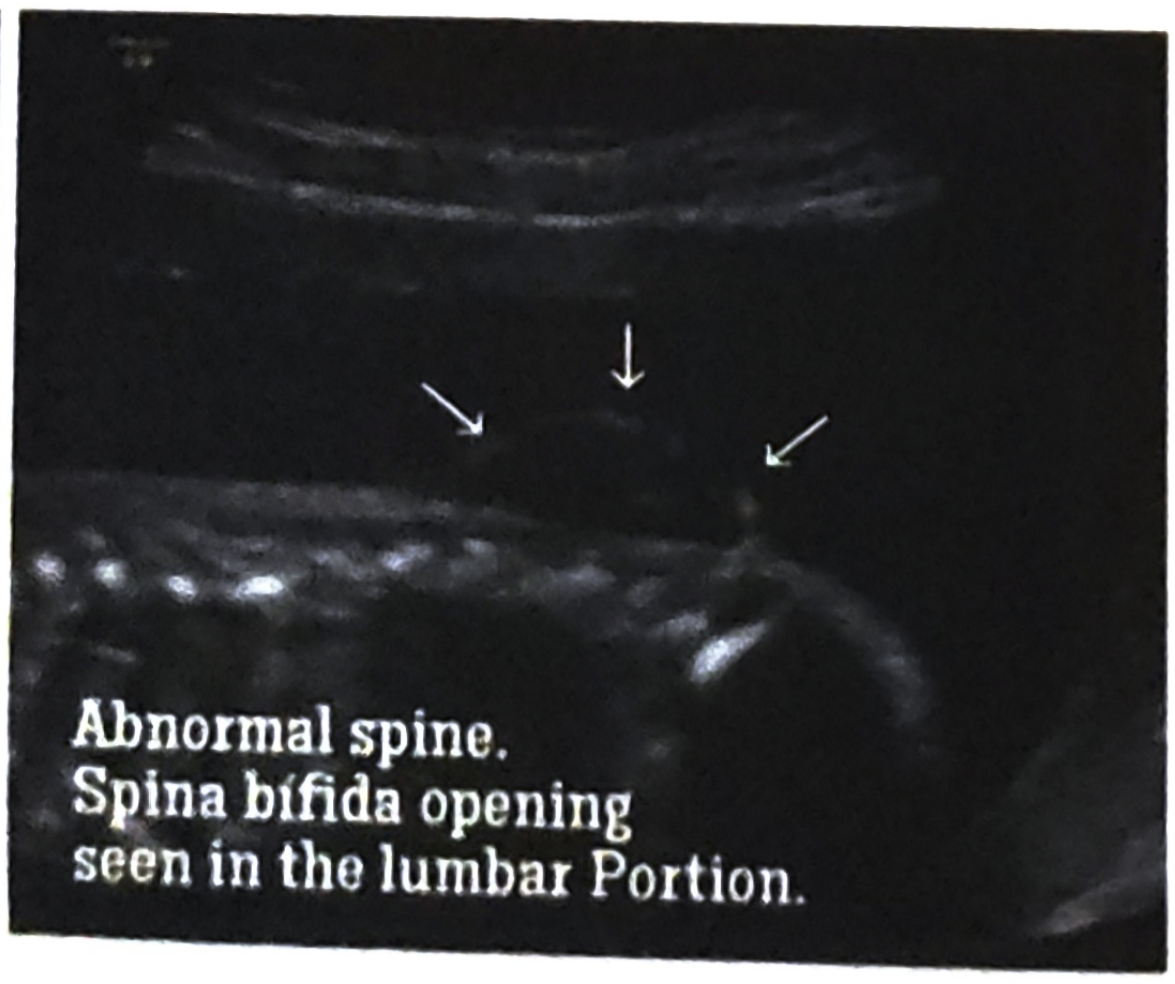
Abnormal spine.
Spina bifida opening seen in the lumbar Portion.

https://t.me/Latestpgnotes

Chapter 12

MAGNETIC RESONANCE IMAGING (MRI) PART 1

Basics of MRI

00:00:28

- → Medical MRI was developed by - Paul Lauterbur & Mansfield
- → Principle of MRI - NMR (Number Magnetic Resonance) was given by Felix Bloch & Purcell
- → MRI is based on - Gyromagnetic property of H^{+} ion
- → MRI has a special Magnet - Superconducting magnet (kept cold by Helium gas)
- → MRI also has a Radiofrequency coil - it produces Radio frequency wave known as RF pulse
- → MRI Gives Multiplanar image acquisition

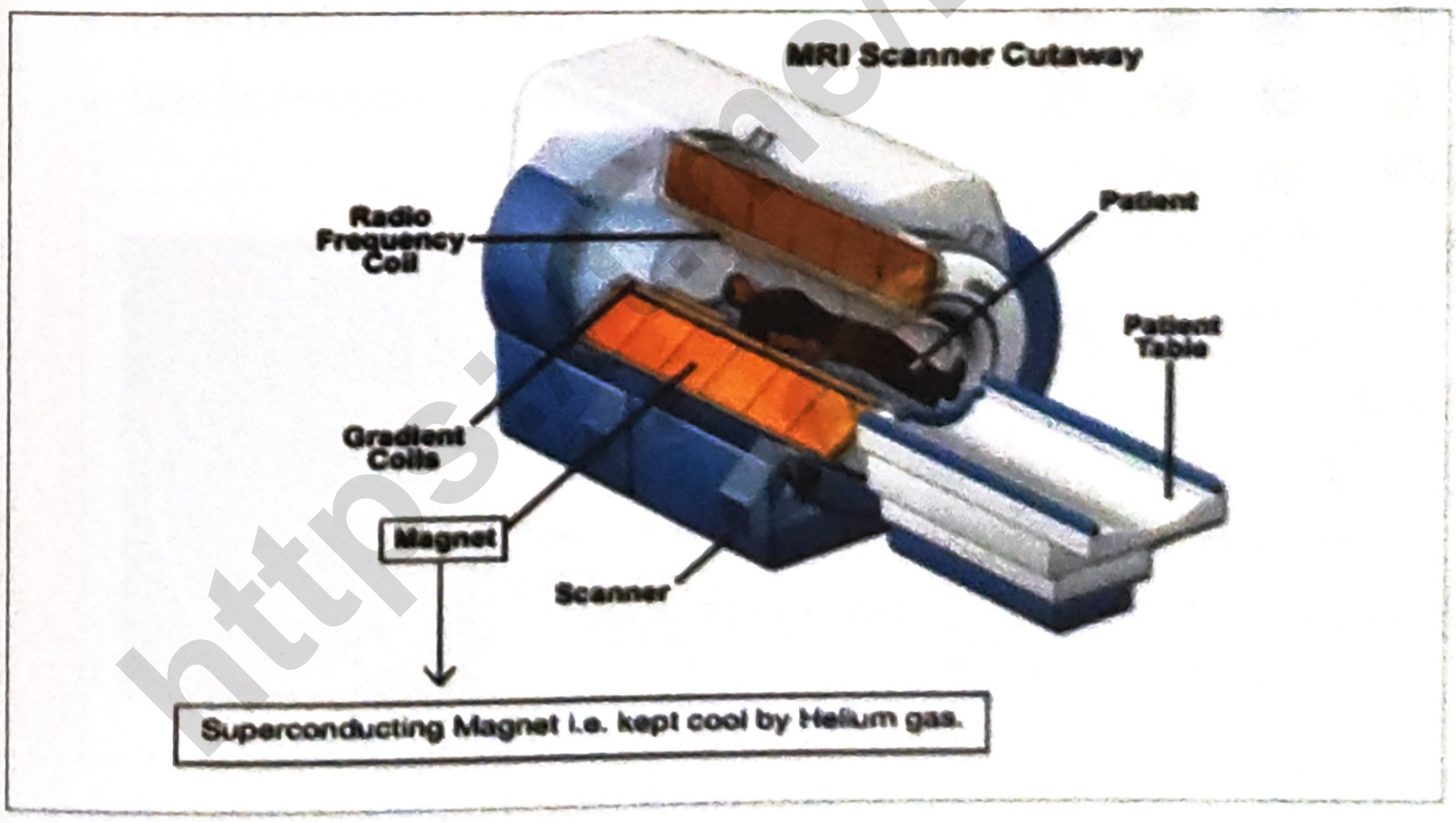

MRI SCANNER PARTS

https://t.me/Latestneetpgnotes

PrepLadder

For more free ebooks and notes, visit

https://t.me/Latestneetpgnotes

Or click this page to join

MRI working mechanism

- → In body H+ ions are present in water, fatty acids & organic acids in varying amount which are randomly arranged with no net magnetization
- → These H^+ ions when exposed to a strong magnet (1.5 T or 3 T magnet) starts aligning according to the original magnet
- → When RF pulse is given, using the energy of this pulse the H^+ ions are deflected to Transverse axis
- → On stopping RF pulse the H^+ ions in transverse axis tends to relax back to longitudinal axis
- → This Relaxation time is different for water (relax faster) & fatty acids (relax slowly). By this mechanism the signal obtained from water & fatty acids can be differentiated and studied

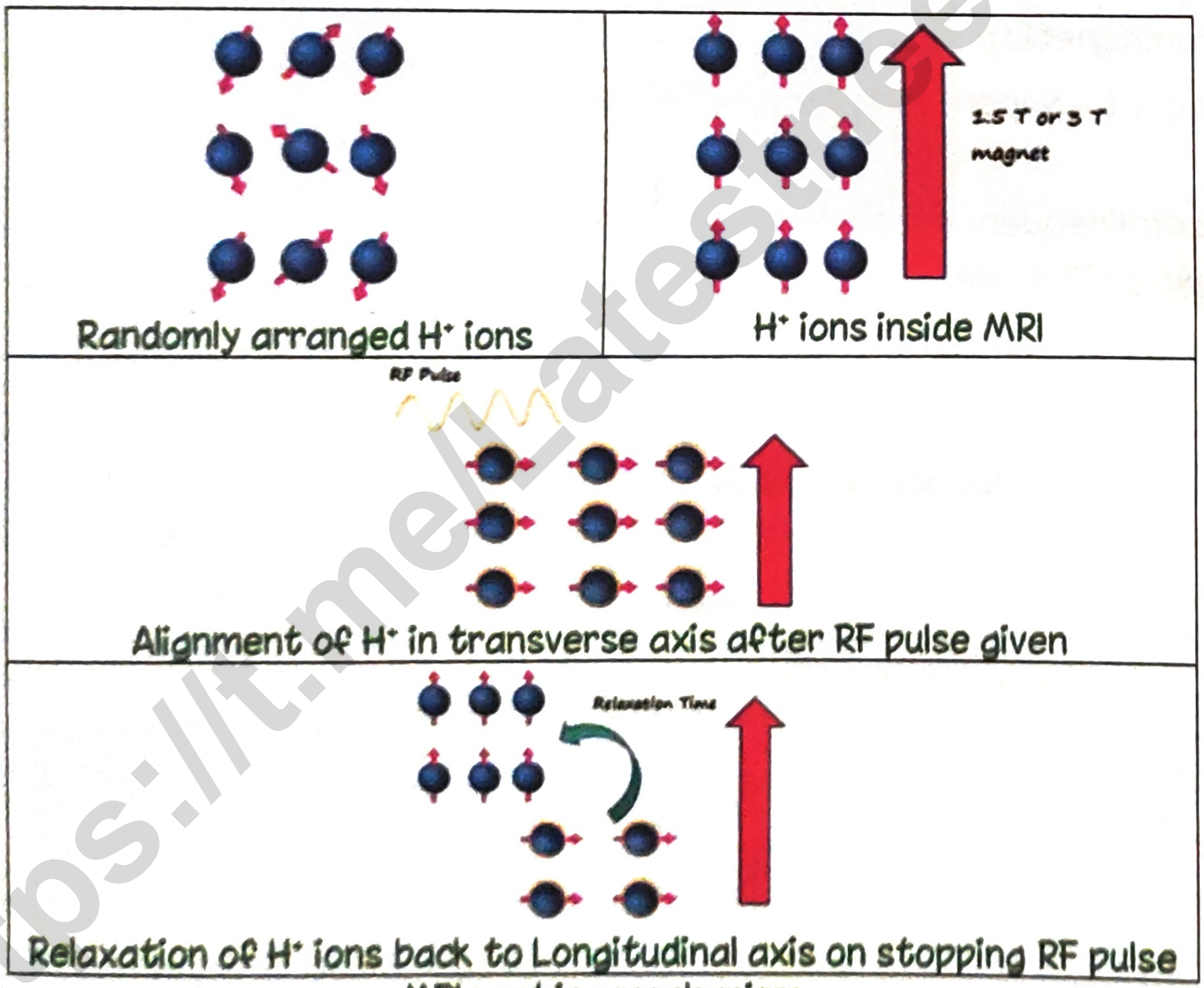

MRI working mechanism

Note:

- → T_1 – to look anatomy
- → T_2 – to look for Pathology (Water appears white on T_2)
- → Most pathologies are HYPOINTENSE on T_1 and HYPERINTENSE on T_2

https://t.me/Latestneetpgnotes

→ Hyperintense on T_1w

- Fat e.g. lipoma
- Proteinaceous substance
- Subacute Hemorrhage (meth Hb stage)
- Melanin
- T_1 hyperintense metastasis is MELANOMA (most of the metastasis are hypointense in T_1)
- Gadolinium (paramagnetic substance)

→ Structures that are Hypointense / dark on both T1 & T2

- Air
- Bone
- Calcification
- Dense fibrous tissues (E.g. ligaments, tendons)
- Flowing blood

Cine MRI

- Most accurate investigation for Cardiac ventricular function

→ T_1 weighted image (for anatomy)

- CSF → Hypointense
- Grey matter → black
- White matter → white

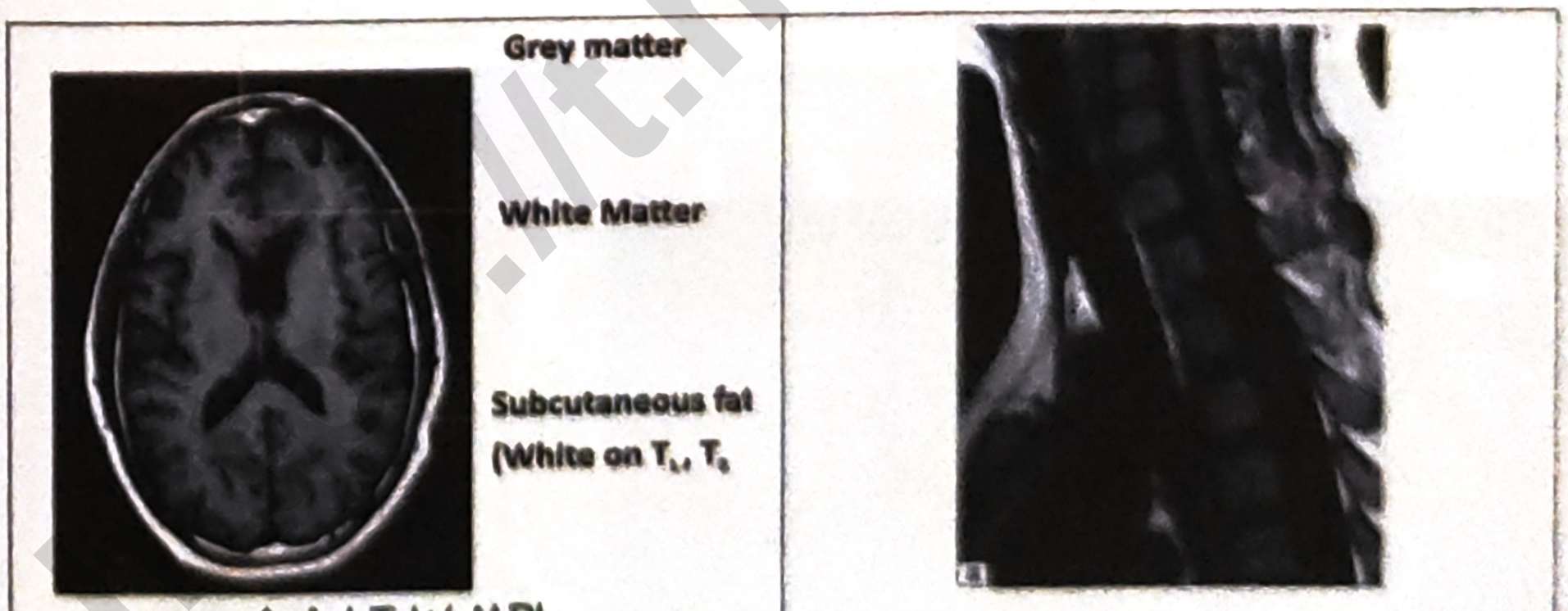

Axial T_1W MRI

→ T_2 weighted image (for pathology)

- CSF → Hyperintense
- Grey matter → white
- White matter → black

http://t.me/Latestneetpgnotes

PrepLadder

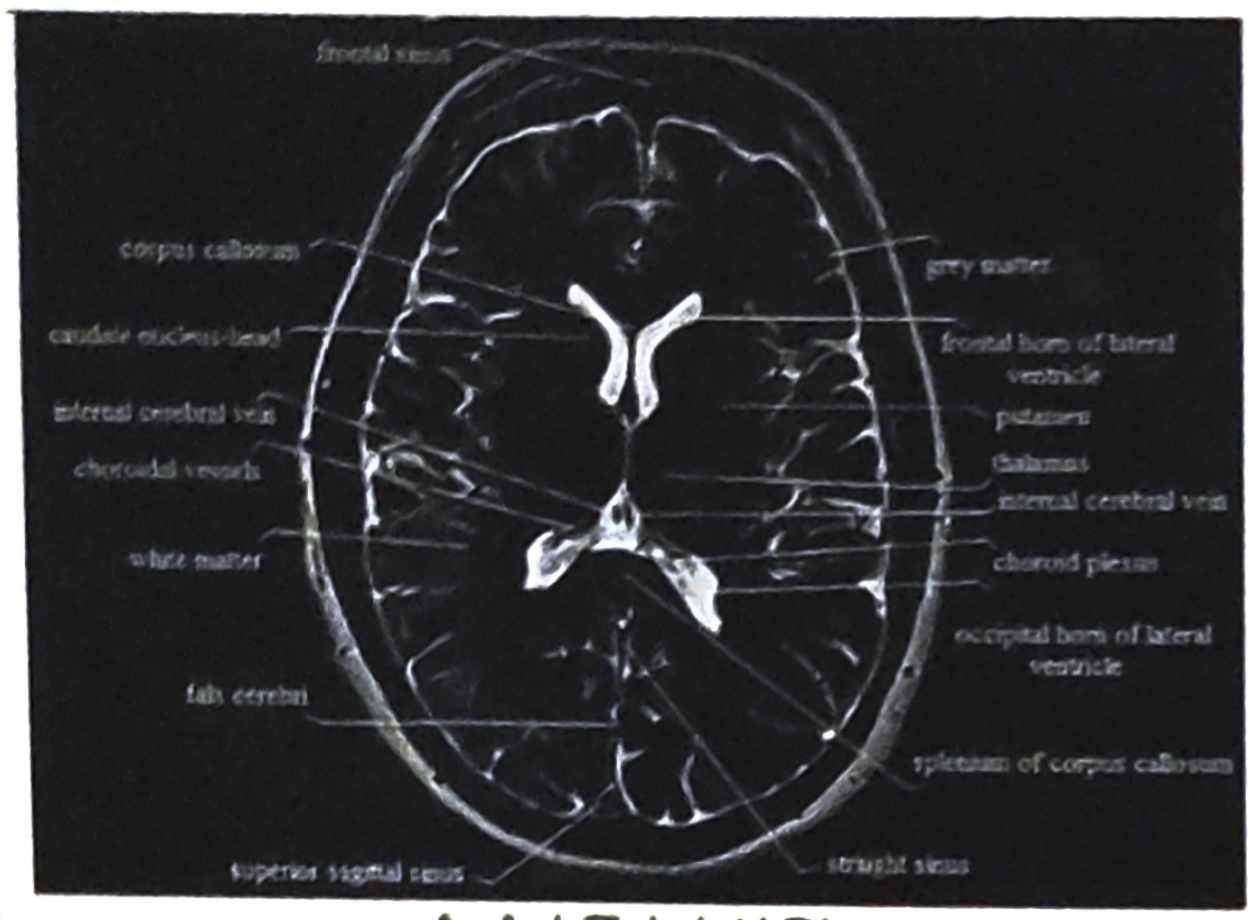

Axial T_2W MRI

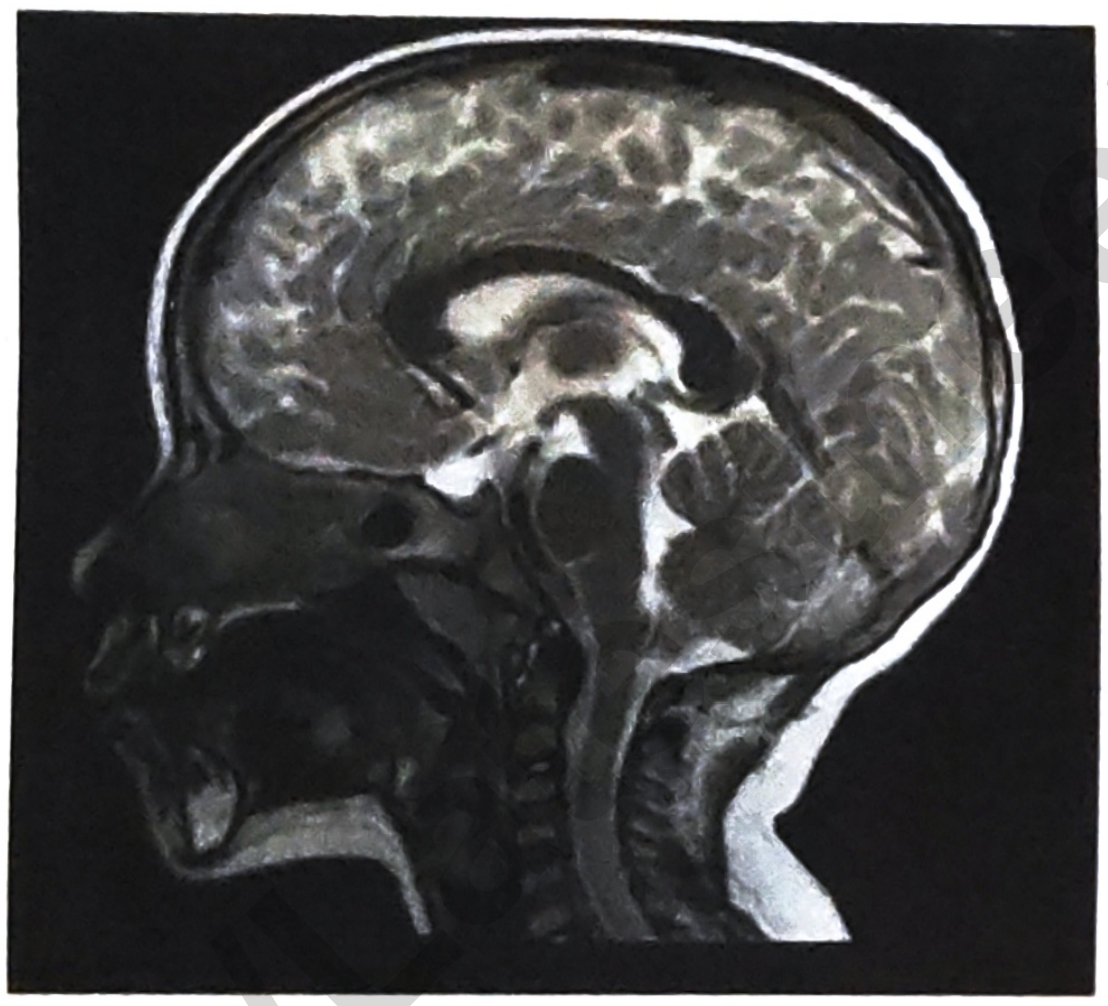

Sagittal T_2W – MRI

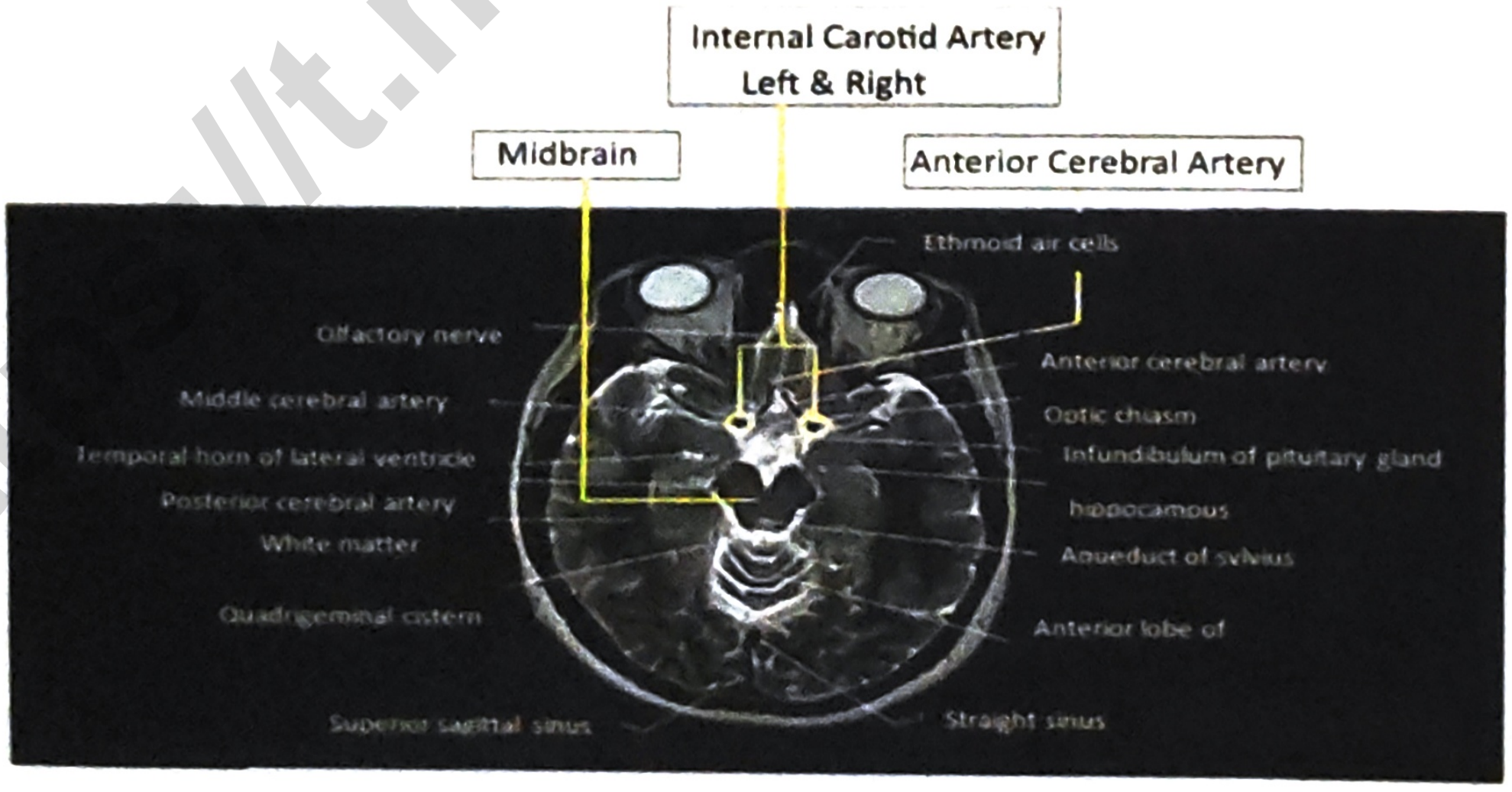

Axial T_2W – MRI at level of Orbit

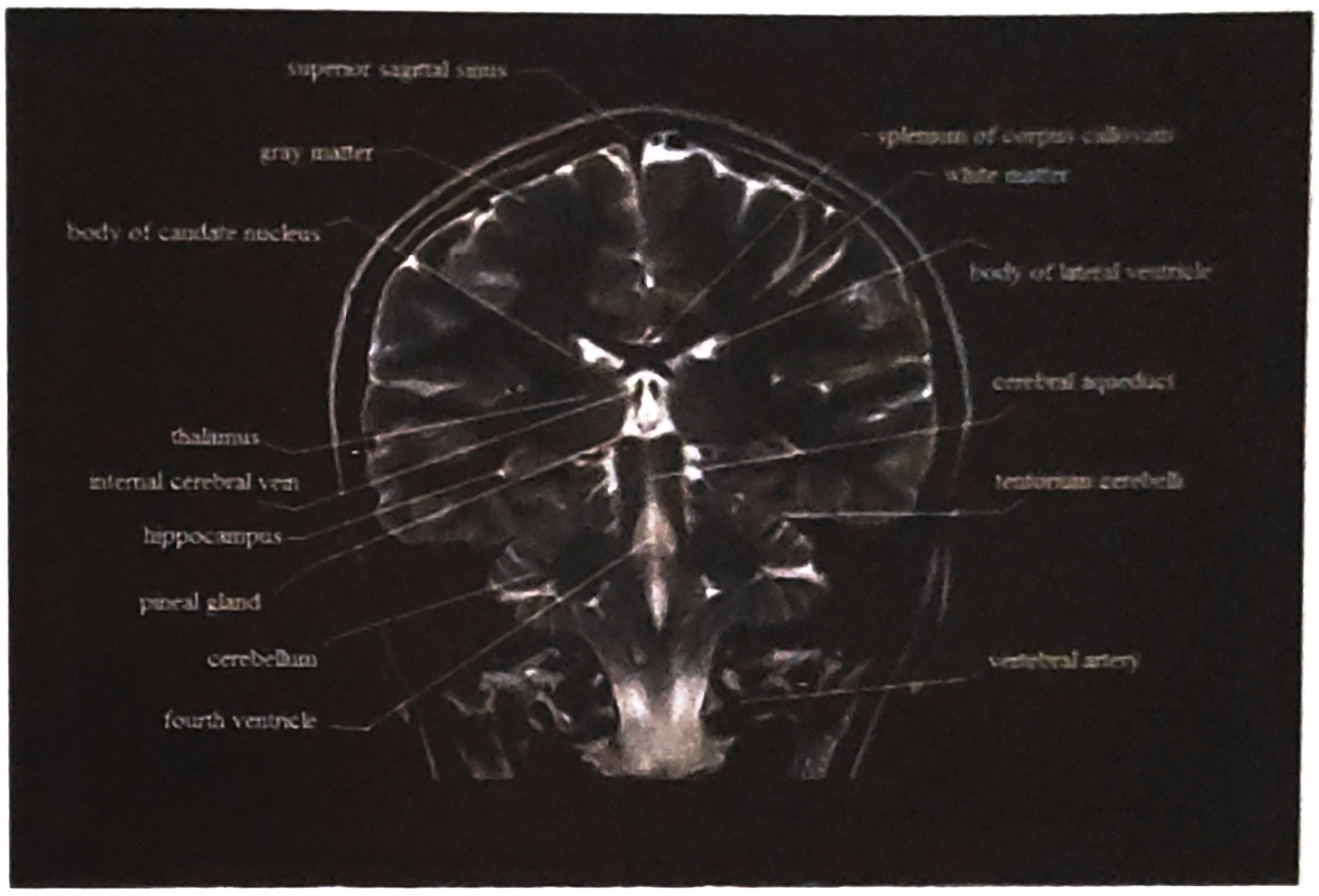

Coronal T_2W - MRI

Sagittal - MRI

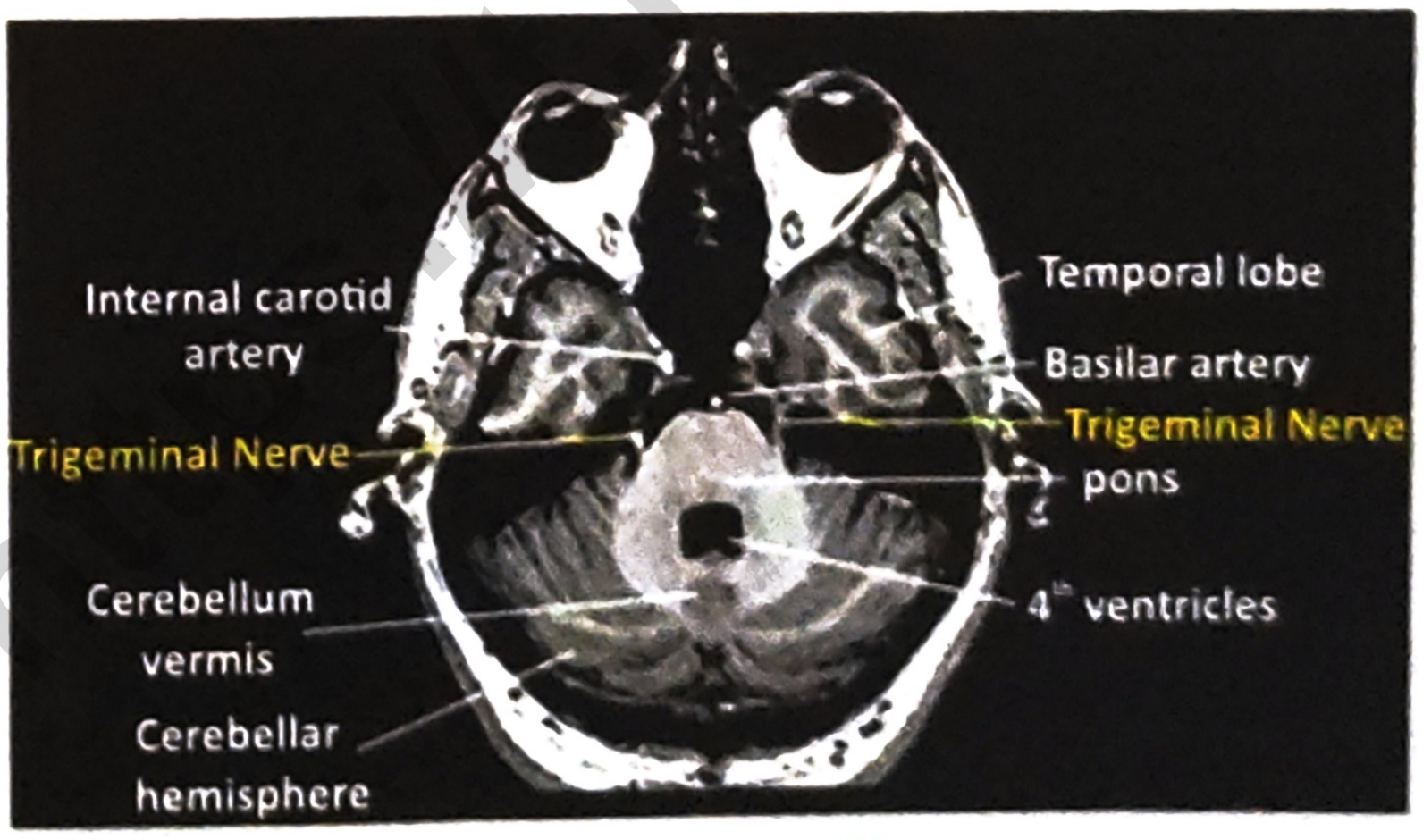

Axial T_1W MRI

PrepLadder

→ Hippocampus

- Better seen on Oblique coronal MRI
- Hippocampal atrophy can occur in two conditions

In Dementia case → Alzheimer

In Epilepsy case → Mesial temporal sclerosis

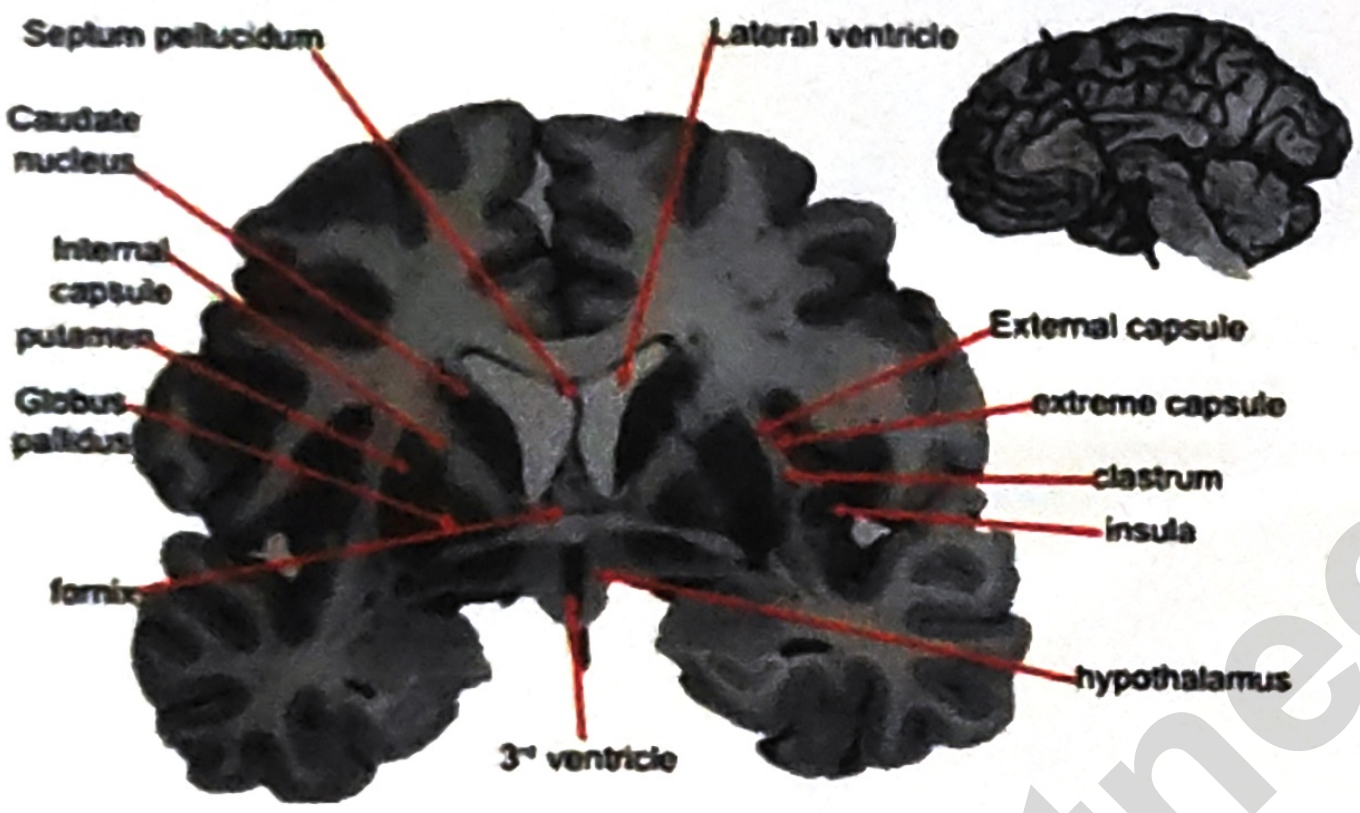

→ Parinaud syndrome

- It is a pineal gland tumors (Germinoma) compressing superior colliculus and causes vertical gaze palsy.

→ Faradays cage

- It is a copper containing cage in which MRI is kept
- It prevents electromagnetic interference in MRI room
- Also used in EEG room



Faradays cage

FLAIR – MRI (Fluid Attenuation Inversion Recovery) 00:06:34

→ It is a Fluid suppressing sequence

→ It is Similar to T_2 with fluid suppression. In FLAIR

- CSF → Hypointense
- Grey matter → white
- White matter → Black

https://t.me/Latestneetpgnotes

→ FLAIR MRI is used

- To evaluate brain edema
- To evaluate Periventricular hyperintensities (feature of Multiple sclerosis)
- Best sequence to diagnose plaques of MS

→ Multiple Sclerosis has involvement of

- Corpus Callosum
- Calloso septal interphase

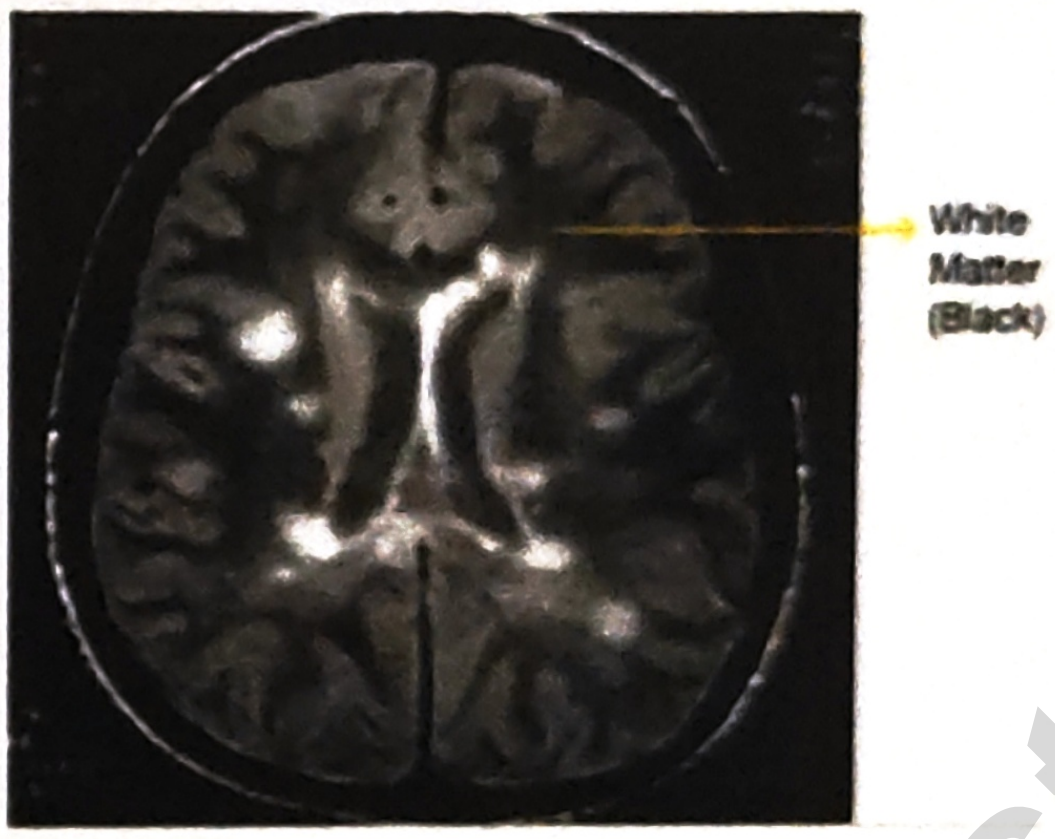

FLAIR MRI of multiple sclerosis (MS)

STIR – MRI (Short Tau Inversion Recovery) 00:07:38

→ It is a Fat suppressing sequence

→ Fat appears Hypointense (fat is hyperintense in both T_1 & T_2)

→ STIR – MRI is used

- To evaluate Bone marrow edema
- In evaluation of Ankylosing spondylitis, Avascular necrosis, Acute osteomyelitis etc.
- STIR MRI is the IOC for Ankylosing spondylitis

Diffusion Weighted MRI 00:09:13

→ It is based on Brownian movements (random free movement of molecules)

→ When there is Diffusion restriction DW-MRI gives bright signal and has low Apparent Diffusion Coefficient (ADC value)

→ DW-MRI detects Cytotoxic edema before a Vasogenic edema develops

https://t.me/Latestneetpgnotes

PrepLadder

→ Lesions that shows Diffusion Restriction

- Infarct (acute infarct) – IOC is Diffusion Weighted MRI
- Abscess
- Medulloblastoma & other high cellularity tumors
- Epidermoid cyst

Note:

→ IOC for Stroke – NCCT

→ IOC for ischemic stroke – DW MRI

STROKE
↓
NCCT
→ Hemorrhagic stroke → Hyperdense
→ Ischemia stroke (Acute infarct)
  → Hypodense
  → Normal → DW – MRI (IOC)

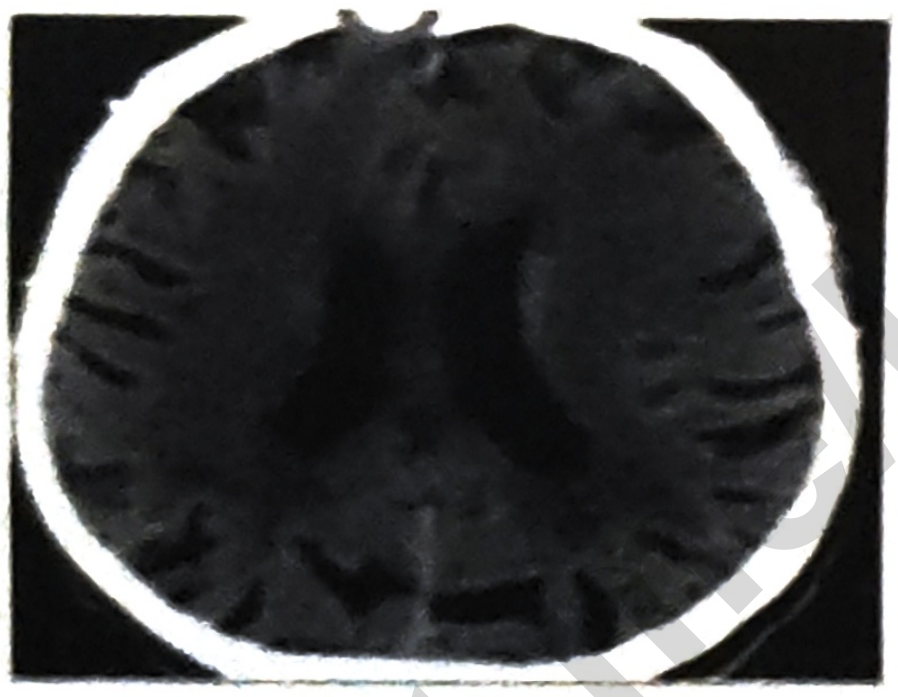

Acute infarct in CT – can appear normal



Acute infarct in DW-MRI

Diffusion Tensor Imaging

00:14:20

→ Also known as Tractography

→ Imaging technique to evaluate white matter tracks

→ It is based on Anisotropic movement

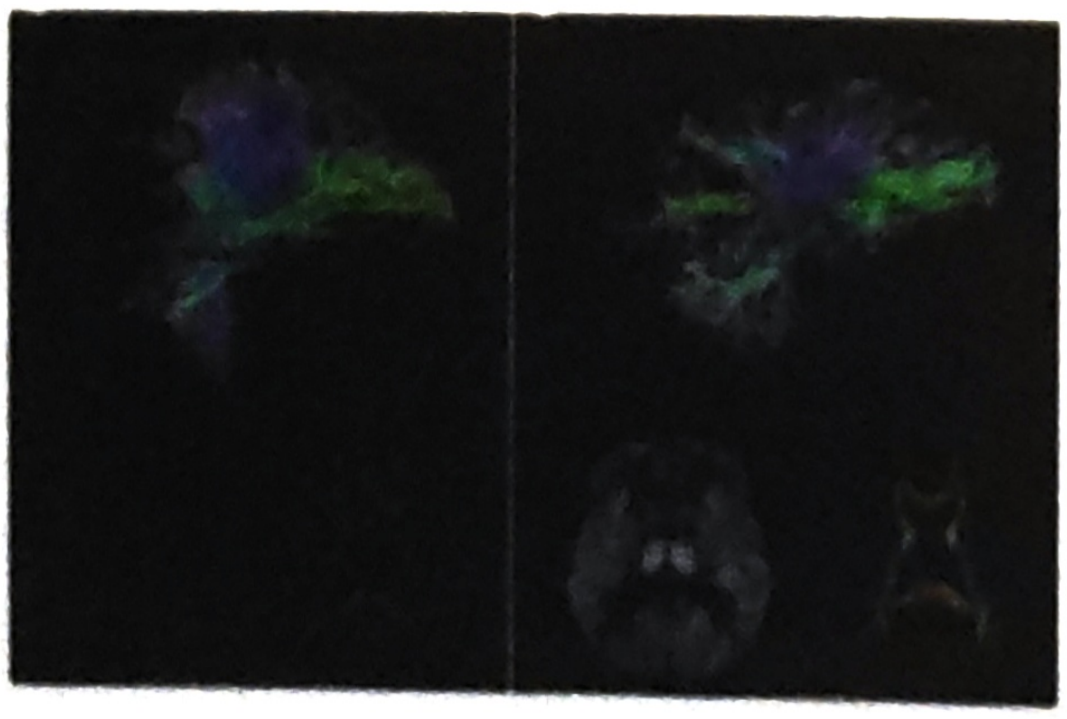

Tractography

https://t.me/Latestneetpgnotes

Prep

Functional MRI (fMRI)

→ It is Based on BOLD technique (Blood O_2 Level Dependent)

→ Used to evaluate

- Speech centre
- Fine motor areas
- Brain mapping

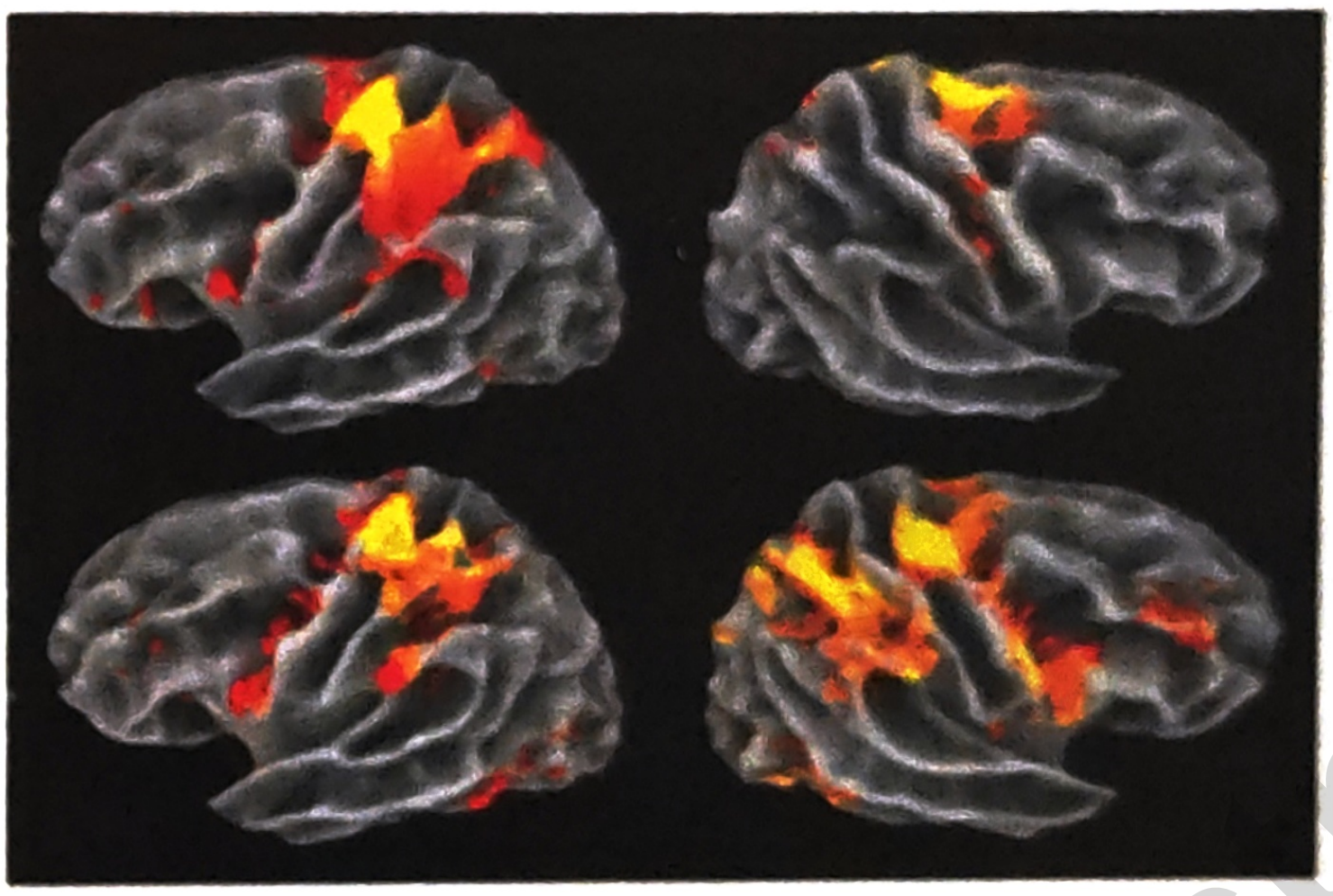

Functional MRI

MR- Spectroscopy

00:18:33

→ Used to evaluate chemical metabolites of a lesions

→ Spectroscopy normally shows

Chemical Metabolite	MR Frequency (parts per million (ppm))
• Lipid lactate	1 ppm
• N – acetyl aspartate (NAA)	2 ppm
• Creatine	3 ppm
• Choline	3.2 ppm
• Alanine	1.4 ppm

https://t.me/Latestneetpgnotes

PrepLadder

• Lipid lactate peak	→ Tuberculoma
• N-acetyl aspartate peak	→ Canavan's disease
• Choline peak	→ Tumors
• Alanine peak at	→ Meningioma

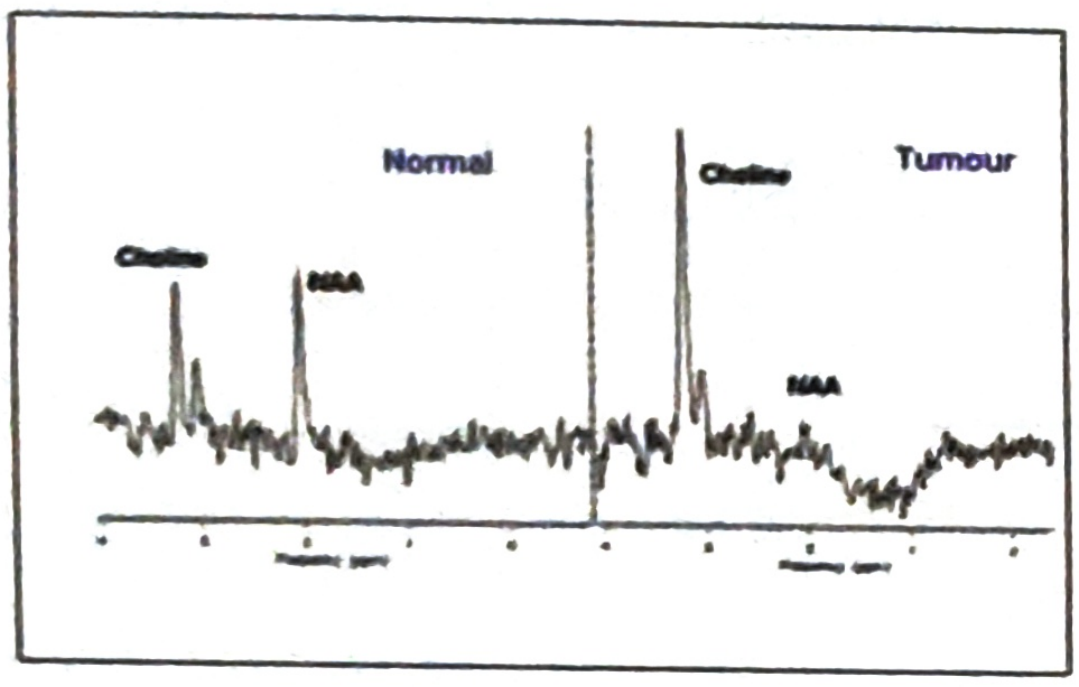

2ppm peak- NAA peak
Seen in Canavan's Disease.

https://t.me/Latestmedpgnotes

Chapter 13

MRI -Part 2

Basic sequence of MRI

→ Spin- Echo sequence

00:00:18

T_1 weighted	T_2 weighted
• It is the time taken to gain 63% of longitudinal magnetization.	• It is the time taken for 37% of transverse magnetization to be left (loss of transverse magnetization)
• T_1 happens in Z axis	• T_1 happens in X-Y axis
• Has Spin- lattice interaction	• Has Spin-spin interaction
• Has Short time to echo & Short time to repeat	• Has Long time to echo & Long time to repeat
• It mainly looks at anatomy	• It mainly looks at pathology
• CSF → Hypointense • Grey matter → Grey/black • White matter → white • Bone → black • Fat → white (more white on T_1 than T_2)	• CSF → Hyperintense • Grey matter → white • White matter → Grey/black • Bone → black • Fat → white

https://t.me/Latestneetpgnotes

PrepLadder

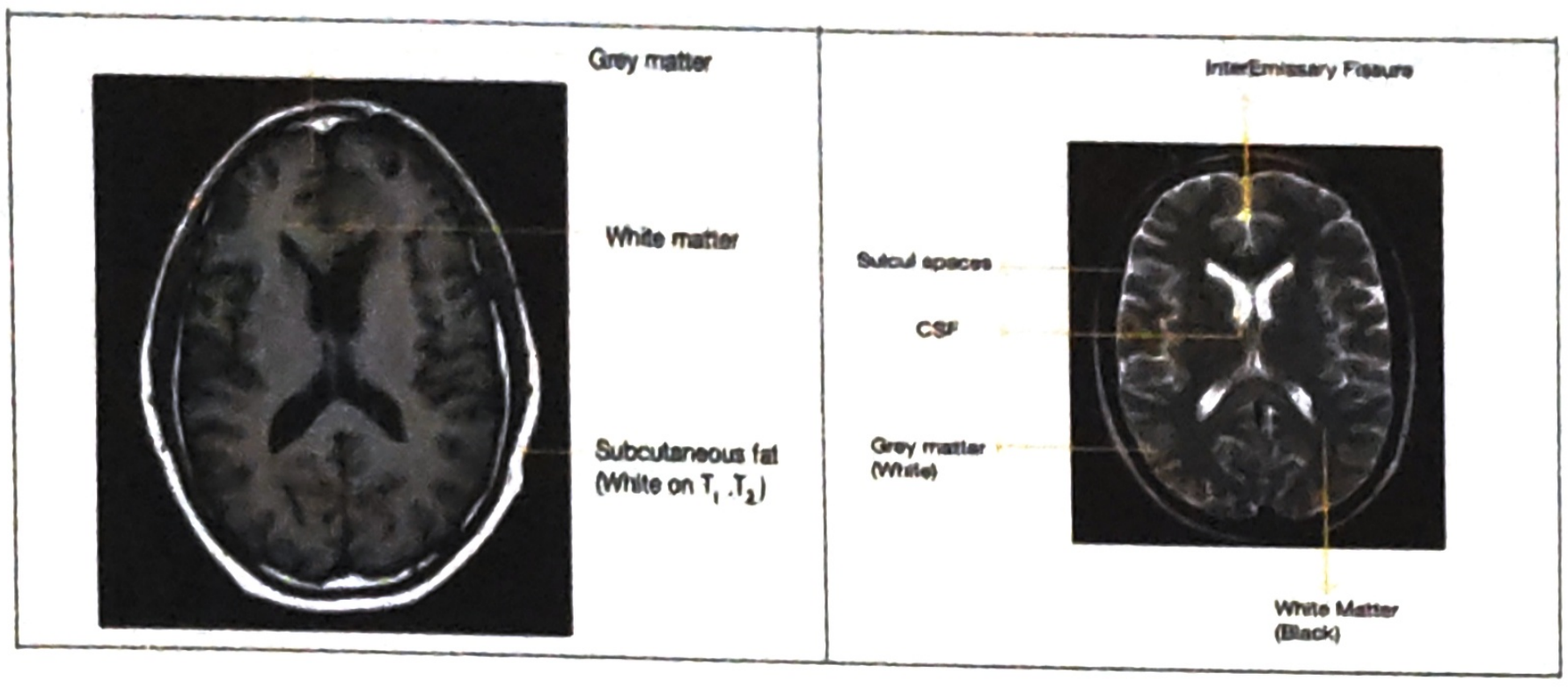

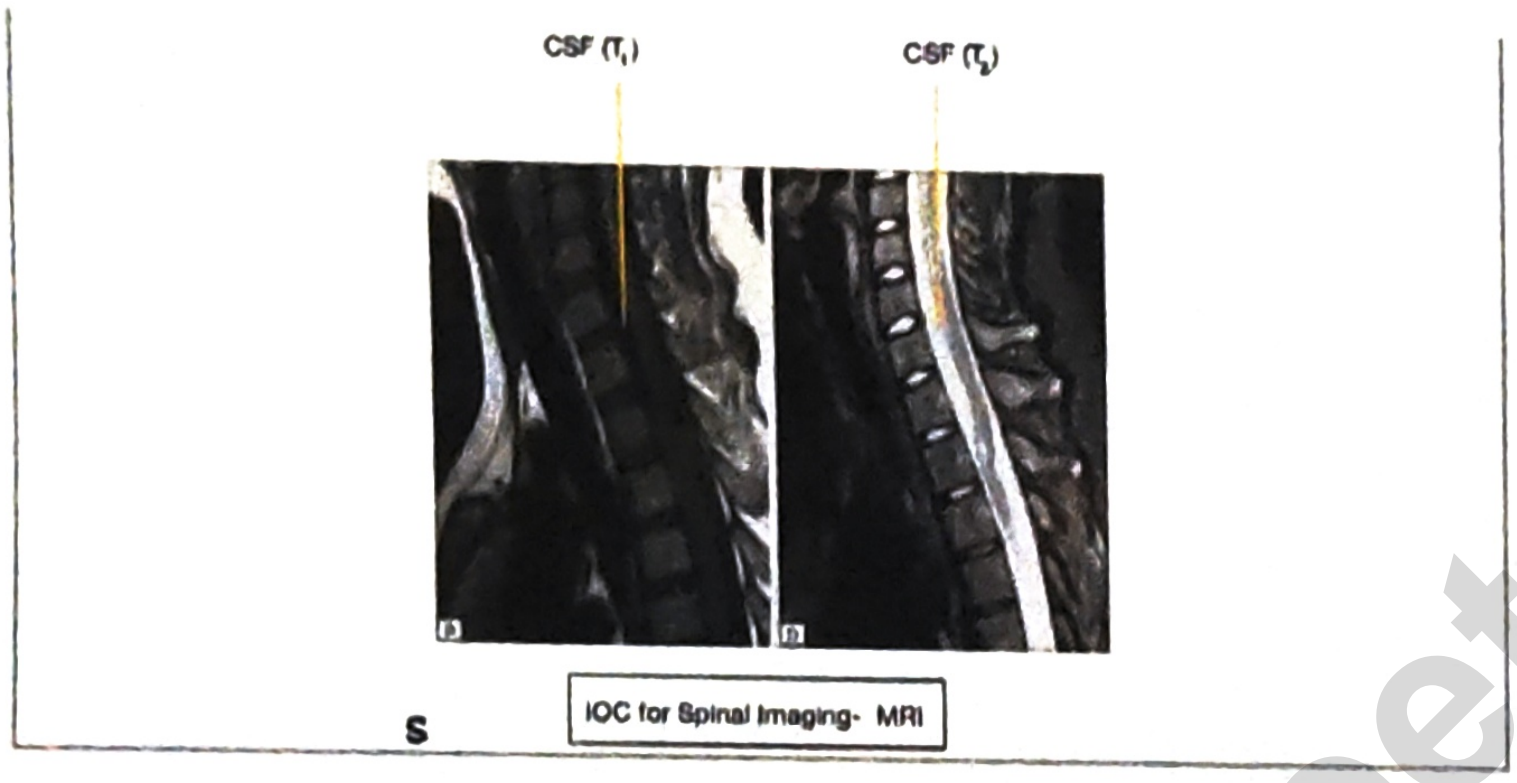

Note:

- Contrast MRI is done in T1 weighted
- Most pathologies appear hypointense on T_1 and hyperintense in T_2

Structures appearing hyperintense on T1 00:09:21

1) Fat
2) Proteinaceous substances (e.g. craniopharyngiomas)
3) Subacute haemorrhage (e.g. venous infarcts)
4) Gadolinium
5) Melanin - 'T_1 hyperintense metastasis'

↓

Melanoma

Structures dark (hypointense) both on T_1 and T_2

1) Air
2) Bone
3) Calcification
4) Flowing blood

} Signal voids

5) Dense fibrous tissues (e.g. ligaments, tendons)

https://t.me/Latestneetpgnotes

PrepLadder

Note:

→ To look at flowing blood= MR Angiography → with contrast

↓

Without contrast- 'Time of flight' technique = to see incoming signal intensities

Advantages of MRI

- → Multiplanar imaging
- → Has good soft tissue resolution
- → Neuroimaging

→ IOC for -

- Neurological diseases – MRI
- Brain tumors - Contrast enhanced MRI
- Spinal metastasis – MRI
- Ventricular function = CINE-MRI
- Preferred for Bone Marrow evaluation (bone cortex is better evaluated by CT)

→ MRI is the IOC for

- Acute osteomyelitis
- Ankylosing spondylitis / sacroiliitis
- Avascular necrosis for head of femur
- Perthes disease
- Stress fracture & March fracture

} STIR-MRI

→ MRI is the IOC for

- Posterior Fossa pathologies
- Potts spine (to evaluate extent of involvement)
- Posterior mediastinum (has neurogenic masses)
- Pancoast tumors (it is an apical lung tumor)
- Pregnant female with upper abdominal mass
- Paraplegia (traumatic)
- Perthes diseases (AVN in young)
- Parameningeal rhabdomyosarcoma

https://t.me/Latestneetpgnotes

PrepLadder

→ MRI is the IOC for Breast implants 00:23:23

- To differentiate Post op scarring from Residual / Recurrence of breast Ca = Contrast enhanced MRI is used.

↓

- Post op scarring – shows no enhancement
- Residual / Recurrence of breast Ca – shows Ductal enhancement

<table>
<tr><th colspan="2">Breast implant rupture</th></tr>
<tr>
<td>→ Intracapsular
↓
On MRI shows
• Keyhole sign
• Linguine sign
On USG shows
• Step ladder pattern
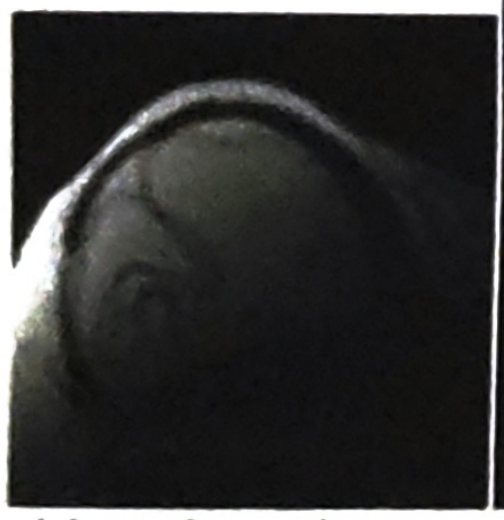

Linguine sign</td>
<td>→ Extracapsular
↓
On USG shows
• Snowstorm appearance

</td>
</tr>
</table>

<table>
<tr>
<td>

Intracapsular breast implant rupture</td>
<td>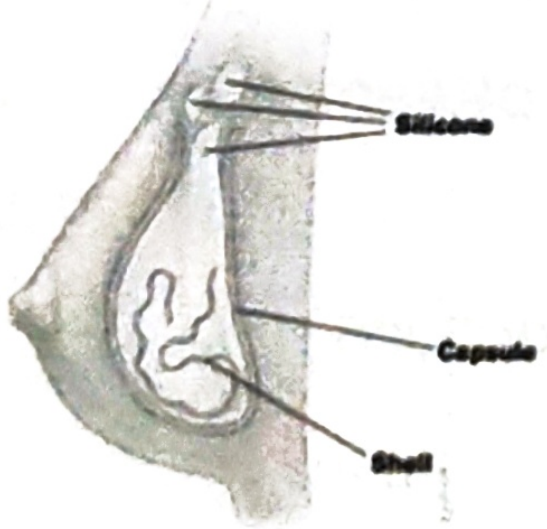

Extracapsular breast implant rupture</td>
</tr>
</table>

Disadvantages of MRI

→ Long acquisition time (so cannot be used in acute settings)

→ Relative contraindication

- Claustrophobia

→ Absolute Contraindication

- Cardiac pacemakers

https://t.me/Latestpgnotes

Prep

- Metallic prosthetic heart values
- cochlear implants
- aneurysmal clips
- Ocular metallic foreign body (IOC is CT)
- Swan – Ganz catheter

→ Not a Contraindication

- Coronary stents
- IUDS
- Orthopedic implants (titanium based)
- Dental fillings
- Foley's catheter, Ryle's tube

00:25:20

T_1 weighted MRI

1) Sylvian fissure (insular)
2) Septum pellucidum
3) Genu of Corpus callosum
4) Caudate nucleus
5) Anterior limb of internal capsule
6) Lentiform nucleus
7) Thalamus
8) Fornix

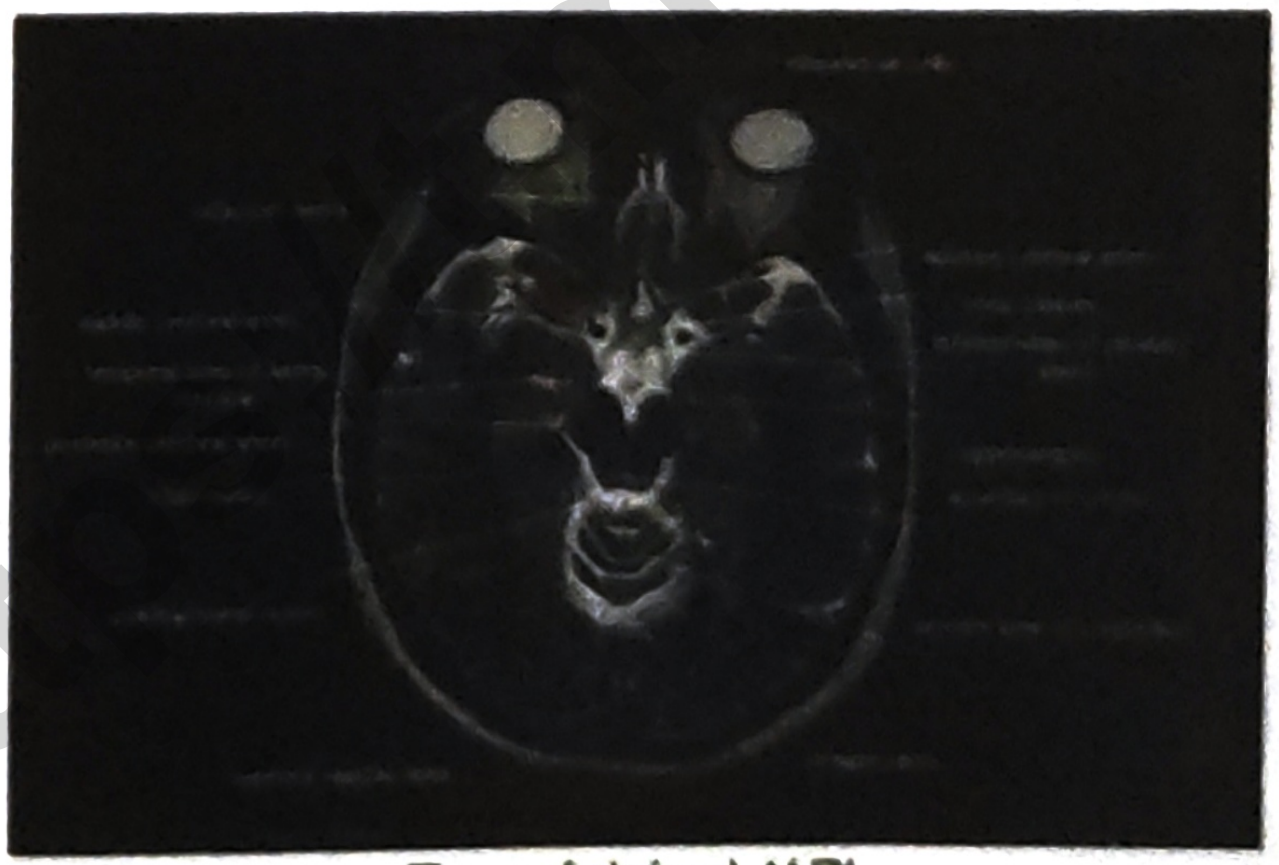

T_2 weighted MRI

http://t.me/Latestneetpgnotes

PrepLadder

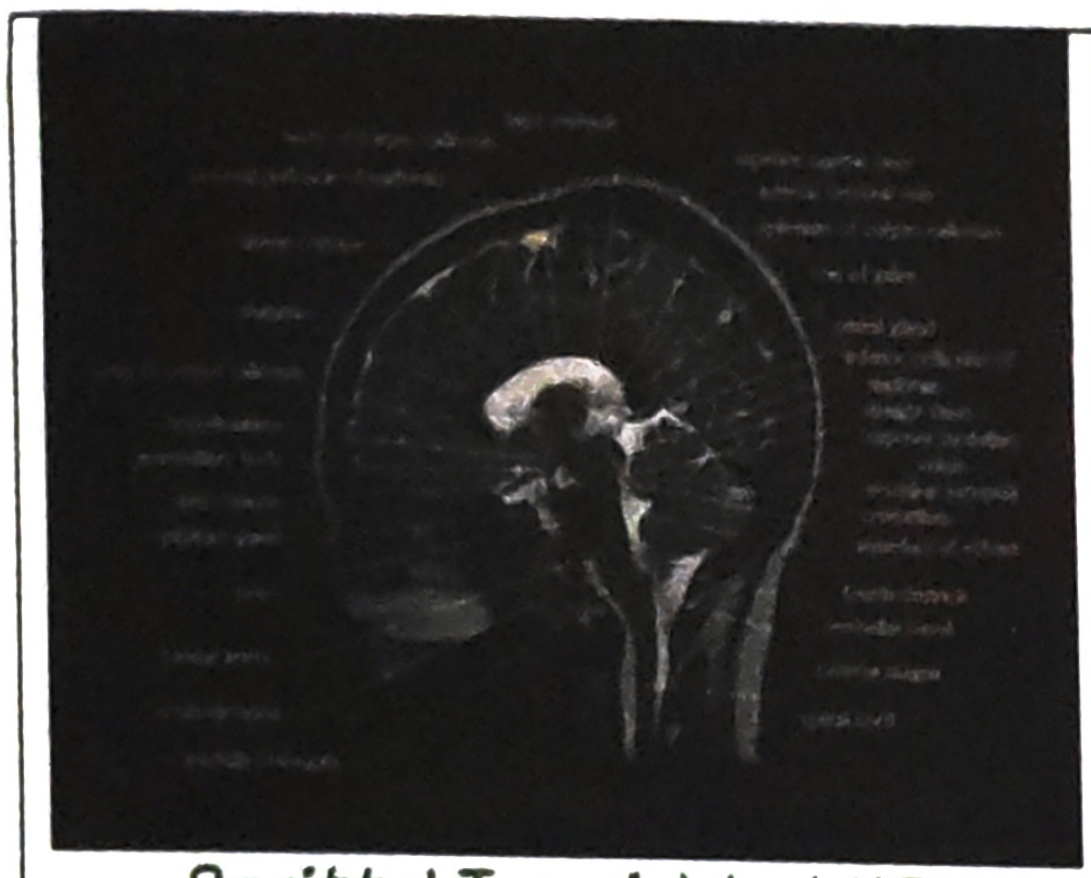

Sagittal T_2 weighted MRI

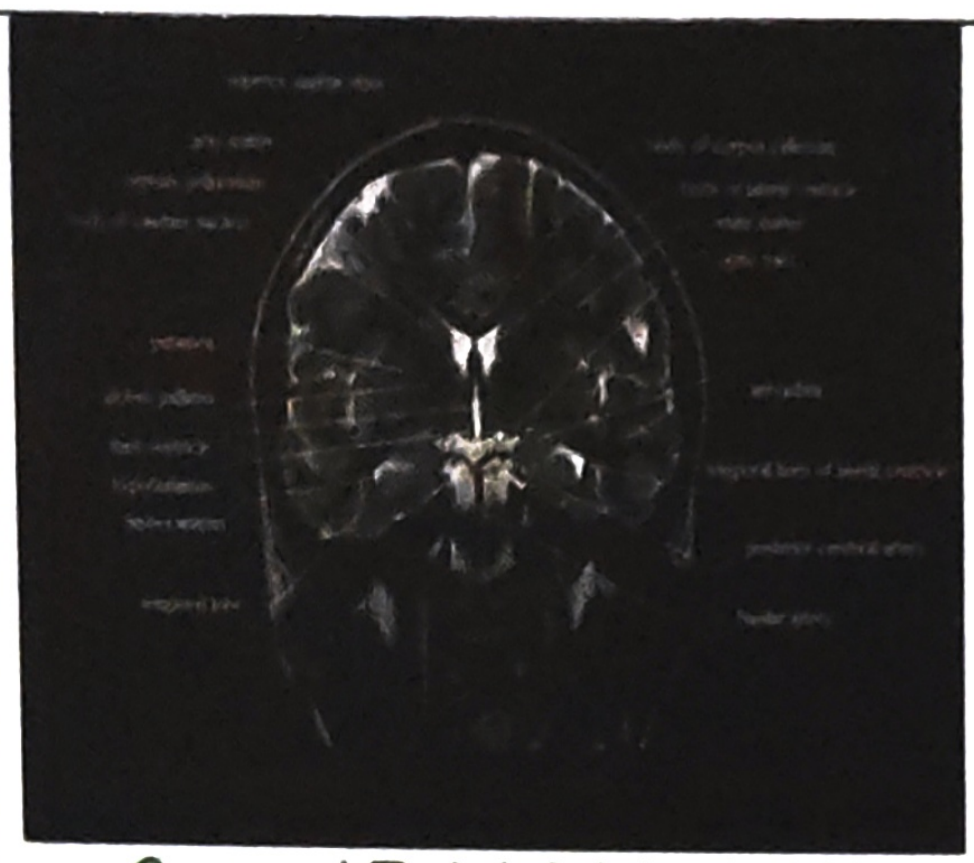

Coronal T_2 Weighted MRI

Hippocampal Atrophy

00:31:00

→ Dilatation of temporal horn of lateral ventricle

→ Important sign of hydrocephalus

→ Hippocampus is best visualized in oblique coronal MRI

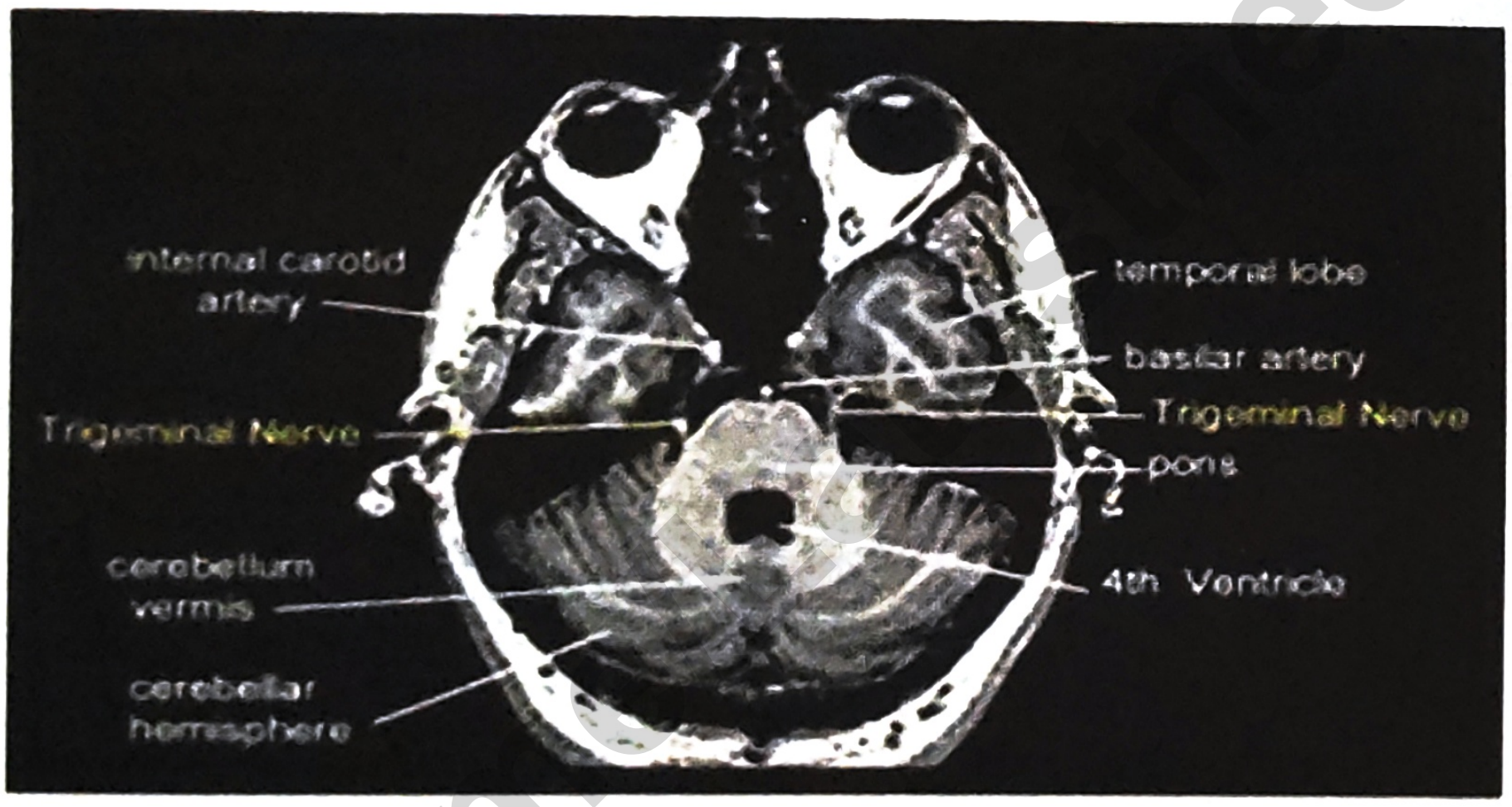

Axial MRI



Green arrow- Trigeminal Neuralgia

https://t.me/neetpgnotes

Sagittal MRI

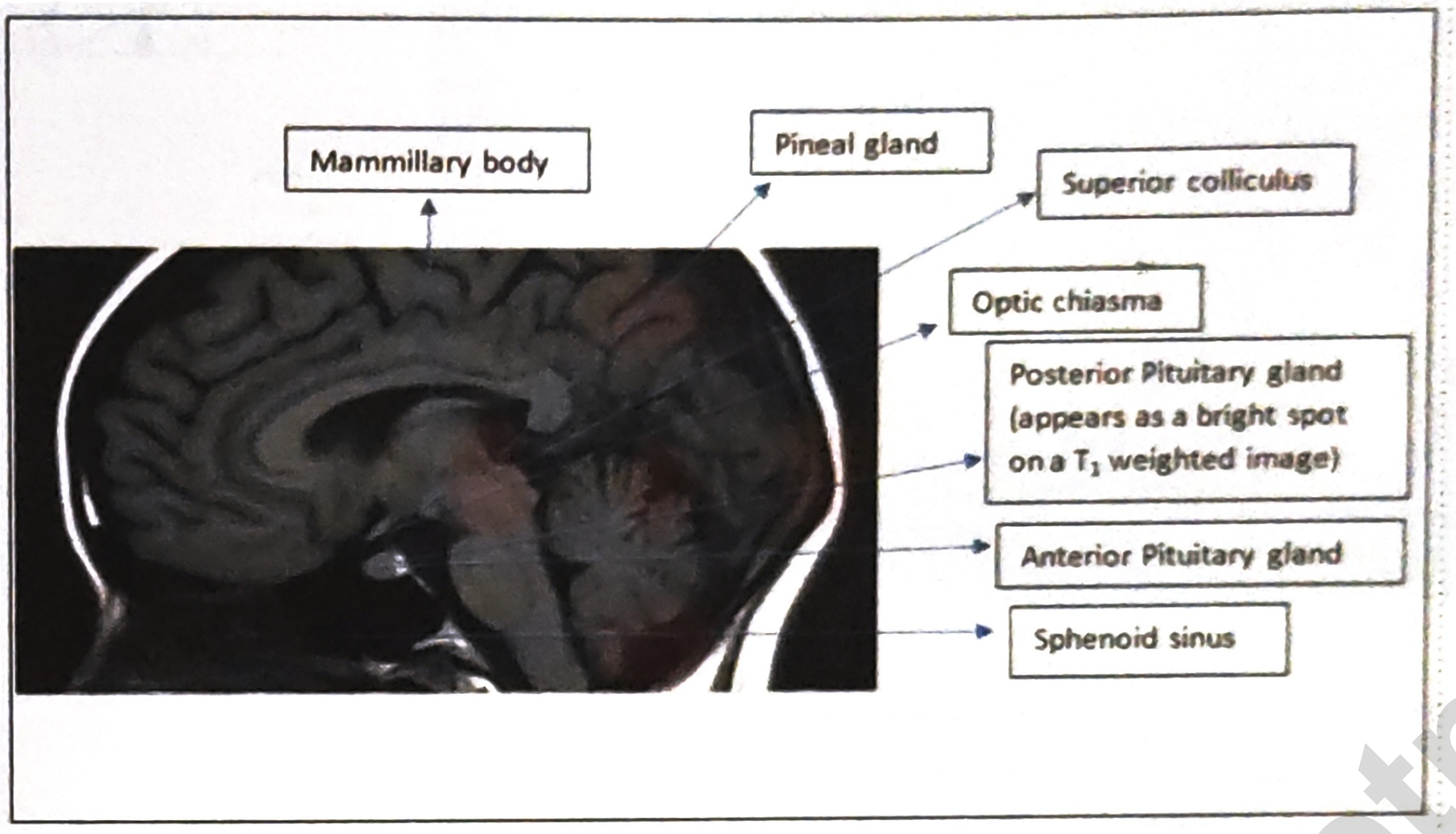

→ Absence of this bright spot of posterior pituitary

- Central Diabetes Insipidus

→ In case of Pituitary enlargement (e.g. pituitary adenoma) - Compression of optic chiasma

↓

Bitemporal heteronymous hemianopia

→ Pineal gland tumor - Compression of Superior colliculus - Upward gaze palsy

↓

Parinaud Syndrome

Note:

→ Most common Pineal gland tumor - Germinoma

Faraday's Cage

To Prevent electro-magnetic interference in MRI Machine

↓

The machine is coated by a Copper Containing Cage

↓

Known as FARADAY 's CAGE

↓

Used in both EEG & MRI rooms

https://t.me/Latestneetpgnotes

PrepLadder

Cerebral Veins

00:38:40

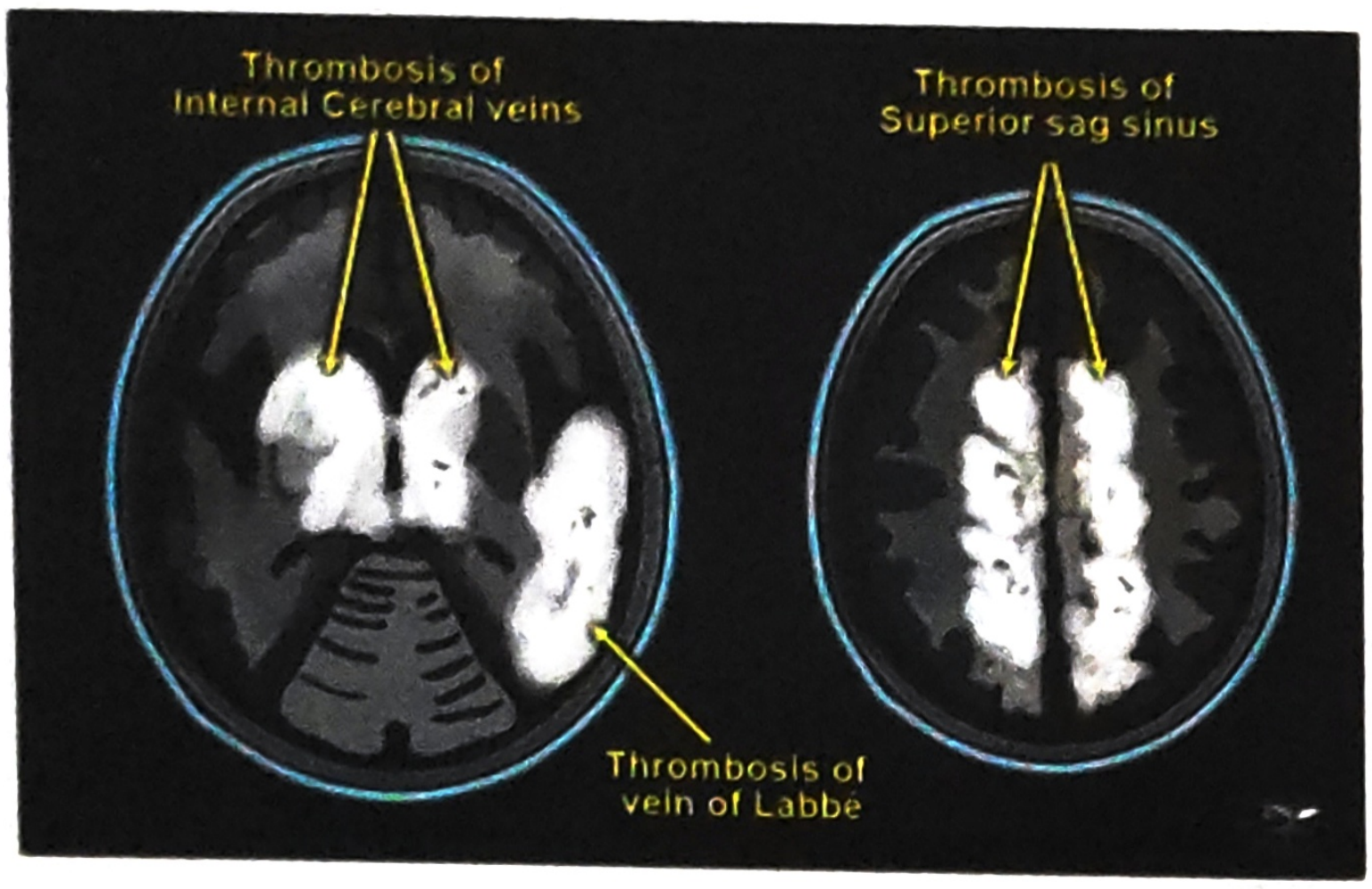

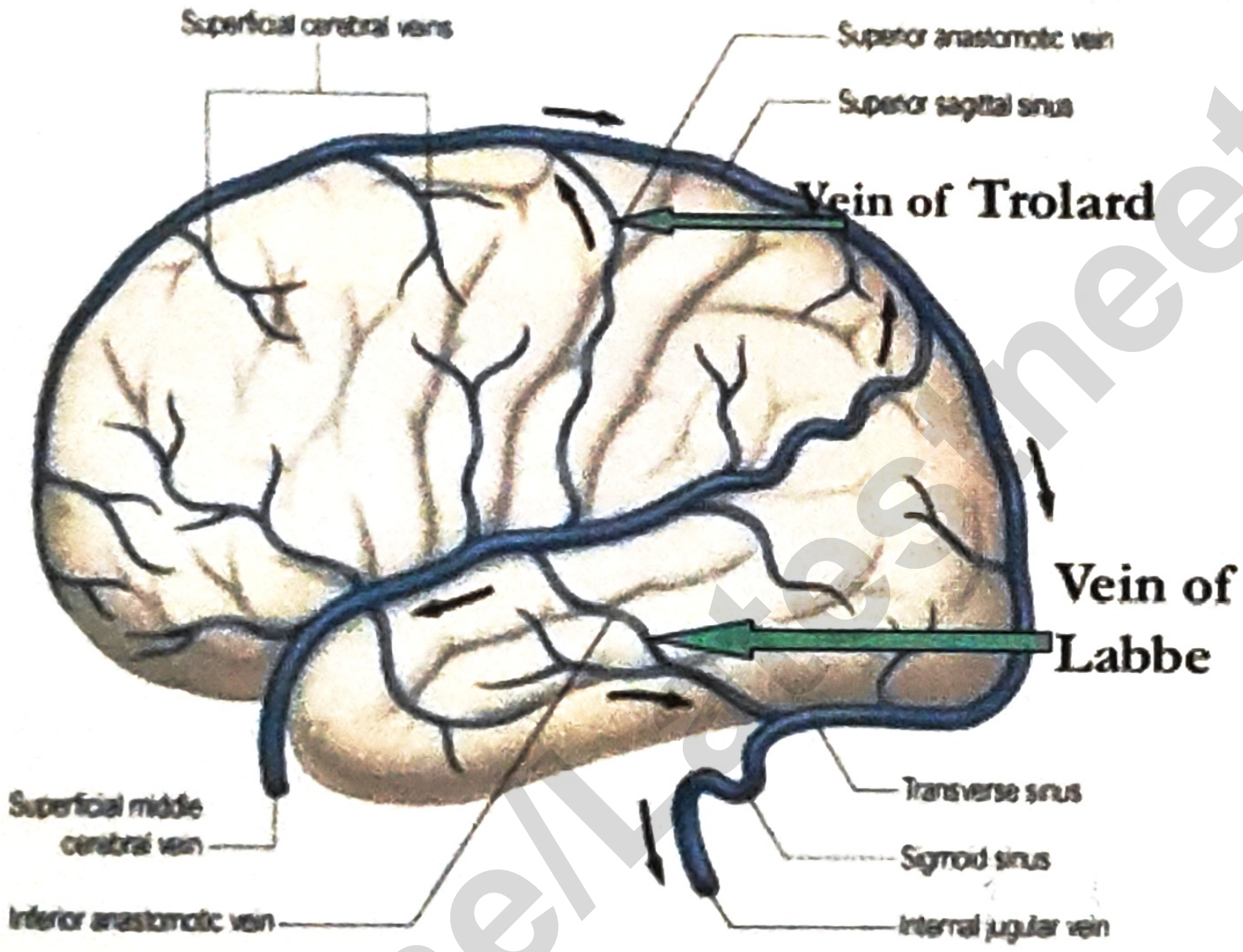

Superficial cerebral Veins

MRI of Knee

00:40:40

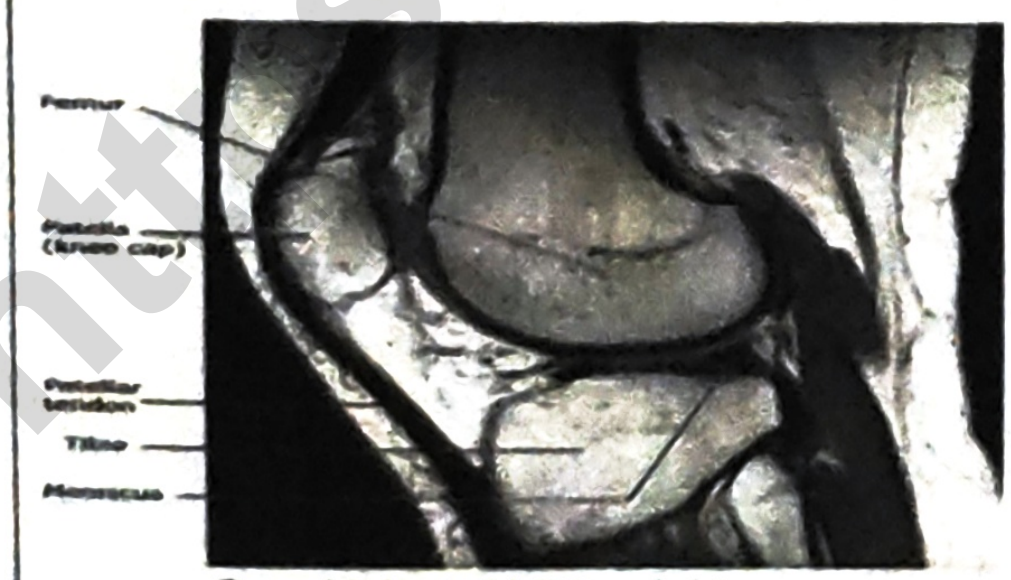

Sagittal MRI of Knee



Bowtie appearance of meniscus

https://t.me/Latestneetpgnotes

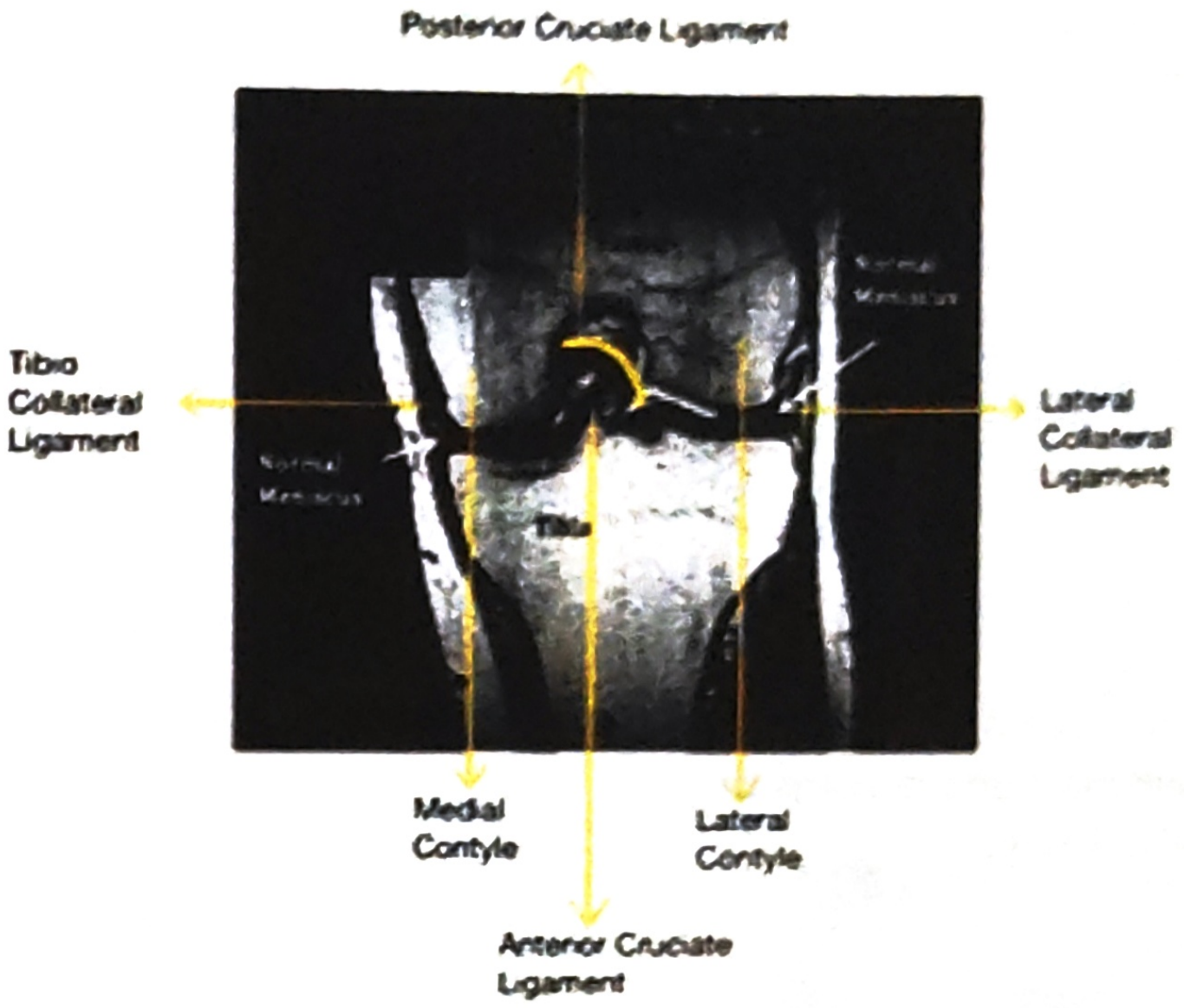

Coronal MRI of Knee

Sagittal MRI of Knee

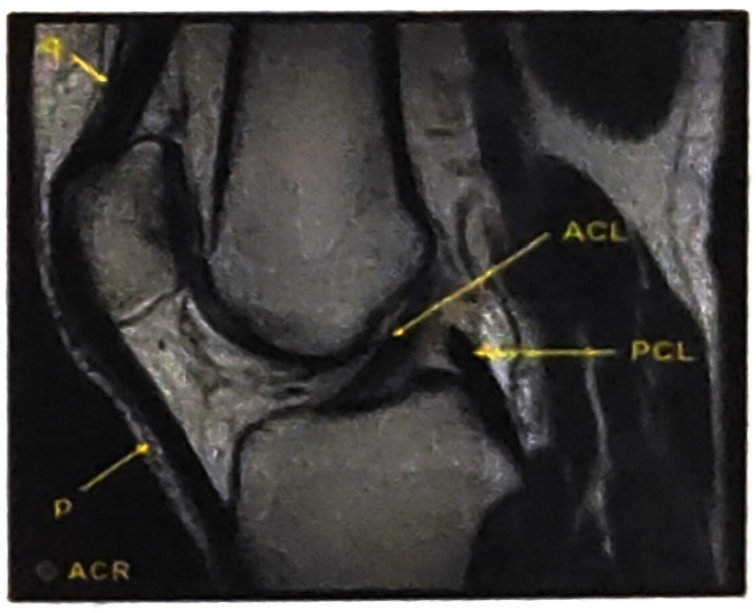

Sagittal MRI of Knee (normal)

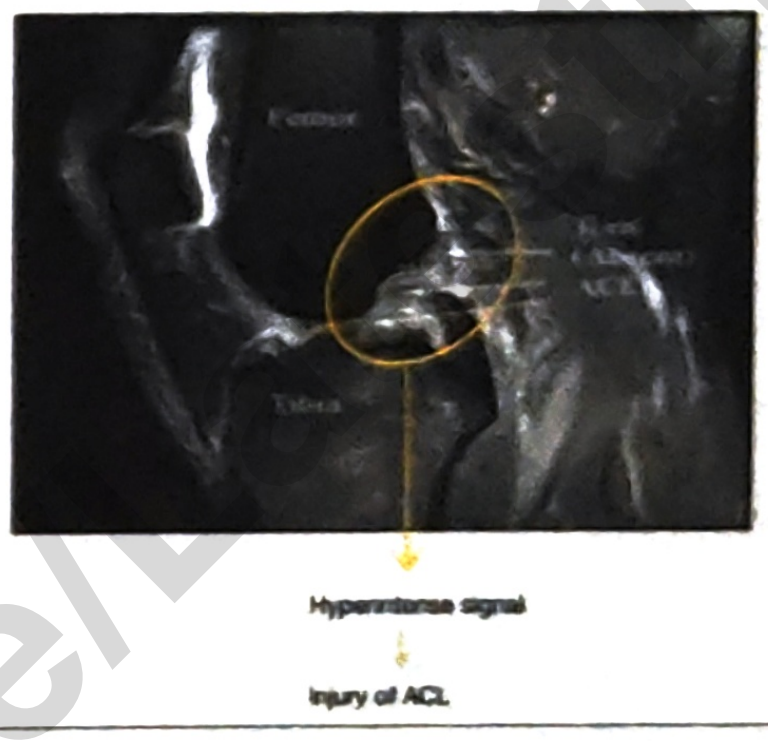

Note:

→Ligaments are hypointense in MRI and gives hyperintense signals only when injured

Double PCL sign

00:46:20

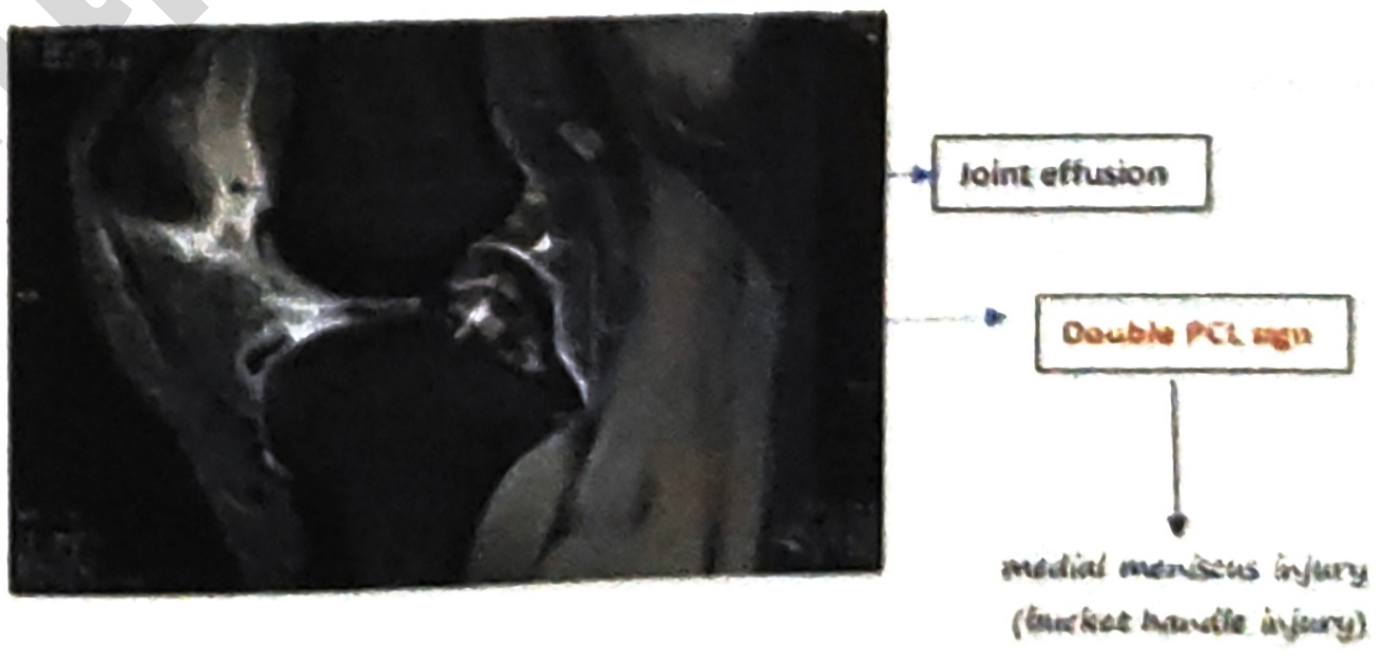

PrepLadder

Chapter 14

NUCLEAR MEDICINE I

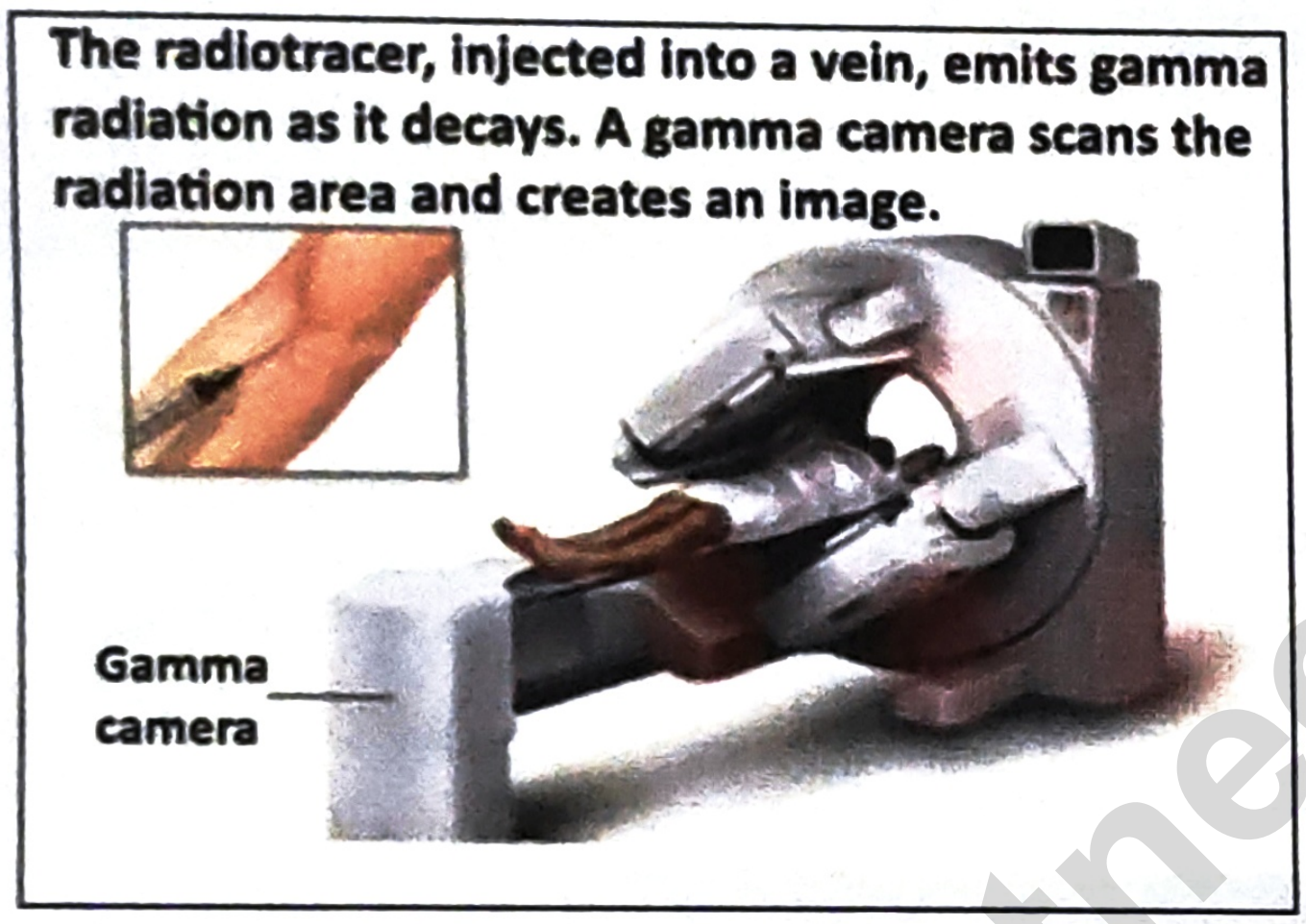

00:01:50

Scintigraphy/ Radioisotope Study	SPECT (Single Photon emission CT)	PET (Positron emission tomography)
• Tc^{99m} isotope used	• Tc^{99m} isotope used • 360° revolving Gamma cameras • 3D image	• 18 F • 11C • 13 N isotopes

Scintigraphy study

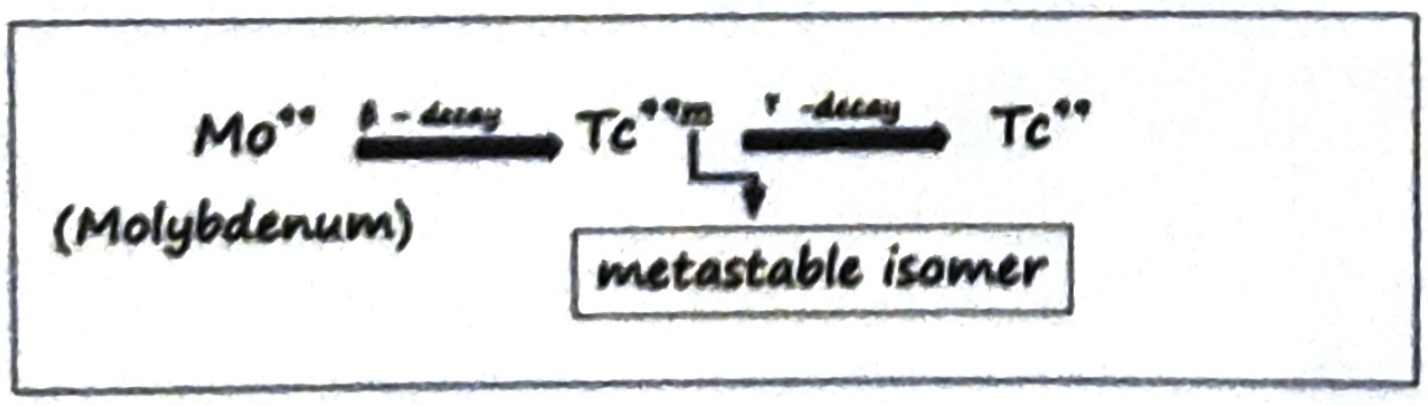

→ Parent component of Tc^{99m} is Mo^{99}

→ $T_{1/2}$ of Tc^{99m} is 6hrs

→ Tc^{99m} is binded to ligands based on organ of interest

https://t.me/Latestneetpgnotes

PrepLadder

For more free ebooks and notes, visit

https://t.me/Latestneetpgnotes

Or click this page to join

Ex:

1) TC^{99m} + DMSA → Kidney

2) TC^{99m} + Pertechnetate → Gastric mucosa

3) TC^{99m} + MDP → Bone

Note:

→ Gamma camera/ anger camera/ scintillation detector

- Detects the gamma rays emitted from the organ

Tc^{99m} – Pertechnetate

Uses:

→ Thyroid scintigraphy

→ Salivary scintigraphy

→ Meckel's diverticulum

HIDA scan 00:04:45

→ It is the most accurate investigation for acute cholecystitis (but IOC for acute Cholecystitis - USG)

→ Non – visualization of gallbladder in HIDA scan is suggestive of acute cholecystitis

→ Used to exclude the diagnosis of biliary atresia

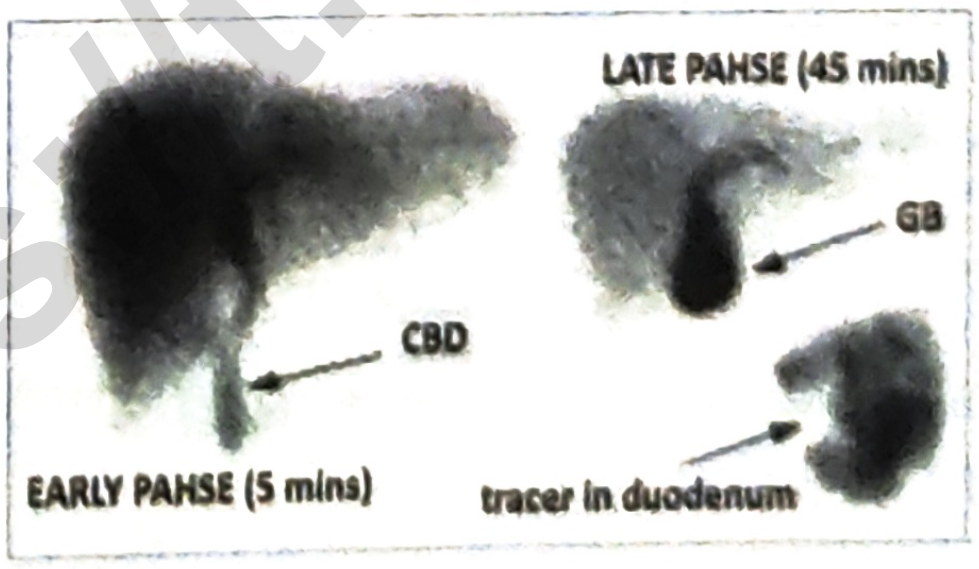

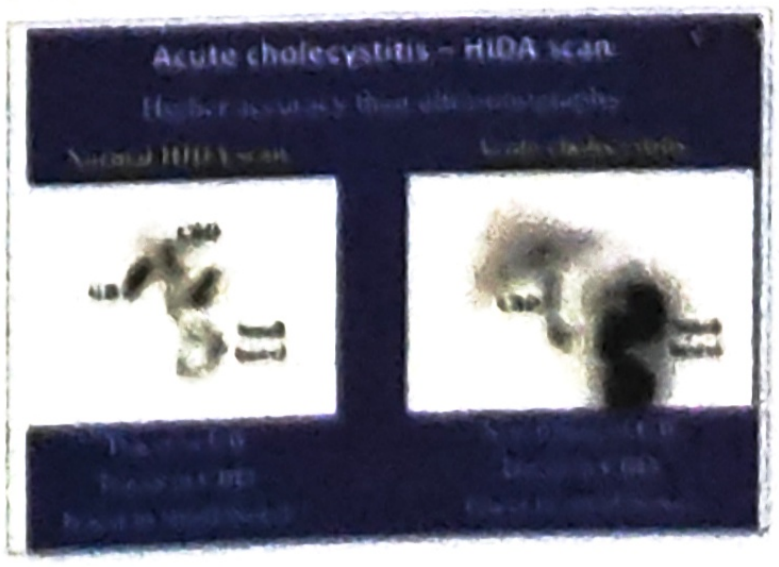

https://t.me/Latestneetpgnotes

PrepLadder

Myocardial perfusion imaging 00:10:32

→ Isotopes used:

- Thallium 201
- Tc^{99m} Tetrofosmin
- Tc^{99m} Sestamibi, MIBI scan

→ Stress thallium study increase sensitivity

Note:

→ N – 13 ammonium PET has greater sensitivity for myocardial perfusion

Myocardial infarct imaging

→ Tc^{99m} Pyrophosphate is used to localize the area of infarct in heart.

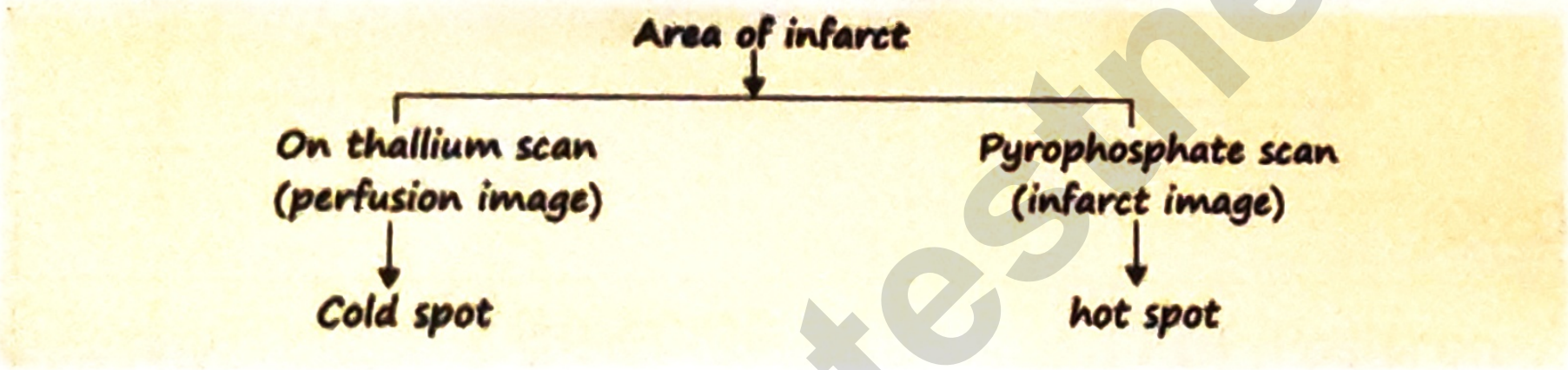

MUGA scan (Multi-gated acquisition scan) 00:14:07

→ Tc^{99m} labeled RBC is used

→ Evaluate ventricular function/ ejection fraction – Cardiac ventriculography

(But most accurate investigation for ventricular function is Contrast – MRI)

Note:

→ Tc^{99m} labeled RBC is very sensitive investigation for detecting minimal lower GIT bleeding (as low as 0.1 ml per Minute)

Bone scan

→ Done with:

1) Tc^{99m} – MDP (Methylene diphosphonate)
2) Tc^{99m} – Medronate

https://t.me/Latestneetpgnotes

→ Hot uptake on bone scan indicates osteoblastic activity

→ Cold uptake on bone scan indicates osteoclastic activity

Normal bone scan 00:23:53

- → Axial skeletal shows normal uptake in bone scan
- → IOC for spinal metastasis - MRI
- → Normal Bone image shows uptake of tracer in axial skeleton, bilateral shoulder, sacral region and kidneys

Hot uptake of bone scan seen with

- → Osteoblastic metastasis / prostatic metastasis
- → Paget's disease
- → Fibrous dysplasia
- → Osteoarthritis
- → Osteomyelitis (3 phase bone scan)

Cold uptake of bone scan is seen in

- → Multiple myeloma (not preferred for bone scan)
- → Focal cortical defects

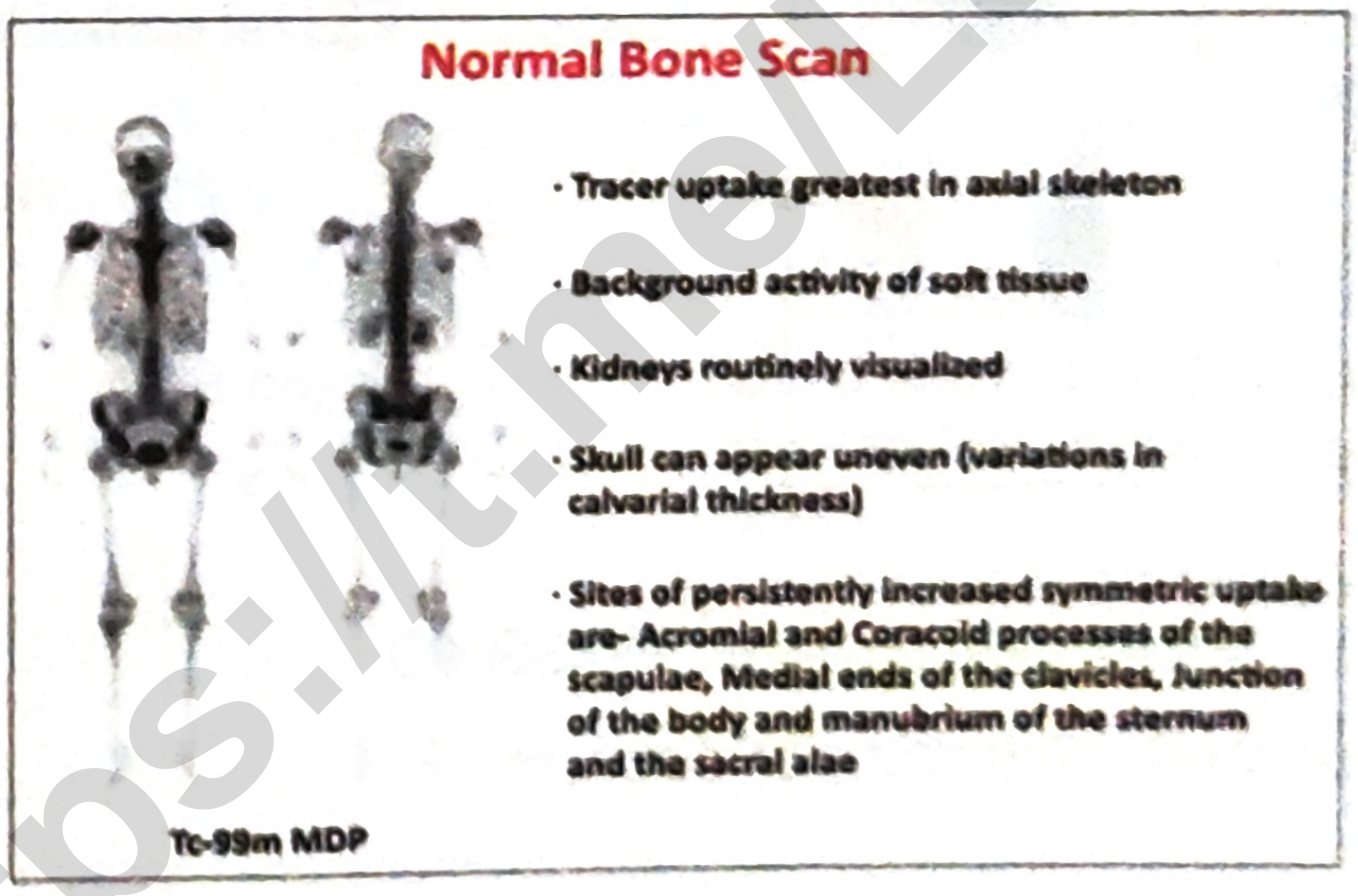

Super scan 00:29:10

→ It resembles normal bone scan but kidney is not visualized

→ It is seen with:

- Renal failure
- Diffuse metastatic bone disease
- Diffuse metabolic

https://t.me/Latestneetpgnotes

PrepLadder

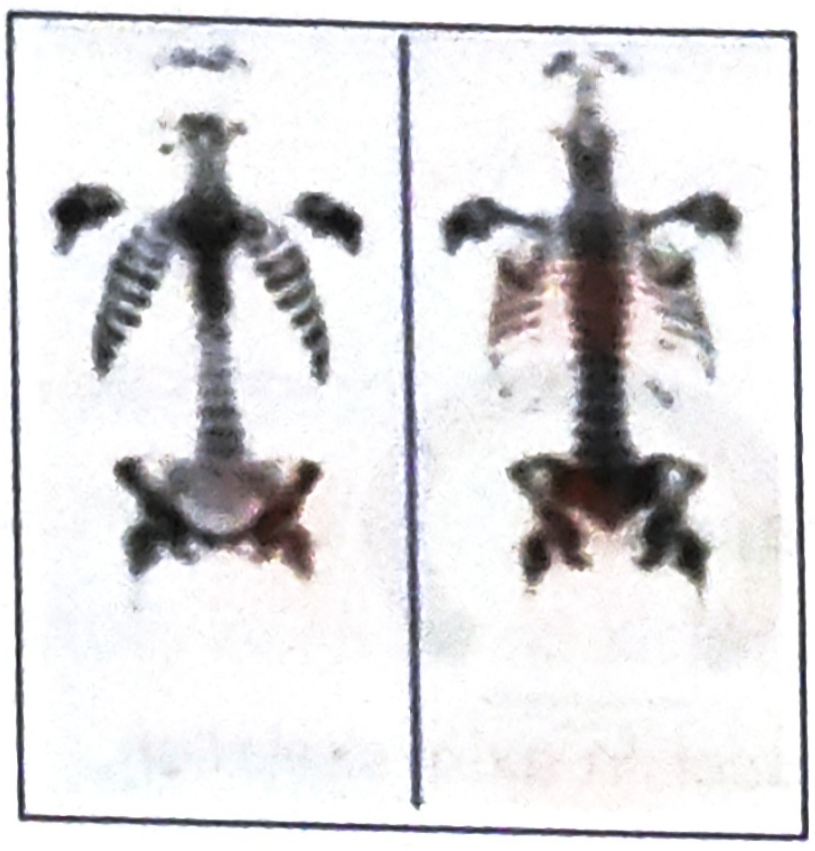

Super scan

Paget's disease

→ Bone scan shows increased uptake of isotope in Calvarium and vertebral body.

→ Because of increased osteoblastic activity - cotton wool skull (feature of Paget's) – increased uptake in calvarium

→ Because of increased osteoblastic activity in vertebra and in its posterior elements

- Showa hot uptake giving "mickey mouse sign" on bone scan.

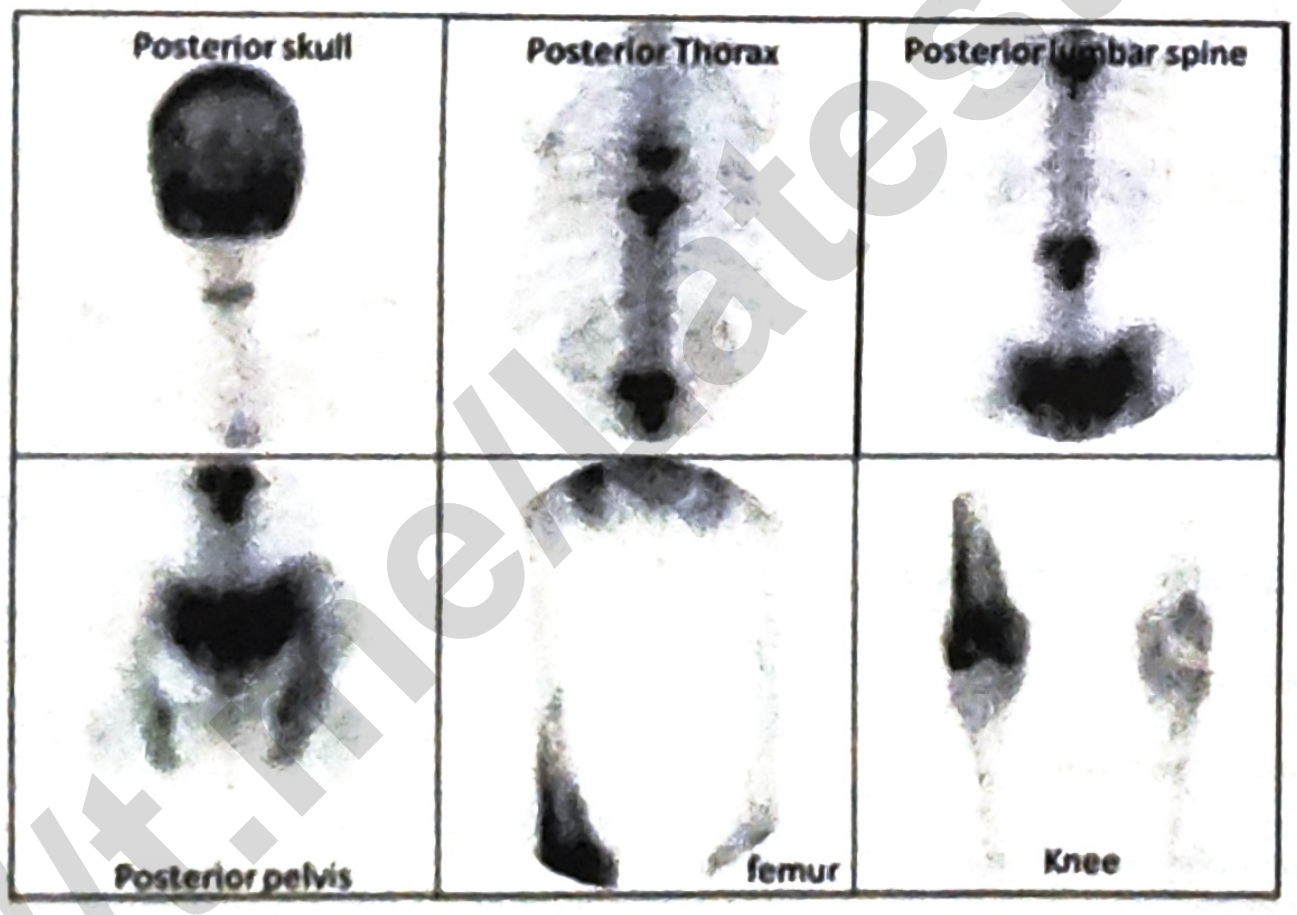

00:33:40

Sacral insufficiency fracture/ Osteoporotic fracture of sacrum

→ "H sign / Honda sign"

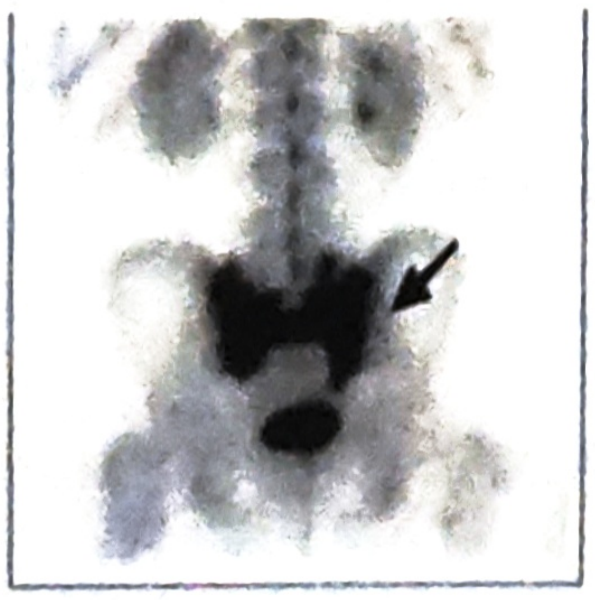

H sign

https://t.me/latestneetpgnotes

Prepl

Technetium 99m sulphur colloid scan

→ Taken up by reticuloendothelial cells

→ Used for

- Phagocytes study
- Evaluate splenic disease
- Detect occult abscess

→ It shows hot uptake in focal hyperplasia (because it has increased number of Kupffer's cells)

Note:

1) Stellate scan in kidney Oncocytoma
2) Stellate scan in pancreas Serous cystadenoma
3) Stellate scar in liver

Fibrolamellar variant of HCC → (has increased hepatocyte) and Kupffer cells) → No Hot uptake

Focal nodular hyperplasia → (has increased hepatocyte → Hot uptake

On sulphur colloid scan

Different types of radioactive Iodine

00:34:53

→ Normal iodine is I127

Radioisotope	t ½	Uses
I^{131}	8 days	Used for radio ablation; systemic radiotherapy for well Differentiated thyroid metastasis; emits β & γ ray Killing of Ca cells is done by β rays
I^{125}	60 days	Brachytherapy for prostate tumor, radio immunoassay
I^{124}	4 days	It is a positron emitter used in PET scan
I^{123}	13 hrs	RAIU studies/ scintigraphy; functional scan (Pertechnetate scan can Be used)

https://t.me/Latestneetpgnotes

PrepLadder

Hyperthyroidism with ↓ed RAIU

→ Subacute thyroiditis / Dequiverans thyroiditis

→ Thyrotoxicosis factitia (exogenous thyroid hormone – Hamburger's thyroiditis)

→ Struma ovarii

https://t.me/Latestneetpgnotes

Chapter 15

NUCLEAR MEDICINE Part II

Renal imaging using scintigraphy 00:00:13

Morphological / anatomical / static imaging

→ Done with Tc^{99m} DMSA scan

→ Also used for evaluating cortical scars

→ Used for

- Cortical function
- Corticomedullary differentiation
- Cortical scars evaluation
- Functional masses of kidney evaluation

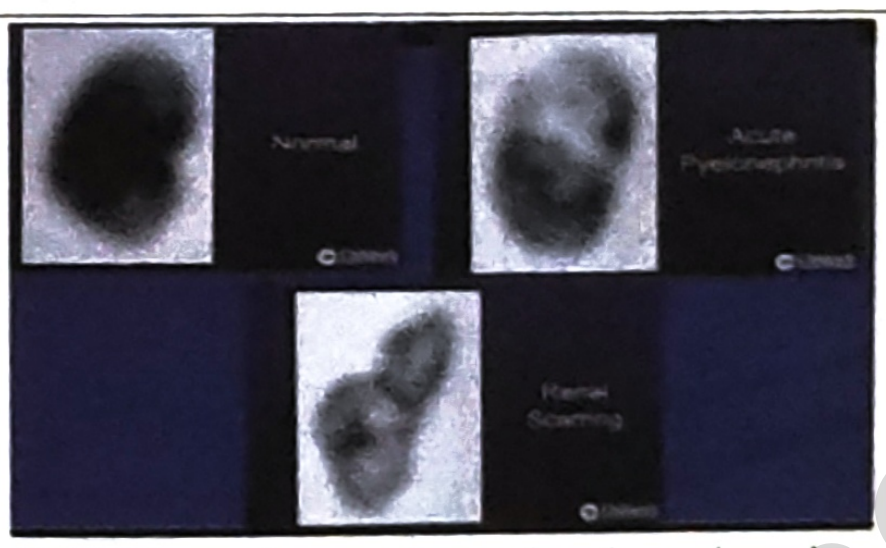

DMSA gets reabsorbed and gets conc. in Cortex

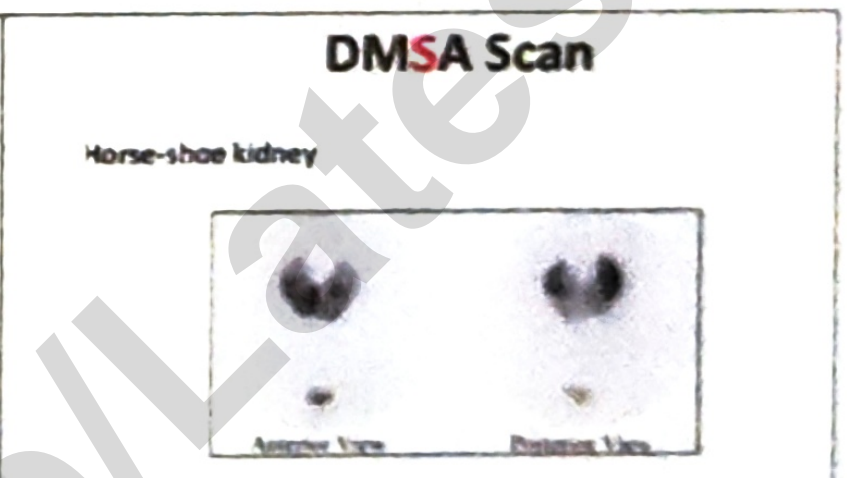

Functional / Dynamic Renography 00:03:37

→ Done with Tc^{99m} DTPA / Tc^{99m} MAG3

→ Tc^{99m} DTPA – evaluate G.F.R

→ Tc^{99m} MAG3 – used to evaluate

- Renal function
- Renal perfusion
- Renal plasma flow

Captopril – DTPA scan

→ used for screening of renovascular hypotension

→ But, gold std for renal artery stenosis is Renal angiography

https://t.me/Latestneetpgnotes

PrepLadder



Gallium – 67 scans

→ This binds to lymphocytes

→ Used for lymph node scintigraphy

→ Used to locate occult abscess

Example: → In sarcoidosis

- Because of presence of B/L hilar lymph node and Right paratracheal lymph node

→ gives "lambda sign" in thorax on gallium scan

- In face – uptake is seen is B/L parotid in nasopharynx & also, in B/L orbits → gives "Panda sign" on gallium scan
- Indium – III labeled WBC scan:

→ Used for locating occult abscess

V/Q scan / ventilation – perfusion scan 00:17:16

→ IOC for PTE – CT – angiography (i.e MDCT with contrast)

→ But, IOC for

- PTE in pregnancy
- PTE in iodine allergy

↓

V/Q Scan

→ For ventilation study – Xe, Kr used

→ For perfusion study

- Tc99m labelled MAA used (macroaggregate of albumin)
- Tc^{99m} labelled RBC

Somatostatin receptor scintigraphy / Octreotide scintigraphy

→ Done in patients with neuroendocrine tumors like

- Carcinoid tumors
- Gastrinoma
- VIPoma
- Glucagonoma

https://t.me/Latestneetpgnotes

Note:

→ Insulinoma is somatostatin receptor negative

→ Parathyroid adenoma - Tc^{99m} Sestamibi scan used

→ Pancreatic carcinoma – Selenium – methionine scan used

SPECT imaging 00:22:09

→ It is a 360° revolving gamma camera giving 3 D ages

→ T Tc^{99m} radioisotope is used (t1/2 = 6hrs)

→ Tc^{99m} – HMPAO:

- Lipophilic/ lipid soluble
- Crosses blood brain barrier
- Cerebral perfusion is evaluated

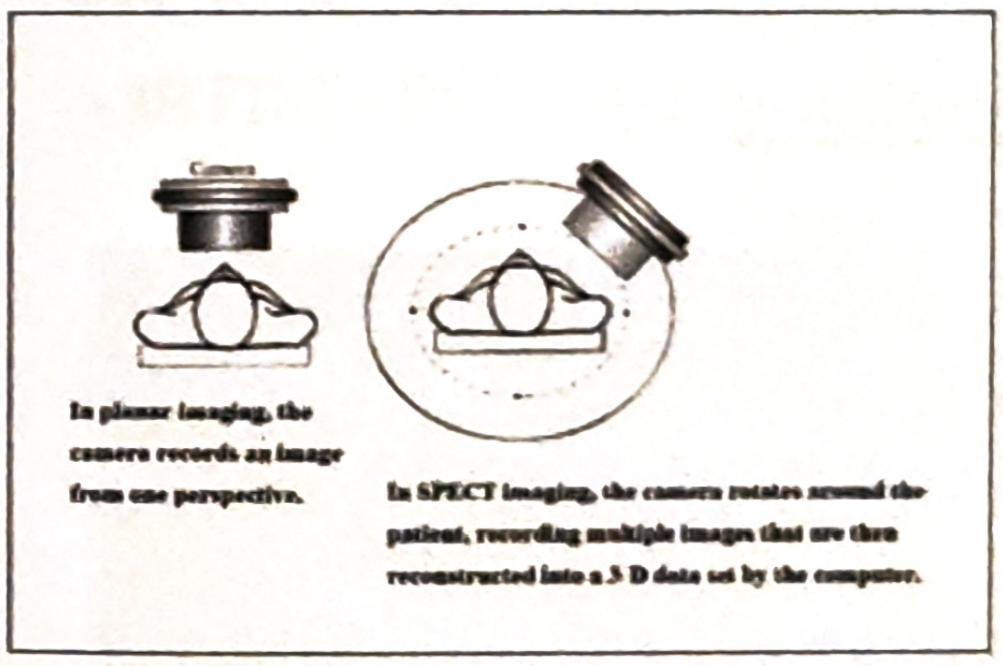

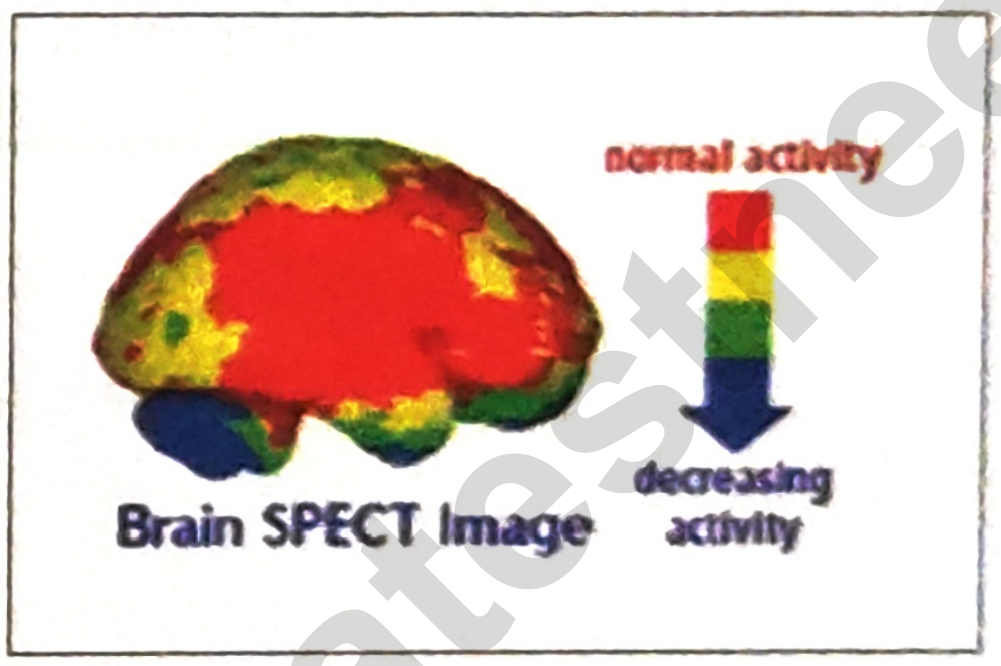

Note:

→ Decreased cerebral perfusion in parieto temporal region → Alzheimer's ds,

→ Decreased cerebral perfusion in Fronto temporal region → Pick's ds

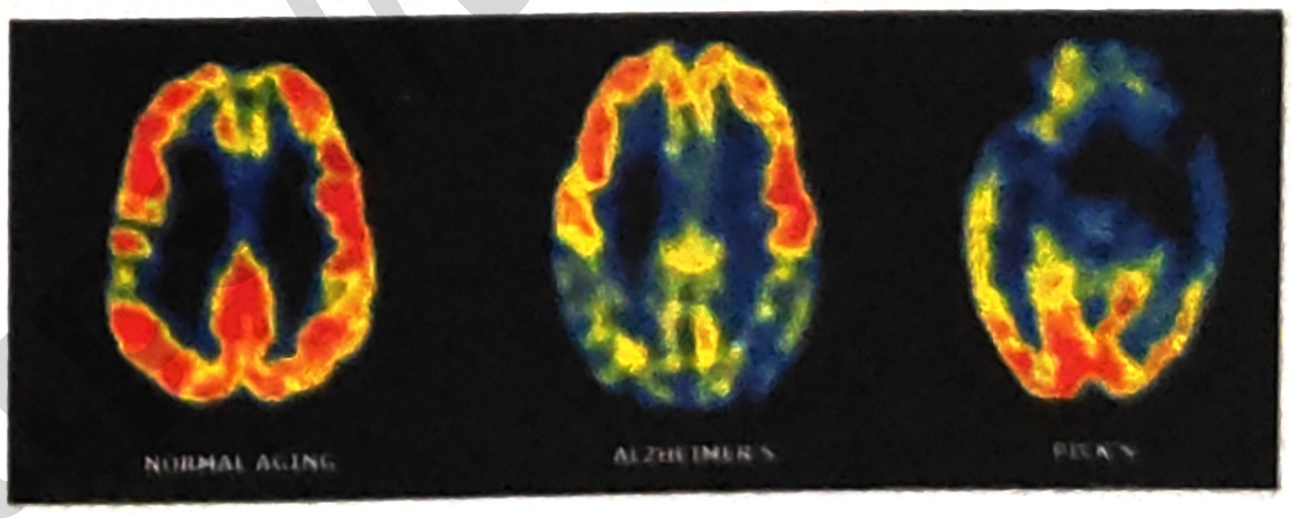

PET scan 00:26:28

→ 18 – FDG is used (t1/2 = 110 mins)

→ Warburg effect: is aerobic glycolysis occurring in tumor cells

→ Because of this effect, 18 FDG selectively enters into tumor cells

https://t.me/Latestneetpgnotes

PrepLadder

Note:

→ Blood glucose should be normal before 18 FDG – PET

18 FDG negative tumors

→ Tumors with low mitotic & low metabolic activity

- Typical carcinoids
- Bronchoalveolar Ca
- Mucinous Ca

Based on Warburg effect

Scar ↓ 18-FDG PET (-)	Vs	Residual / Recurrence of tumor ↓ 18-FDG PET (+)
Radiation necrosis ↓ 18-FDG PET (-)	Vs	Residual / Recurrence of tumor ↓ 18-FDG PET (+)

Basic physics of PET

00:33:31

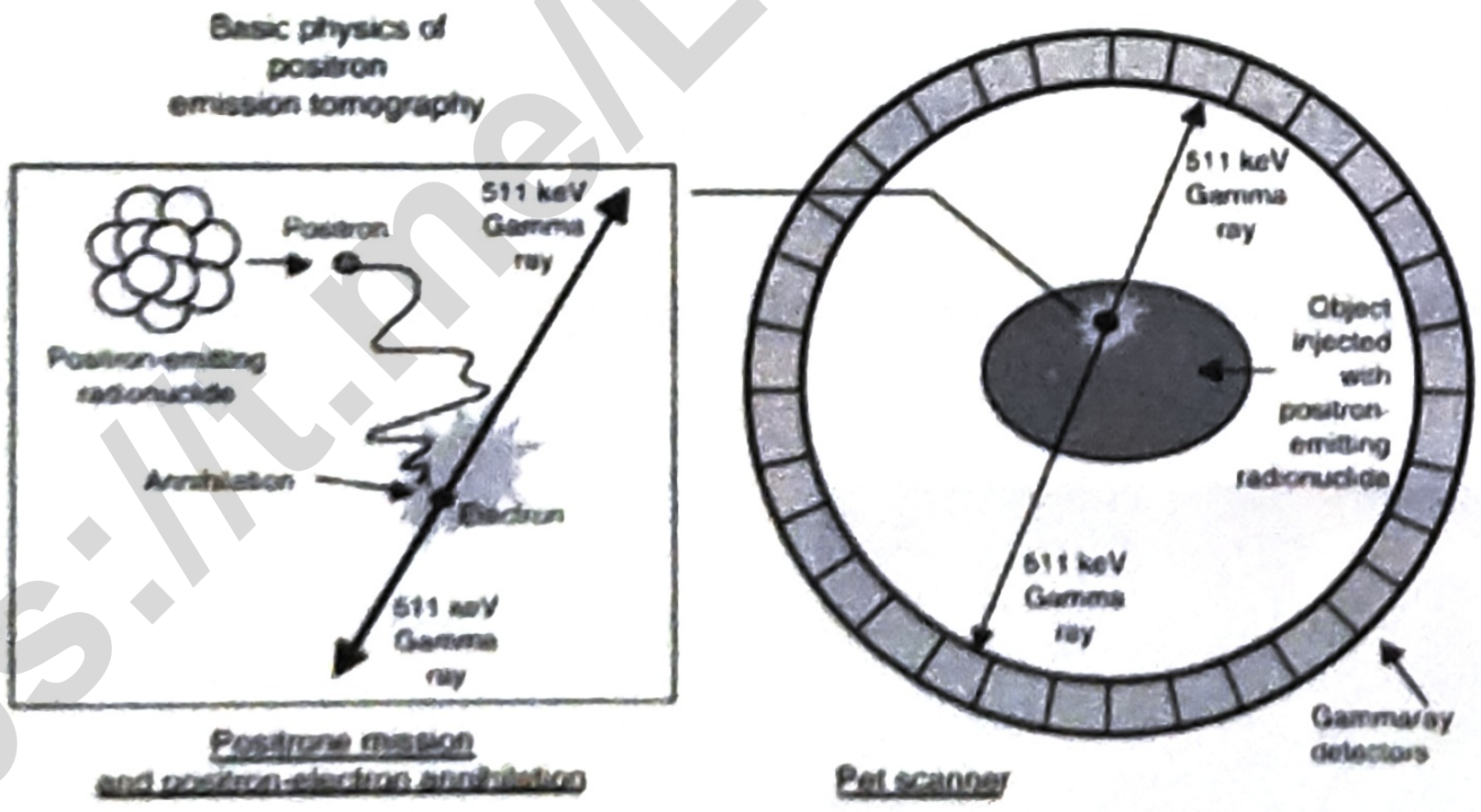

Note:

→ Gold std. in evaluation of solitary of solitary pulmonary nodules – CT guided biopsy

→ 2nd preferred IOC (non – invasive) – PET scan

→ For skeletal metastasis

NaF – PET > 18 FDG PET > whole body MRI > Bone scintigraphy

https://t.me/Latestpgnotes

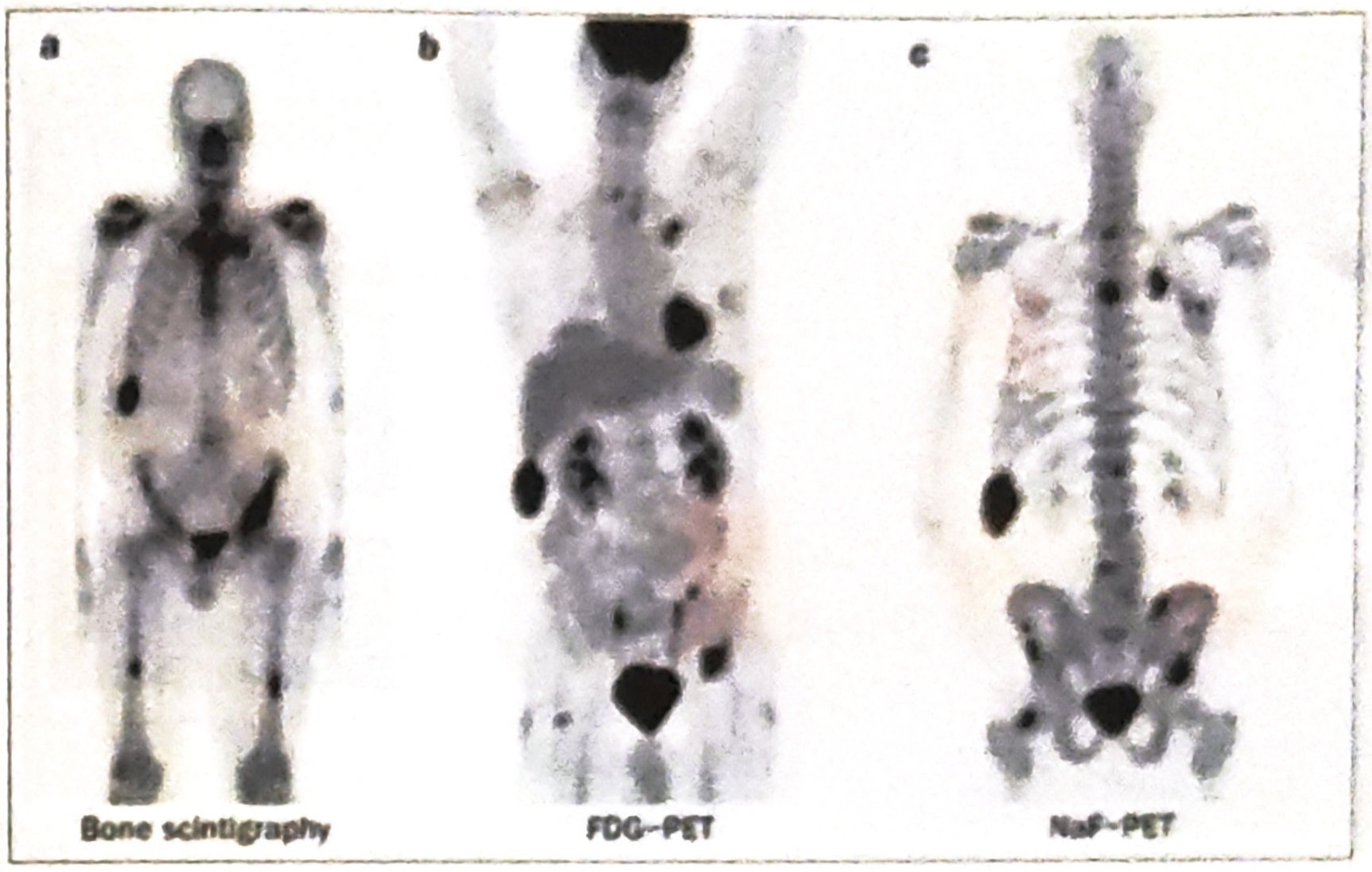

PET scanning in heart 00:45:55

→ N-13 ammonia PET = very sensitive for myocardial perfusion

→ 18 FDG – PET = myocardial viability

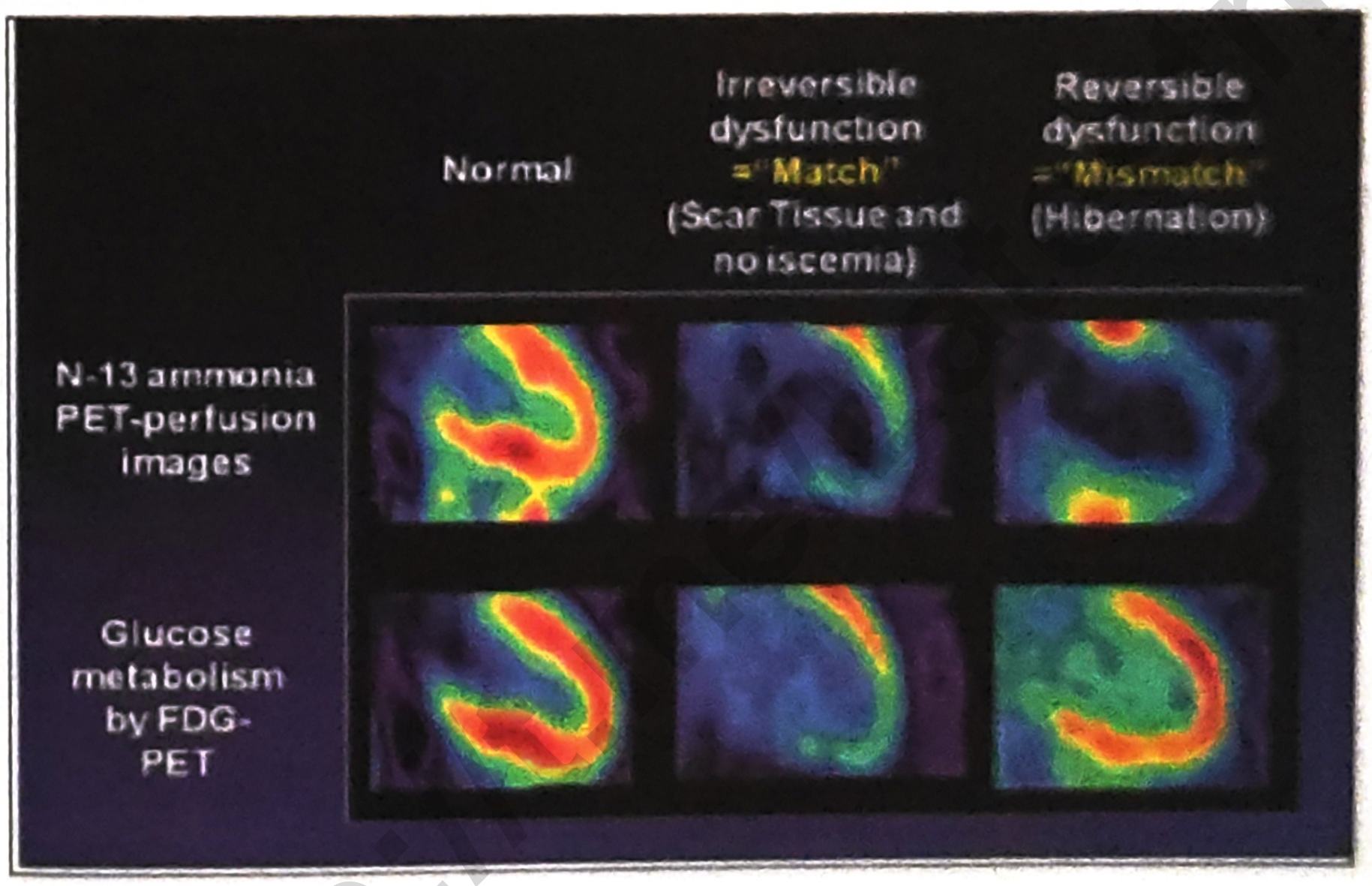

- IF N- 13 ammonia PET (-) & 18 FDG PET (-) → Suggestive of scar tissue
- If N – 13 ammonia PET (-) & 18 FDG PET (+) → Hibernating myocardium

Note:

→ C-11 methionine PET is better than 18 FDG PET – for brain tumors

https://t.me/neetpgnotes

PrepLadder

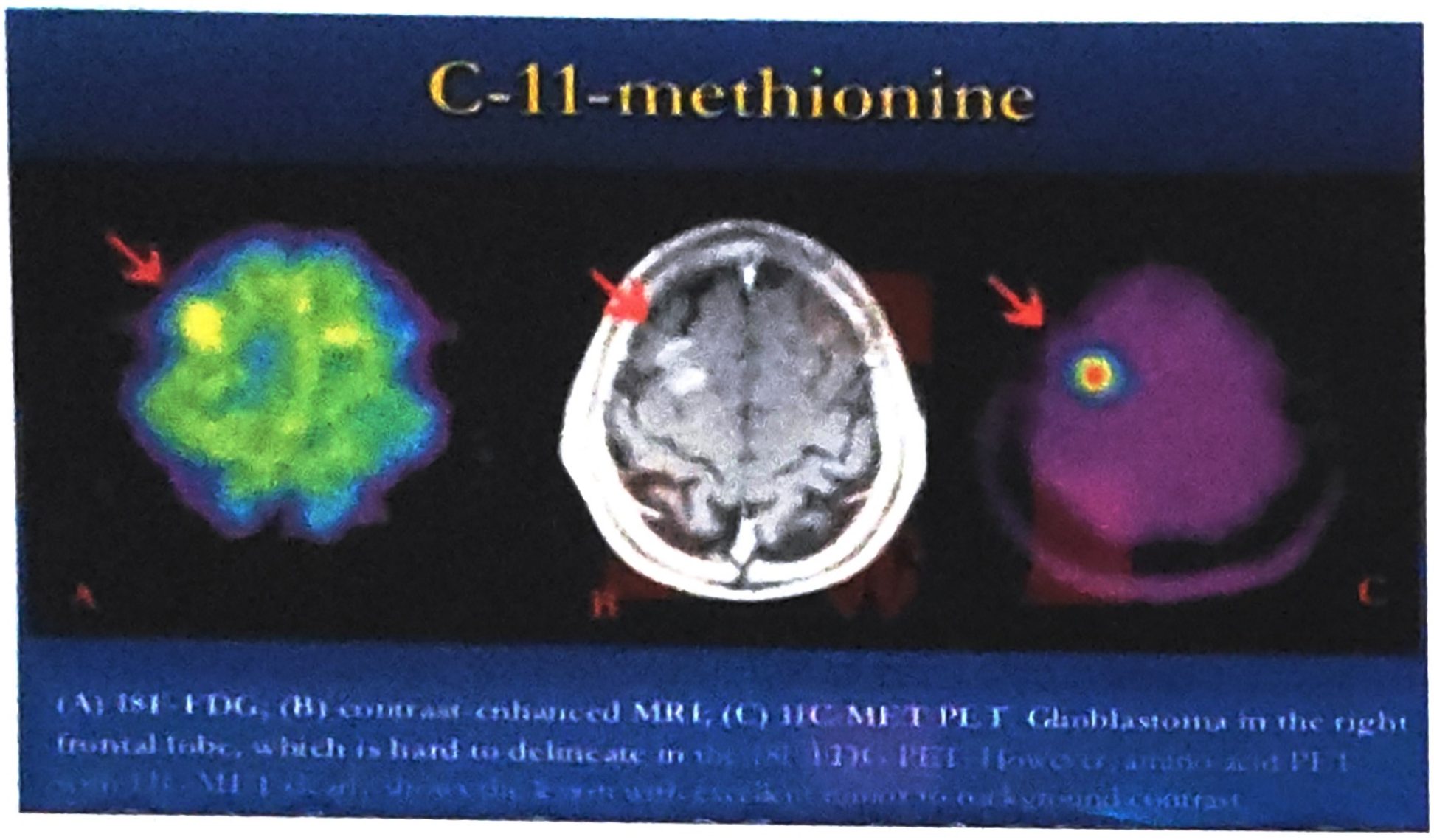

Note:

00:48:30

- Light bulb appearance on MRI abdomen → Pheochromocytoma
- Light bulb appearance on MRI liver (T2W) → Hemangioma
- Light bulb appearance on MRI brain (DW-MRI) → Acute infarct
- Light bulb appearance on shoulder radiography → Posterior dislocation

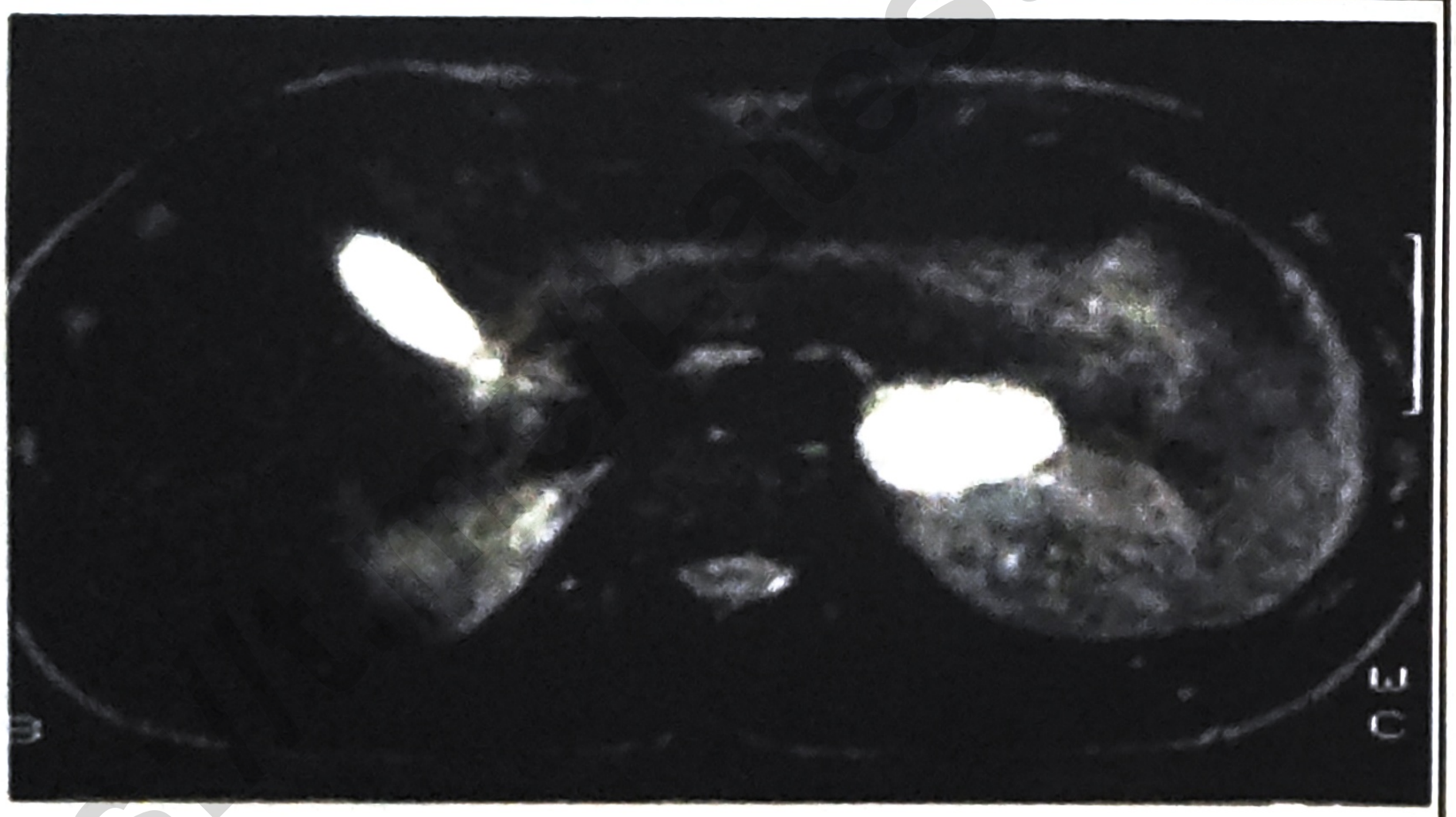

Light bulb appearance on MRI abdomen

Note:

→ IOC for Adrenal Pheochromocytoma – MRI

→ For extra abdominal Pheochromocytoma

- DOPA PET > MIBG > MRI

https://t.me/latestpgnotes

Note:

→ Ga-68 DOTATOC PET / DOTATATE PET = carcinoid tumor

(Somatostatin receptor SPECT can also be done)

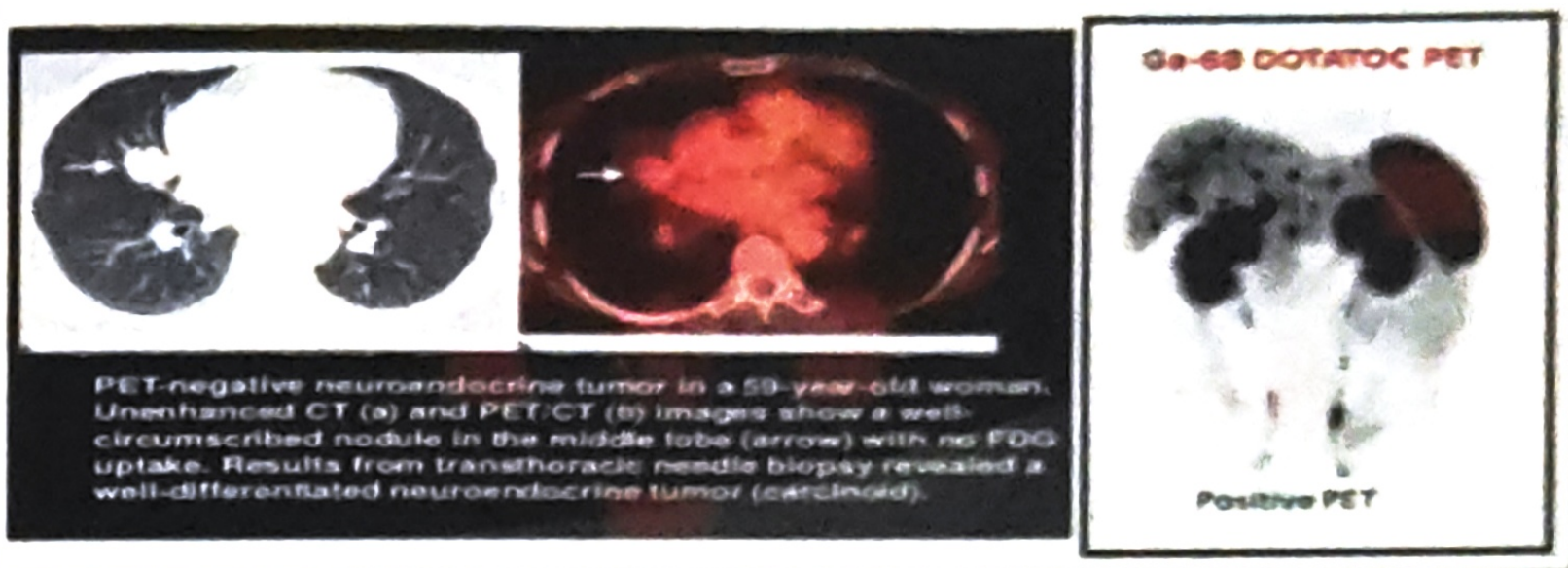

PET-negative neuroendocrine tumor in a 59-year-old woman. Unenhanced CT (a) and PET/CT (b) images show a well-circumscribed nodule in the middle lobe (arrow) with no FDG uptake. Results from transthoracic needle biopsy revealed a well-differentiated neuroendocrine tumor (carcinoid).

→ PSMA – PET (Prostate specific membrane antigen) - Prostate cancer

→ NaF PET - Skeletal metastasis

→ C11 methionine PET - Brian tumor

DOPA PET - Extra abdominal pheochromocytoma

https://t.me/Latestneetpgnotes

PrepLadder

Chapter 16

RADIOTHERAPY (Part – 1)

Mechanism of action of Radiotherapy 00:00:10

→ By causing

- Ionization of molecules (removal of electron)
- Free radical generation
- ds DNA damage more than ss DNA damage

Types of Radiotherapy 00:01:04

Teletherapy	Brachytherapy	Systemic Radiotherapy
• AKA External Beam Radiotherapy (EBRT) • MC method of Radiotherapy	It can be – Interstitial brachytherapy (as in Prostate Ca) – Intracavitary brachytherapy (as in cervical Ca) – Mold brachytherapy (as in epithelial cancers or Penile Ca)	• Oral/ injectable form of radioisotope is used • E.g. – I^{131}

https://t.me/Latestneetpgnotes

Teletherapy

00:04:03

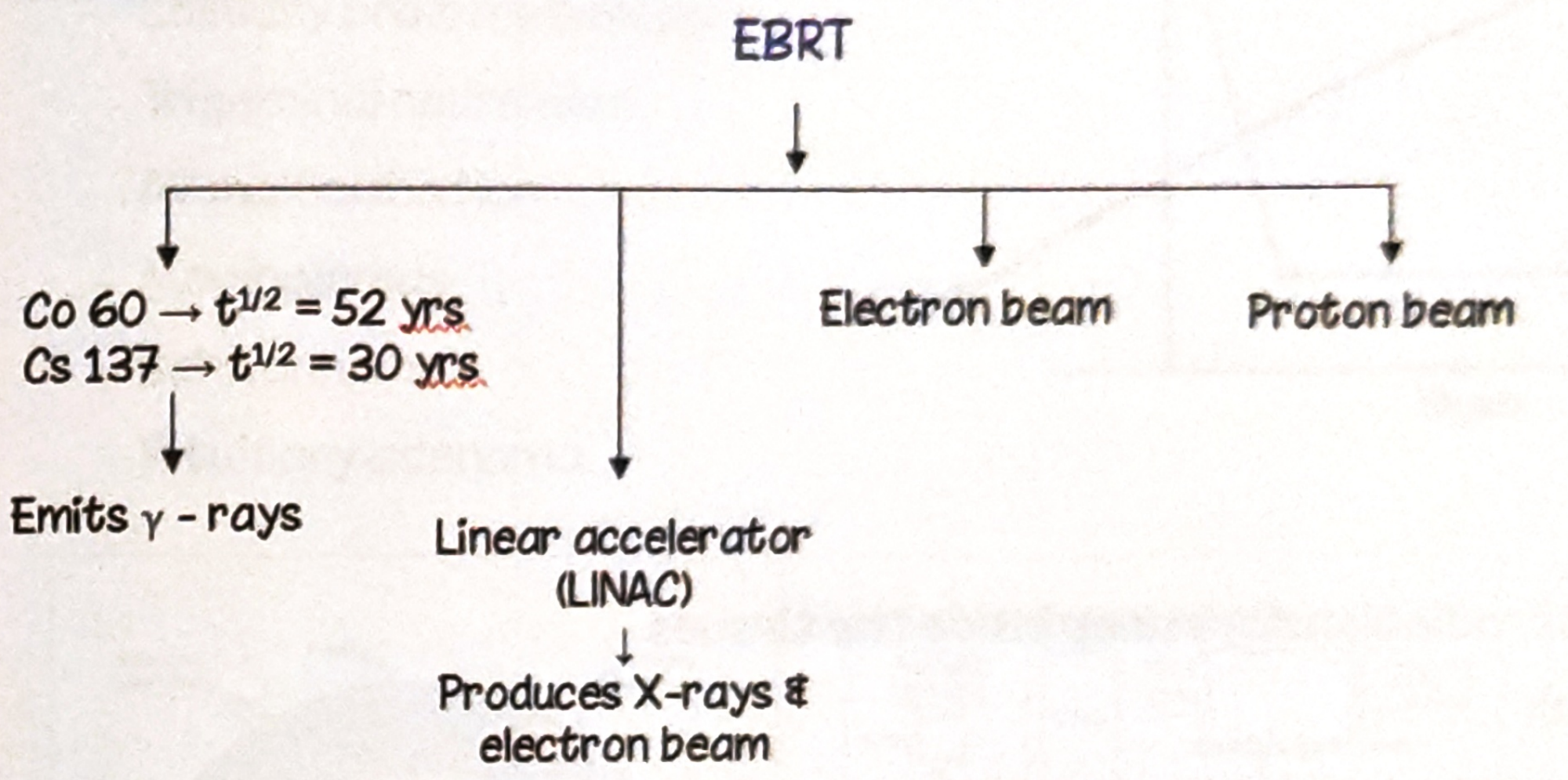

Note:

→ Most commonly used rays in Radiotherapy / Teletherapy = X – rays

Types of X – rays

00:07:22

Orthovoltage X-rays	Super voltage X-rays	Megavoltage X rays
• Have energy up to 500 KV	• Have energy of 500-1000 KV	• Have energy > 1 MV • Preferred over orthovoltage because of skin sparing effects

Electron beams (superficial pathologies)

→ Deposits most of its radiation dose in superficial tissues

→ Used for Mycosis fungoides - Total skin electron beam irradiation is done

→ Also done for Tumors of eyelids & lips

→ It is the most common method preferred for Intraoperative RT

https://t.me/Latestneetpgnotes

PrepLadder

Chapter 17

RADIOTHERAPY-PART 2

Brachytherapy

00:00:20

- → It is a technique used to avoid radiation damage to the surgeon and normal tissues of the patient from radiation while inserting radioisotope in the tumor site
- → In this technique empty pellets / catheters are inserted first and are filled with radioisotopes from reservoir by robotic means.
- → This technique is used in Brachytherapy

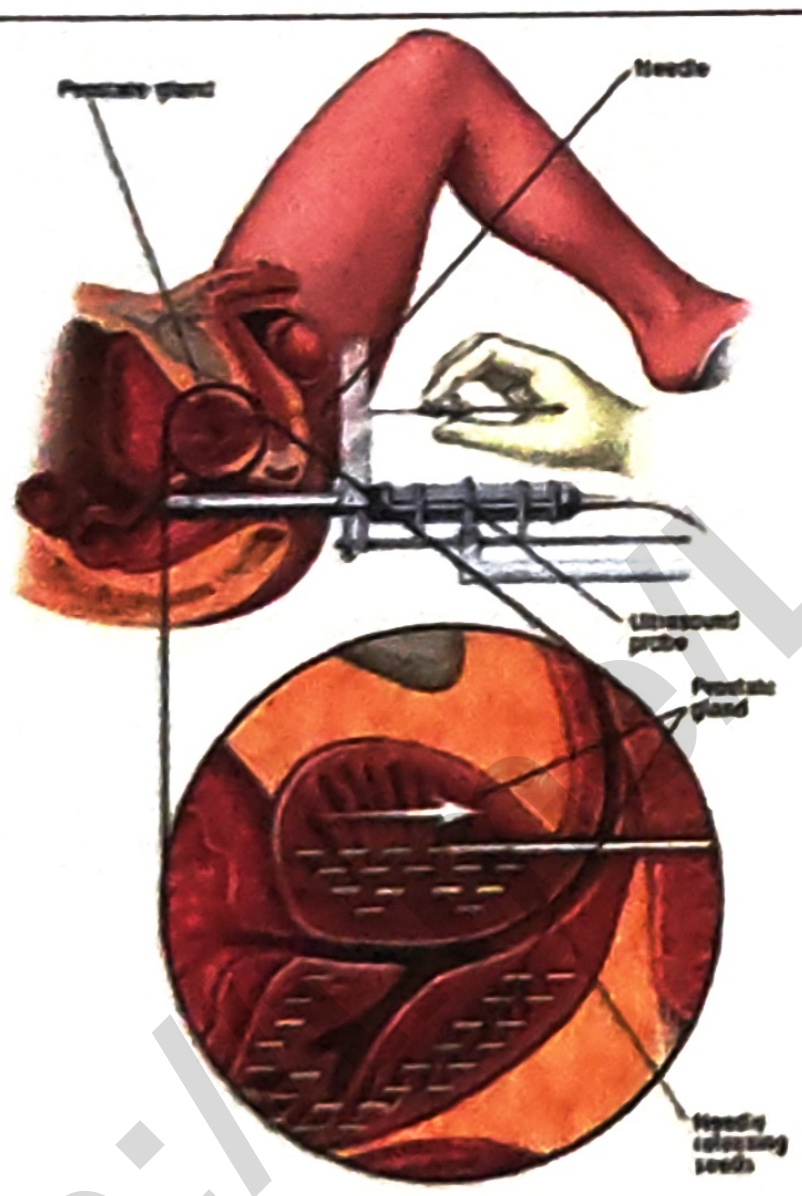

Brachytherapy of Prostate



Remote After loading Technique

Mold Brachytherapy

- → Radioisotopes are kept in contact with epithelial surfaces

Mold Brachytherapy

https://Latestneetpgnotes

Systemic Radiotherapy 00:02:28

→ Radioisotopes given orally or injected

I^{131}	Beta And Gamma Emitter	Thyroid Metastasis
P^{32}	Beta emitter	Polycythemia Vera
Strontium	Beta emitters	Bone metastasis
Samarium	Beta and Gamma Emitter	Bone metastasis

→ Iodine 131

- $t^{1/2}$ → 8 days
- Used in Systemic Radiotherapy for Thyroid metastasis
- Beta & gamma emitter
- Killing of cancer cells is by Beta rays
- Most carcinogenic Radioisotope

Pure Beta - emitters

→ Yttrium

→ Phosphorus

→ Strontium

Radio sensitizers Vs Radio protectors 00:05:25

Radio sensitizers	Radio protectors
• Hyperbaric oxygen • (Hypoxic tumors → radio resistant)	• Amifostine - Does not cross BBB
• Metronidazole • Misonidazole	• Pentoxiphylline
• Cisplatin	• IL - 1
• 5FU, gemcitabine	• GM-CSF
• Hydroxyurea	

https://t.me/Latestneetpgnotes

Law of Bergonie

00:08:28

→ This law states that

- Undifferentiated cells (cells with high mitotic activity) are - Radiosensitive
- Quiescent well differentiated cells are - Radioresistant

Radiosensitive	Radioresistant
• Nephroblastoma (AKA Wilm's tumor) • Medulloblastoma • Pinealoblastoma • Ewing's sarcoma • Lymphoma • Myeloma • Seminoma / Dysgerminoma	• Nervous tissue • Stratified squamous epithelial cells of vagina

Cell cycle

00:10:35

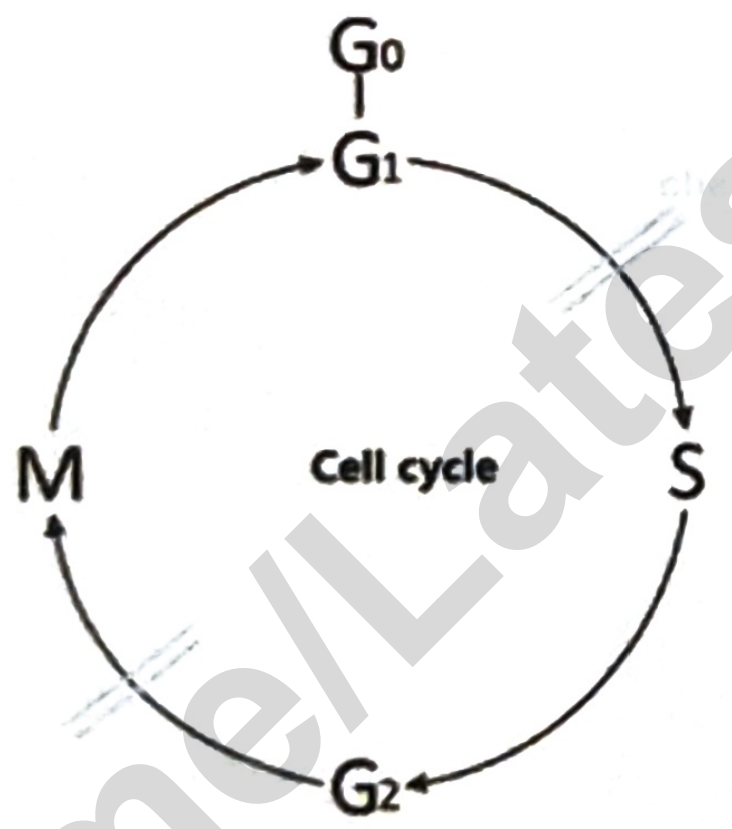

→ The checkpoints of cell cycle are controlled by - p53 gene

→ Three proteins work in coordination with p53 gene

- p21 - Arrest cell cycle
- GADD 45 - DNA repair gene
- BAX - Apoptotic gene

Note:

→ When Radiotherapy is given it causes extensive DNA damage that can't be repaired by GADD 45 and undergoes apoptosis by activation of BAX gene

→ If a tumor is associated with p53 mutation (Li Fraumeni syndrome) - it become Radioresistant

https://t.me/Latestneetpgnotes

→ Radiotherapy at G1 Phase cause - Chromosomal damage
→ Radiotherapy at G2 Phase - Chromatid damage

→ Most radiosensitive phase of cell cycle - G2M Phase > M phase
→ Most radio resistant phase - Late S phase

→ Most radio sensitive tissue - Bone marrow/ Gonads
→ Most radio resistant tissue - Nervous tissue

→ Most radio resistant organ – Vagina

→ Most radio sensitive Blood cell - Lymphocyte
→ Most radio resistant blood cell - Platelet

Craniospinal irradiation 00:18:03

→ It is done in

- Medulloblastoma - Prophylactic Craniospinal irradiation is done because of its drop metastases
- Pinealoblastoma
- Non-Hodgkin's lymphoma
- ALL
- Small cell Ca

Note: 00:20:40

→ MC hormone deficient after Craniospinal irradiation - GH Deficiency

→ MC thyroid cancer that develops after head neck radiation - Papillary Carcinoma of Thyroid

→ Papillary Ca of Thyroid has

- Psammoma bodies
- Orphan Annie nuclei
- Associated with Thyroglossal nuclei

https://t.me/Latestneetpgnotes

PrepLadder

For more free ebooks and notes, visit

https://t.me/Latestneetpgnotes

Or click this page to join

→ Thyroid cancer that develops in a case of long - standing goiter - Follicular carcinoma of Thyroid

→ Follicular carcinoma of Thyroid has

- Hematogenous spread
- Hurthle cells
- FNAC cannot be used to differentiate Benign follicular adenoma from Follicular carcinoma of Thyroid

→ Dose of RT that is deposited in treatment of bone metastasis

- 8 Gy is single fraction (has longer period of pain relief

https://t.me/Latestneetpgnotes

PrepLa

Chapter 18

GASTRO INTESTINAL RADIOLOGY - I

Barium Swallow Studies

00:00:30

Esophageal webs

→ Seen associated with Patterson kelly Syndrome / Plummer - vinson Syndrome

→ Webs are present in upper part of esophagus

→ Shows proximal pooling of barium on barium swallow

Esophageal Webs

Zenker's diverticulum

→ False diverticulum - since only mucosa is out pouching

→ It is a posterior midline out pouncing

→ IOC is Barium swallow

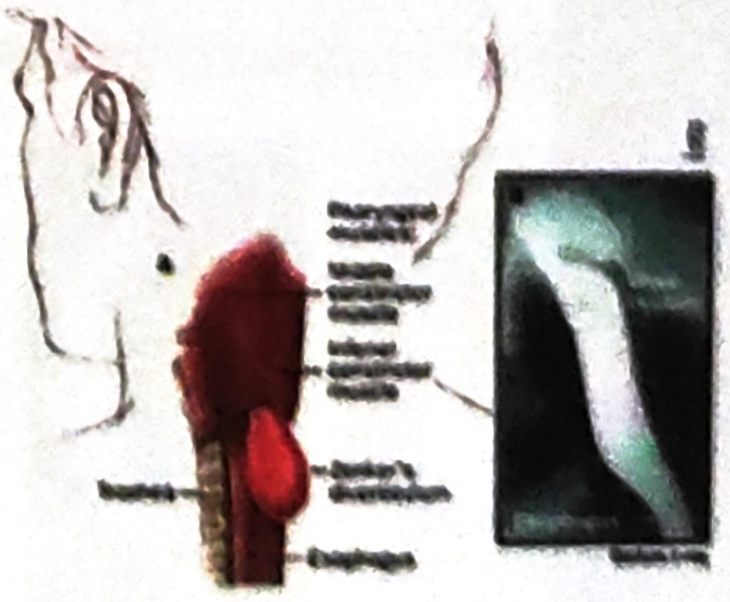

Zenker's diverticulum

https://t.me/Latestneetpgnotes

PrepLadder

Diffuse esophageal spasm

→ Gives cork screw appearance of esophagus on barium swallow

Cork screw esophagus

Esophageal varices

→ Gives serpentine / worm like filling defects on barium swallow

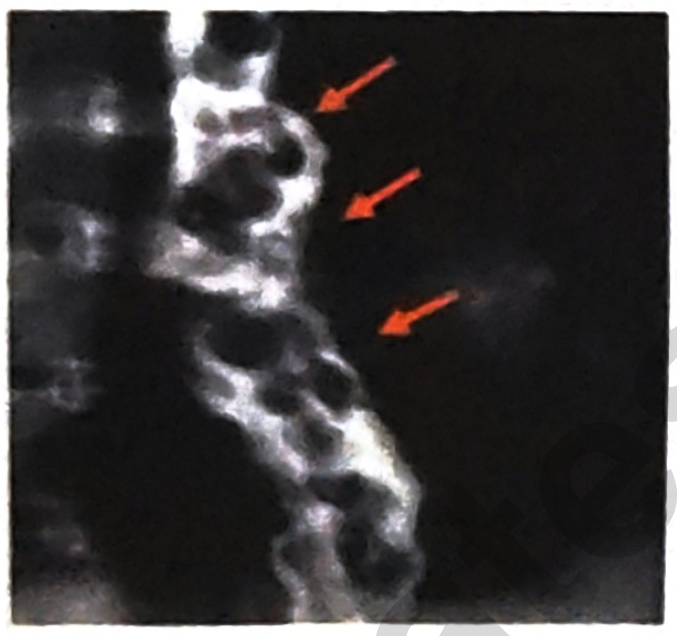

Esophageal varices

Hiatus hernia/ Sliding hernia

→ Herniation of a part of stomach into thorax through diaphragmatic opening is known as hiatus hernia

→ IOC is barium swallow



Hiatus hernia

https://t.me/Latestneetpgnotes

PrepLadder

Congenital Diaphragmatic hernia

00:06:00

→ It is a defect in pleuroperitoneal membrane

→ 2 types:

1) Bochdalek hernia (M/C) - Left posterolateral defect

2) Morgagni hernia - Right anteromedial defect

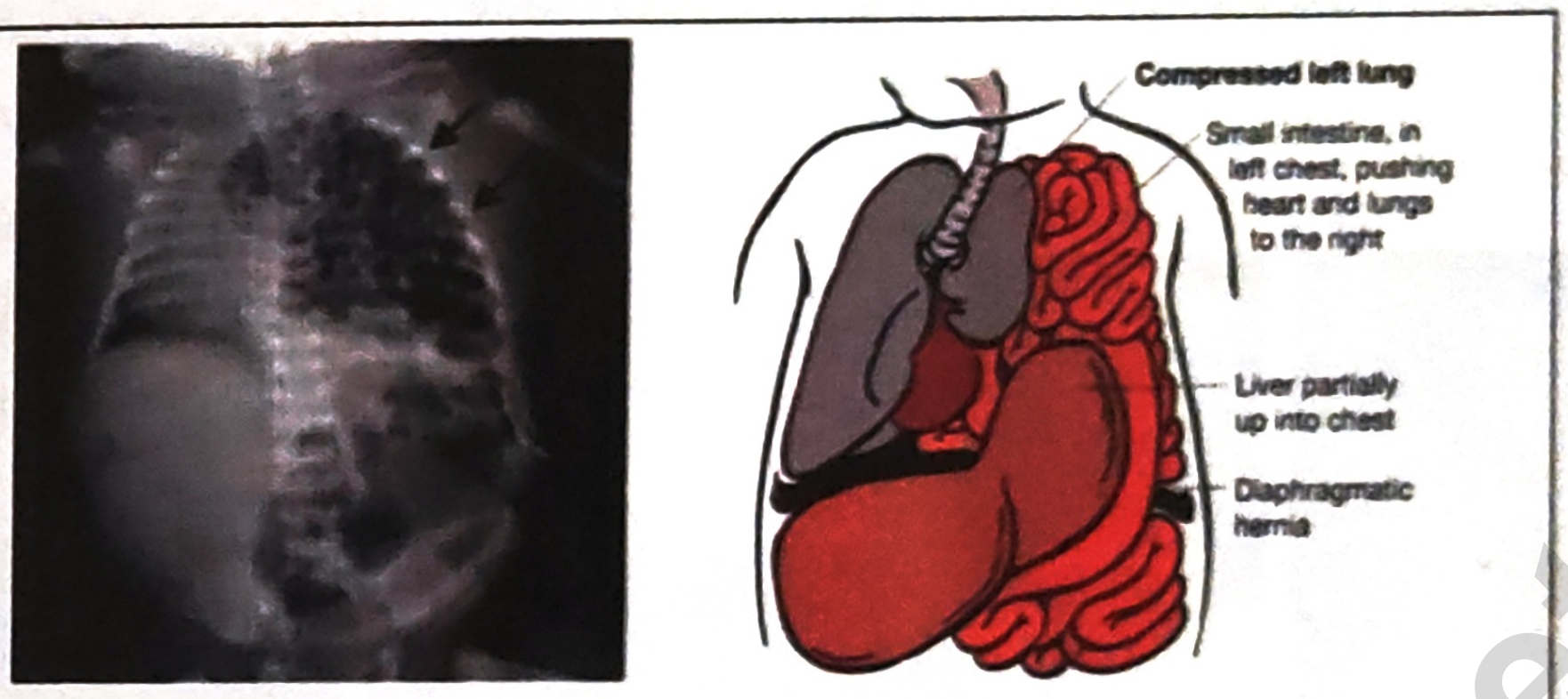

Congenital Diaphragmatic hernia

→ In a chest radiograph - multiple dilated bubble loops can be seen

Schatzki's Ring

00:07:45

→ Mucosal ring in lower end of esophagus

Schatzki's Ring

Achalasia Cardia

→ Barium swallow shows bird beak or rat tail appearance

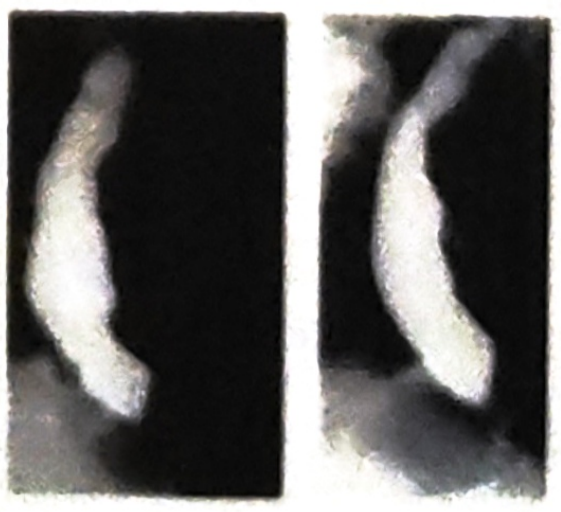

Achalasia Cardia

https://t.me/Latestneetpgnotes

PrepLadder

Note:

→ Rat tail appearance with shouldering is seen in esophageal Carcinoma

Scleroderma 00:11:26

→ Shows dilated aperistaltic patulous appearance of esophagus on barium swallow

→ Has soft calcinosis in hand

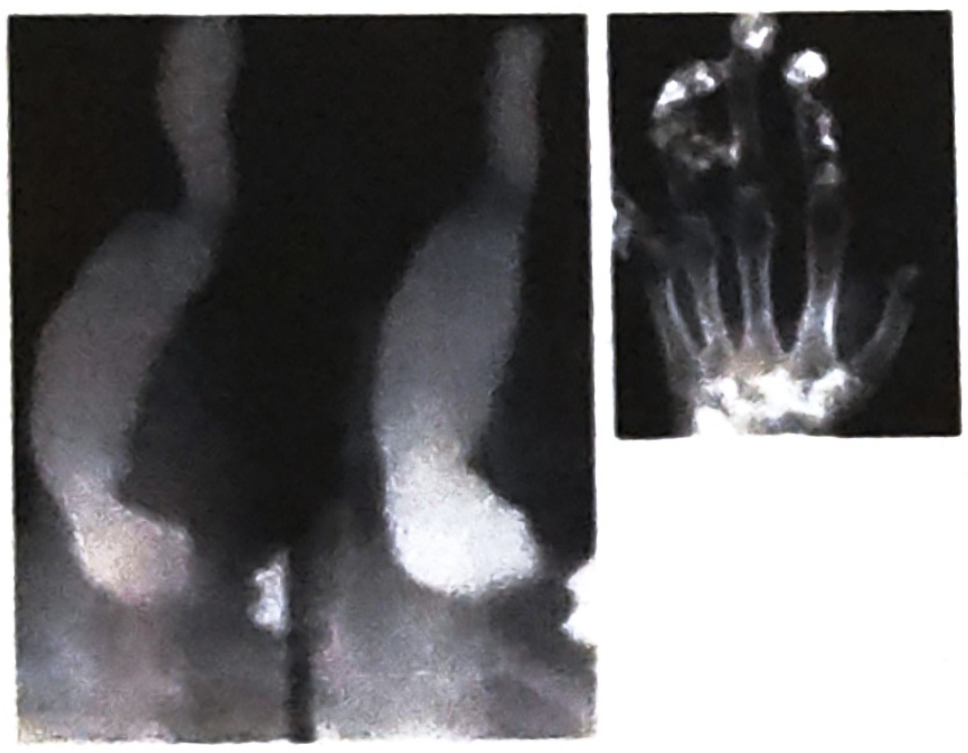

Scleroderma

Congenital hypertrophic pyloric stenosis 00:12:00

→ MC in 1st born male child

→ Present with non-bilious vomiting, at 3-12 weeks of age

→ Classical feature is metabolic alkalosis with paradoxical aciduria

→ IOC is USG



Hypertrophic Pyloric Stenosis

→ In USG

- Target sign
- Cervix sign → Indentation of muscle mass on fluid filled antrum
- Antral nipple sign → Redundant pyloric canal mucosa protruding into gastric antrum

https://t.me/Latestneetpgnotes

- Has Pyloric Ms. wall thickness > 3 mm
  Pyloric length > 16mm

→ On barium study
- String Sign
- Diamond / Twinning sign
- Mushroom sign
- Double track sign
- Caterpillar sign - because of gastric hyperperistalsis

→ In CHPS = because of continuous vomiting & gastric hyperperistalsis there will be ↓sed gastric residue.

Target Sign

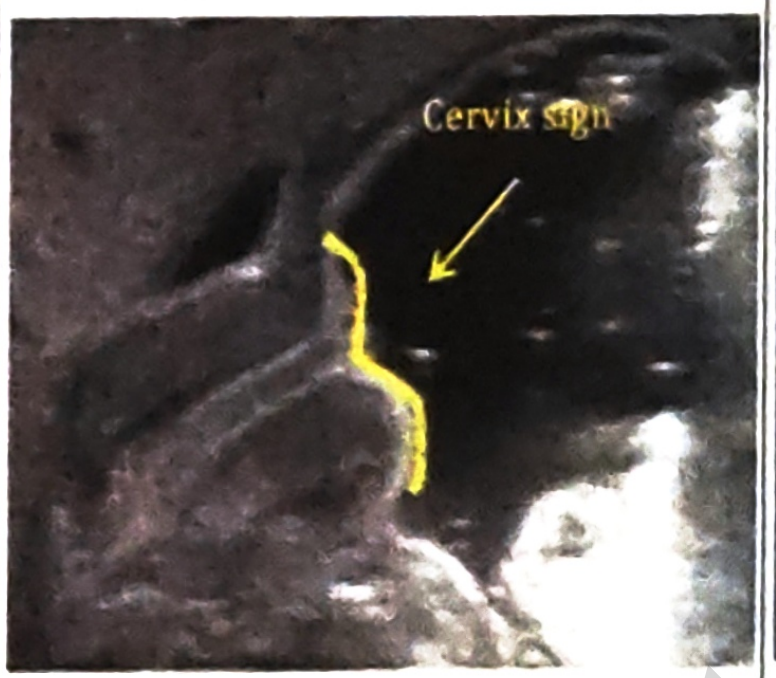

Cervix Sign


Antral nipple sign

String Sign

Double Track Sign

Mushroom Sign

Note:

In abdominal X-ray
→ Single bubble appearance = CHPS
→ Double bubble appearance = Duodenal atresia
→ Triple bubble appearance = Jejunal atresia
→ Multiple air fluid levels = ileal atresia

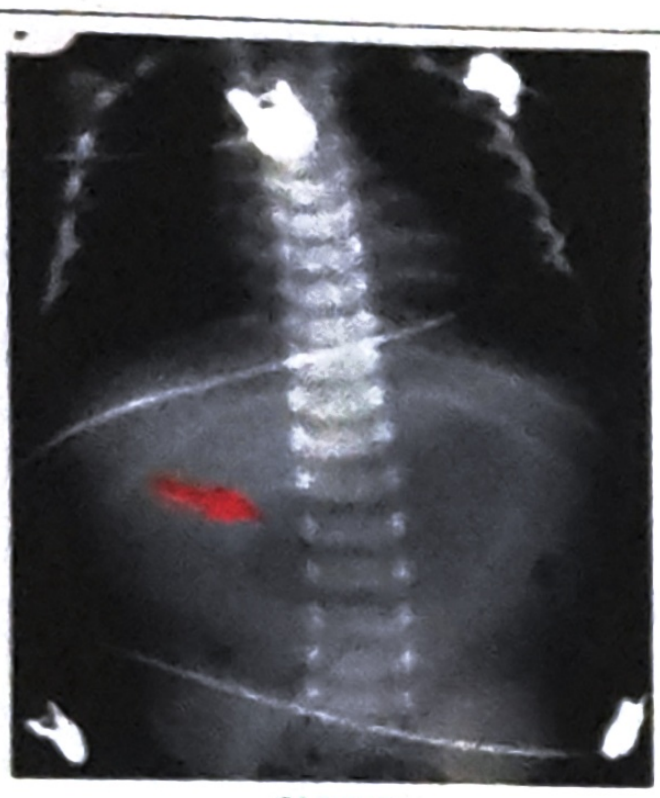 CHPS	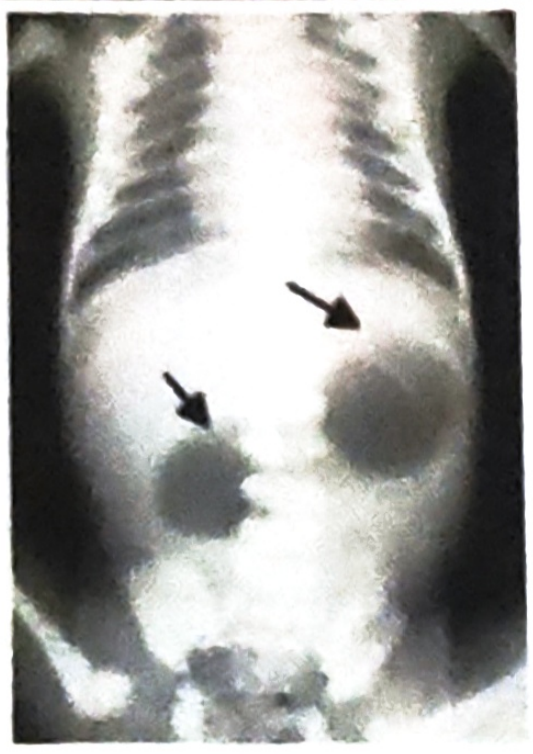 Duodenal atresia	 Jejunal atresia

Gastric Ulcers

00:22:48

Benign	Malignant
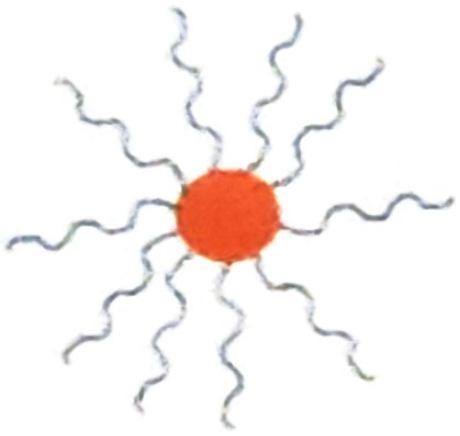 → Mucosal rugae extend up to ulcer base	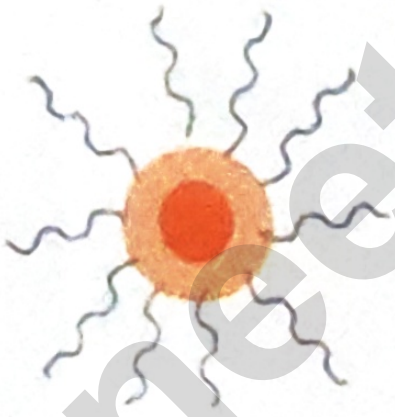 → Has aggressive infiltrated mass around ulcer → Rugae stops & don't reach ulcer base
On Barium meal: → Shows Hampton line ulcer collar 	On barium meal: → shows carmen meniscus sign 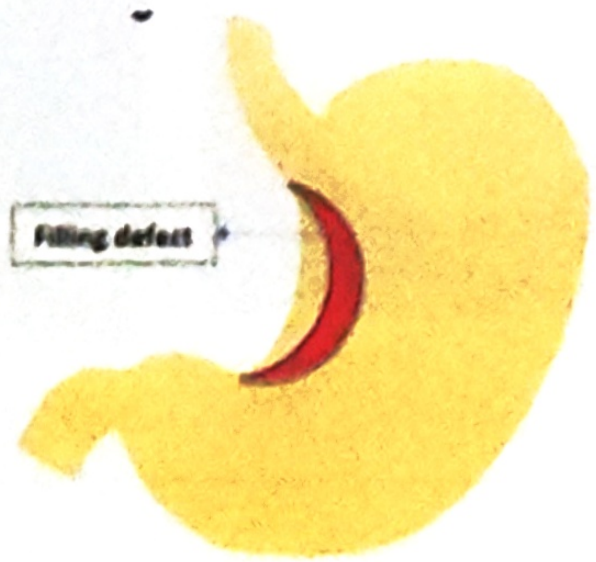
 Hampton's Line	 Carmen meniscus sign

https://t.me/Latestneetpgnotes

PrepLadder

Pneumoperitoneum

00:27:51

→ IOC - CT-scan (show air anterior to liver)

→ Best x-ray view - chest x-ray erect

On radiography

Cupola sign

1) Cupola Sign: air under central tendon of diaphragm
2) Doges cap sign: free air in Morrison's pouch
3) Falciform ligament sign:
   - Because of free air in abdomen all ligaments stand Out clearly
   - Falciform ligament sign / ligament teres sign /
   - lateral umbilical ligament / inverted V sign /
   - Median umbilical ligaments / urachus sign
4) Football Sign:
5) Rigler's Sign: air on either side of bowl wall
6) Tell-e-tale triangle sign: Triangular air lucency

Doges Cap Sign

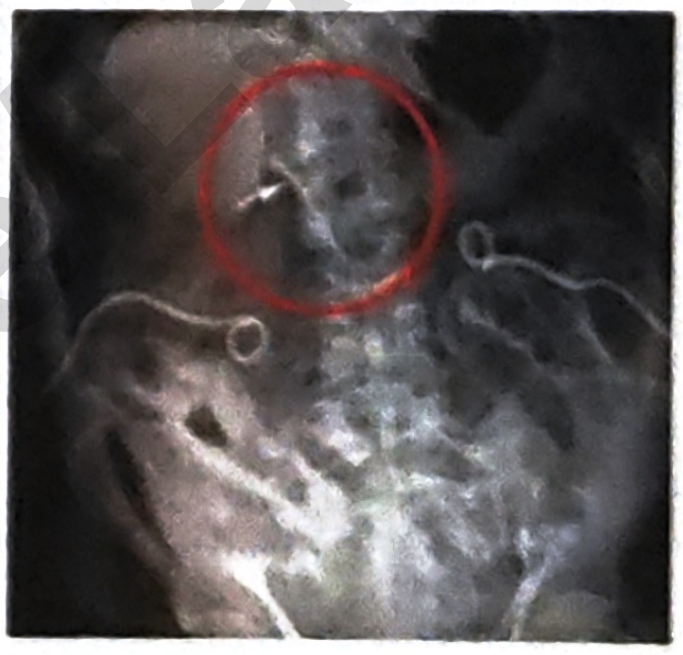

Falciform Ligament Sign

Football Sign

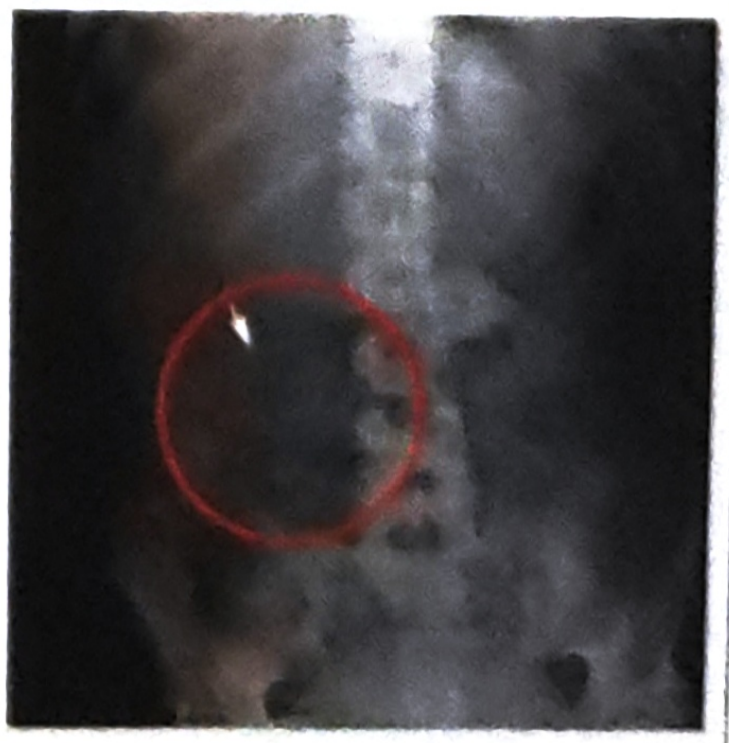

Rigler's Sign

https://t.me/latestneetpgnotes

PrepLadder

Triangle Sign

Ligamentum Teres Sign

Inverted V Sign

Urachus Sign

Note:

→ 2nd best x-ray view for pneumoperitoneum = left lateral decubitus

Pneumoperitoneum - left lateral decubitus view

https://t.me/Latestpgnotes

Pseudo pneumoperitoneum

→ Chilaiditi sign:

- A normal variant - a part of bowel interposed between right dome of diaphragm & liver

→ Subphrenic abscess

→ Subpulmonic pneumothorax

→ Basal atelectasis

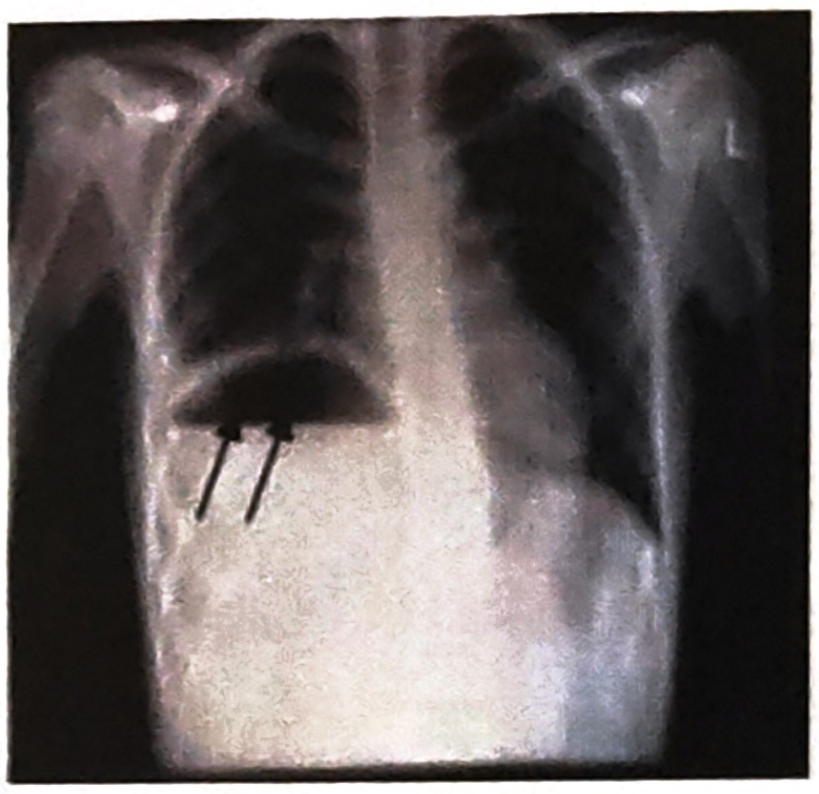

Subphrenic abscess

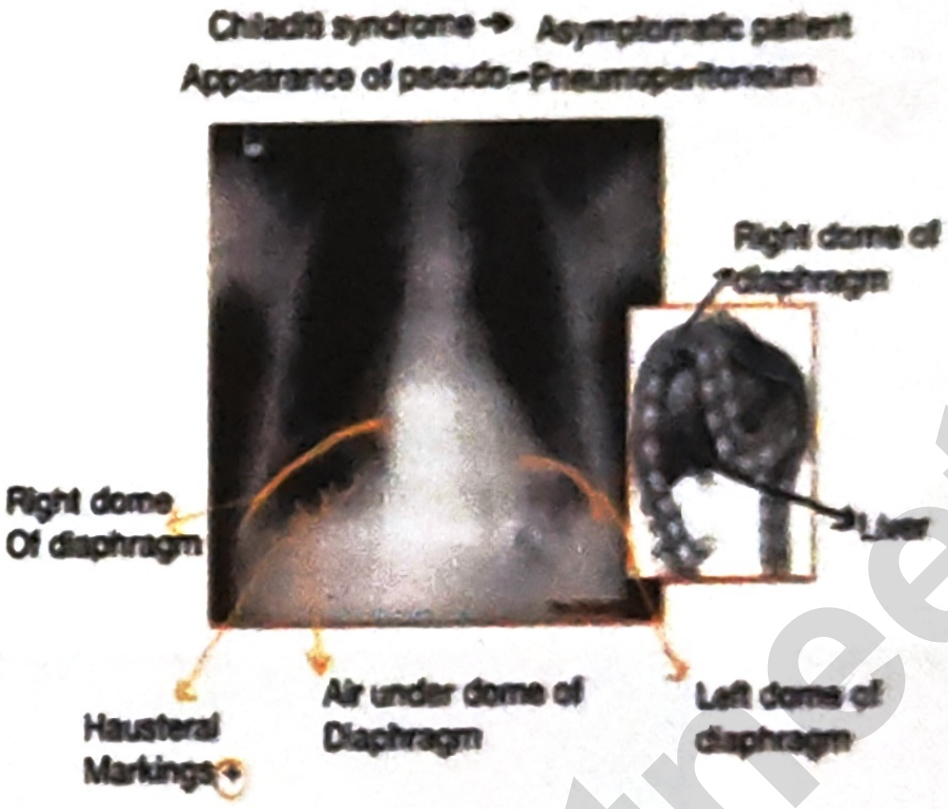

Chilaiditi Sign

https://t.me/Latestreetpgnotes

PrepLadder

Chapter 19

GASTRO INTESTINAL RADIOLOGY - II

Ileal atresia 00:00:40

→ On barium enema

- Microcolon
- Apple peel appearance
- Multiple air fluid levels

Microcolon

Multiple air fluid levels

Meconium ileus

→ Soap bubble appearance in RIF on abdominal X-ray

Soap bubble appearance (X-ray)

https://t.me/...etpgnotes

PrepL

Note:

→ Soap bubble appearance around knee - GCT / Osteoclastoma

→ Soap bubble appearance of mandible - Adamantinoma

→ Soap bubble appearance on MRI brain - Cryptococcus

→ Soap bubble appearance on Antenatal scan - Multicystic dysplastic kidney

Inflammatory bowel Disease 00:04:11

Crohn's disease	Ulcerative colitis
→ Terminal ileitis	→ Rectum
→ Skip areas 	→ Continuous → Backwash ileitis
→ has transmural involvement	→ has superficial involvement
→ Signs seen • Target sign / halo sign • Comb sign • Rose thorning sign • Creeping fat sign • String sign of kantor	→ Sign Seen • Mucosal granularity • Lead pipe appearance • Collar button sign • Loss of haustration
→ Earliest finding • Aphthous ulcer - gives cobblestone appearance in bowel Note: → Cobblestone appearance in oesophagus-Candida	→ Earliest finding • Mucosal granularity
→ Has Pseudo sacculation → Has rectal sparing / fibrosis / strictures/ Gut shortening	→ Has Pseudo polyps & crypt abscesses

https://t.me/Latestneetpgnotes

PrepLadder

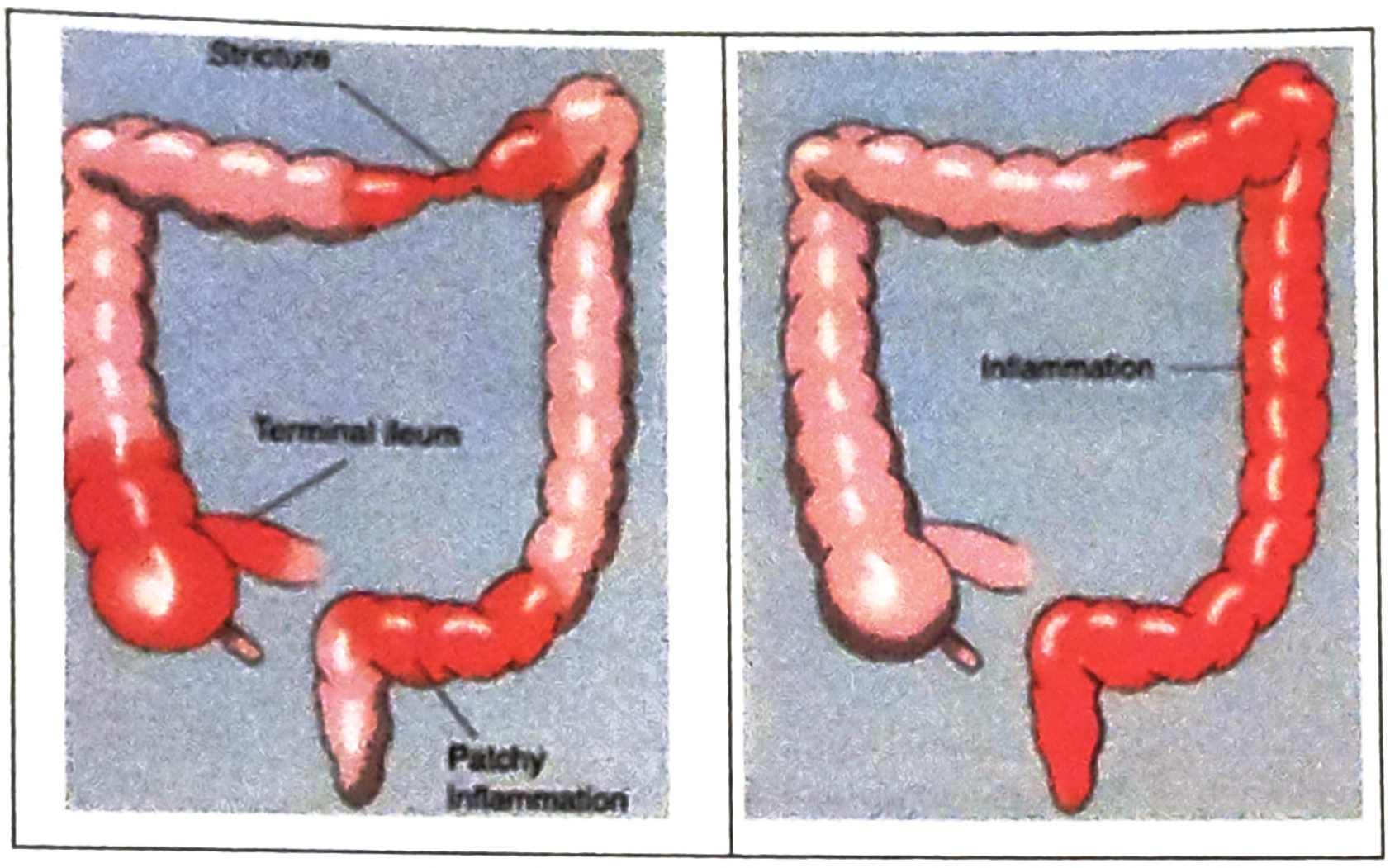
Stricture
Terminal ileum
Patchy
inflammation
Inflammation

Cobblestone appearance:
due to deep fissuring
ulcers around inflamed
mucosa

Aphthoid ulcers
(target sign)
Pathology: mucosal ulcers with surrounding translucent mound of edema.

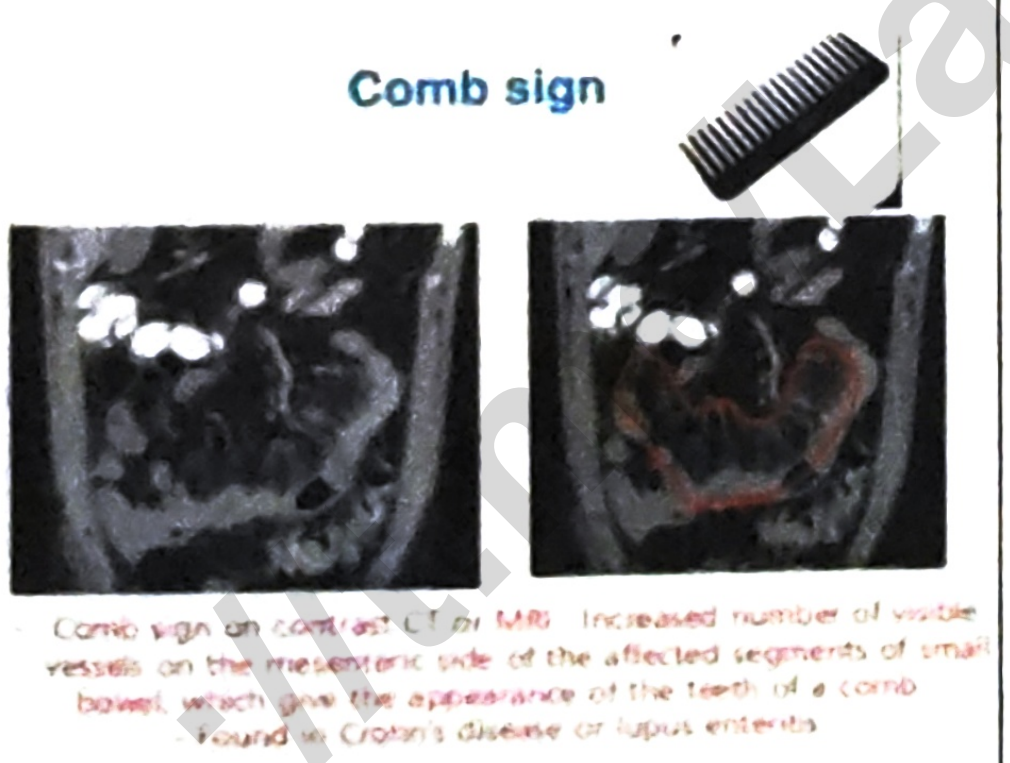
Comb sign
Comb sign on contrast CT or MRI. Increased number of visible vessels on the mesenteric side of the affected segments of small bowel, which give the appearance of the teeth of a comb
- Found in Crohn's disease or lupus enteritis

The Fat Halo Sign
The fat halo sign is seen on CT scans of the abdomen and appears as a thickened bowel wall demonstrating three layers: an inner and an outer layer of soft-tissue attenuation, between which lies a third layer of fatty attenuation

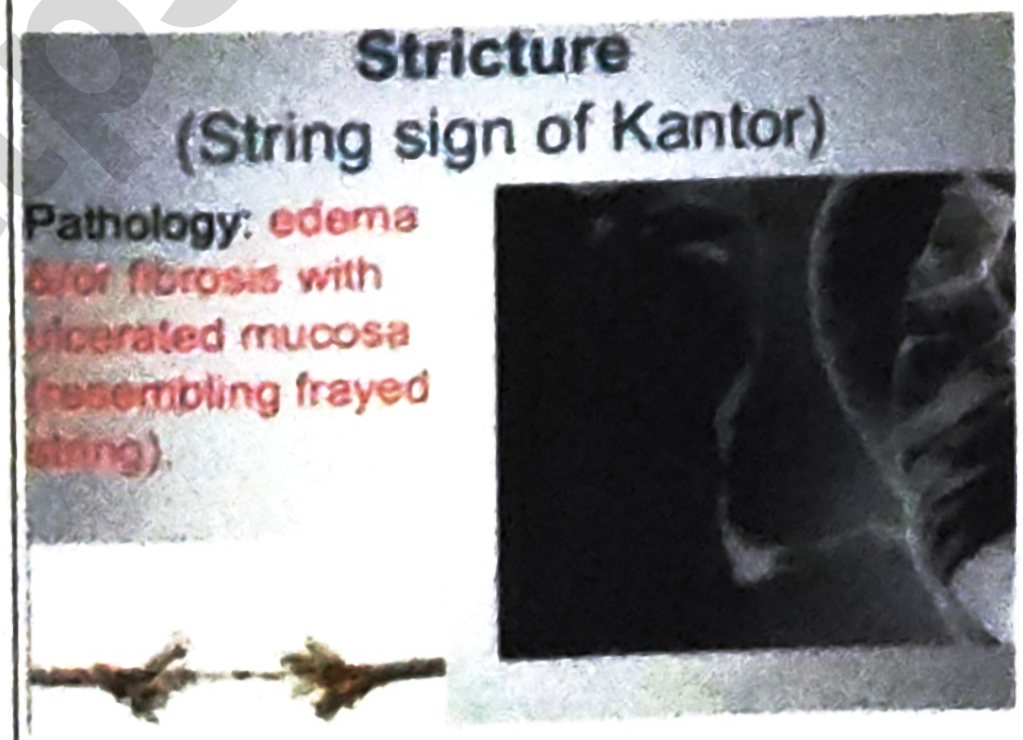
Stricture
(String sign of Kantor)
Pathology: edema &/or fibrosis with ulcerated mucosa (resembling frayed string).

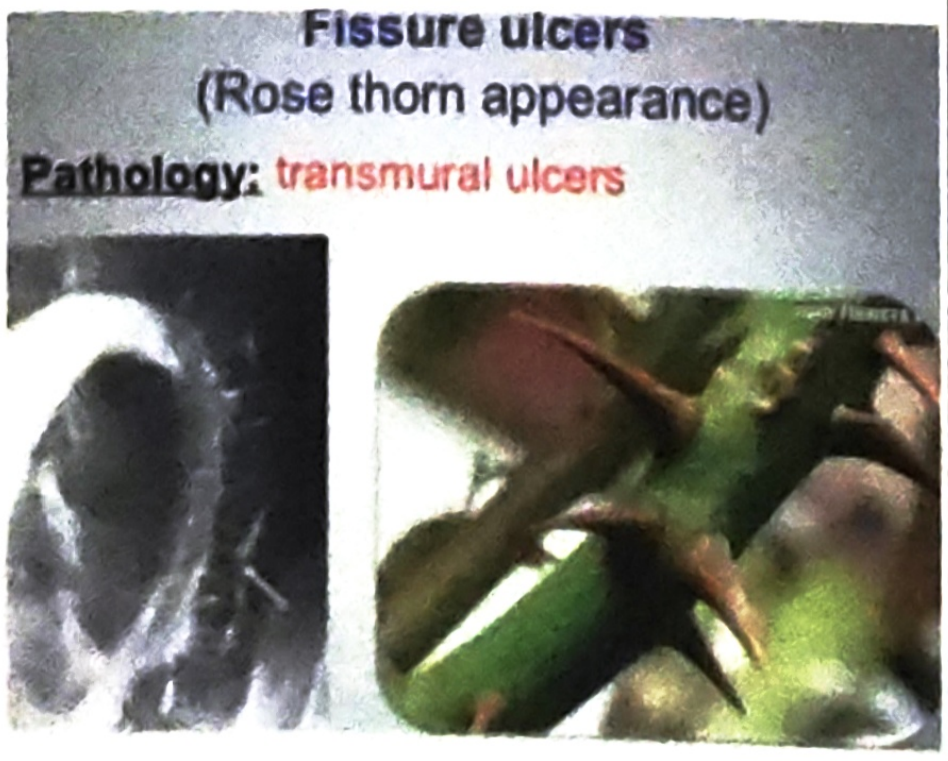
Fissure ulcers
(Rose thorn appearance)
Pathology: transmural ulcers

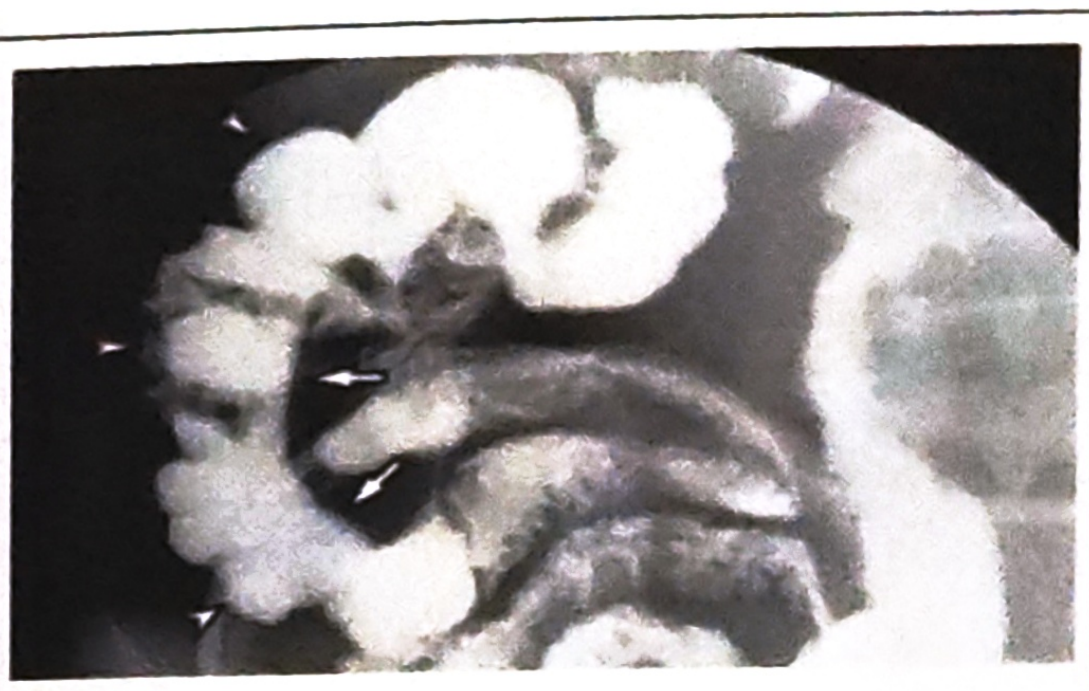

Pseudosacculations

Lead pipe appearance of colon

Ischemic Colitis 00:16:00

→ Thumb print appearance on abdominal radiograph because of edematous mucosa due to ischemia.

→ M/C site - Splenic flexure (Watershed area of colon)

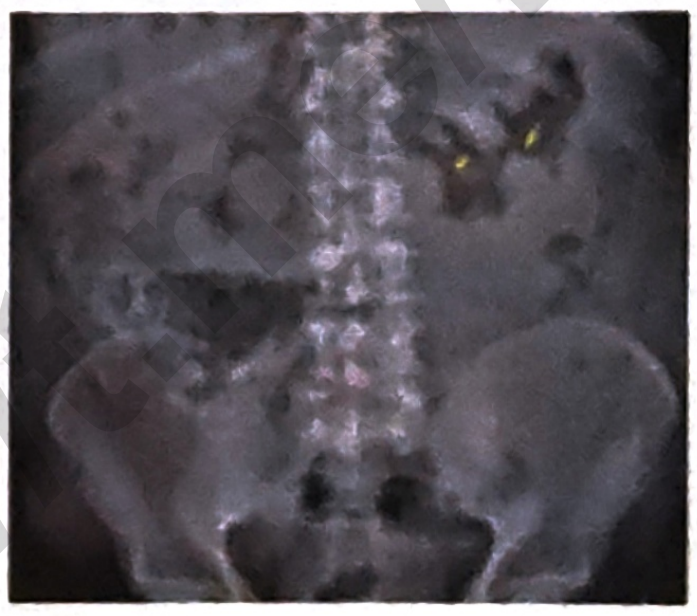

Thumb print appearance (X-ray)

Ileocecal TB 00:16:53

→ has obtuse ileocecal angle & pulled up cecum

→ Thickened ileocecal valve - Fleischer sign / inverted umbrella sign

→ Retracted, fibrosed cecum - Goose neck deformity

→ On Barium enema, pooling of barium in normal part & hyperperistalsis of barium in affected part is seen - Sterling sign

https://Latestneetpgnotes

→ Has transverse ulcers - leads to purse string or napkin ring stenosis (note: Typhoid-has longitudinal ulcers)

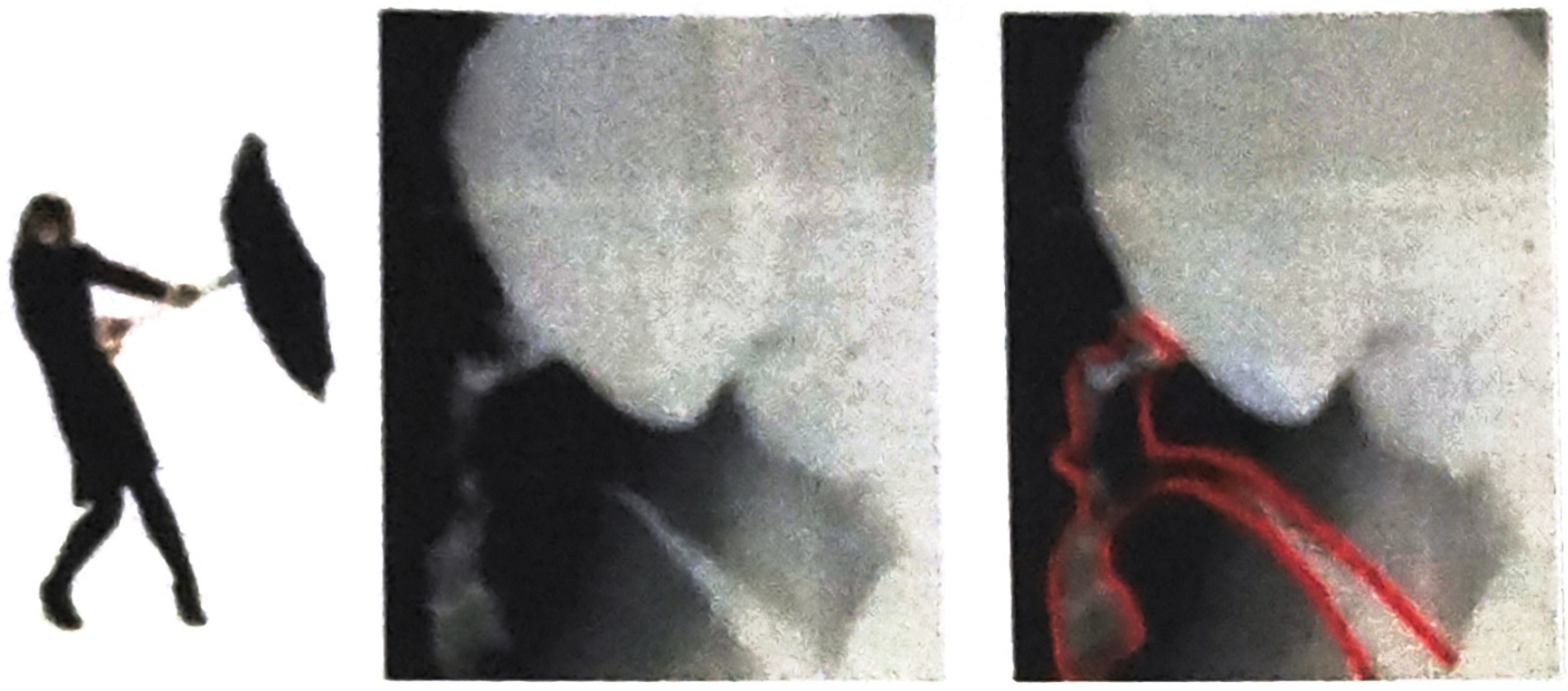

Fleischer sign / inverted umbrella sign

Goose neck deformity

Sterling sign

Intussusception 00:22:05

→ On a plain radiograph
- Meniscus sign

→ On USG
- Target sign / doughnut sign
- Pseudo kidney

→ On Barium
- Claw sign / pincer sign
- Coiled spring appearance

https://t.me/neetpgnotes

PrepLadder

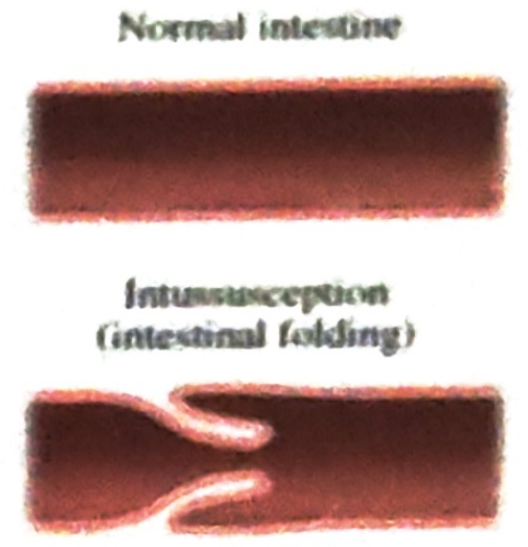

Cut-section of small intestine

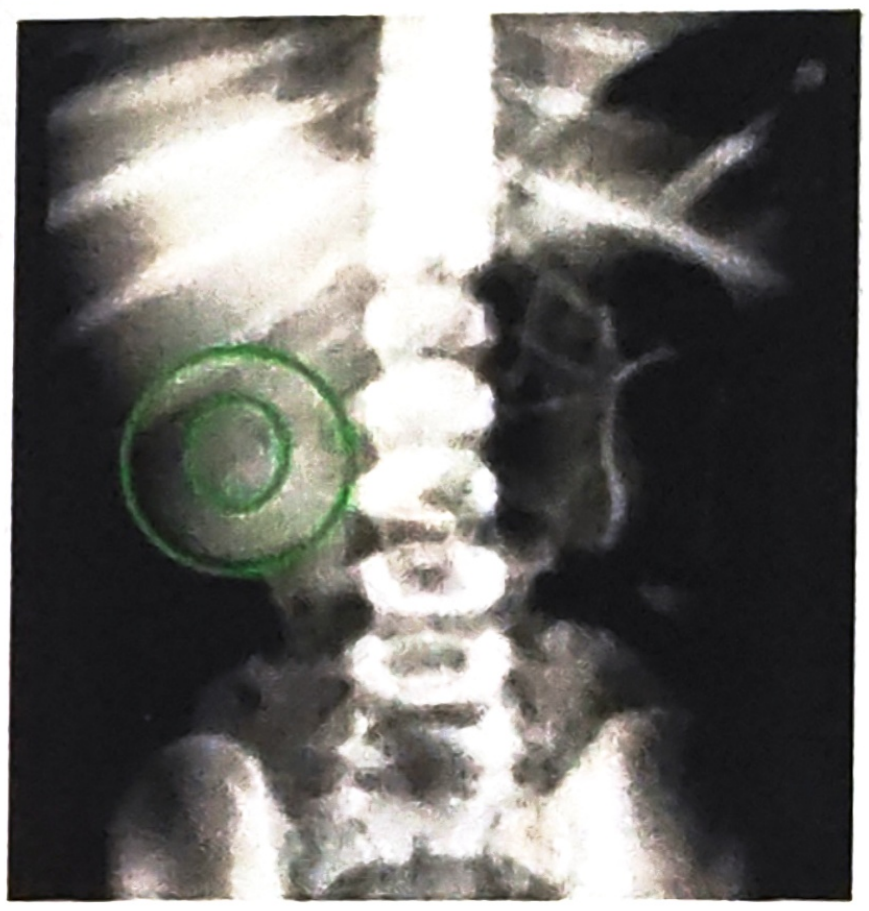

Target sign

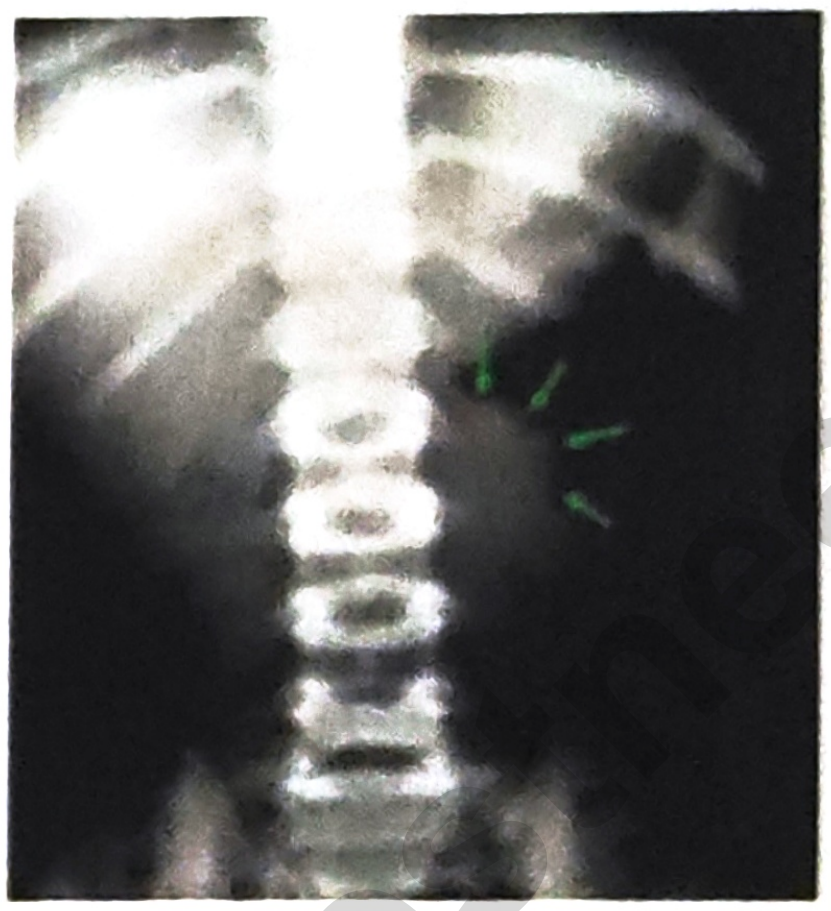

Meniscus sign

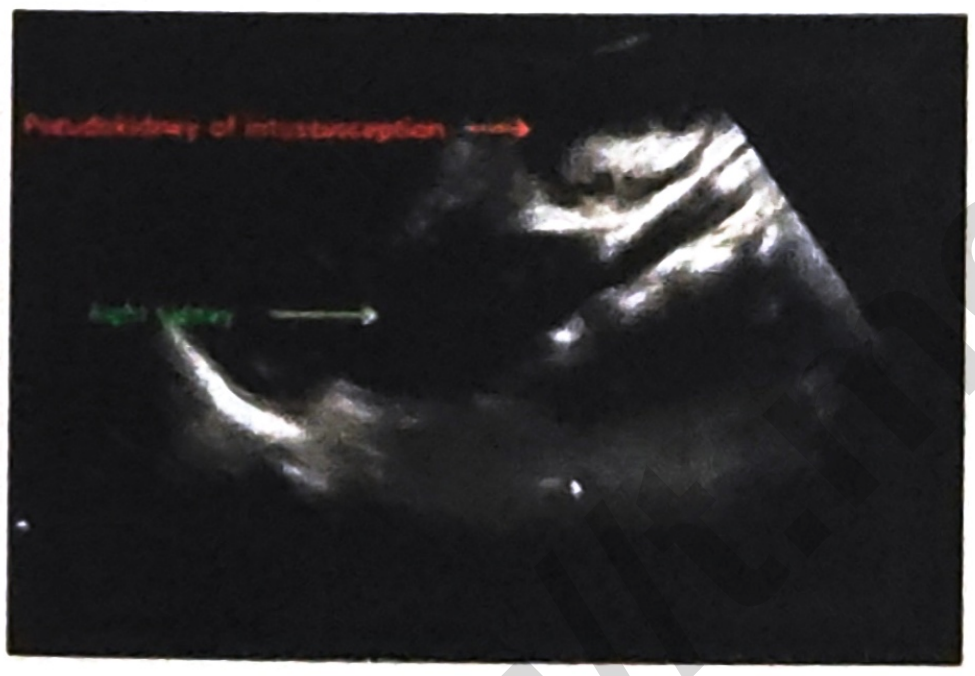

Pseudo Kidney

Target sign / doughnut sign

Claw sign / pincer sign

Coiled spring appearance

PrepLadder

Barium Study

- → Barium swallow - Oesophagus
- → Barium meal - Stomach & duodenum
- → Barium meal follow through - Small intestine
- → Barium enema - Large intestine

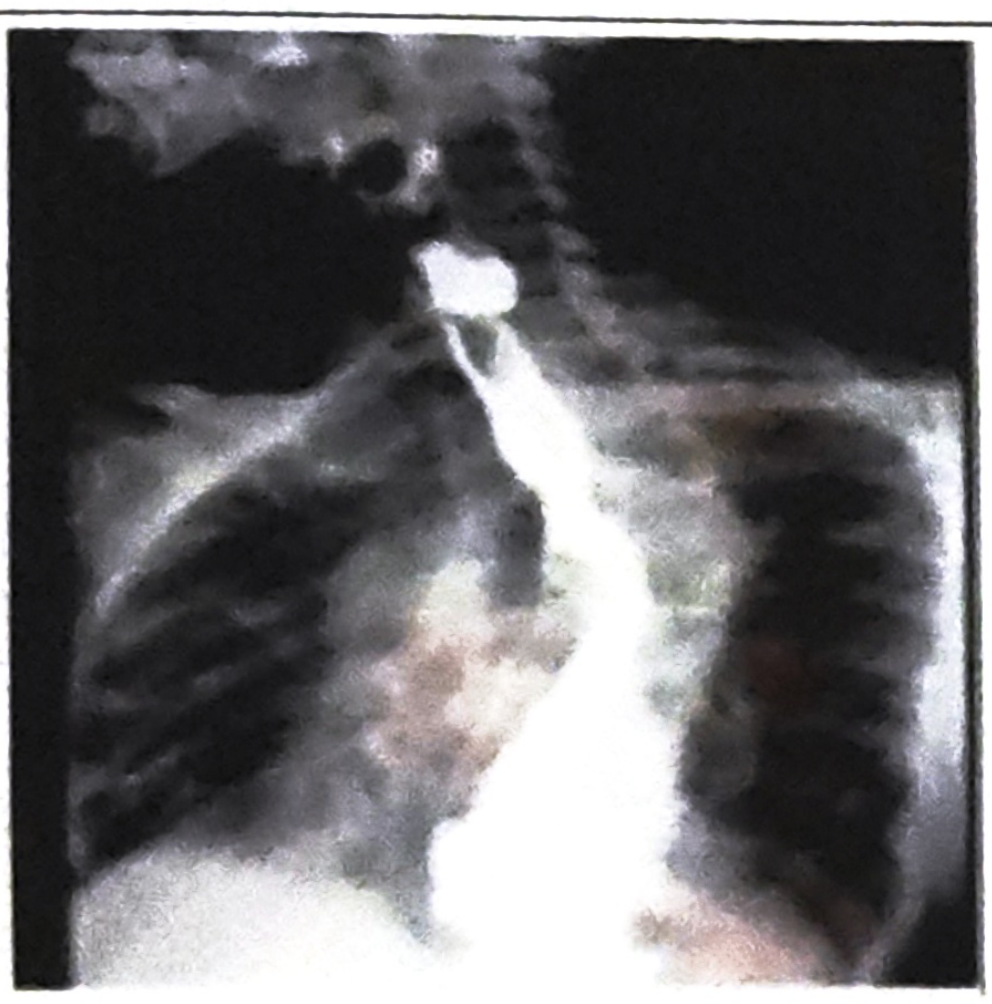

Barium Meal

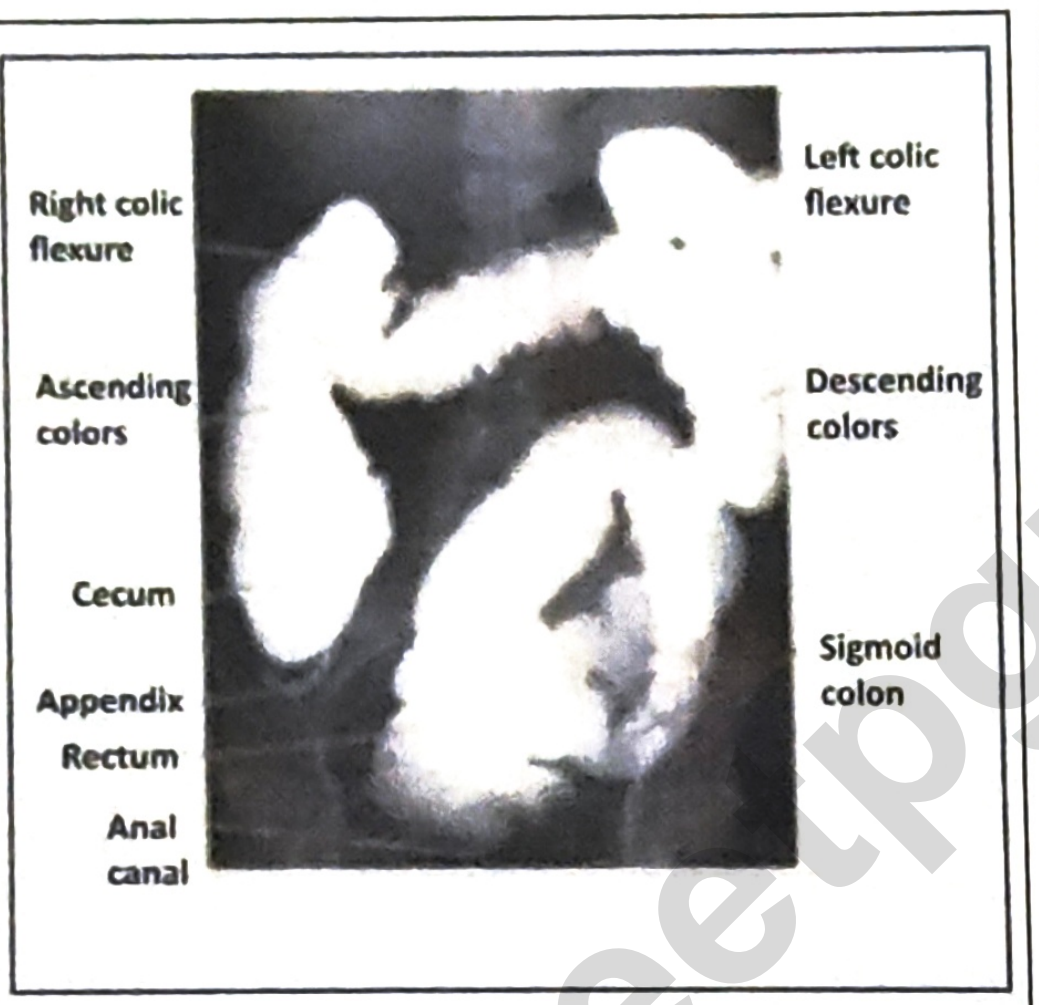

Barium enema

→ Barium meal - 2 type

1) Single contrast - only barium given
2) Double contrast - barium & air given (better)

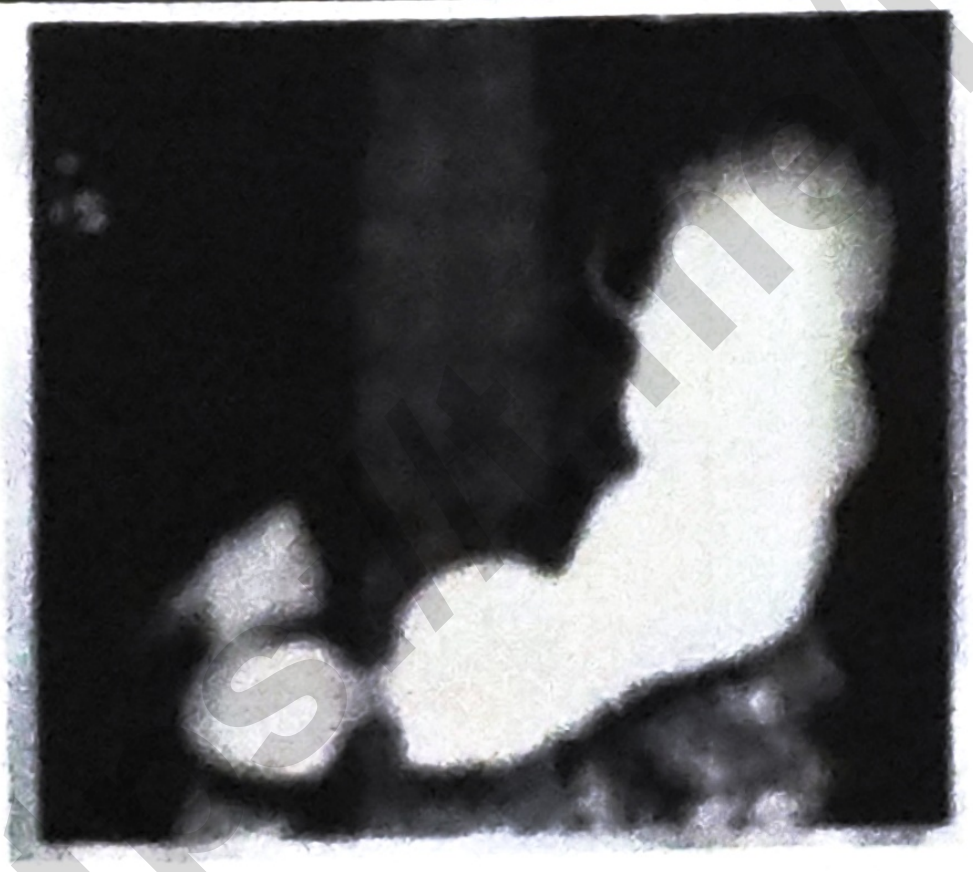

Single contrast

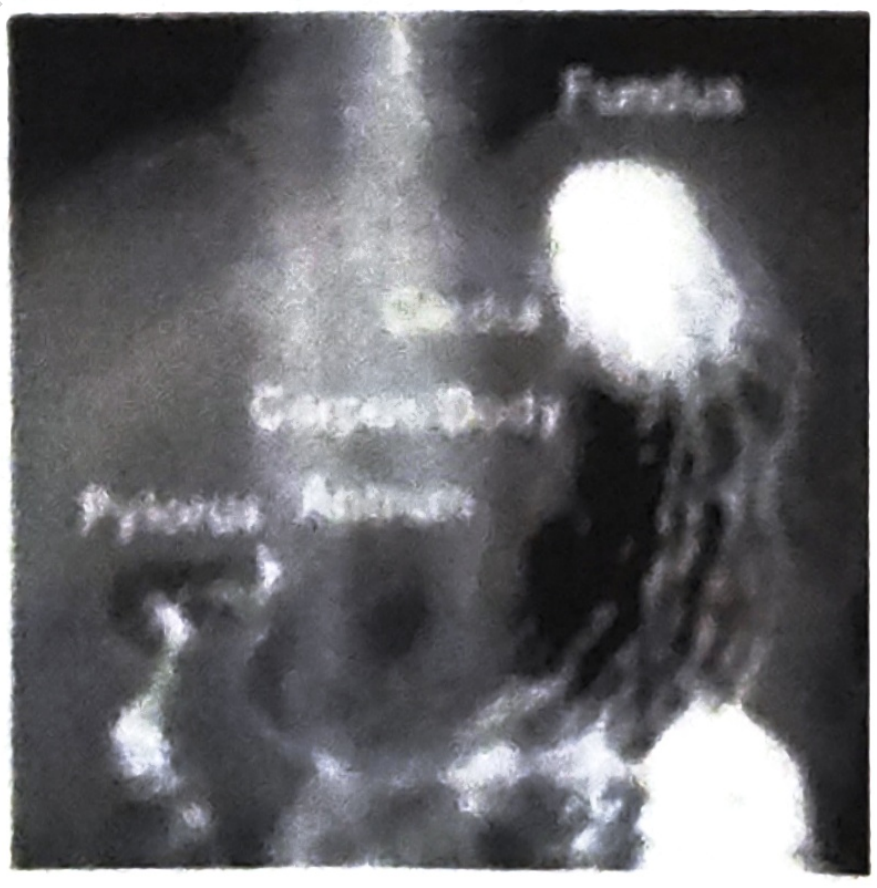

Double contrast

→ On Barium meal follow through

- Jejunum - Valvulae conniventes
- Ileum - Featureless

https://t.me/Latestneetpgnotes

Prepl

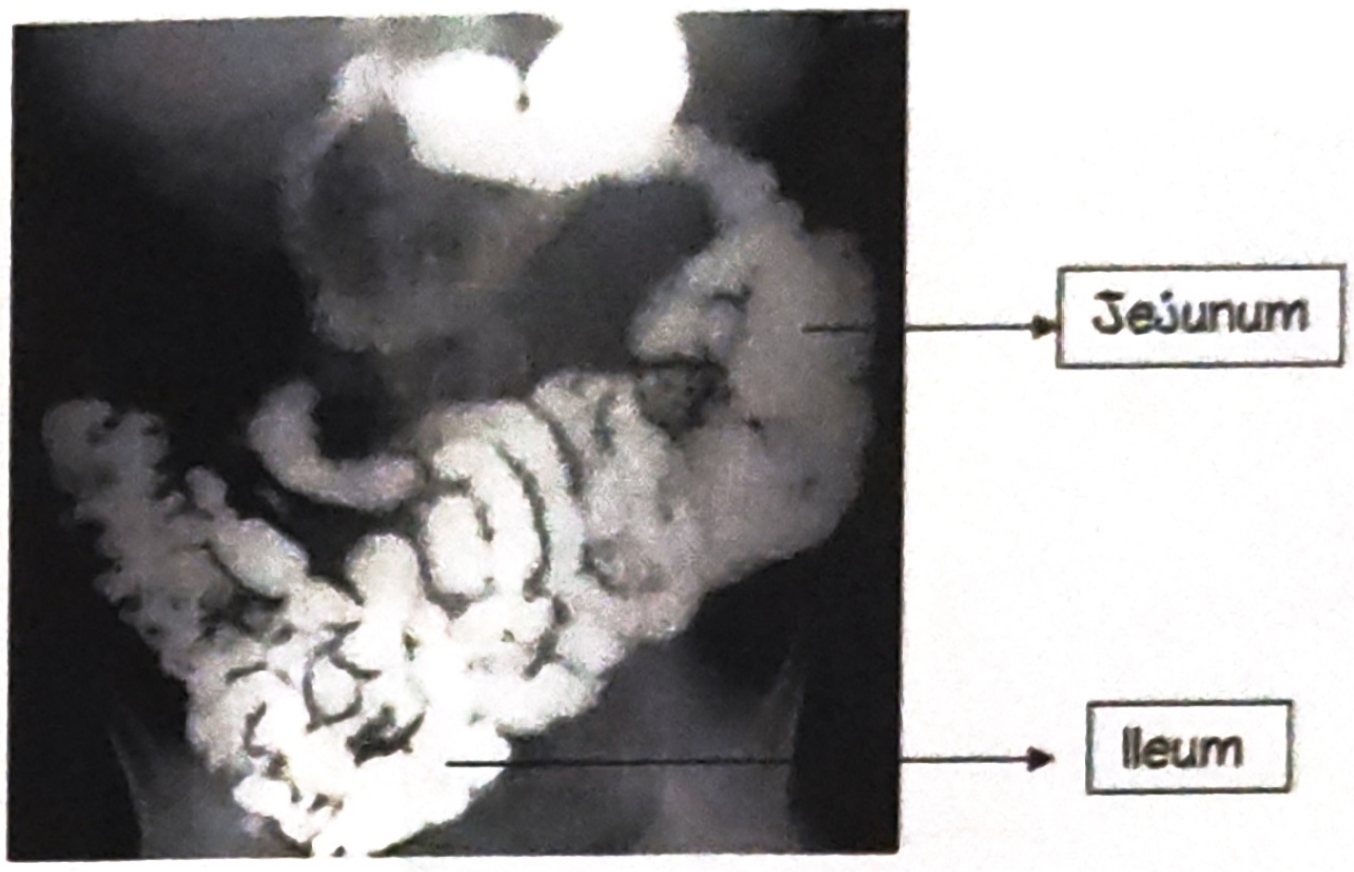

Barium meal follow through

Enteroclysis

00:28:51

→ Through NJ tube, barium is given directly to stomach & X-ray taken

→ If CT used - CT - enteroclysis

→ Double contrast is used ($BaSO_4$ & Methylcellulose)

→ If MRI used and fluid in bowel provides the MR signal - MR-enteroclysis

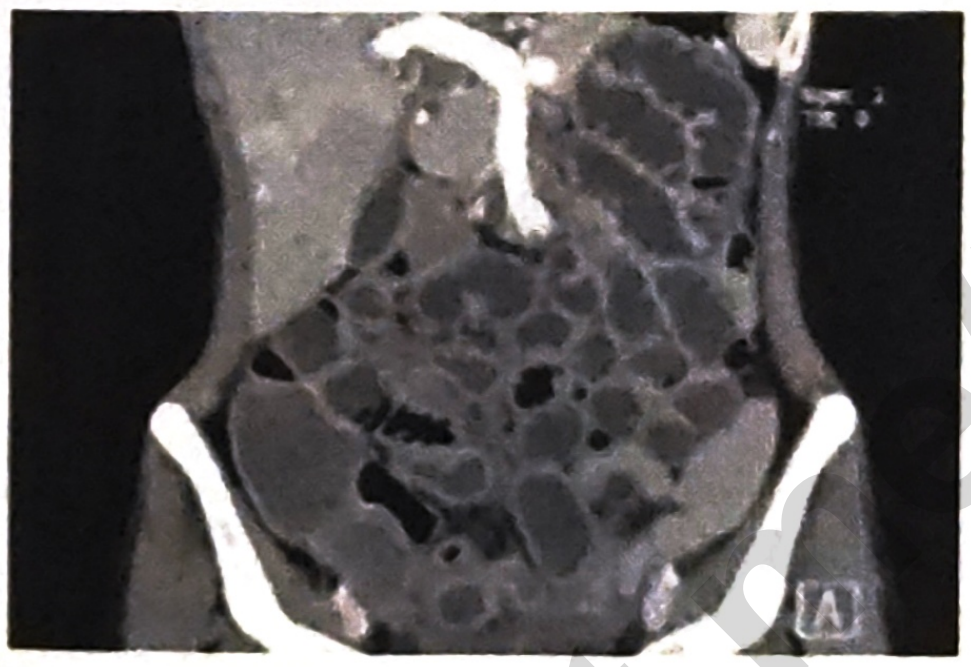

CT-Enteroclysis

MR - Enteroclysis

Pseudomembranous colitis

00:30:43

→ Accordion sign - Thick edematous mucosal wall seen in Pseudomembranous colitis and other nonspecific colitis, ischemic colitis

Accordion sign

https://t.me/neetpgnotes

PrepLadder

Ascariasis

Multiple Linear Lucencies

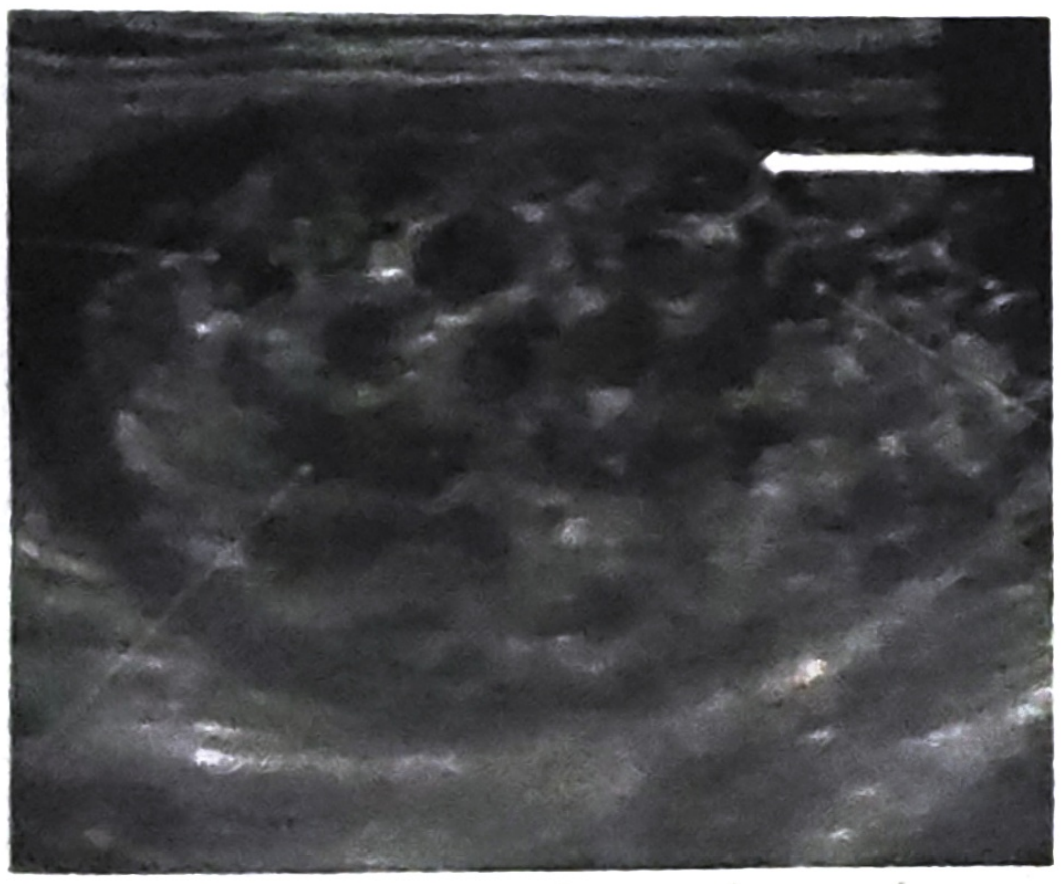



Medusa head appearance on USG

Shark mouth ileocecal valve

→ Normal appearance of ileocecal valve in colonoscopy

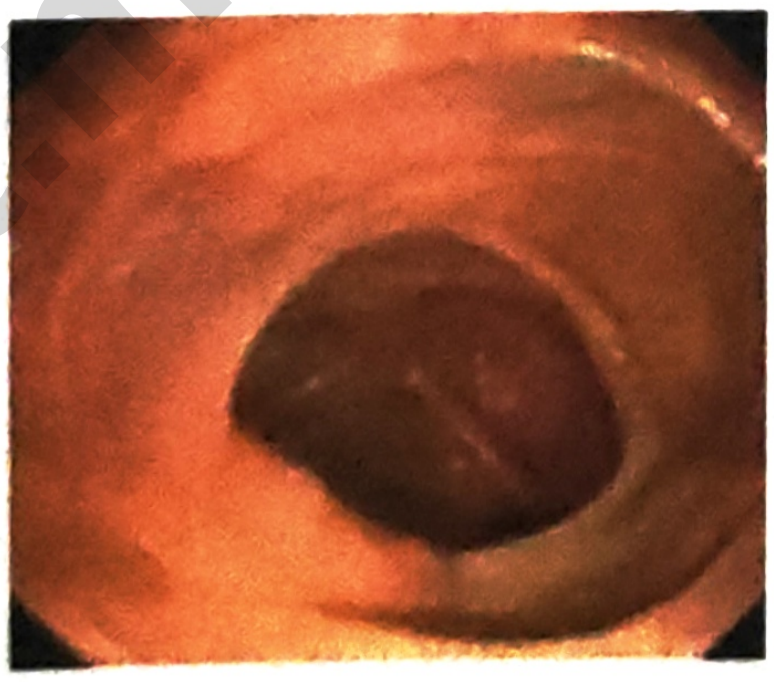

Shark mouth appearance

Diverticulosis 00:31:40

→ Has multiple outpouching on mesenteric side

→ M/C site is sigmoid colon

→ IOC for diverticulosis is barium enema (Saw tooth appearance)

→ IOC for diverticulitis is CECT

https://t.me/Latestpgnotes

PrepL

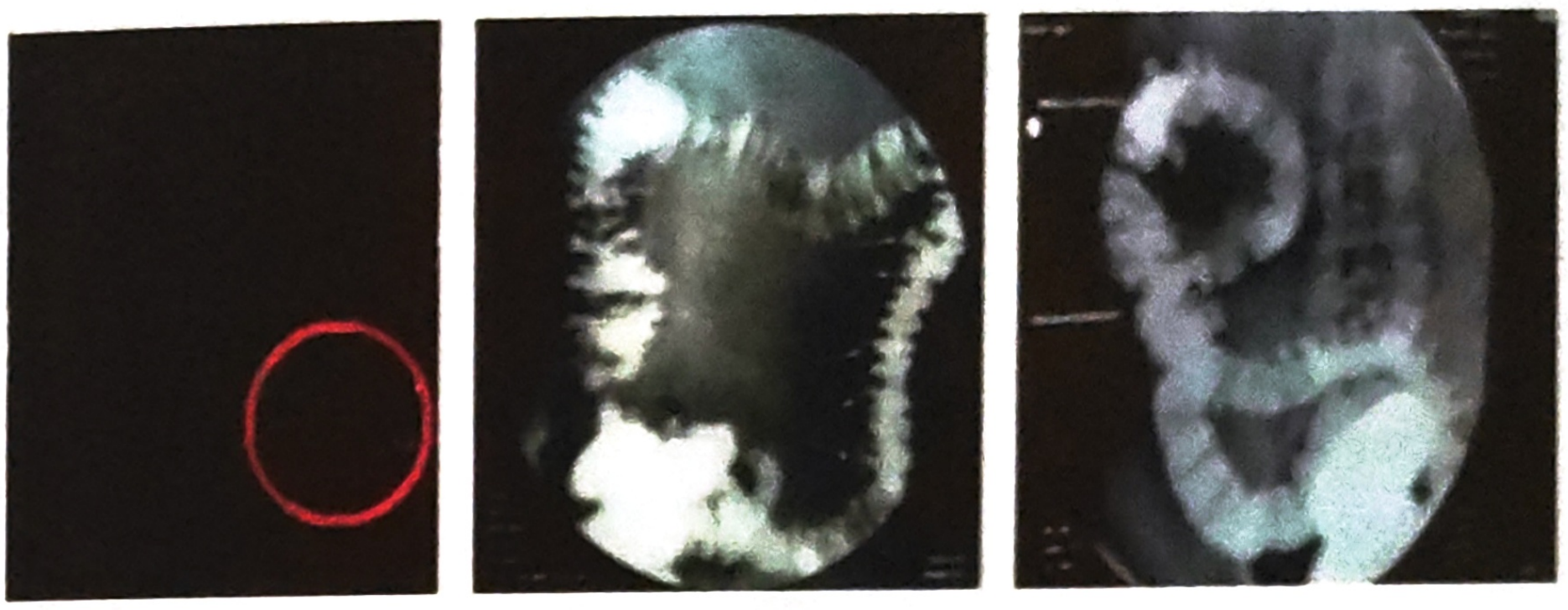

NOTE:

→ Pseudo sacculation in Crohn's disease & Meckel's diverticulum occurs in anti-mesenteric side

→ Barium is C/I in suspected bowel perforation - causes peritonitis

Colon Cancer

00:33:45

Apple core lesion

Sigmoid volvulus

- In X-ray coffee → bean sign
- In barium enema → Bird beak / bird of prey sign
- No Haustrations

(X-ray) coffee bean sign

https://t.me/neetpgnotes

PrepLadder

Bird beak / bird of prey sign

Cecal volvulus

- In X-ray coffee bean sign
- Haustrations can be seen

X-ray → coffee bean sign

Gastric volvulus

- In X-ray → coffee bean sign (located in epigastric area)

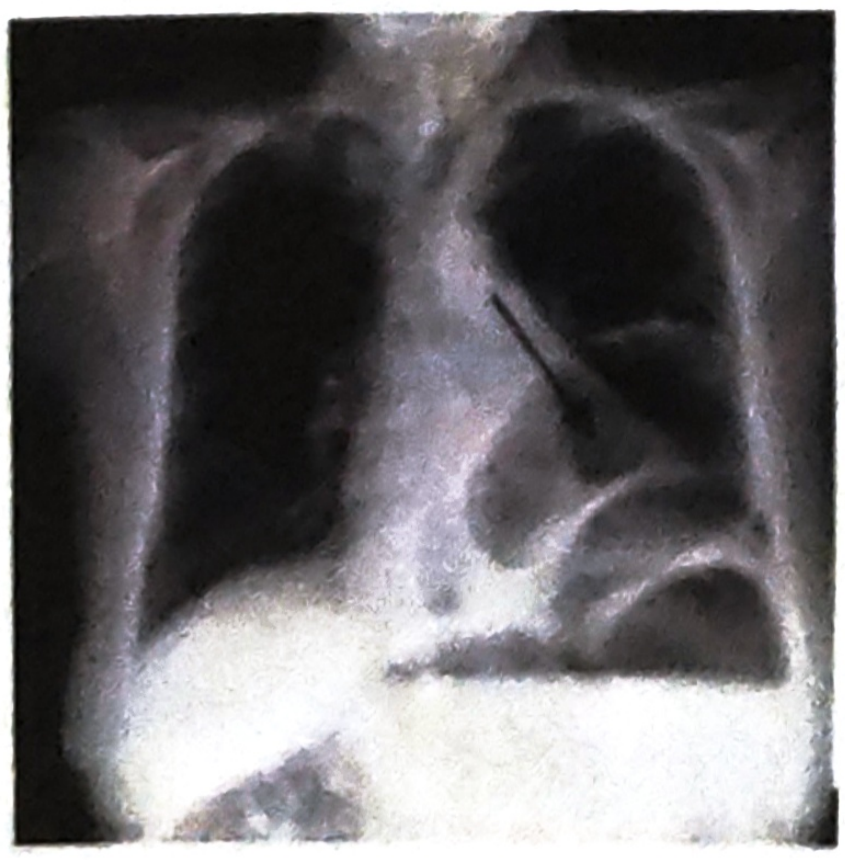

X-ray → coffee bean sign

https://t.me/Latestneetpgnotes

Midgut volvulus 00:38:00

- Corkscrew appearance of small intestinal loops (all small intestine loops are present on right side)
- On barium study - Corkscrew sign
- On USG or CT-shows whirlpool sign

Clinical	Ass. Congenital defects	Management
• Bilious vomiting (rarely non - bilious) • Hemodynamic instability • Abdominal distention	• Congenital diaphragmatic Hernia • Congenital heart disease • Omphalocele	• Surgical (LADD Procedure)

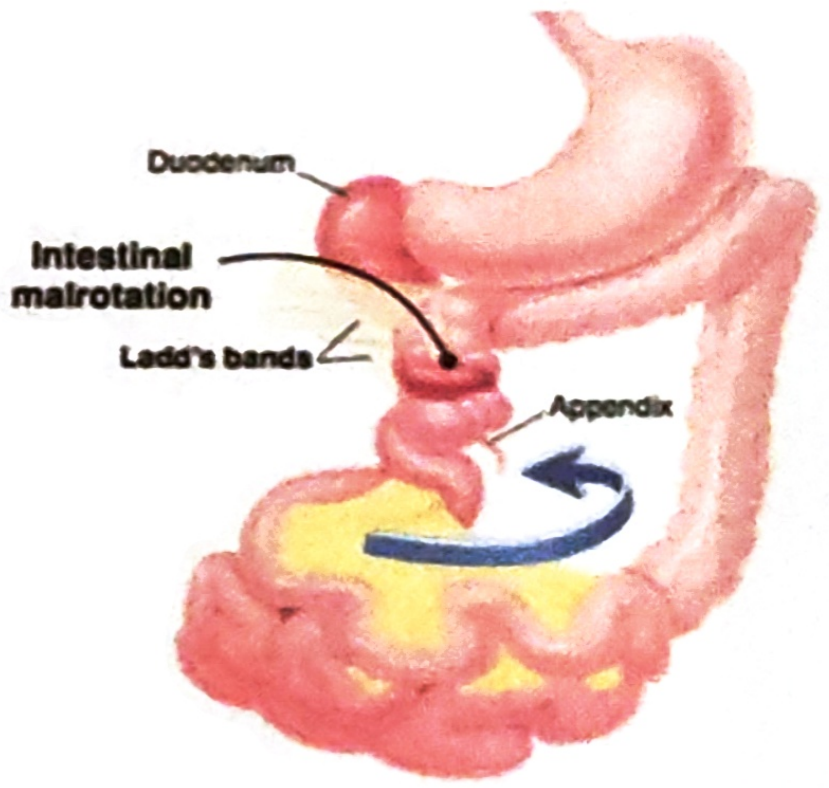

Intestinal malrotation with midgut volvulus

Corkscrew sign



Whirlpool sign on USG

Whirlpool sign on CT

t.me/neetpgnotes

PrepLadder

Sessile colonic polyp

→ Bowler hat sign - Cup shaped filling defect seen in air contrast barium enema that represents polyp if it points toward lumen

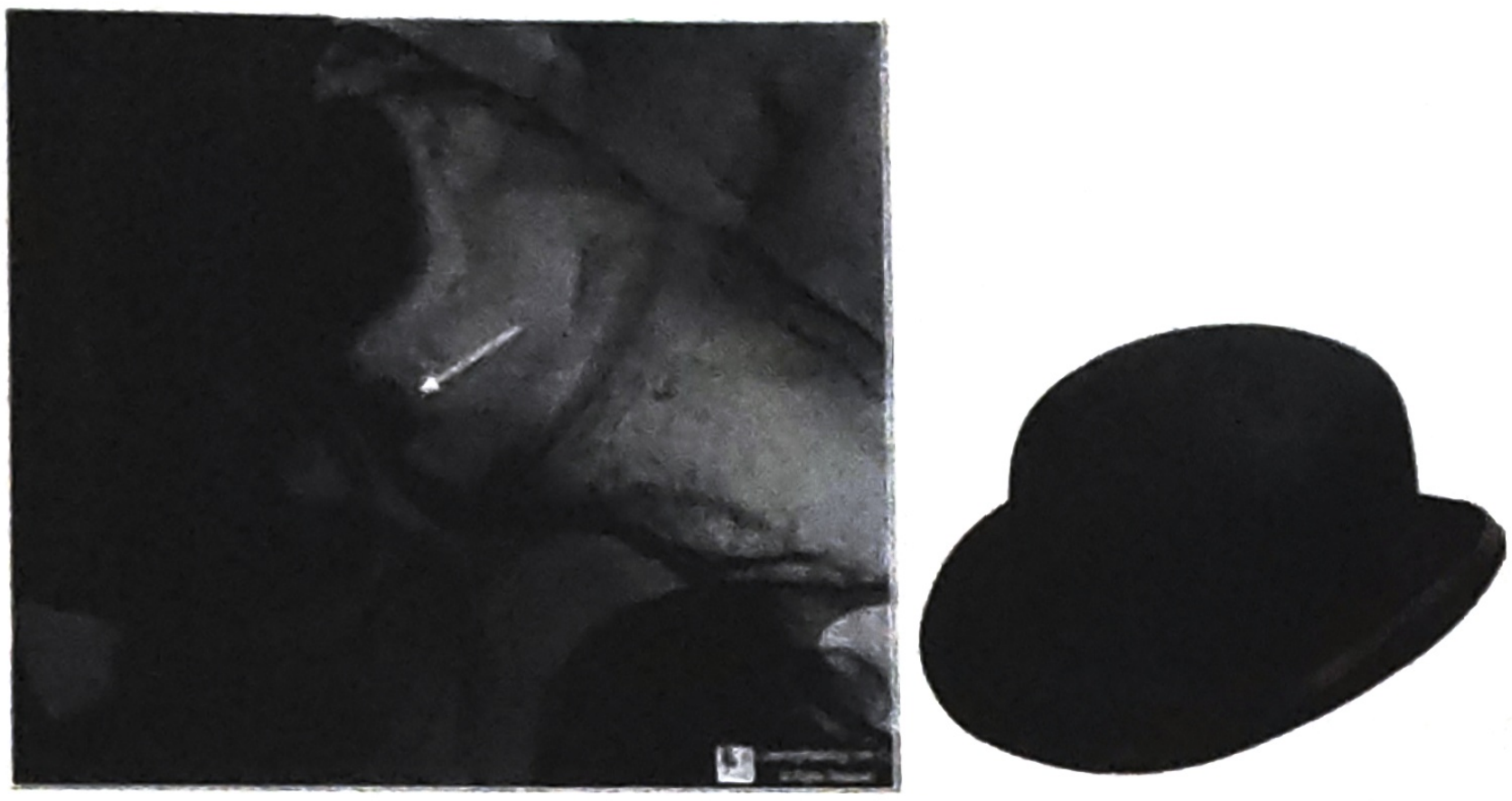

Bowler hat sign

Pedunculated polyp

→ Mexican hat sign - has an inner ring and outer ring.

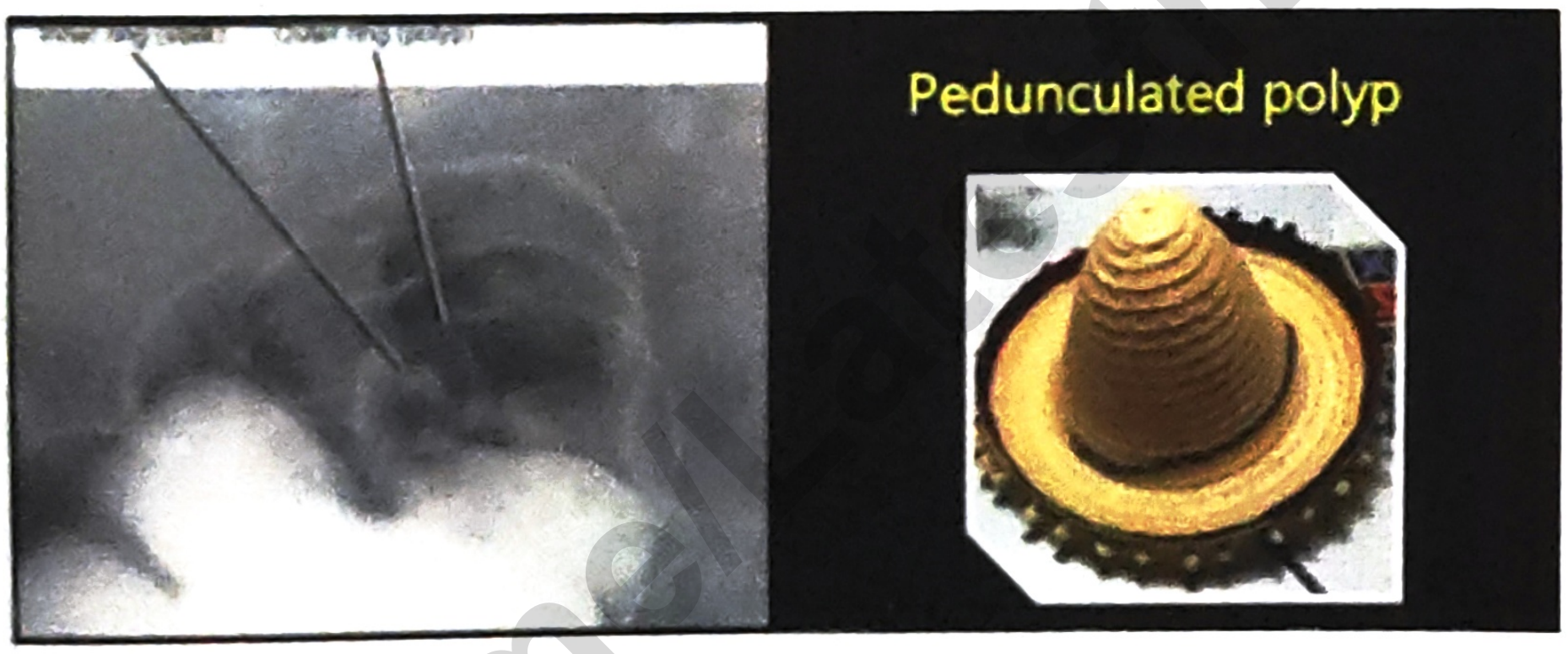

Mexican hat sign

Hirschsprung disease

00:42:50

→ Failure of migration of ganglions to distal part of colon

→ AKA colonic aganglionosis

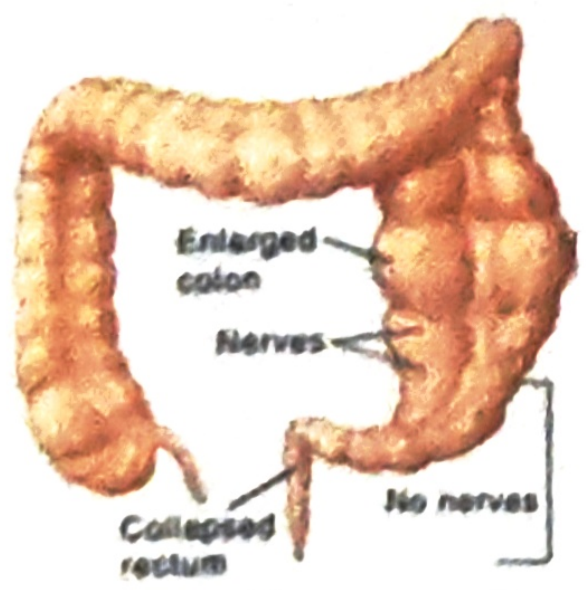

(Blue arrow) Distended part is normal
(Orange arrow) Constricted part is abnormal

https://t.me/neetpgnotes

Small bowel Vs large bowel obstruction

00:44:40

SBO	LBO
→ Dilated central bowel loop	→ Dilated peripheral bowel loop
→ Diameter of distension - 35 cms 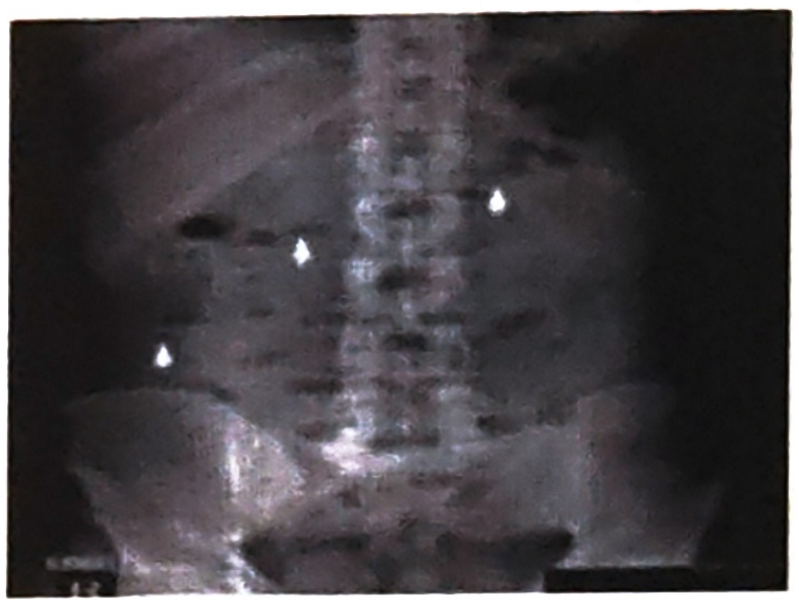	→ Diameter of distension > 5 cms 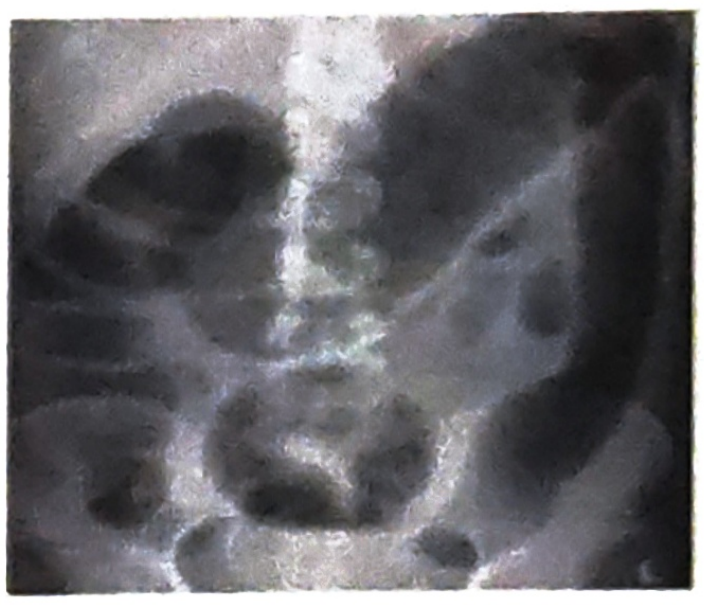
• Has step ladder pattern • Has string of beads sign • In Jejunal obstruction – valvulae Conniventes plica circularis	• Solid feces sign • Haustral folds

SUMMARY

Radiological Features	Diseases
→ Bird's beak appearance	• Oesophageal achalasia
→ Cork screw appearance	• Diffuse oesophageal spasm
→ Seagull/ Mercedes Benz/ Crow feet sign	• Radiolucent gall stone with gas
→ Medusa head colonies on CT	• Round worm
→ Pincer sign, claw sign, coiled spring appearance	• Intussusception
→ Whirl pool sign on USG	• Midgut volvulus
→ Coffee bean sign, bent tyre tube sign	• Sigmoid volvulus

https://t.me/Latestneetpgnotes

PrepLadder

→ Shark mouth appearance	• Ileocecal valve
→ Lead pipe appearance	• Ulcerative colitis
→ String of Kantor, bull's eye or target lesion	• Crohn's disease
→ Thumb printing sign	• Ischemic colitis
→ Saw tooth appearance	• Diverticula of colon (sigmoid)
→ Apple core lesion, napkin's sign	• Ca - colon
→ Claw appearance	• Intussusception

https://t.me/Latestneetpgnotes

PrepL

For more free ebooks and notes, visit

https://t.me/Latestneetpgnotes

Or click this page to join

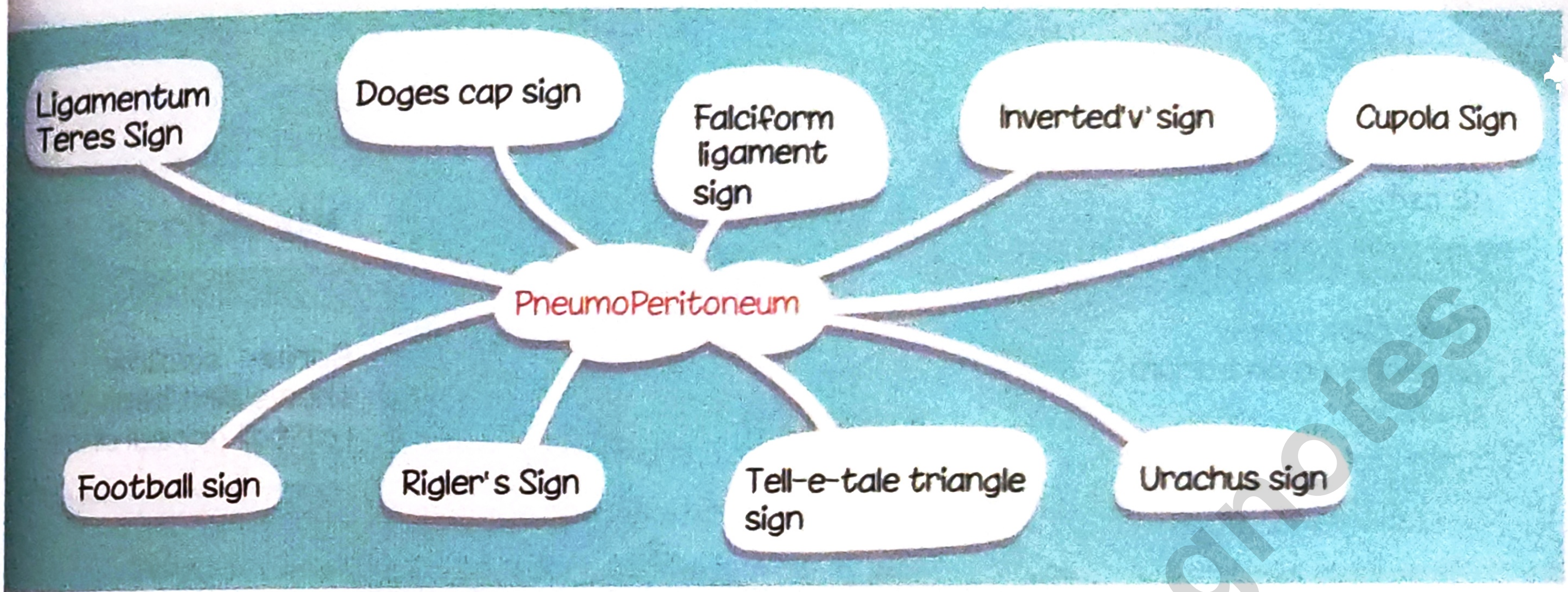

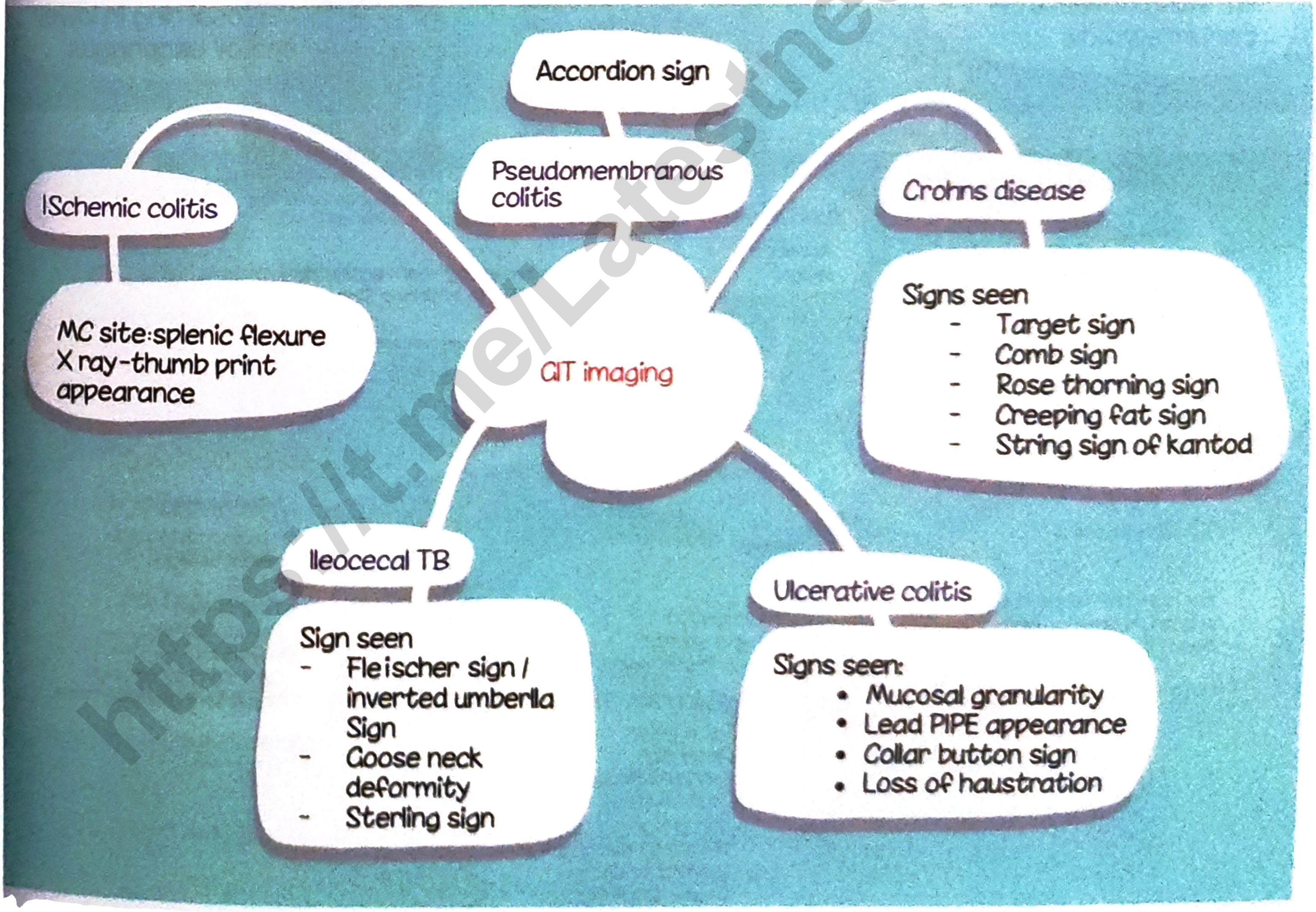

https://t.me/Latestneetpgnotes

GIT (Esophagus)

- **Diffuse esophageal spasm**
  - Gives cork screw appearence on barium swallow
- **Esophageal varices**
  - Gives serpentine / worm like filling defects on barium swallow
- **Achlasia cardia**
  - Barium swallow shows bird beak o rat tail appearanc
- **Schatzkis Ring**
  - Mucosal ring in low end of esophagus

GIT imaging

- **Diverticulosis**
  - IOC-Barium enema
  - "Saw tooth appearance"
- **Colon cancer**
  - Apple core lesion
- **Mid gut volvulus**
  - On barium study -cork screw sign
  - On USG or CT- Whirloop Sign
- **Sigmoid volvulus**
  - In X ray - coffee bean sign
  - In brarium enema - Bird beak / bird of Prey sign
- **Congenital hypertrophic pyloric stenosis**
  - In USG
    - Target sign
    - Cervix sign
    - Antral nipple sign
  - On barium study
    - String Sign
    - Diamond / twinning sign
    - Mushroom sign
    - Double track sign
- **Intussusception**
  - On plain radiograph - meniscus sign
  - On USG
    - Target sign
    - Pseudo kidney
  - On Barium
    - Claw sign / pincer sign
    - Coiled spring appearan

https://t.me/Latestneetpgnotes

Chapter 20

NEURORADIOLOGY PART -1

Normal sites of calcification in brain

00:00:25

- → Pineal gland (present posterior to third ventricle)
- → Choroid plexus (Present in occipital horns of lateral ventricle)
- → Folds of dura (like falx cerebri, tentorium cerebelli)
- → Lens

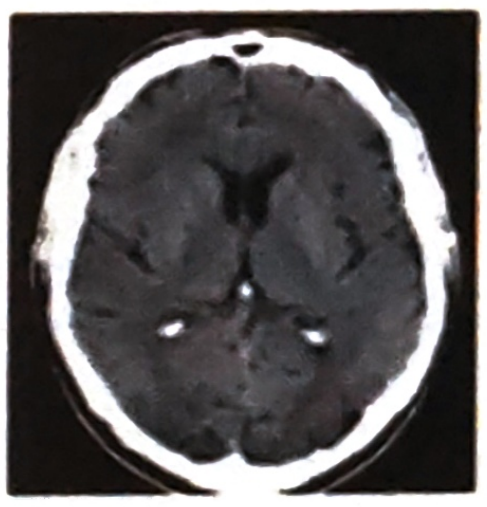

Choroid Plexus and Pineal Gland Calcifications

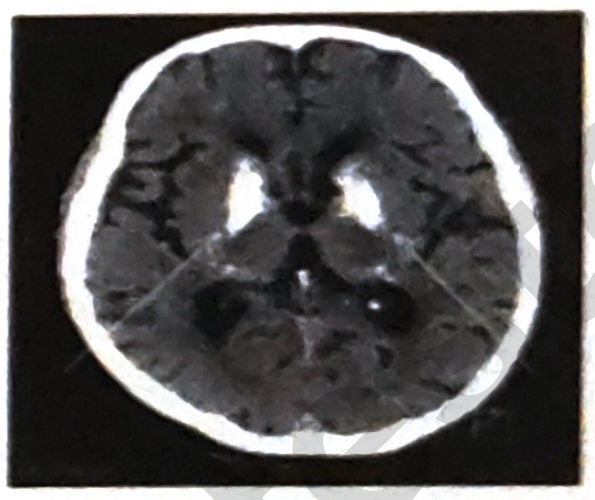

FAHR's Disease

Basal ganglia calcification

- → Hypoparathyroidism
- → Pseudohypoparathyroidism
- → Hypoxia
- → Hypothyroidism
- → Hyperparathyroidism
- → CO poisoning
- → Lead poisoning
- → TORCH infection
- → FAHR disease (B/L symmetrical basal ganglia calcification)

Note:

- → Basal ganglia calcifications are NOT seen in Wilson disease.
- → Periventricular calcification is classic feature of CMV
- → Subependymal calcification - tuberous sclerosis

https://t.me/Latestneetpgnotes

PrepLadder

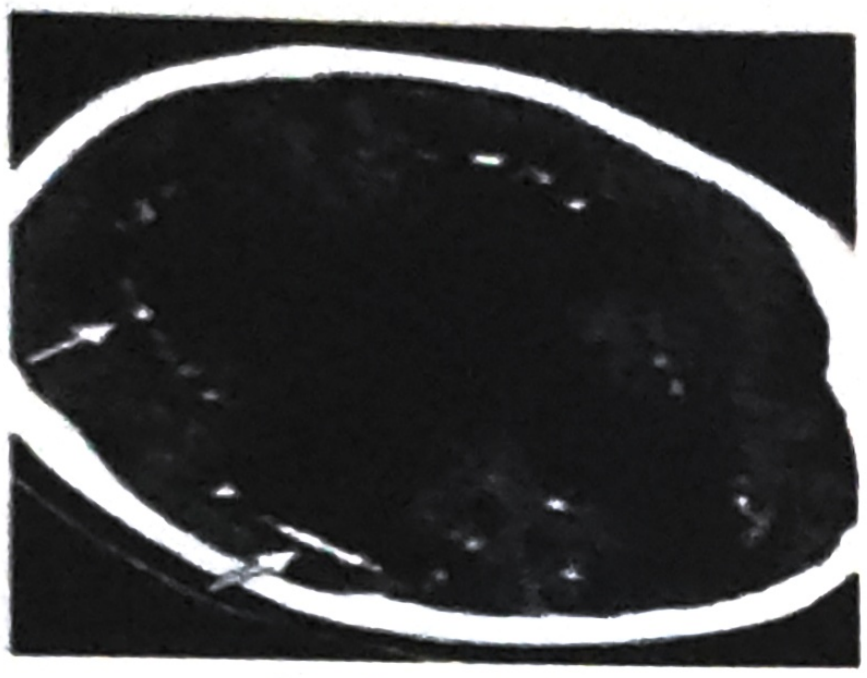

Periventricular calcification - CMV

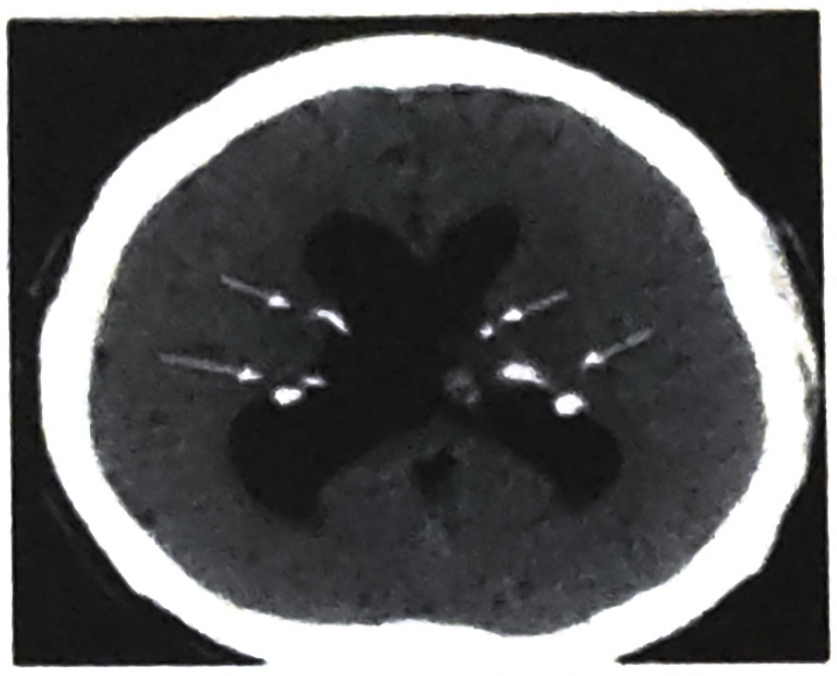

Subependymal calcification - Tuberous sclerosis

Superior sagittal sinus thrombosis 00:05:20

→ Empty delta sign

- Hypodensity within the hyperdense posterior falx
- Feature of superior sagittal sinus thrombosis seen on CECT

NCCT - Delta Sign



CECT - Empty Delta Sign

Swirl sign 00:12:26

→ Hypodensity within the hyperdense epidural hematoma

→ Indicates active extravasation (bleeding) of unclotted blood.

EDH-swirl sign

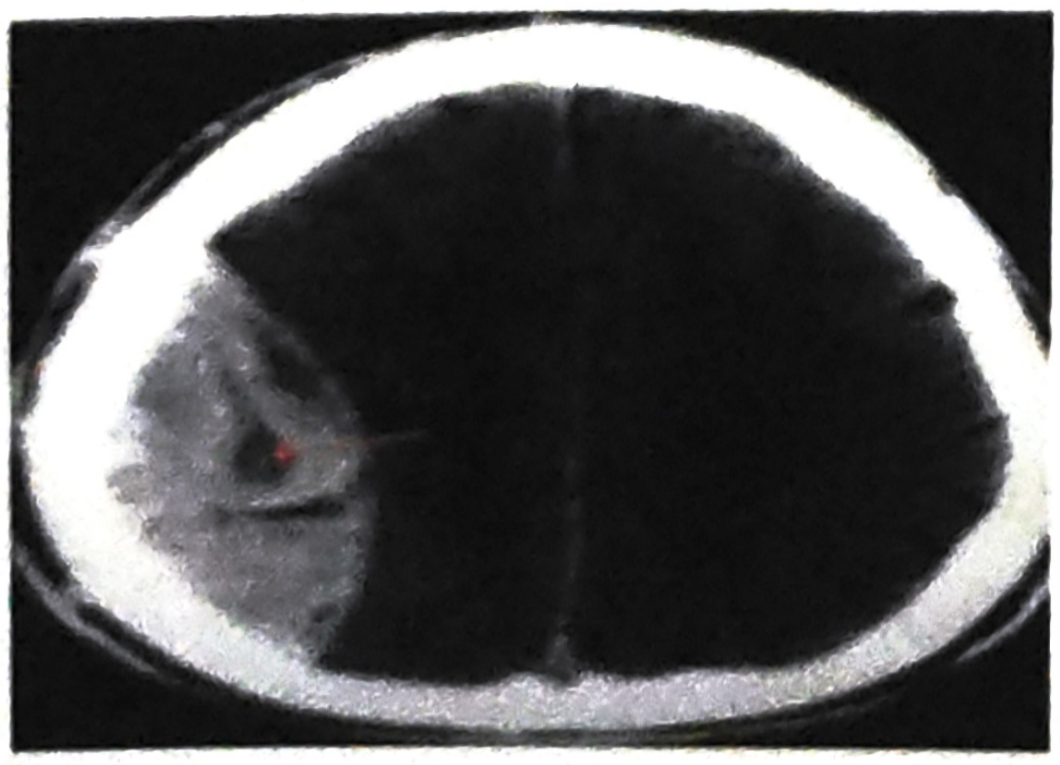

https://t.me/Latestpgnotes

PrepL

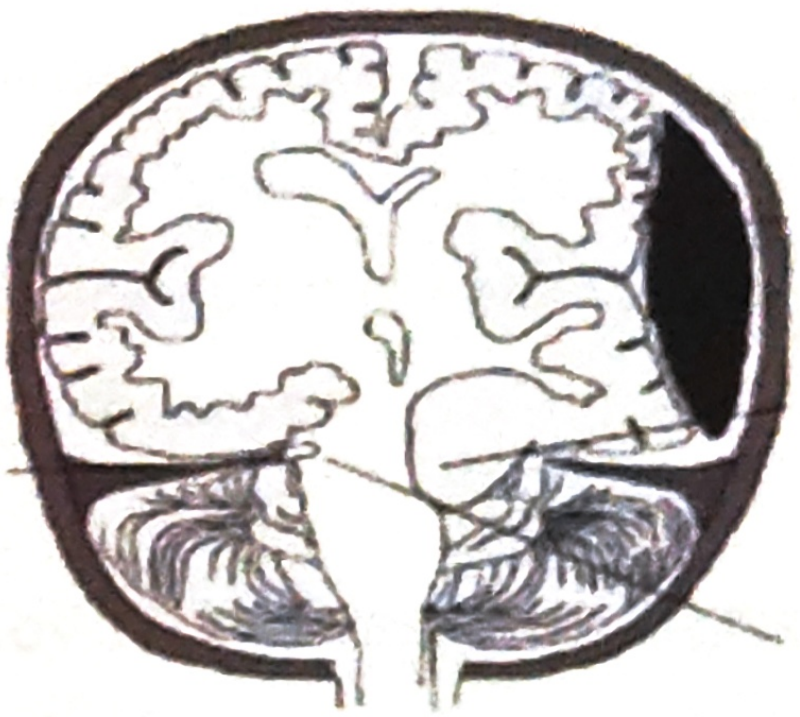

Kernohan Notch Phenomenon

↓

False Localizing sign

→ Head Trauma / Mass / EDH → uncal herniation

↓

Compresses midbrain (crus cerebri on contralateral side gets compressed under tentorium Cerebelli)

↓

Known as kernohan Notch

↓

Paralysis occurs ipsilateral to the side of lesion

EDH (Epidural hematoma)

- → AKA Extradural hematoma
- → Biconvex / lentiform / lemon shaped appearance seen
- → Limited by suture lines so does not cross sutures
- → Due to rupture of middle meningeal artery
- → Happens due to fracture of Pterion (H shaped suture)
- → Causes midbrain hemorrhages or Duret hemorrhages
- → Causes uncal herniation
- → Causes third nerve palsy
- → Has lucid interval

https://t.me/Latestneetpgnotes

PrepLadder

SDH (Subdural hematoma) 00:16:55

→ Concavo-convex or Crescentic or banana shaped

→ Crosses suture lines

→ Happens due to rupture of Bridging veins

→ Seen with

- Chronic old trauma
- Cortical atrophy
- Alzheimer's disease
- Punch drunk syndrome (Professional boxer)
- Battered baby syndrome (BBS also has metaphyseal corner fracture)

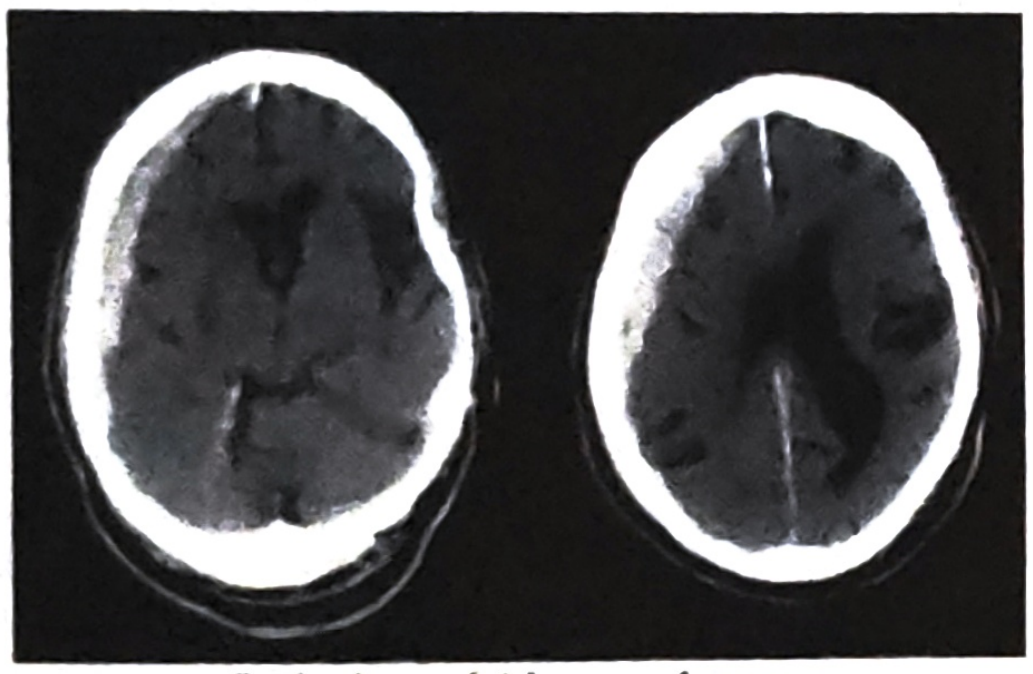

Subdural Hematoma

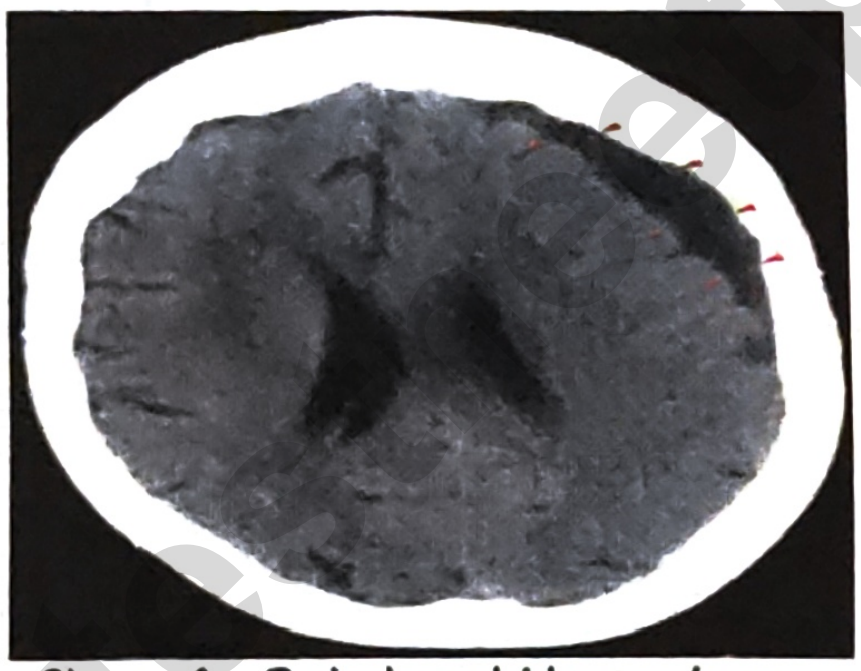

Chronic Subdural Hematoma

SAH (Subarachnoid hemorrhage) 00:20:00

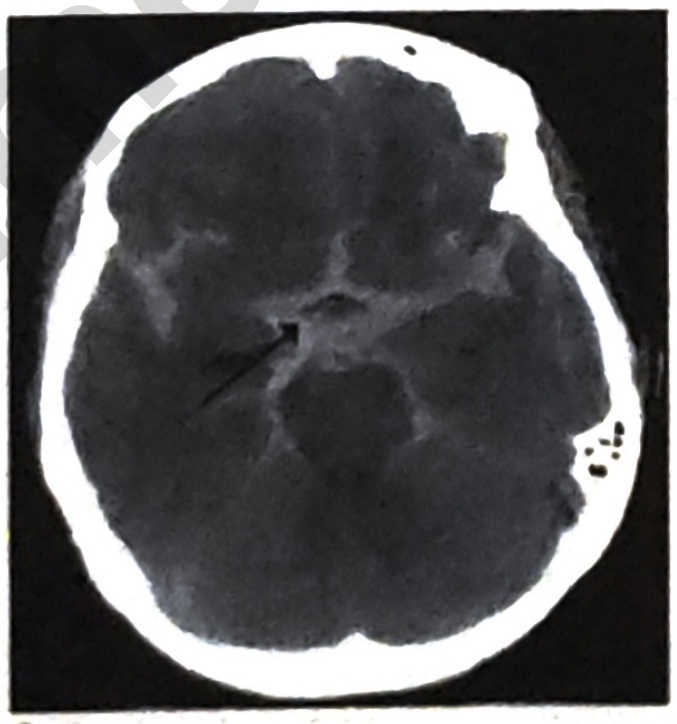

Subarachnoid hemorrhage

→ Shows Hyperdensity in:

- sulcal spaces
- sylvian fissures
- basal cisterns
- anterior interhemispheric fissure

https://t.me/Latestpgnotes

→ IOC for acute SAH (<48 hrs) – NCCT

→ IOC for chronic SAH (>48 hrs)–MRI

→ Most common cause of SAH – Trauma

→ Most common cause of spontaneous SAH

- Rupture of Berry aneurysm

→ IOC to know cause of SAH – 4 vessel angiography

1) One Vertebral arteries

2) Two Internal Carotid arteries

→ In case of acute settings, to know site of aneurysm

- CT Angiography

→ In chronic setting / stable patient to know site of aneurysm – MR Angiography

→ Gold standard for the imaging of intracranial aneurysms and vascular malformations – Digital subtraction catheter angiography (DSA)

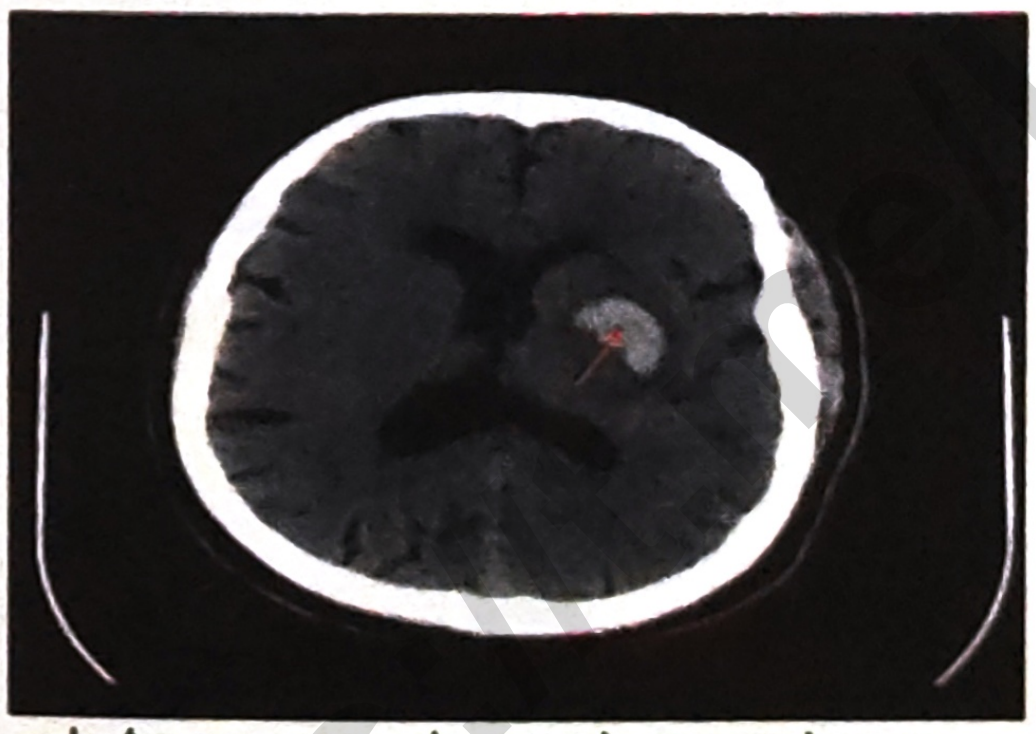

Intra parenchyma hemorrhage

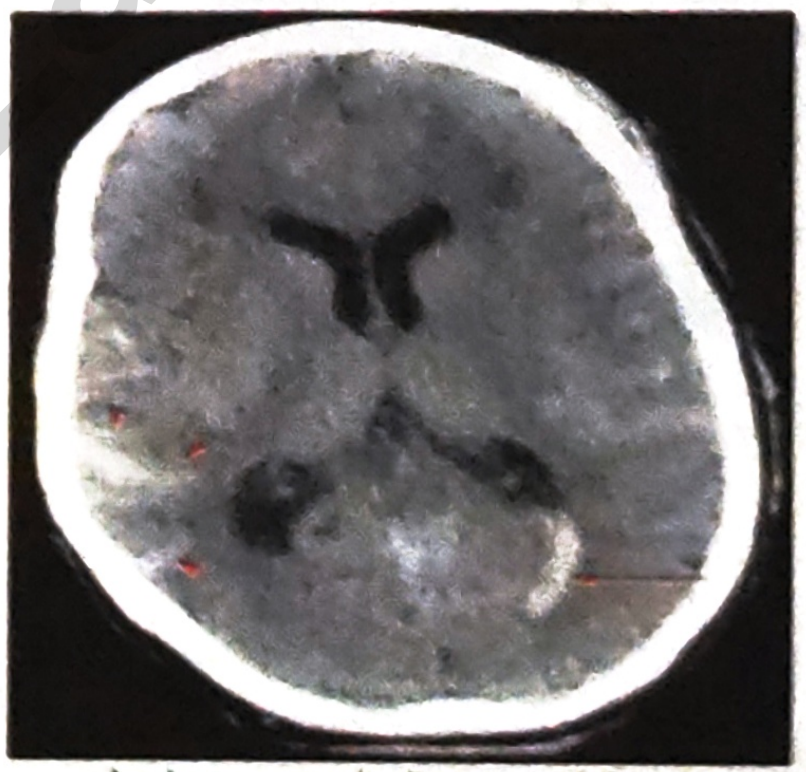

Intraventricular bleed – Occipital horn of lateral ventricle

Note:

→ Intraventricular bleed - occipital horn of lateral ventricle

→ Intraparenchymal bleed - Left putamen

→ Most common site of hypertensive bleed – Putamen

https://t.me/Latestneetpgnotes

PrepLadder

Young patient with RTA, unconscious (poor GCS)

↓

NCCT – normal / petechial hemorrhages

↓

Suspect diffuse axonal injury

↓

IOC – MRI (hyperintensities in white matter of brain can be viewed)

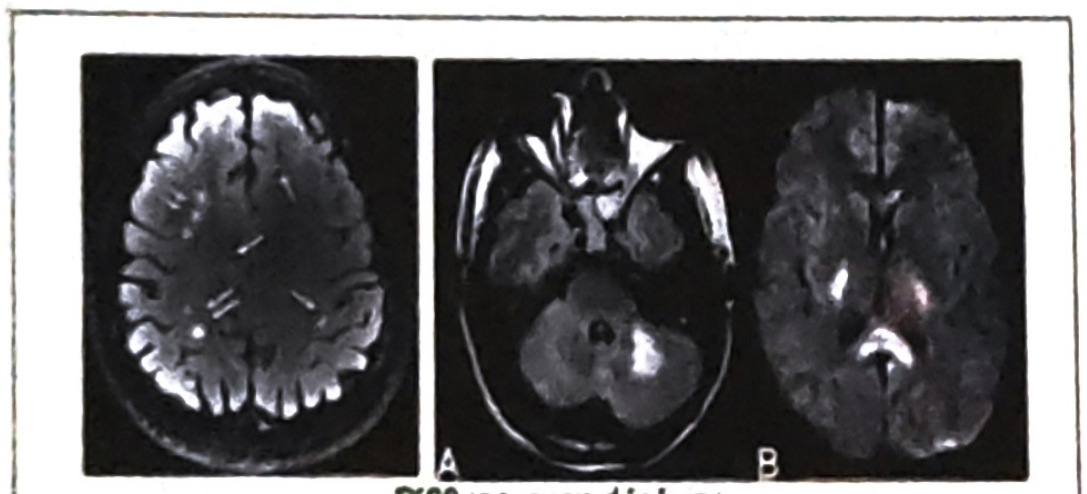

Diffuse axonal injury

→ To evaluate petechial hemorrhages, sequence of MRI preferred

- Susceptibility weighted imaging (SWI)/ Gradient Echo imaging

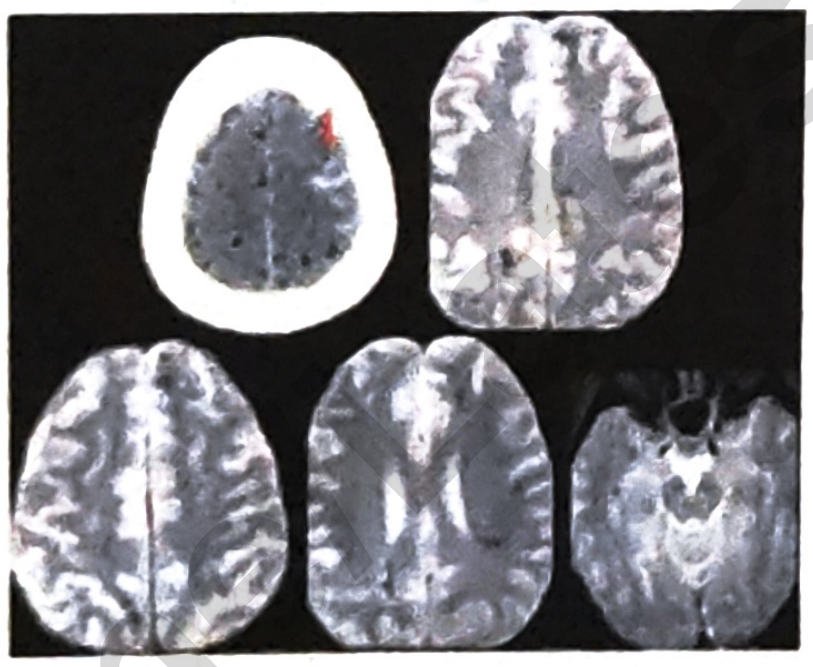

Susceptibility weighted imaging (SWI)

MOUNT FUJI sign

→ Feature of Tension pneumocephalus

→ IOC – CT scan

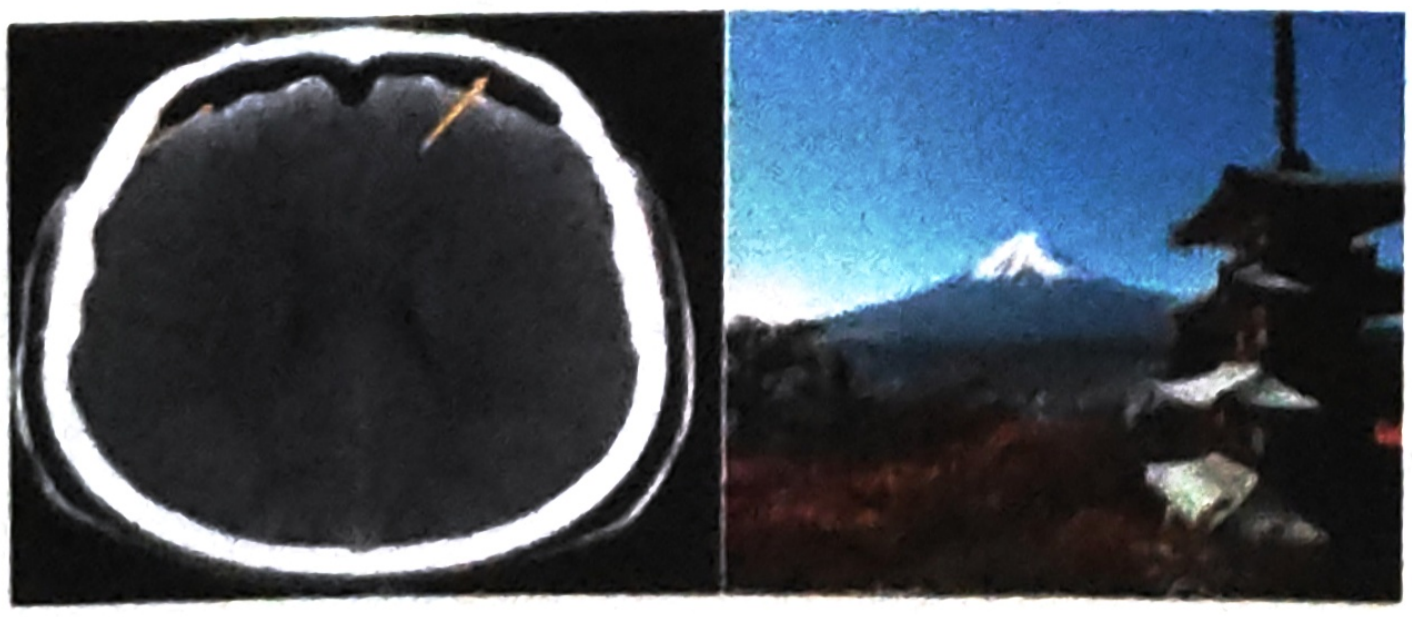

Mount Fuji sign

https://t.me/streetpgnotes

PrepLadder

SCIWORA (Spinal cord injuries without radiographic abnormalities)

- → Occurs exclusively in CHILDREN < 8 years with quadriplegia after accidental fall
- → Involves Upper cervical spinal cord
- → IOC – MRI (to look for injury at the upper cervical spinal cord)

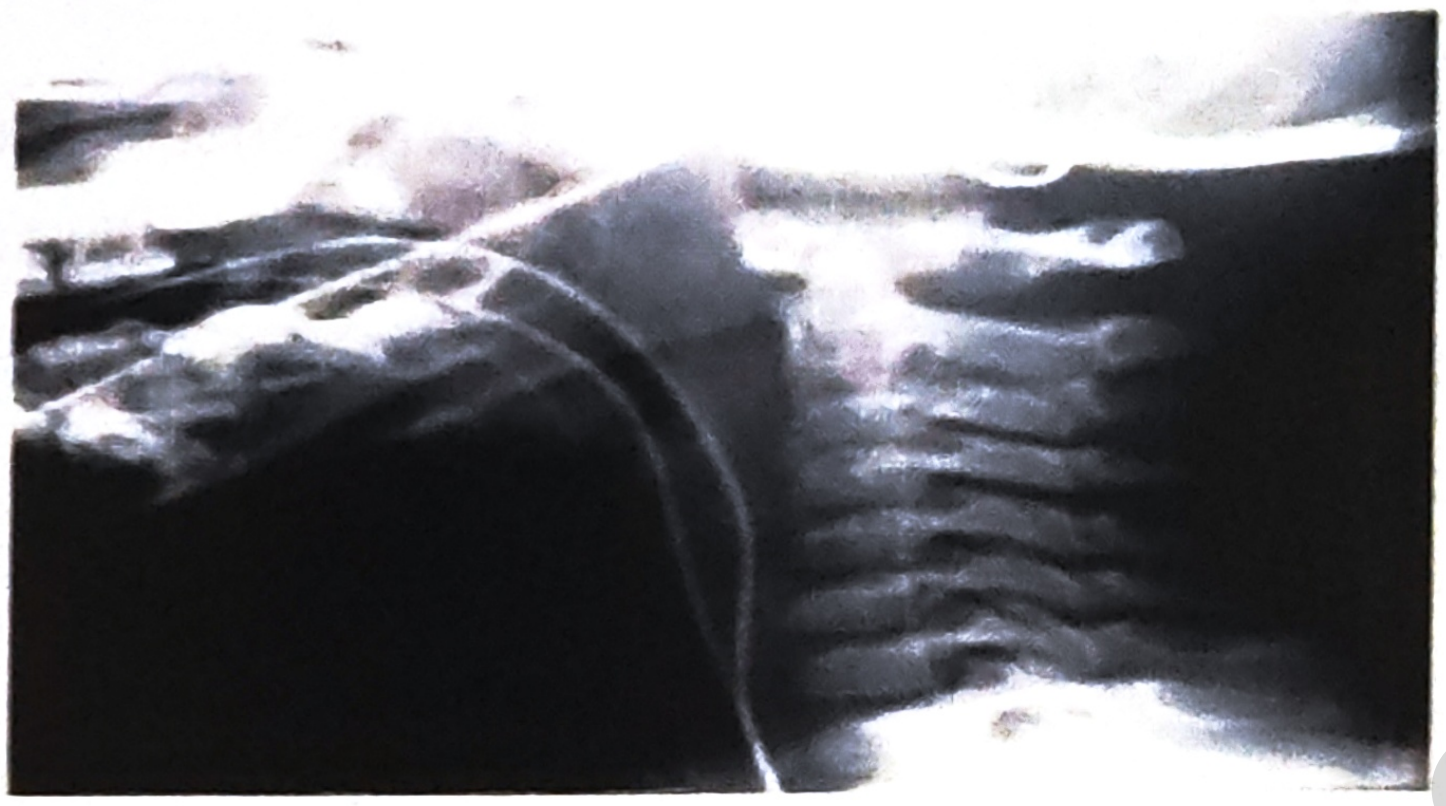

SCIWORA

Arterial supply of brain

- → Medial and superior surface of brain
  - Anterior cerebral artery
- → Superolateral surface of the brain - Middle cerebral artery
- → Occipital lobe and inferior part of temporal lobe
  - Posterior cerebral artery.

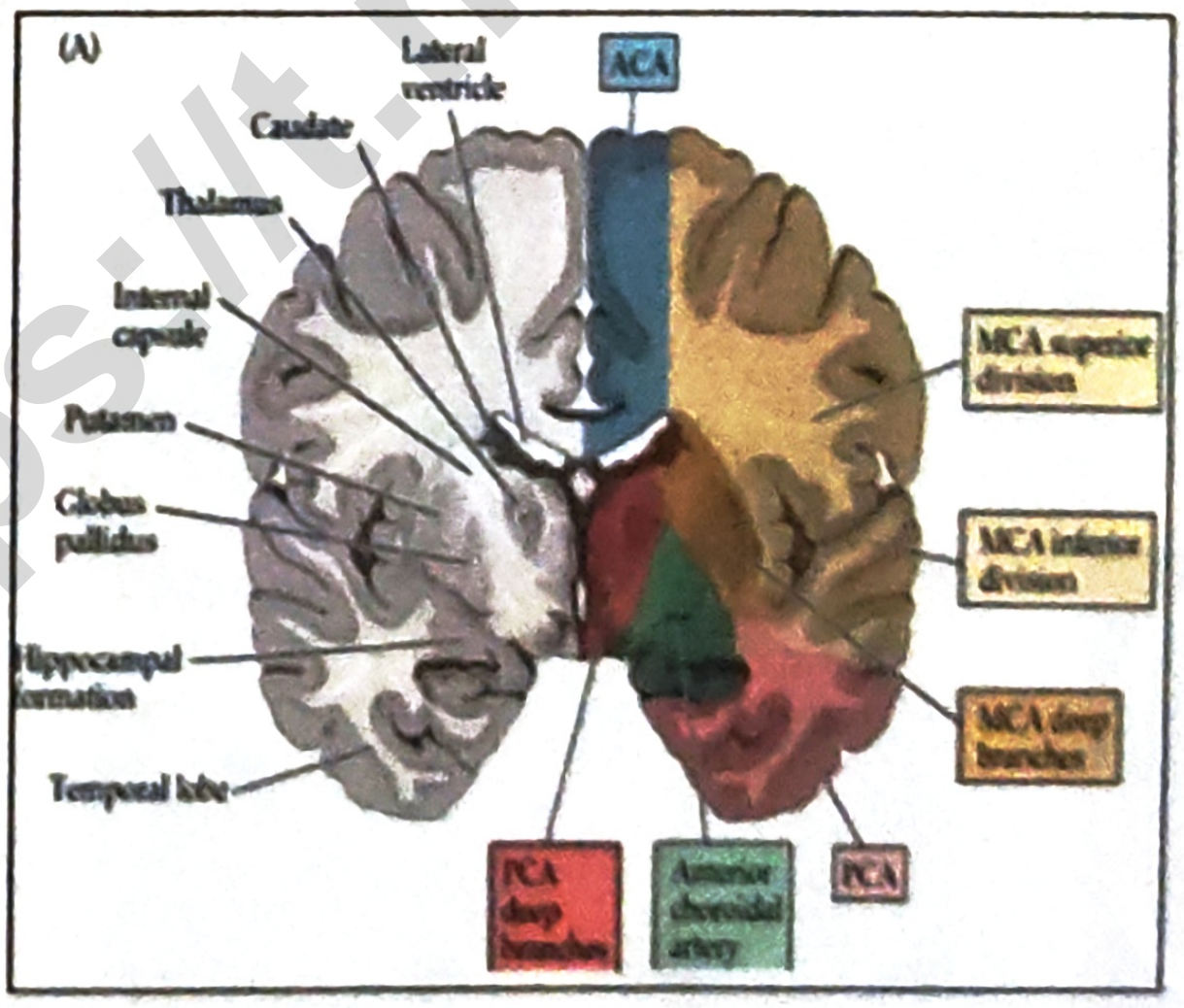

Arterial supply of brain

https://t.me/Latestneetpgnotes

PrepLadder

HOMUNCULUS

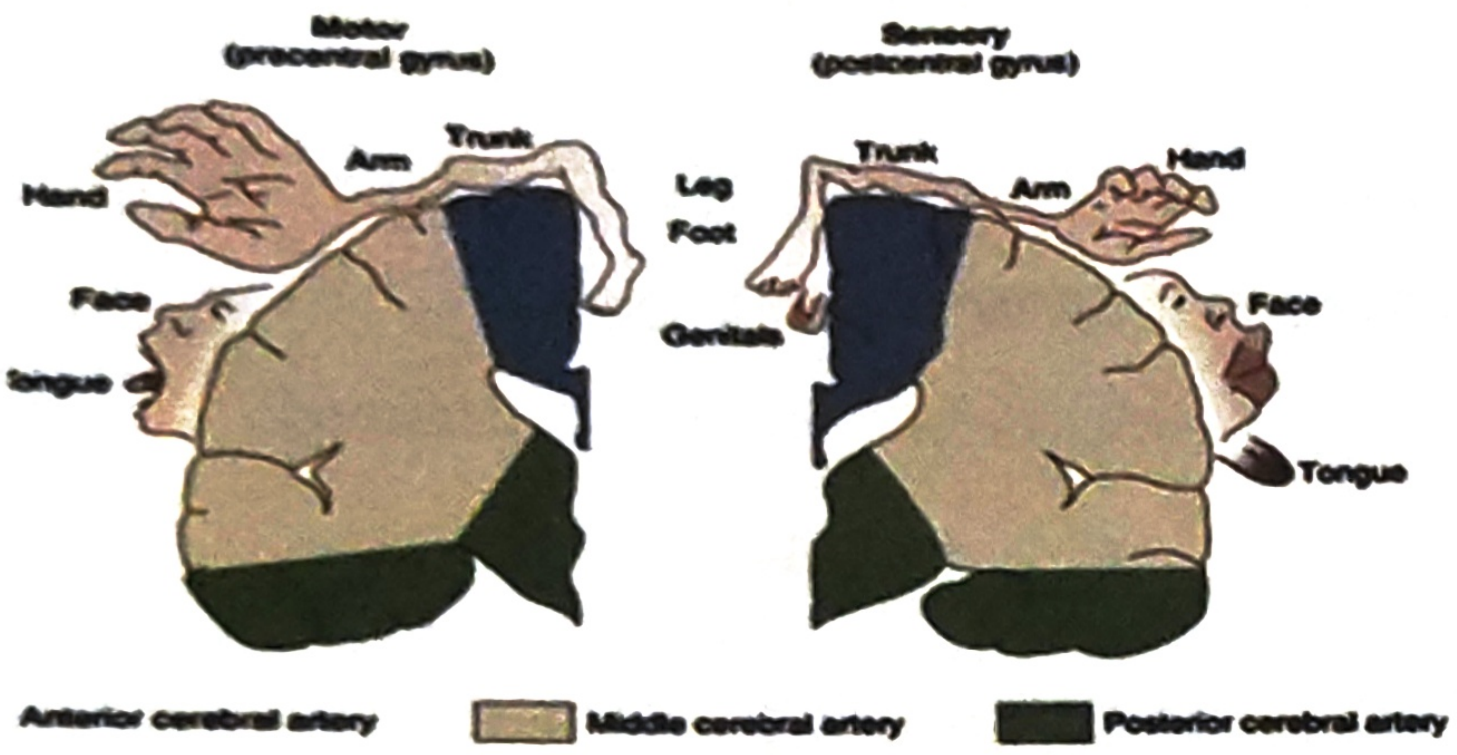

→ For anterior cerebral artery infarction – Paraplegia

→ Middle cerebral artery infarction – Hemiplegia

→ Posterior cerebral artery infarction – Visual symptom

00:35:56

Stroke
↓
NCCT - Initial Investigation
↓
Hyperdense → Hemorrhagic stroke
Hypodense/ Normal → Ischemic stroke

→ IOC for acute infarct / Ischemic stroke → Diffusion weighted MRI (CT scan can be normal in acute infarcts)

→ IOC for stroke – Non contrast CT scan

Right ACA infarct

Right MCA infarct

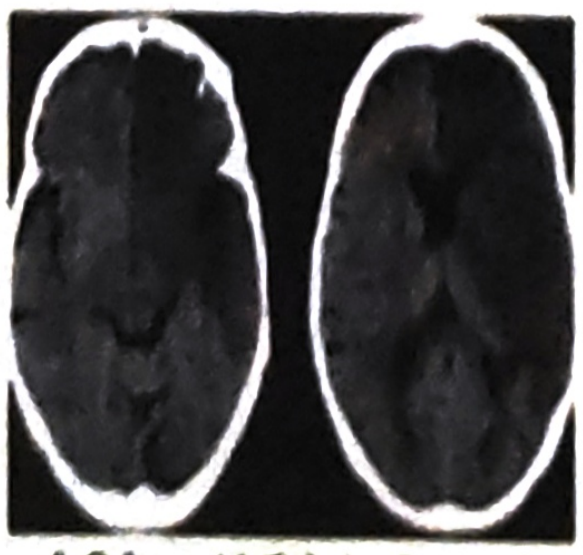
ACA + MCA Infarct

https://t.me/Latestneetpgnotes

Chapter 21

NEURORADIOLOGY PART -2

Acute infarct/Ischemic stroke 00:00:20

→ Light bulb appearance on DW – MRI brain is suggestive of Acute infarct/ischemic stroke

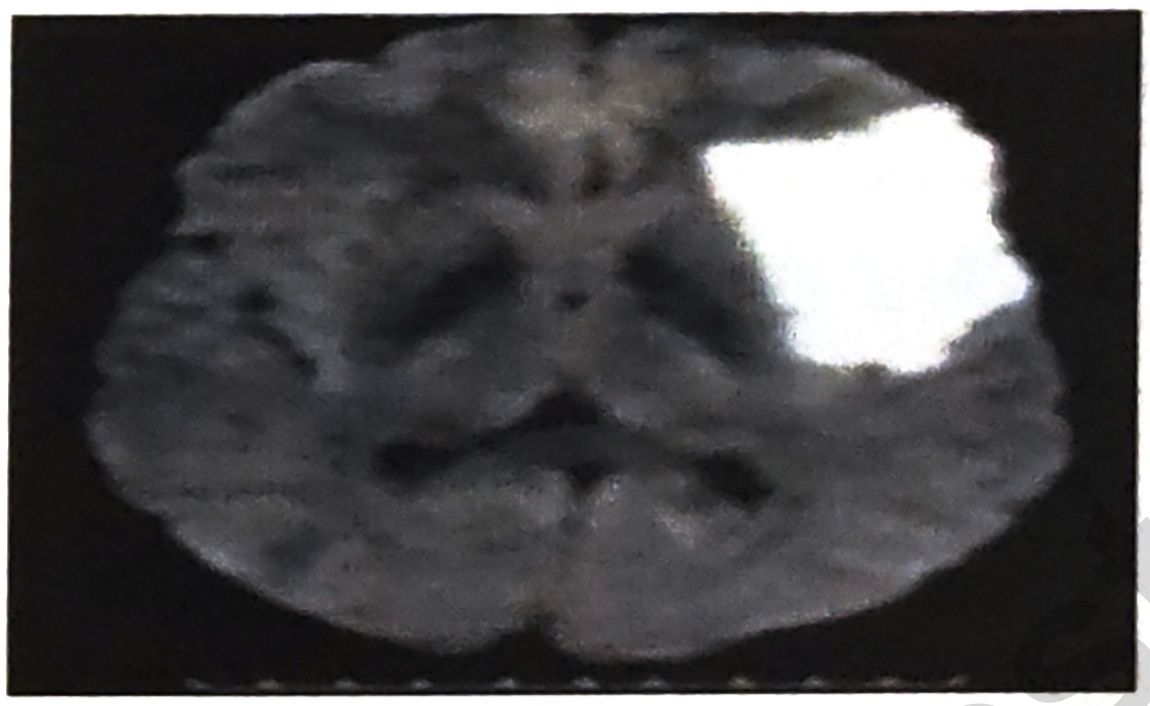

Light bulb appearance on DW

Signs of acute infract on NCCT scan

→ Hyperdense MCA sign

→ Sylvian dot sign

→ Obscuration of lentiform nucleus

→ Insular ribbon sign

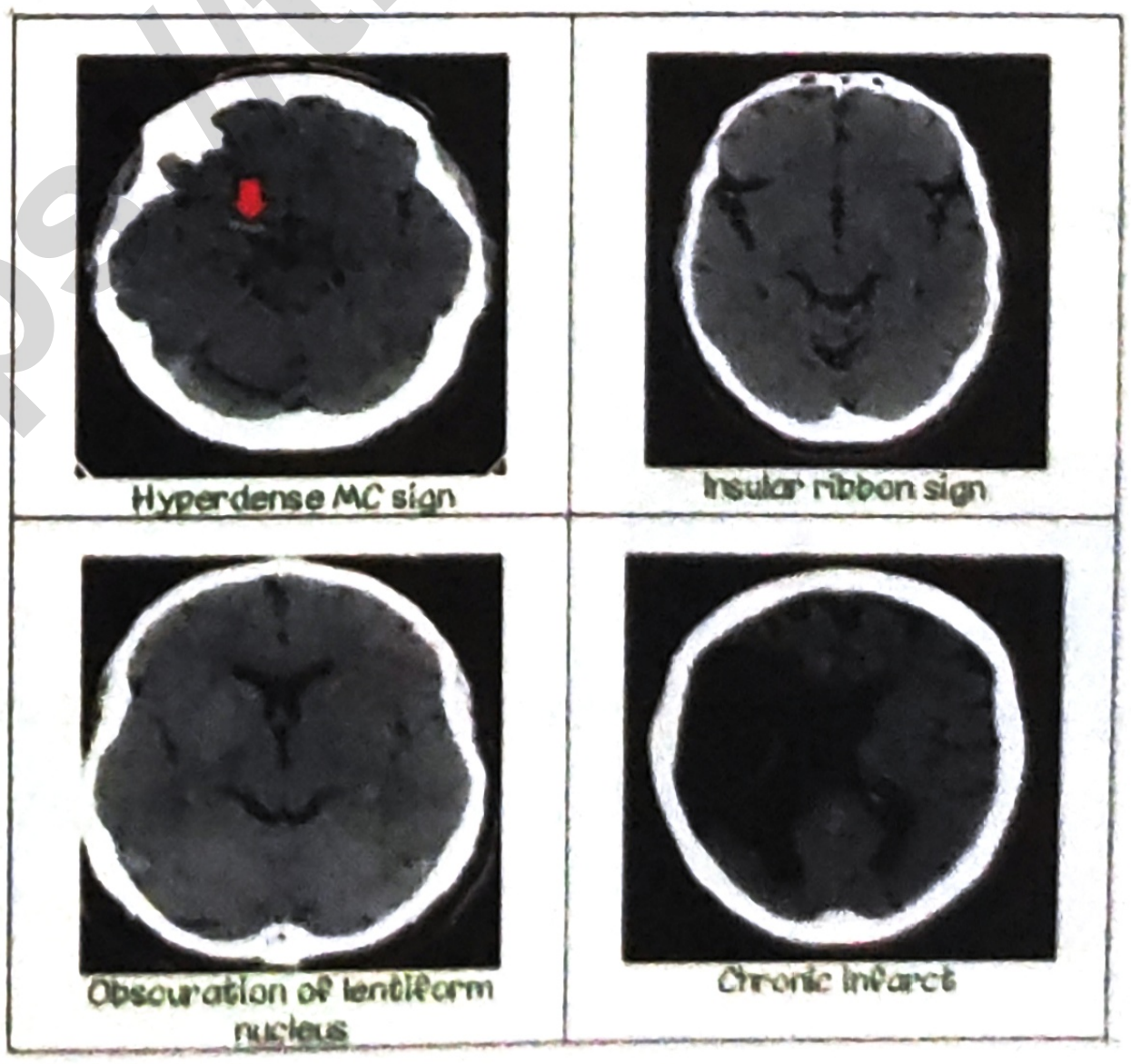

https://t.me/Latestneetpgnotes

PrepLadder

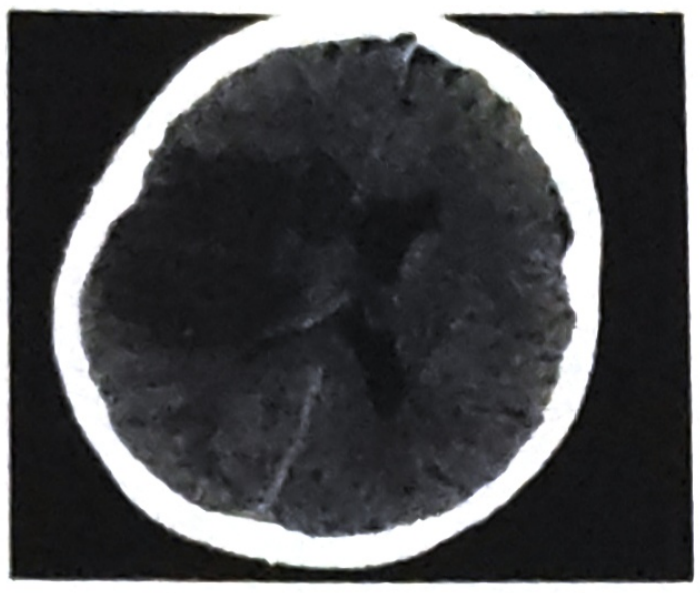

Acute infarct

Radiological findings of demyelinating disorders 00:09:06

Multiple sclerosis (Autoimmune)

→ Autoimmune destruction of myelin formed

→ Periventricular white matter hyperintensities perpendicular to ventricles – DAWSON Fingers

→ Involvement of Calloso-septal interface

→ Open ring / horseshoe enhancement is suggestive of demyelination.

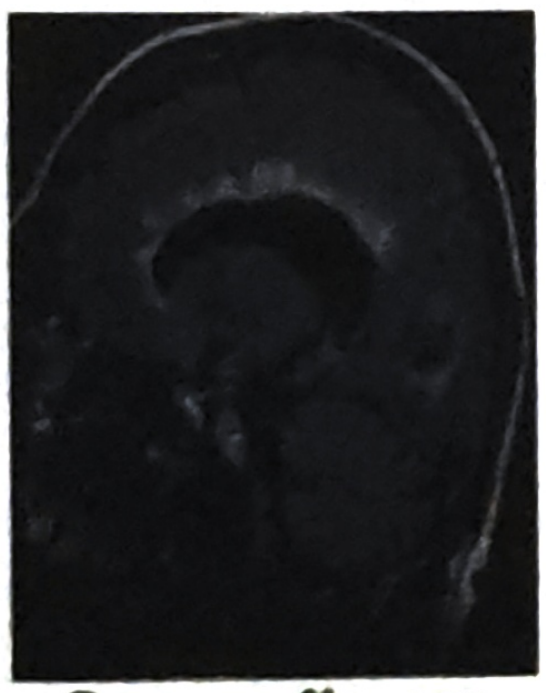

Dawson fingers

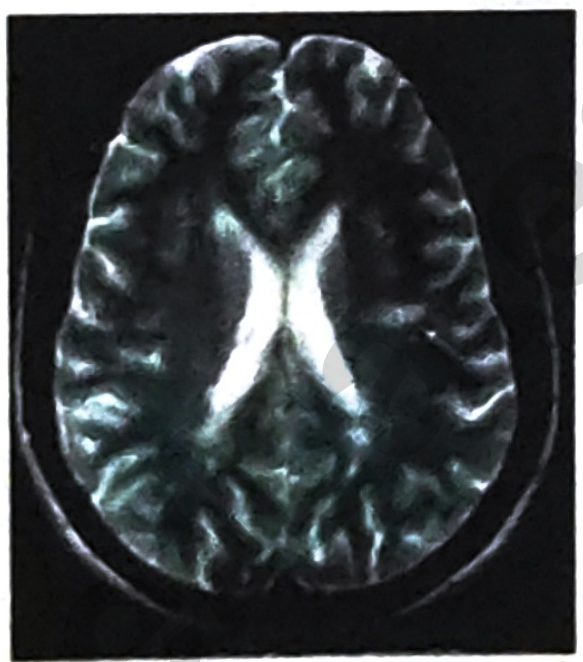

T2 weighted image of Dawson fingers

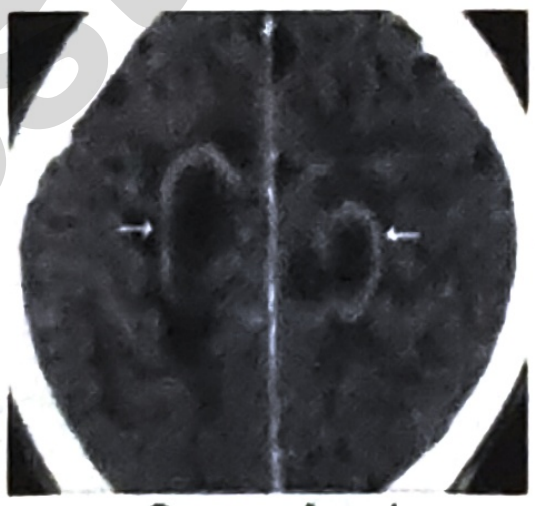

Open ring/ horseshoe enhancement

White matter leukodystrophy

→ Alexander disease

- White matter dystrophy of Bilateral frontal lobes
- Associated with Megalencephaly (Large skull)

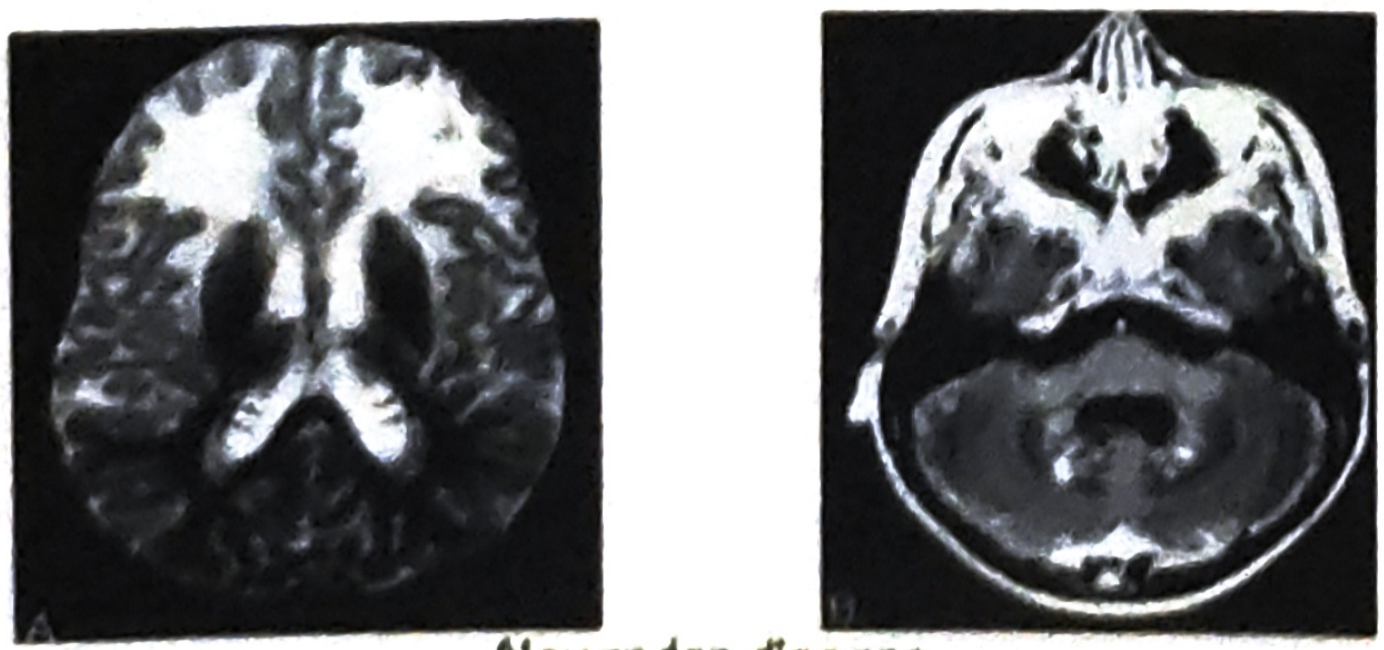

Alexander disease

https://t.me/neetpgnotes

→ Adrenoleukodystrophy

- White matter of Bilateral occipital lobes is involved.

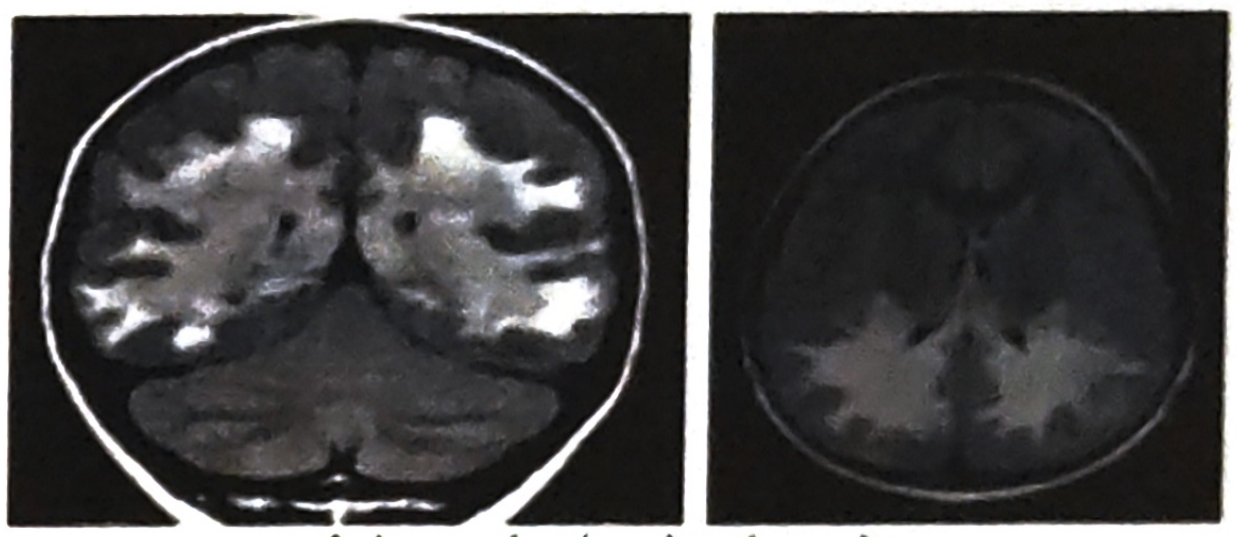

Adrenoleukodystrophy

→ Krabbes Disease / Globoid cell leukodystrophy

- Involvement of B/L thalami

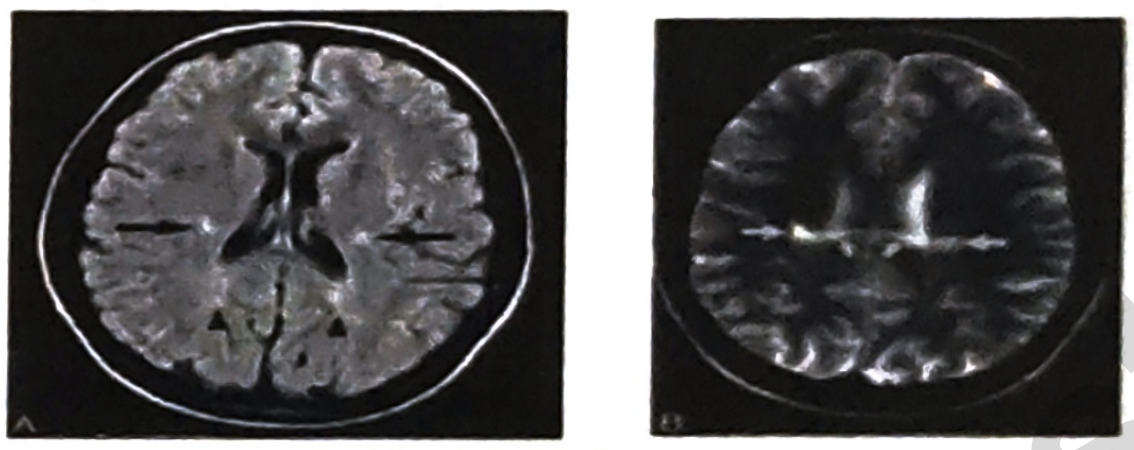

Krabbes Disease

→ Metachromatic Leukodystrophy

- Deficiency of Aryl sulfatase
- Deep white matter disease with sparing of subcortical 'U' fibers
- Lamellated / Tigroid / Leopard skin Appearance on MRI

→ CANAVANS disease

- Diffuse white matter involvement
- N – acetyl / aspartate peak / NAA peak on MR – spectroscopy @ 2 ppm
- Patient has Megalencephaly

https://t.me/Latestneetpgnotes

PrepLadder

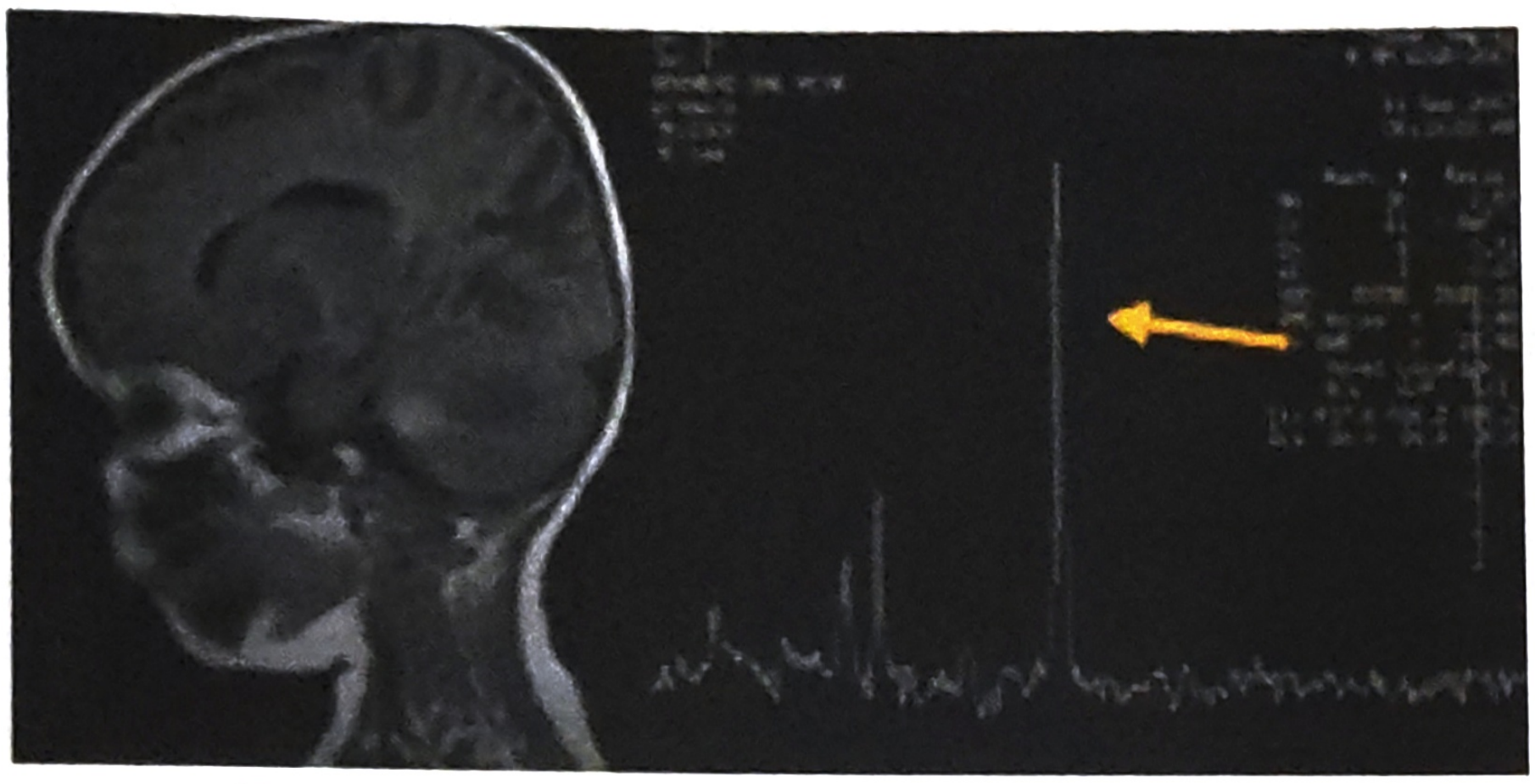

NAA peak on MR – spectroscopy @ 2 ppm

CANAVANS disease

Summary

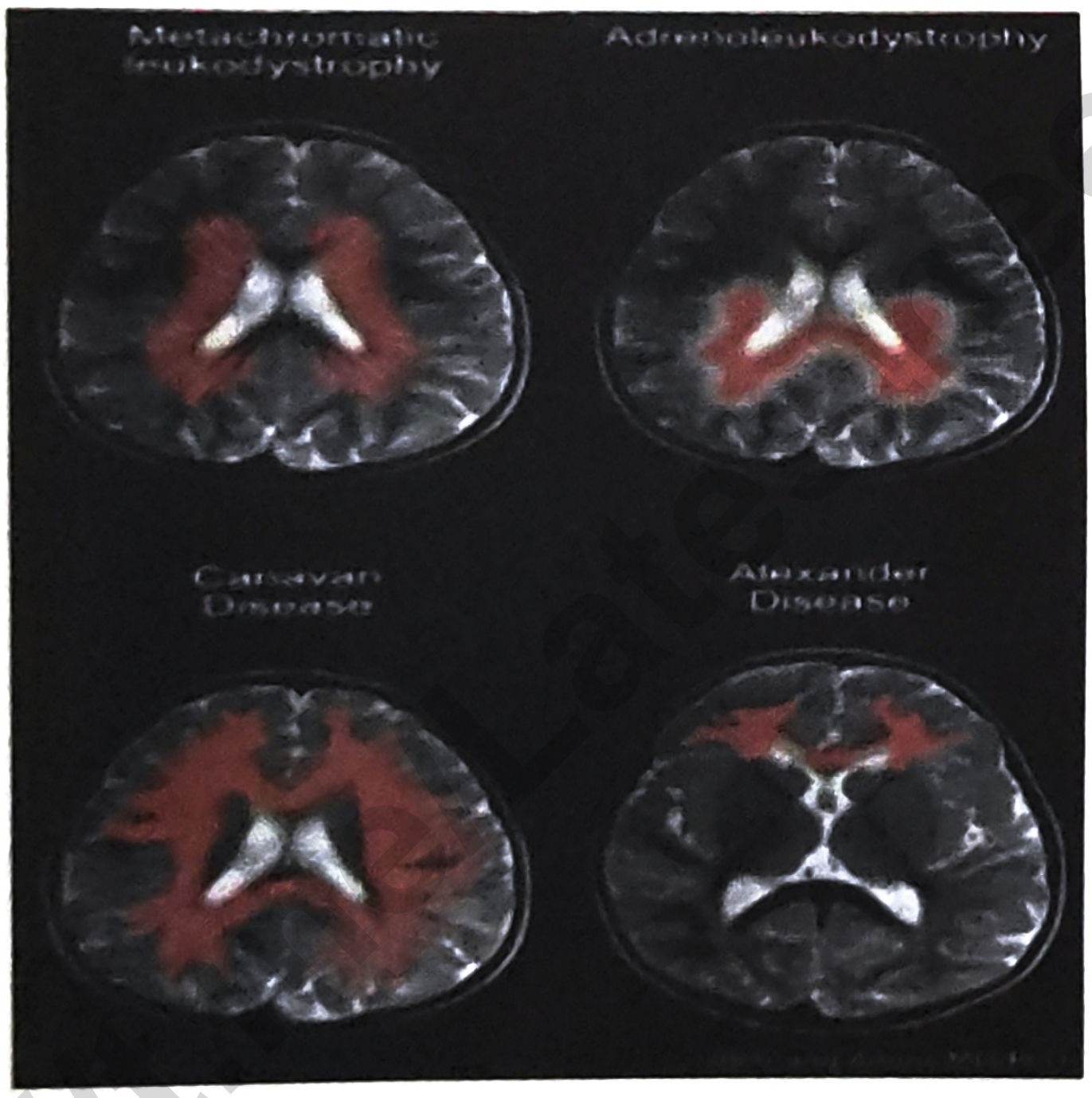

Encephalitis

00:22:38

→ HSV encephalitis
- Involvement of temporal lobe (MC)
- Involvement of Basi frontal lobes

→ VZV encephalitis
- Involvement of Cerebellum

→ Japanese encephalitis
- Involvement of B/L thalami

https://t.me/Latestpgnotes

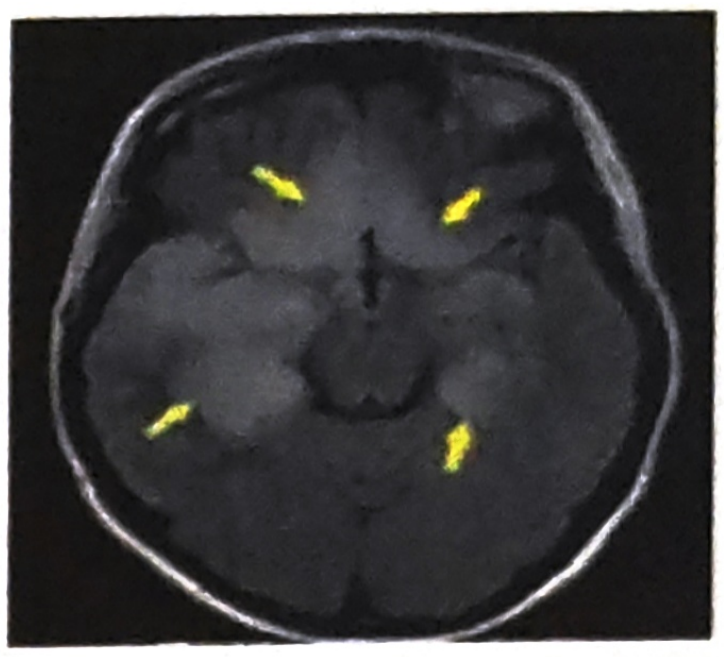

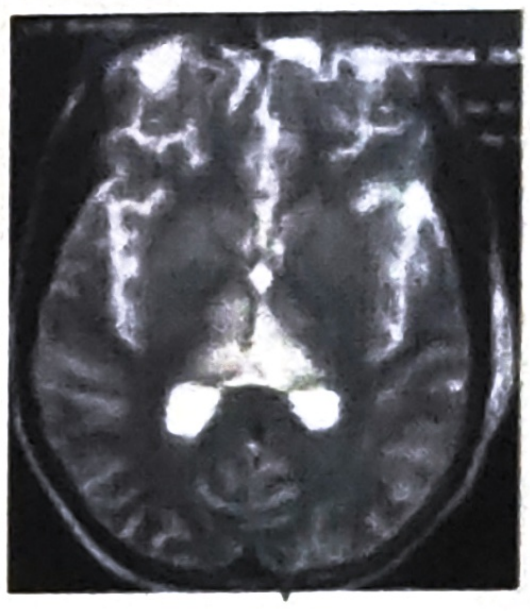

Ring enhancing lesions

00:25:07

→ Ring enhancing lesions In AIDS patient

- Toxoplasmosis (Eccentric Target Sign)

→ Ring enhancing lesions that are Multiple, conglomerate (fused) with lipid lactate peak on MRS – Tuberculoma

→ Ring enhancing lesions that shows Diffusion Restriction

- Cerebral abscess

→ Ring enhancing lesions at Grey white matter Junction

- Metastasis

→ Ring enhancing lesions that shows Escobar staging

- Neurocysticercosis
  - Vesicular stage → Parasite - alive, Minimal edema
  - Colloidal stage → colloidal cyst disintegrates and perilesional edema is maximum
  - Granular stage → thick walled cyst and edema decreases
  - Calcific nodular stage → dense calcifications gives Starry sky appearance on NCCT and No Edema

https://t.me/Latestneetpgnotes

PrepLadder

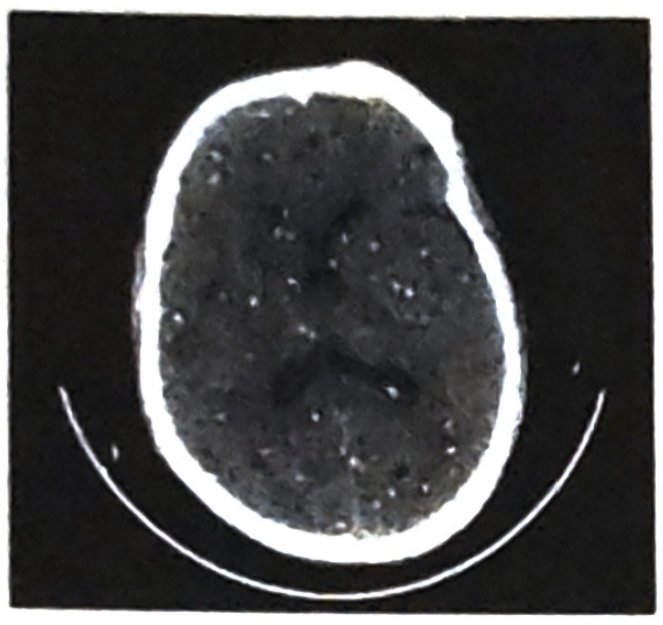

Starry sky appearance on NCCT

→ Rice grain calcification – Cysticercosis

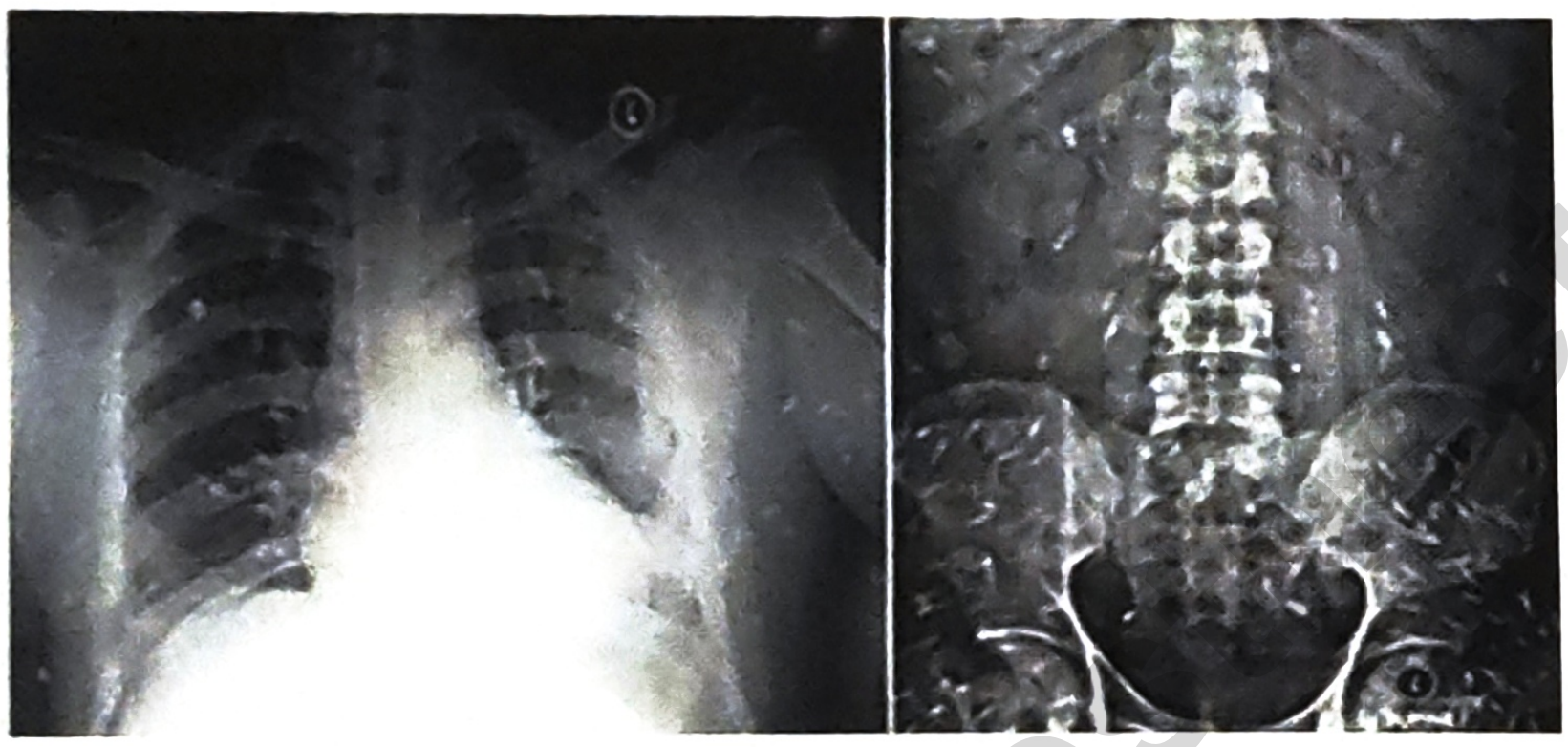

Starry sky appearance

→ On NCCT Brain – Neurocysticercosis (Calcific nodular stage)

→ On histopathology – Burkitt's lymphoma

→ On USG liver – Acute hepatitis

→ On immunofluorescence – PSGN

Tuberculoma

→ Multiple ring enhancing lesions that show a Lipid lactate peak (LLP) on MR Spectroscopy at 1 ppm

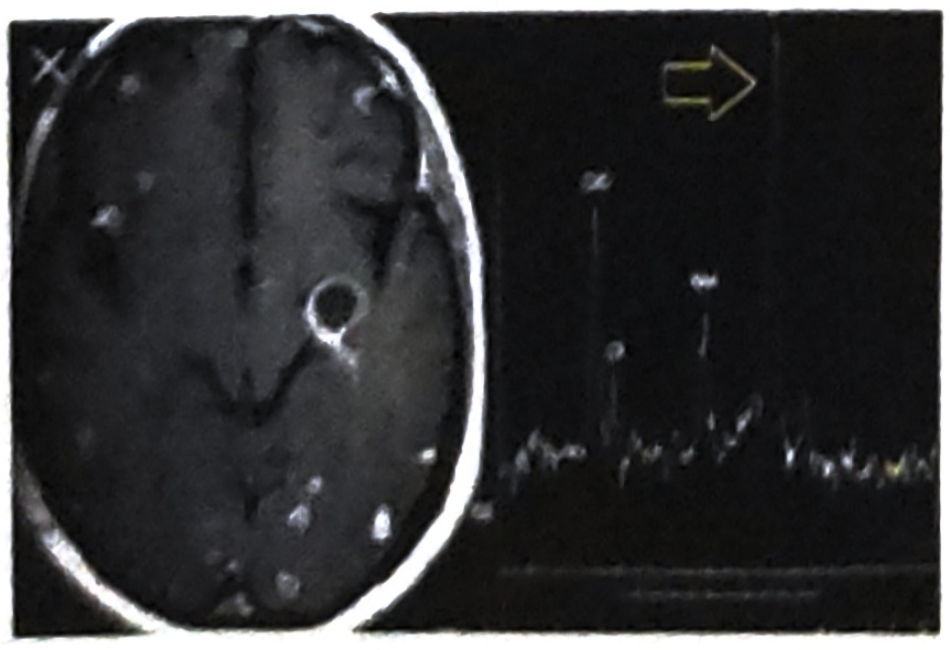

MR Spectroscopy

https://t.me/Latestpgnotes

PrepLa

Cerebral Abscess

→ Ring enhancing lesion showing Diffusion Restriction (DWI)

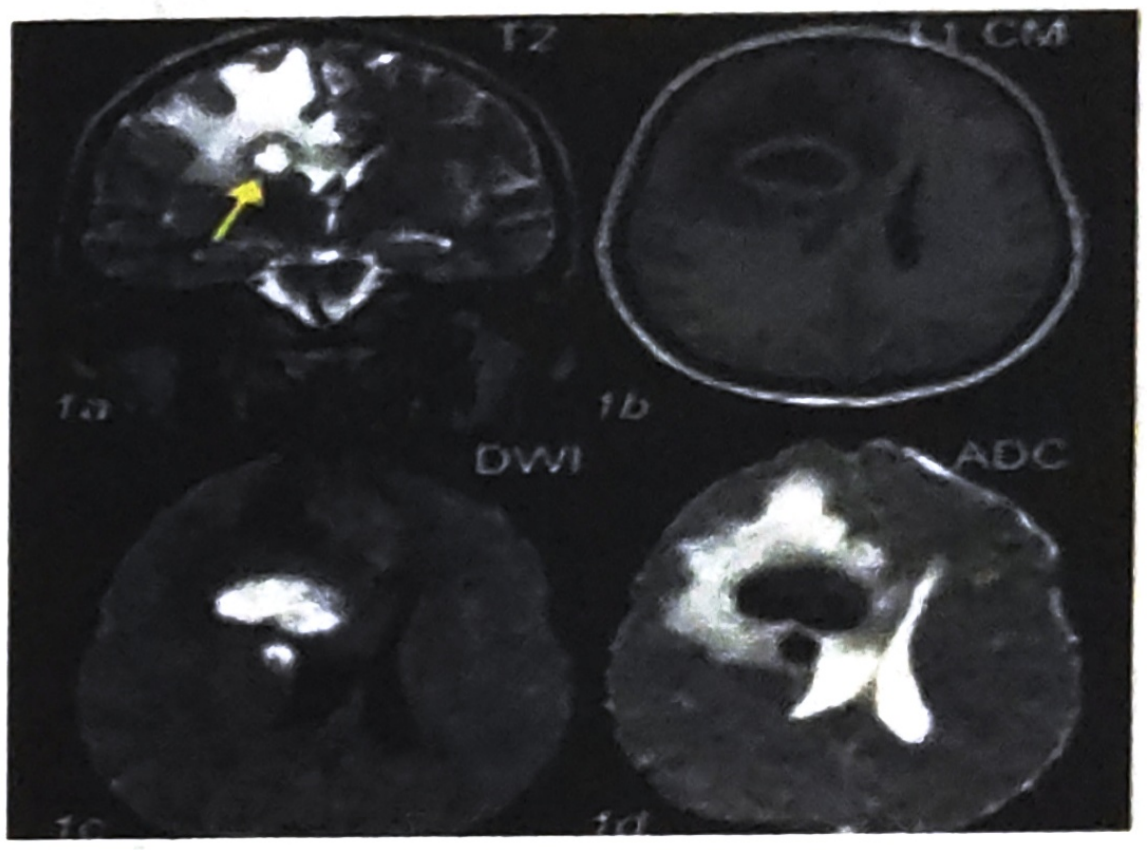

Cerebral Abscess

00:37:08

Supra nuclear palsy	Panda sign
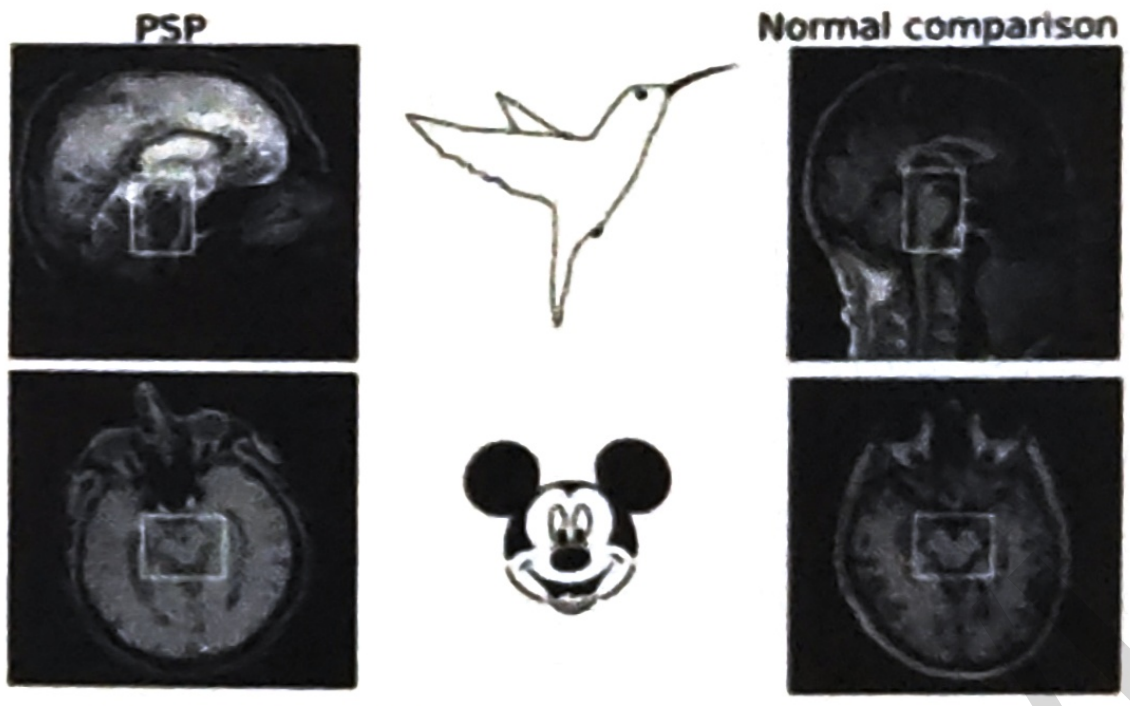 • Humming bird sign (midbrain atrophy) – on sagittal MRI • Micky Mouse Sign (midbrain atrophy) – on axial MRI	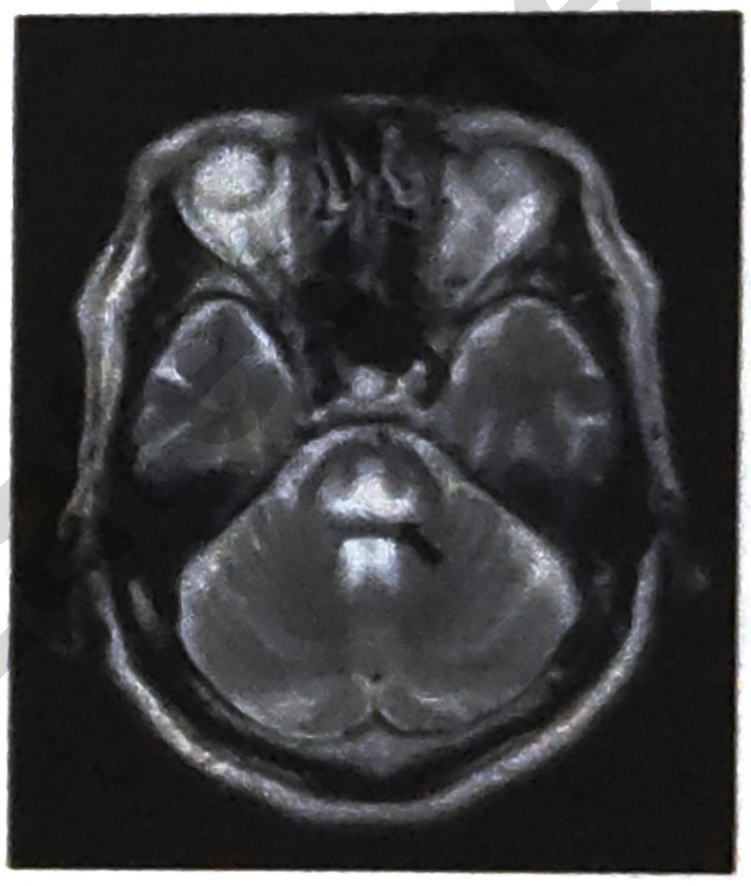 Feature of Wilson disease (due to deposition of copper)

Joubert syndrome

00:40:25

→ Molar tooth sign (due to elongated Cerebellum Peduncles

→ Bat wing appearance (dilation of 4th Ventricle)

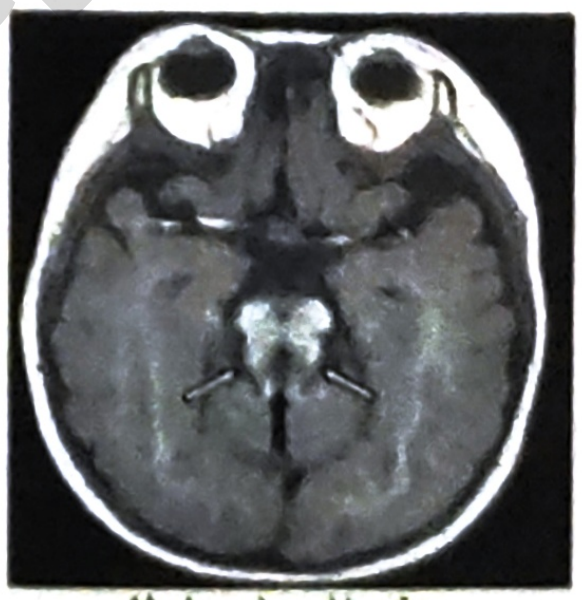

Molar tooth sign

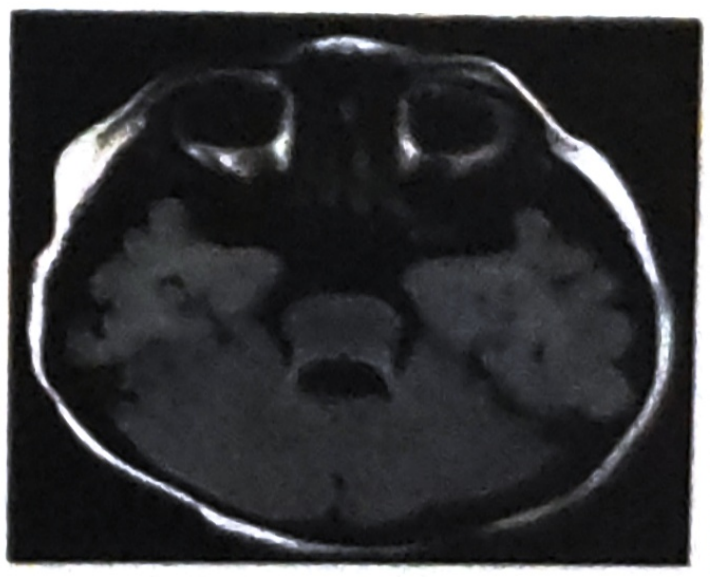

Bat wing appearance

PrepLadder

Moya Moya Disease

→ Chronic vasospasm of supraglenoid part of ICA – gives Puff of Smoke appearance on Angiography

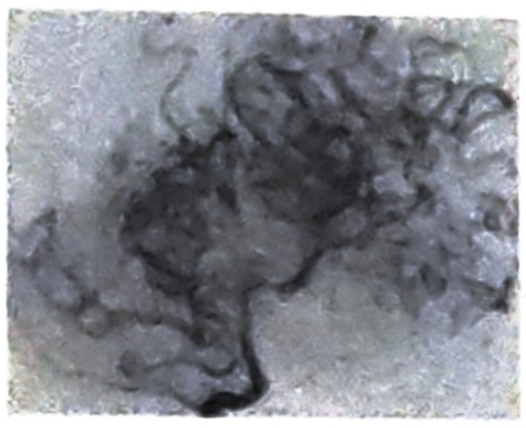

Vein of Galen Malformation

→ Characterized by Triad of

- Midline cystic swelling
- Hydrocephalus
- CHF

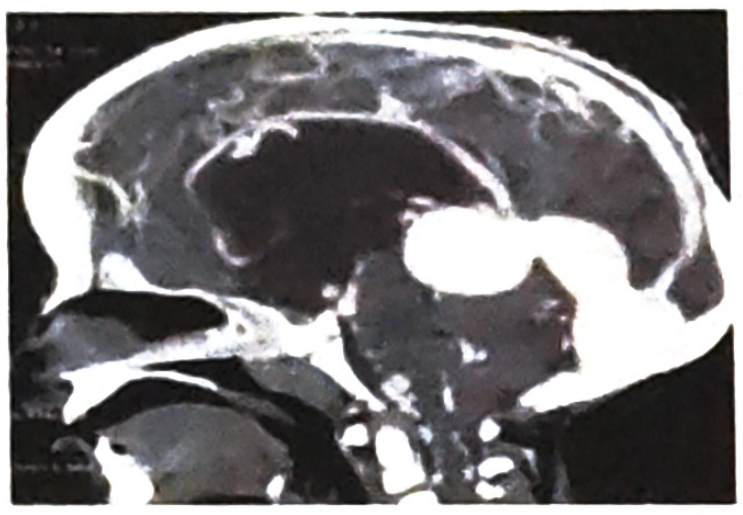

Multiple system atrophy(Type C)

→ Hot Cross Bun sign (Cruciate Cross like Hyperintensities)

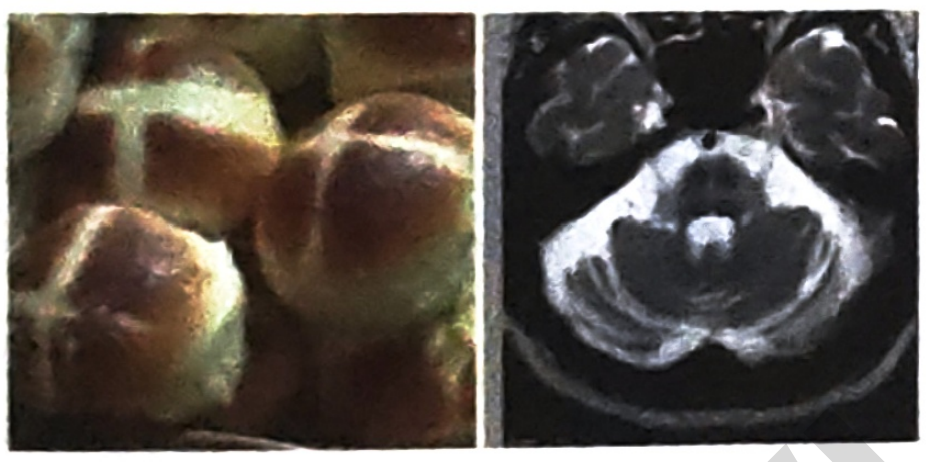

CJD (Spongiform leuco encephalitis)

→ Gyral Hyperintensities / Cortical ribboning

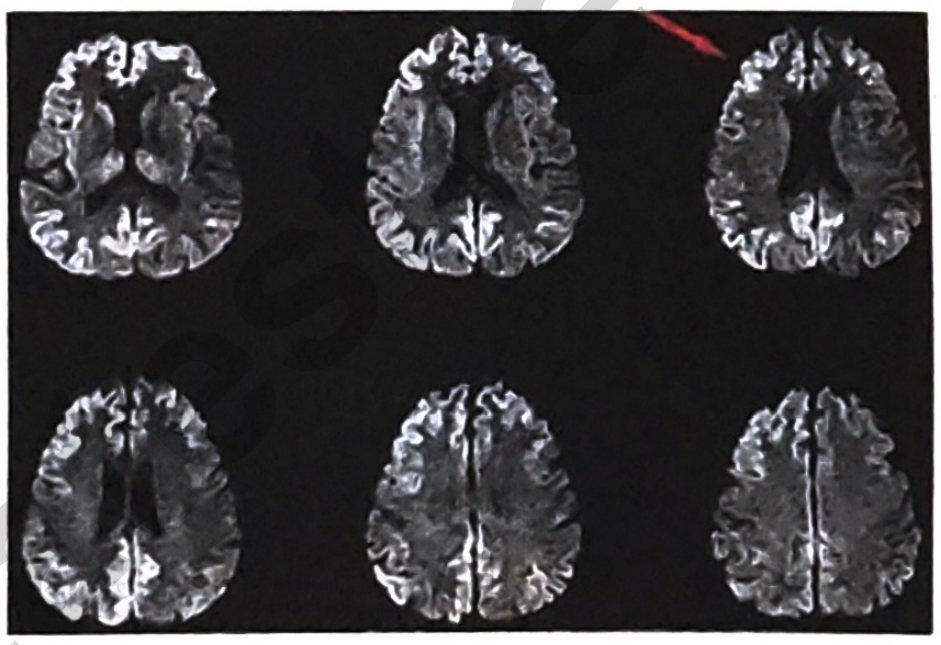

Variant CJD

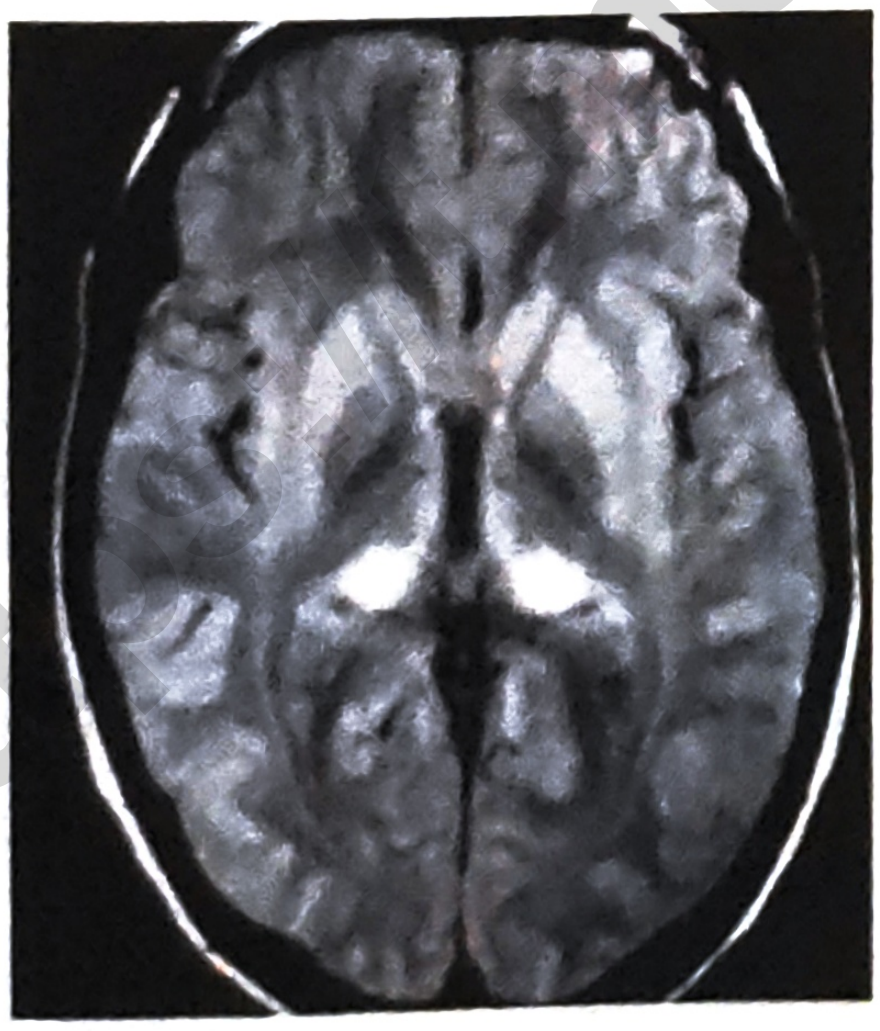

→ Shows Hockey Stick Sign on CT

TB meningitis

→ Characterized by

- Basal exudates
- Hydrocephalus
- Infarcts

AML (Amyotrophic Lateral sclerosis) 00:49:15

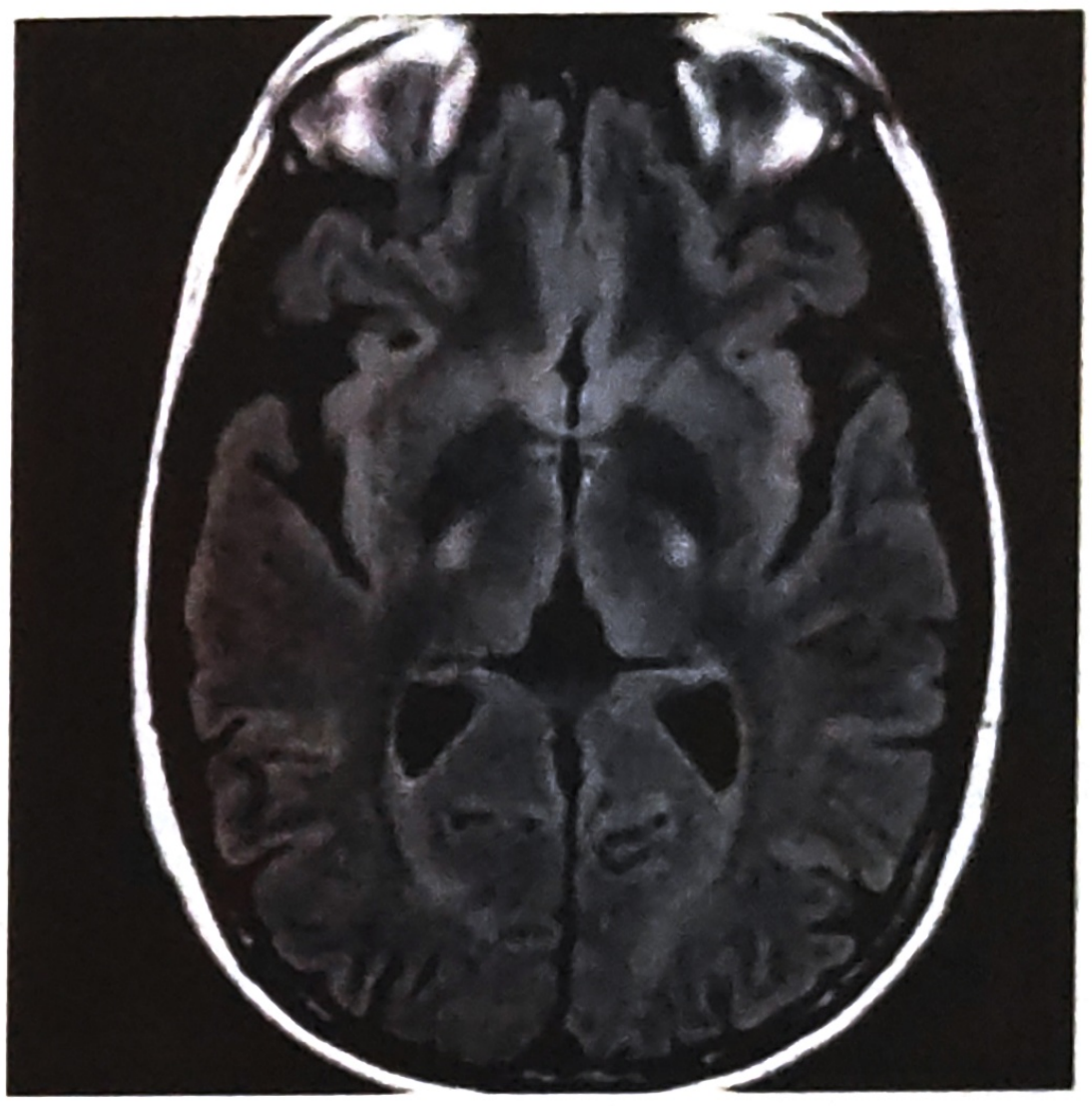

→ Hyperintensities in corticospinal tracts (Posterior limb of Internal capsule)

https://t.me/Latestneetpgnotes

PrepLadder

Chapter 22

NEURORADIOLOGY- PART 3

Brain tumor 00:00:17

- → M.C brain tumor - Secondaries / metastasis
- → M.C Primary brain tumor - Meningioma
- → M.C intraparenchymal brain tumor - Glioma
- → M.C calcifying brain tumor - Craniopharyngioma
- → M.C intraparenchymal calcifying brain tumor Oligodendroglioma

Most brain tumors are hypodense on CT except:

- → Medulloblastoma
- → CNS lymphoma
- → Meningioma
- → Pineal Germinoma

} hyperdense on CT

Note:

- → IOC for brain tumors → C - MRI (contrast enhanced MRI)

→ Brain tumor spread by CSF: MeC-EGG

- Me - Medulloblastoma
- C - CNS lymphoma
- E - Ependymoma
- G - Glioblastoma multiforme
- G - Germinoma

→ Calcifying brain tumors; "Ca2+ COME"

- C - Craniopharyngioma (MC)
- A - Astrocytoma, aneurysm (2'A's)

https://t.me/Latestneetpgnotes

PrepL

- C - Choroid plexus papilloma
- O - Oligodendroglioma (MC intraparenchymal calcifying)
- M - Meningioma
- E - Ependymoma

Medulloblastoma (PNET) 00:07:14

→ Highly malignant undifferentiated tumor

→ 15 - 20 % pediatric brain tumor

→ Occurs at 4-11-years age group peaks at 5 years

→ M > F (2-4) times

→ Location - from roof of 4th ventricle & cerebellar vermis

→ 1/3 have subarachnoid metastasis and drop metastasis to spine

→ Hyperdense on CT

→ On MRI - diffusion restriction

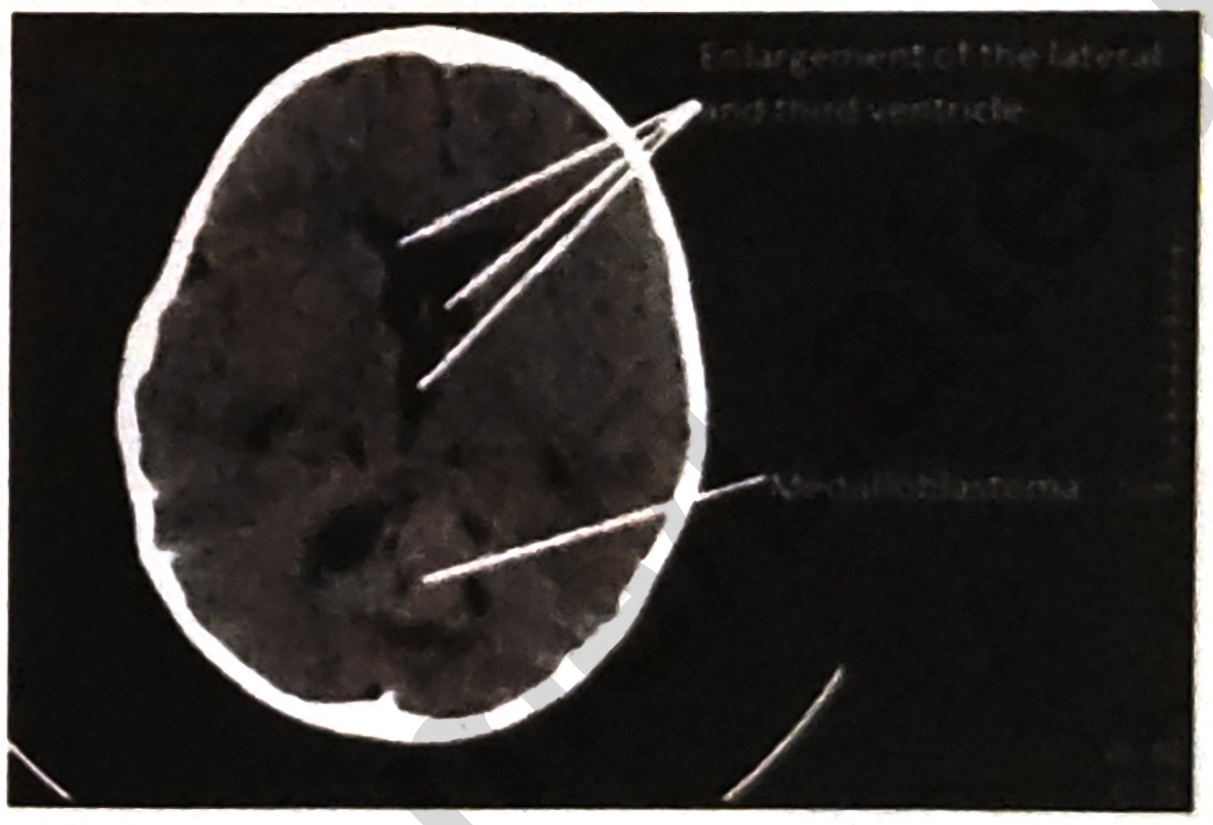

Medulloblastoma

Ependymoma	Medulloblastoma
→ Floor of 4th ventricle	→ Roof of 4th ventricle & Cerebellar vermis
→ Hypodense on CT	→ Hyperdense on CT
→ NO diffusion restriction	→ Diffusion restriction
→ ↑ ADC	→ ↓ ADC
→ Foraminal spread	→ CSF spread, drop Metastasis with Sugar Coating
	→ Prophylactic Cranio spinal Irradiation

https://t.me/neetpgnotes

PrepLadder

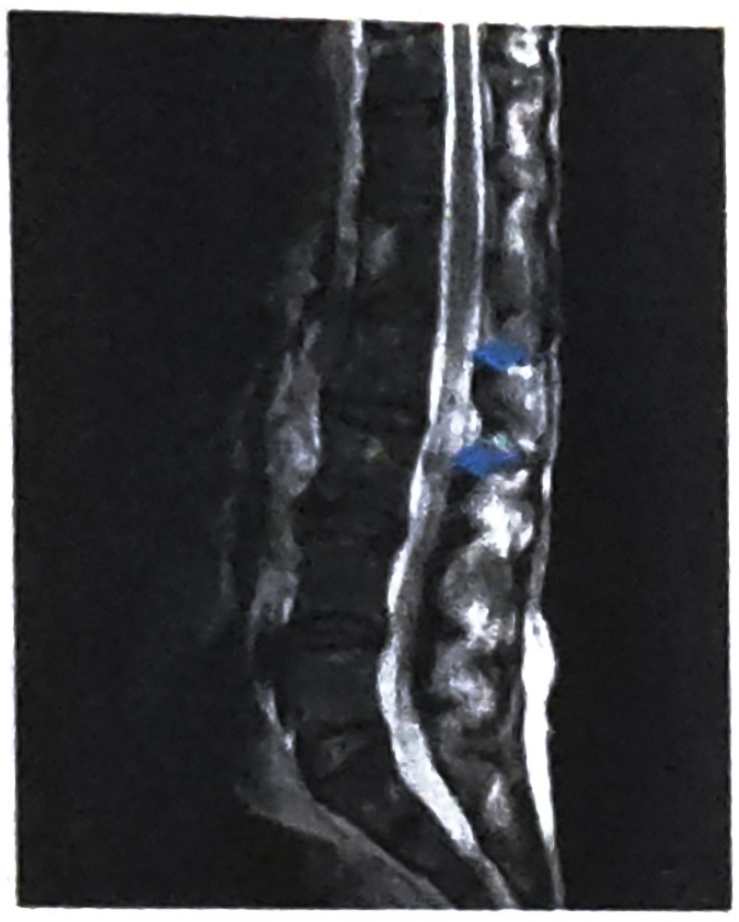

Sugar coating Drop metastasis

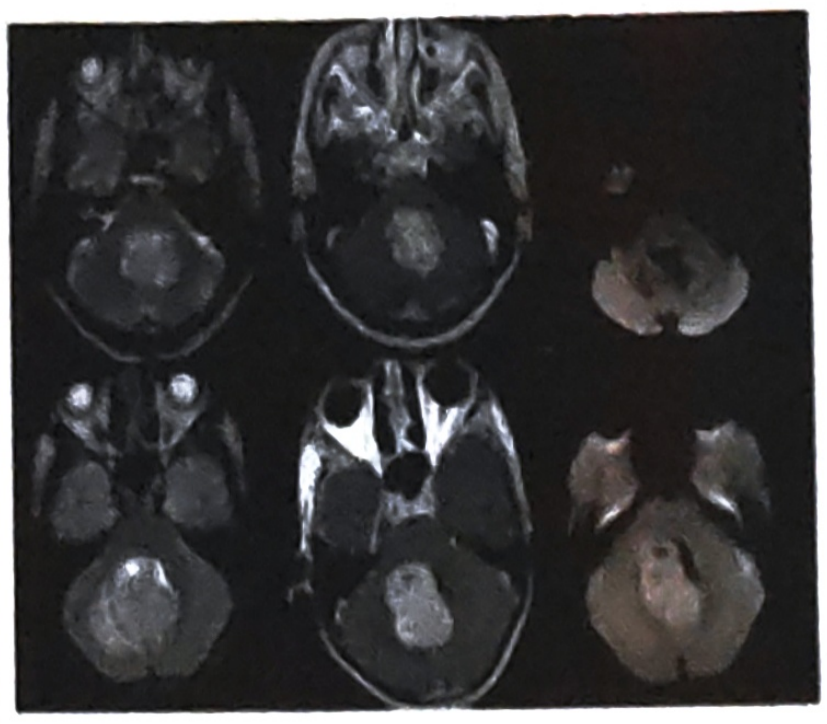

Medulloblastoma

Ependymoma

- → 10% primary brain tumors of children
- → 70% are infratentorial and 30% are supratentorial
- → M > F
- → Location - arise from ependymal cell of floor of 4th ventricle and foramen of Luschka and less commonly from roof.
- → Plastic tumor that conforms to ventricle and extrudes through foramen of Luschka

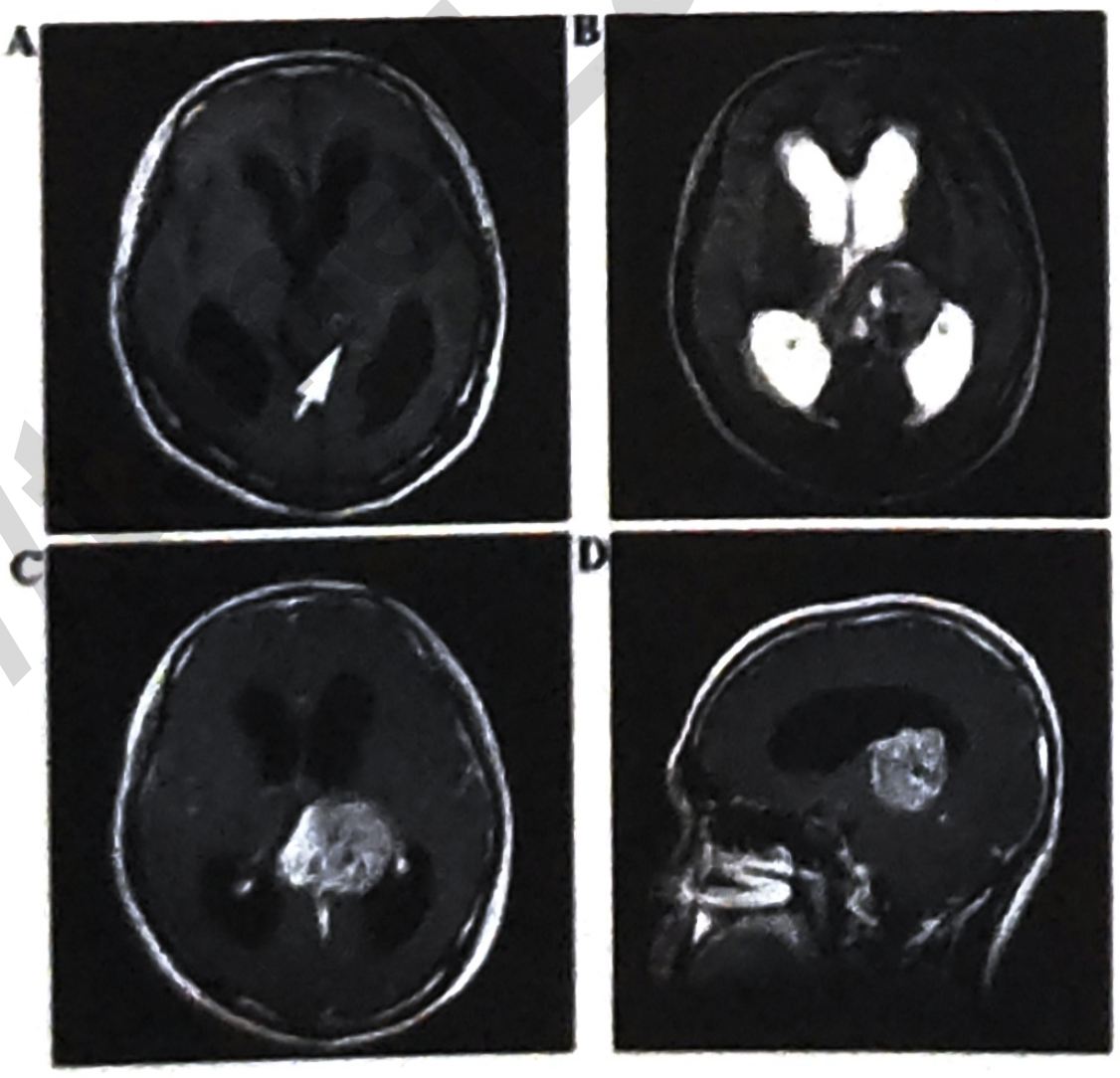

Ependymoma

Pineal Germinoma

- → Lesion posterior to 3rd ventricle
- → They are hyperdense lesions.

https://t.me/latestneetpgnotes

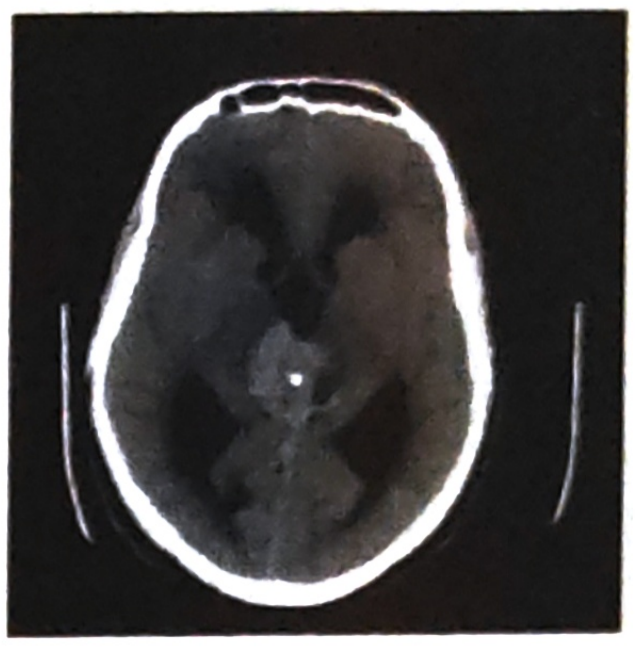

Pineal germinoma

PARINAUD Syndrome 00:20:36

→ Pineal gland tumor compressing superior colliculus causing upward gaze palsy

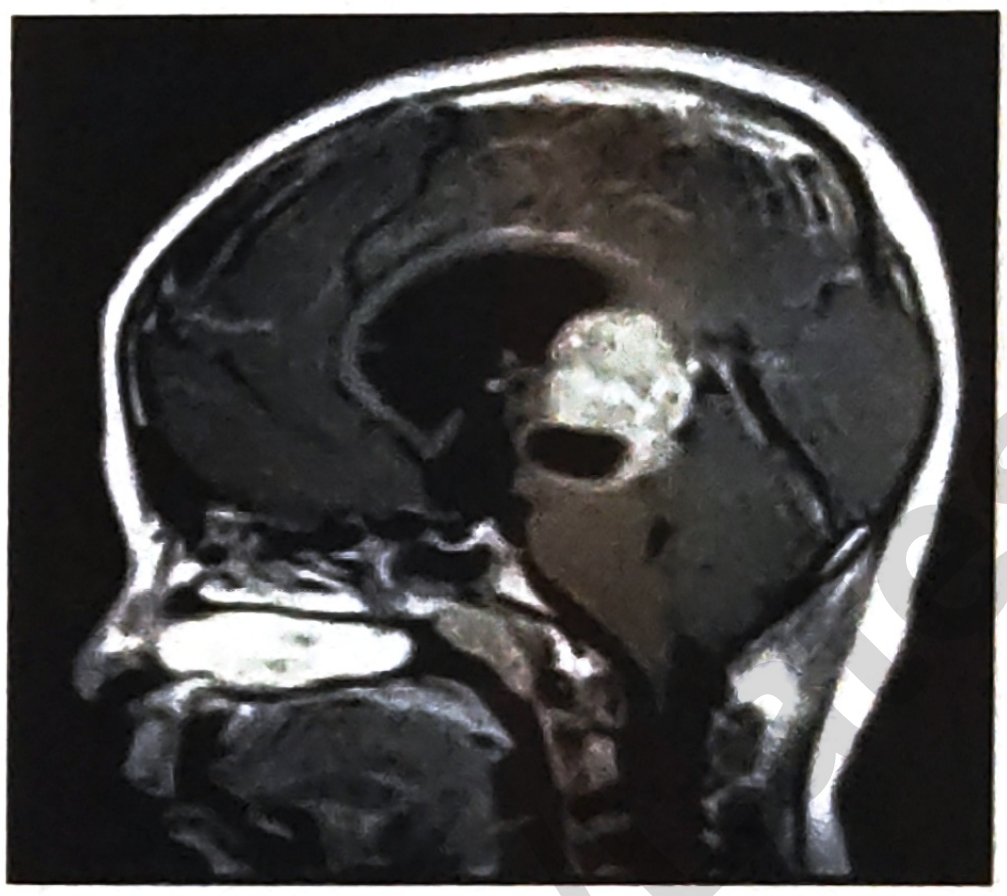

Parinaud syndrome

00:22:00

Craniopharyngioma	Pituitary Adenoma
→ Solid cystic lesions	→ Solid
→ Suprasellar lesion with sellar extension	→ Seller mass with suprasellar extension
→ Machine oil proteinaceous content	→ Figure of 8 / snowman appearance
→ On CT - Calcification is seen	→ No calcification
→ Hyperintense on T1	→ Hypointense on T1

https://t.me/bestneetpgnotes

PrepLadder

Craniopharyngioma

→ can be Adamantinomatous / papillary

Adamantinomatous	papillary
• More common in children • Commonly undergoes calcification	• More common in adult • No calcification

Glioblastoma Multiforme

→ Thick wall Enhancing lesion with some areas of necrosis

→ Can cross the midline and invading the corpus

→ Callosum which gives a Butterfly shaped lesion

Glioblastoma Multiforme

Meningioma 00:25:15

→ MC primary brain tumor

→ Broad base towards Dura

→ Dural Tail sign

→ commonly calcify

→ Sunray / Spoke Wheel vasculature

- It produces Intense contrast enhancement
- Early to come & late to go" → Mother in Law sign
  (Early enhancement & delayed washout)

→ Hyperdense on CT

→ calcification

→ Skeletal hyperostosis

→ Pneumosinus dilatans - adjacent sinuses are dilated

→ On MRI → isointense / Hypointense on T2

https://t.me/Latestneetpgnotes

PrepL

→ On MRS → Alanine Peak @ 1.4 ppm
→ Extra axial, intradural
→ Intradural extramedullary
→ Produces CSF cleft

Meningioma

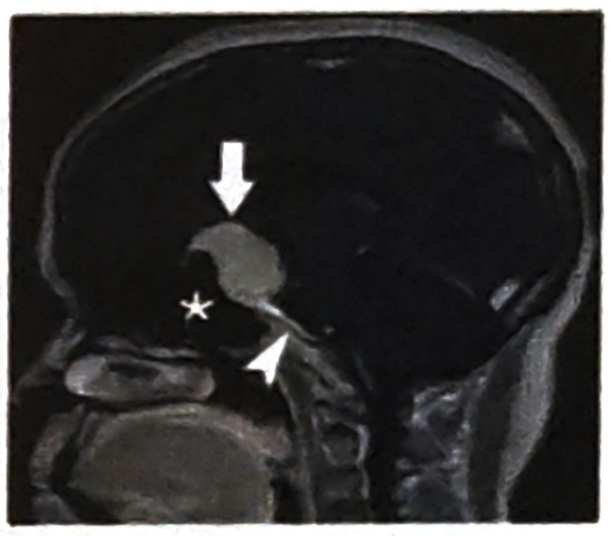

Pneumosinus dilatans

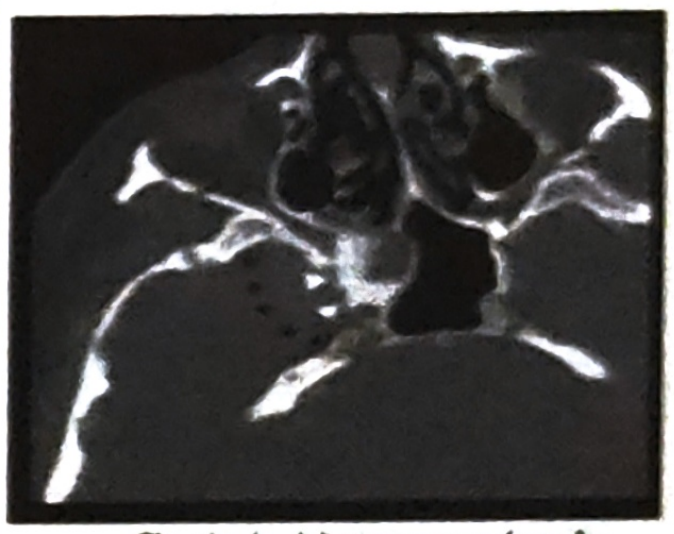

Skeletal hyperostosis

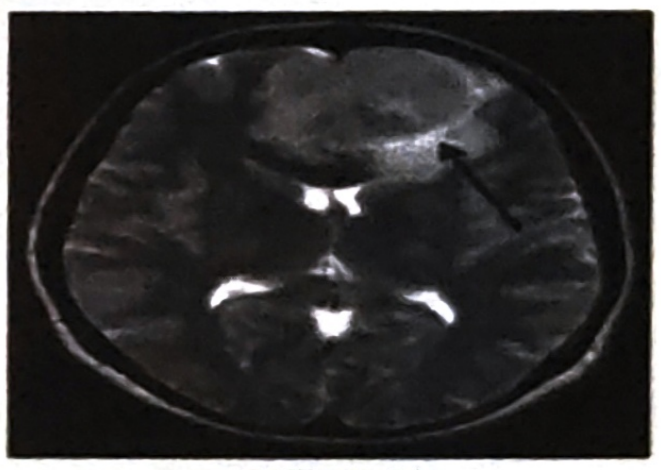

CSF cleft

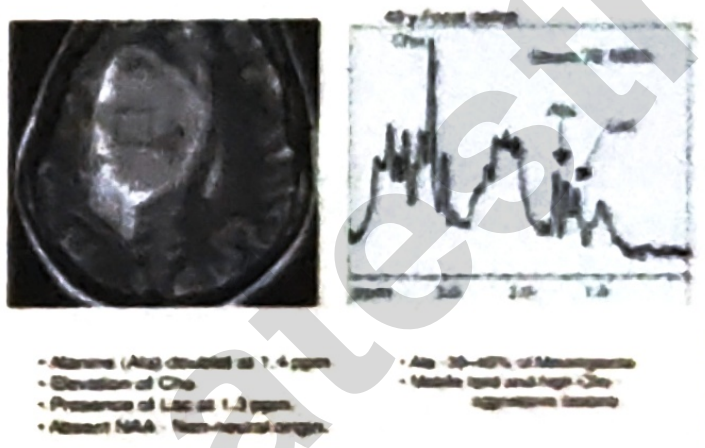

Alanine peak on MRS

https://t.me/Latestneetpgnotes

Choroid plexus papilloma

00:34:12

→ CSF producing
→ Normal location of choroid plexus is occipital horns of lateral ventricle
→ Causes both Upstream and down stream hydrocephalus

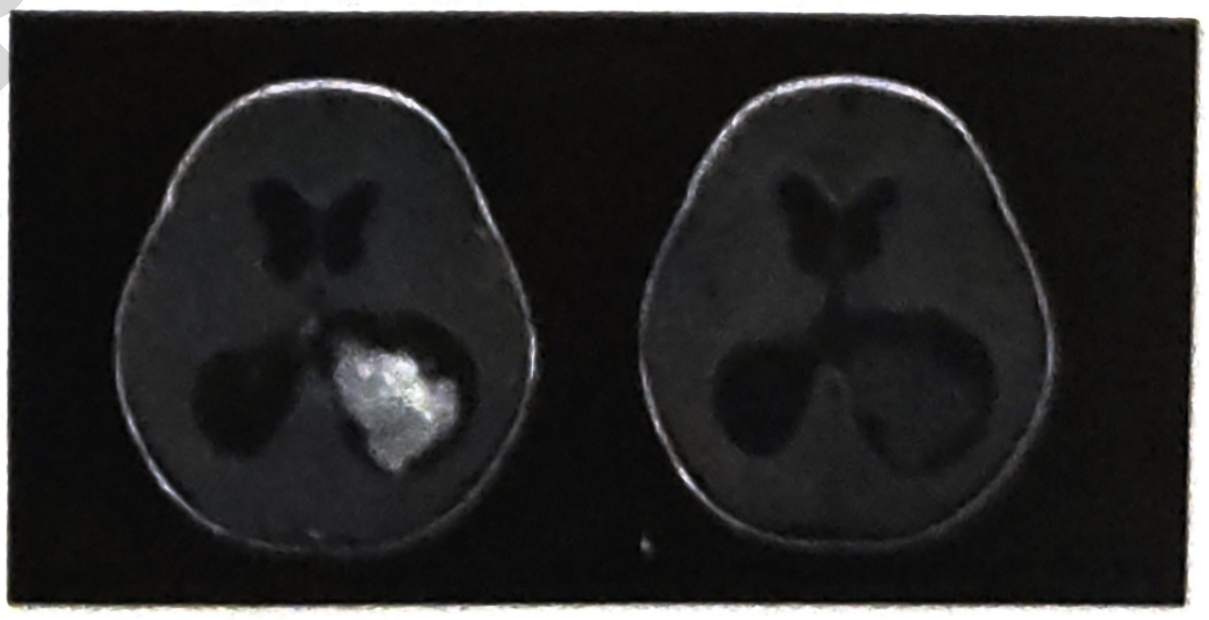

Choroid plexus papilloma

Chapter 23

Neuro Radiology Part 4

00:00:30

NF1	NF2
→ Defect in chromosome – 17 → protein involved in NF1 is Neurofibromin	→ Defect on chromosome - 22 → Protein involved in NF2 is Merlin
→ NF1 are Peripheral lesions • Lisch Nodules • Iris Hamartomas • Optic nerve gliomas • Plexiform neurofibromas	→ NF2 are Central lesions Mnemonics' MISME' • Multiple inherited • Schwannoma • Meningioma • Ependymoma
→ Musculoskeletal defects • Ribbon ribs • Sphenoid dysplasia of greater wing of Sphenoid • Bare orbit sign – absent innominate line • Pseudoarthrosis of tibia • Scoliosis • Lateral meningocele	

https://t.me/Latestneetpgnotes

PrepLadder



Dumb bell sign -NF

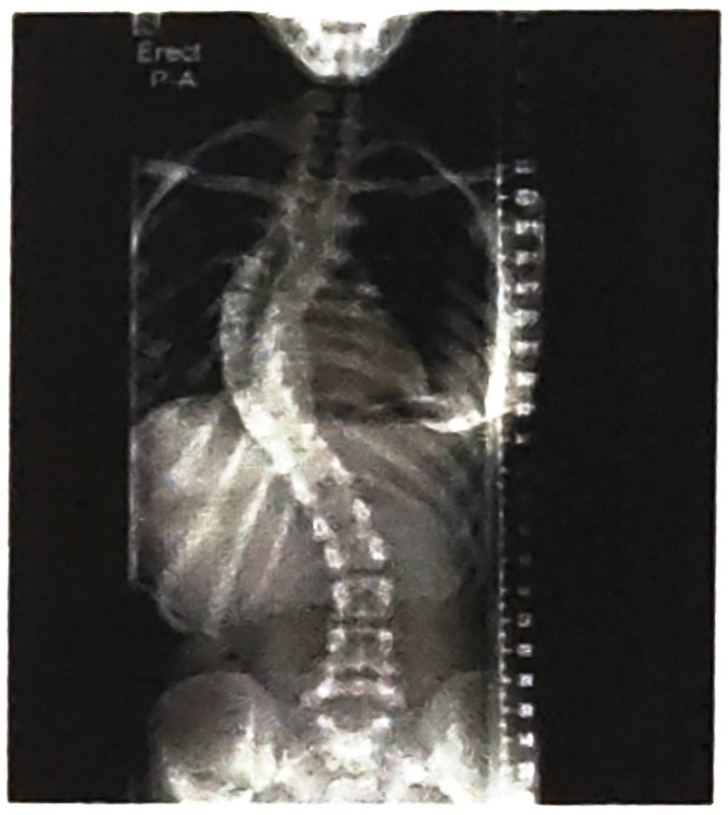

Scoliosis - NF1

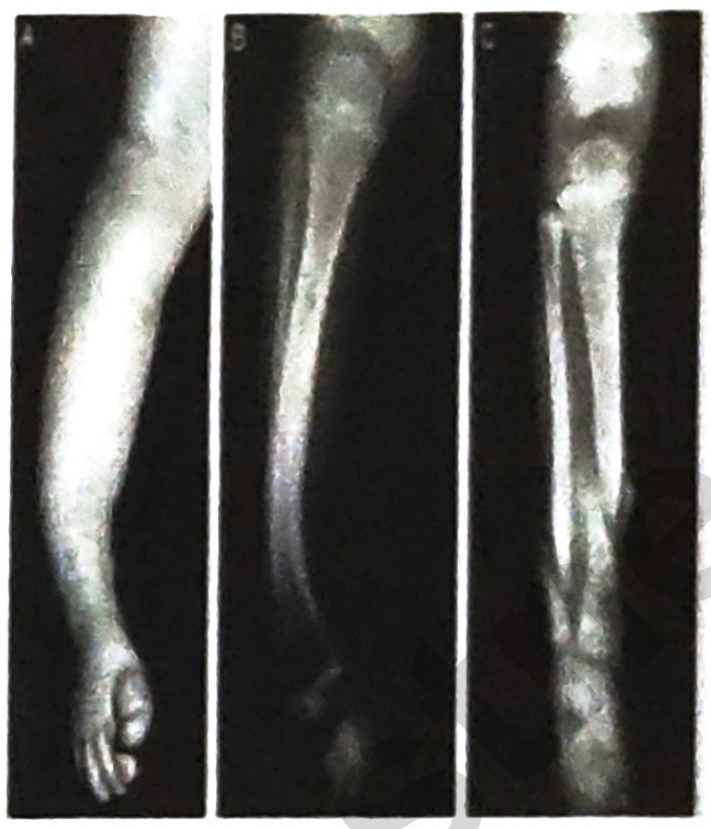

Pseudoarthrosis of tibia - NF1

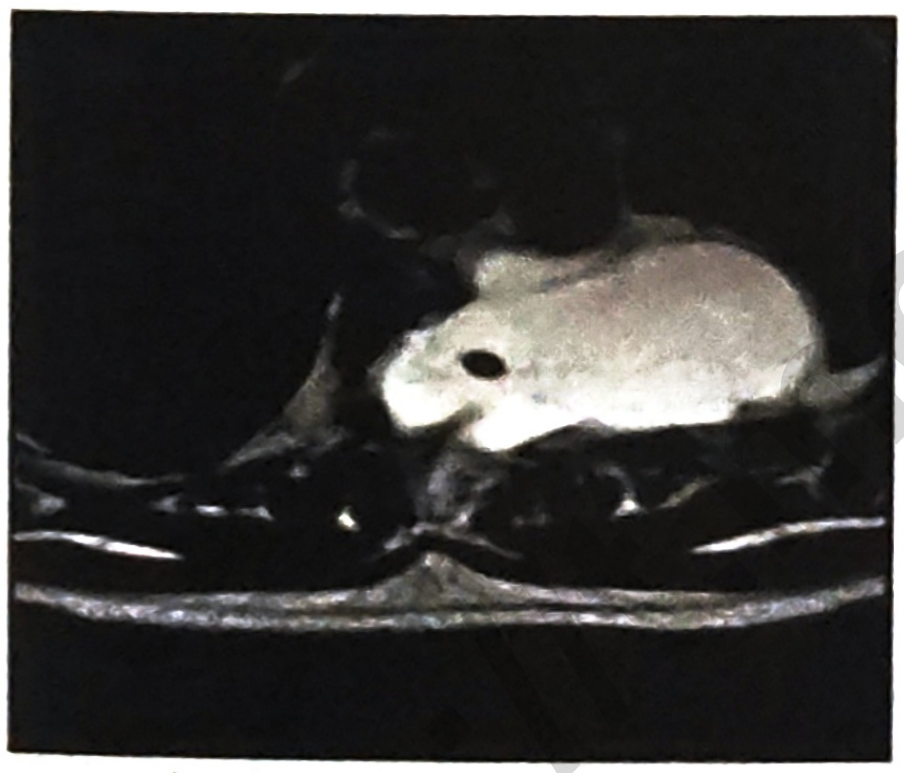

Lateral meningocele

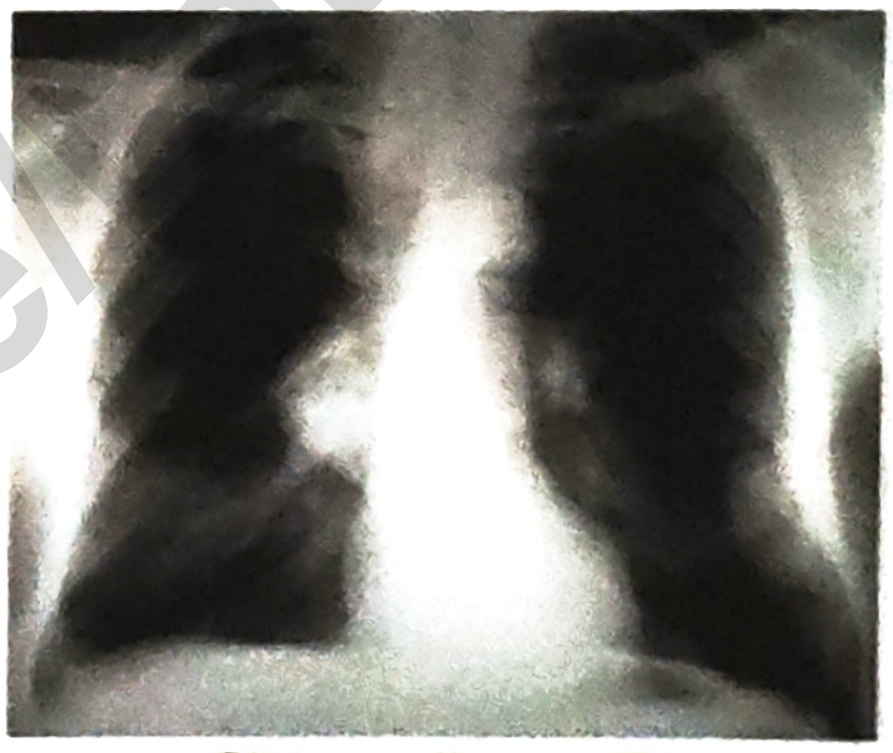

Ribbon ribs - NF1

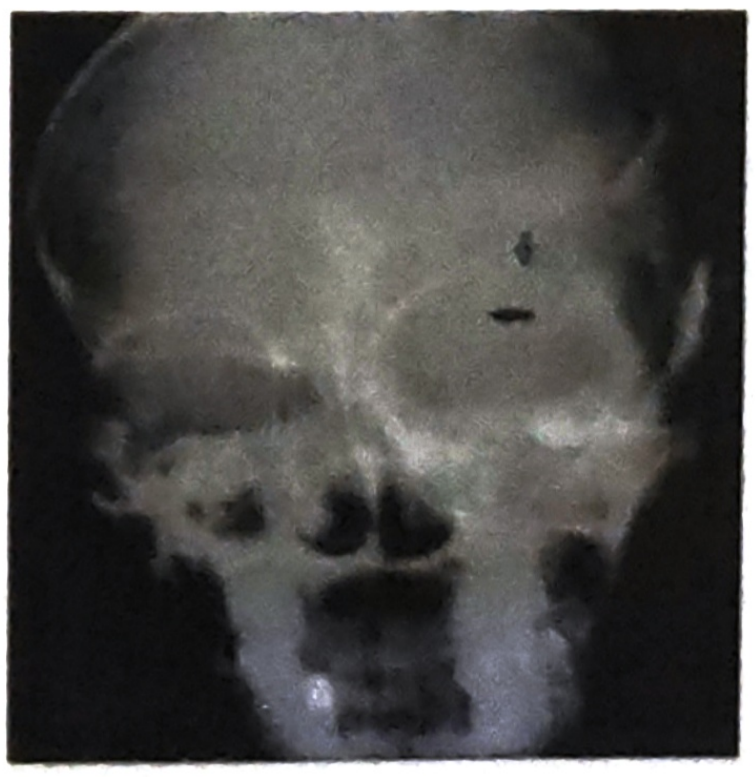

Bare orbit sign - NF1

https://t.me/neetpgnotes

PrepLadder

Tuberous sclerosis

00:08:55

- → Subependymal calcific nodules showing candle drippling like calcifications
- → Ash leaf macule (MC)
- → Adenoma sebaceum (Angiofibroma)
- → Bilateral angiomyolipoma in Kidney
- → Shagreen patch
- → Subependymal calcific nodules
- → Cortical tubers
- → SEGA
  - Subependymal Giant cell astrocytoma
  - SEGA more commonly located on ' Foramen of Monro'

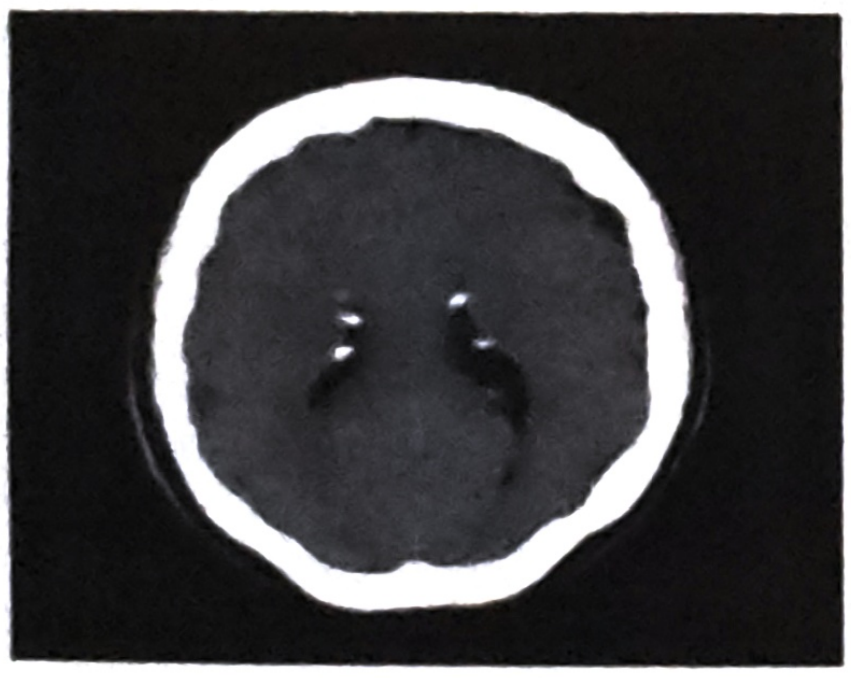

Tuberous sclerosis

SEGA

Findings of tuberous sclerosis

- → VOGTS TRIAD: (EPI LO IA)
  - EPI - Epilepsy
  - LO - Law IQ
  - IA - Adenoma sebaceum
- → Cardiac Rhabdomyoma
- → In the Lungs - cystic dilatation of lymphatic vessels, common in Female called as lymphangioleiomyomatosis (LAM)

https://t.me/Latestpgnotes

PrepLadder

For more free ebooks and notes, visit

https://t.me/Latestneetpgnotes

Or click this page to join

Cystic lesion with enhancing neural nodule involving cerebellar hemisphere

Child	Adult
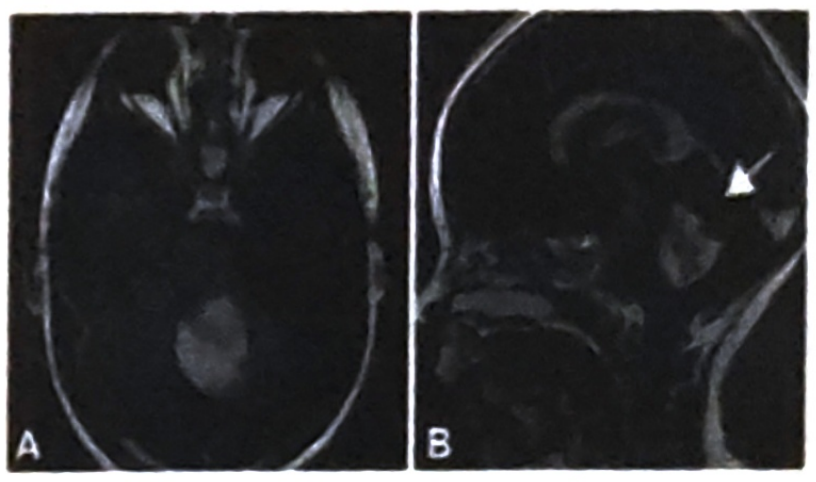	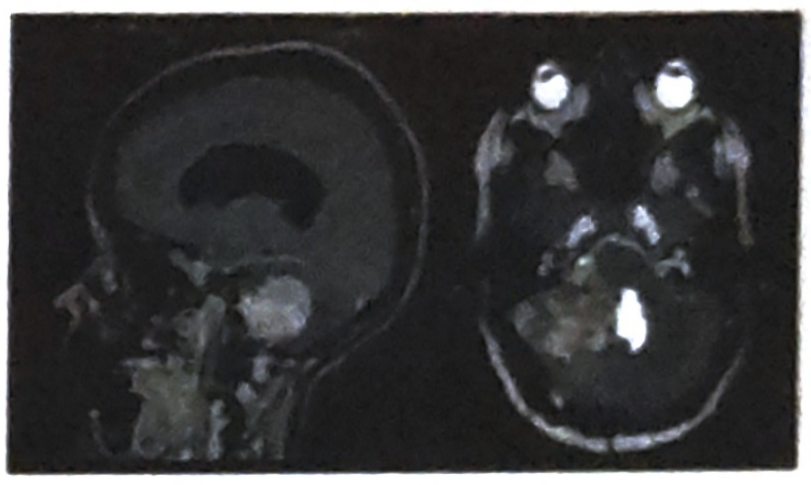
Pilocytic astrocytoma	Hemangioblastoma

Von-Hippel Lindau Syndrome (VHL) 00:15:17

→ More than 1 cystic lesions

→ Ch 3 defect

→ B/L clear cell RCC

→ Cerebellar hemangioblastoma

→ Retinal hemangioblastoma

→ ↑ risk of pheochromocytoma

→ ↑ risk of islet cell tumors

→ ↑ risk of endolymphatic sac tumors

Acoustic Neuroma / vestibular Schwannoma 00:17:57

→ Ice cream cone appearance

→ M/C cerebellopontine angle tumor

→ NF2 - B/L acoustic neuromas

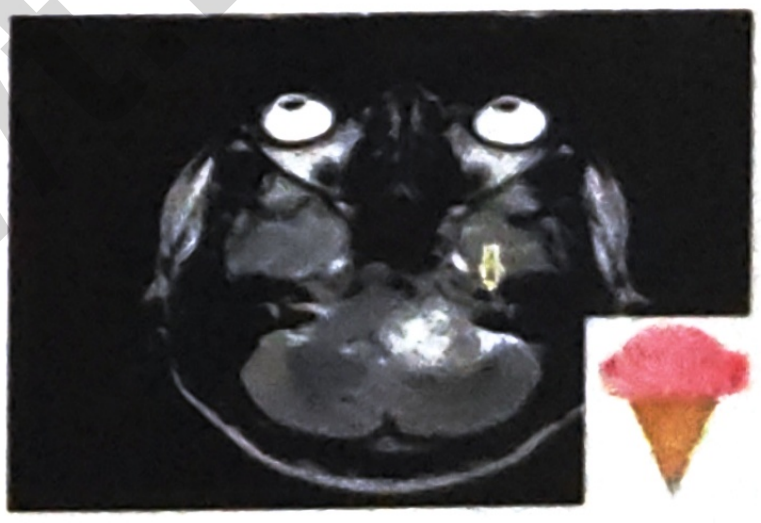

Ice cream cone appearance

Imaging sign associated with Corpus callosum

→ Lipoma of corpus callosum - Bracket calcification

→ Agenesis of corpus callosum - Racing car sign / moose head appearance / Viking helmet sign

→ Necrosis of corpus callosum - Marchiafava Bignami disease

https://t.me/Latestneetpgnotes

PrepLadder

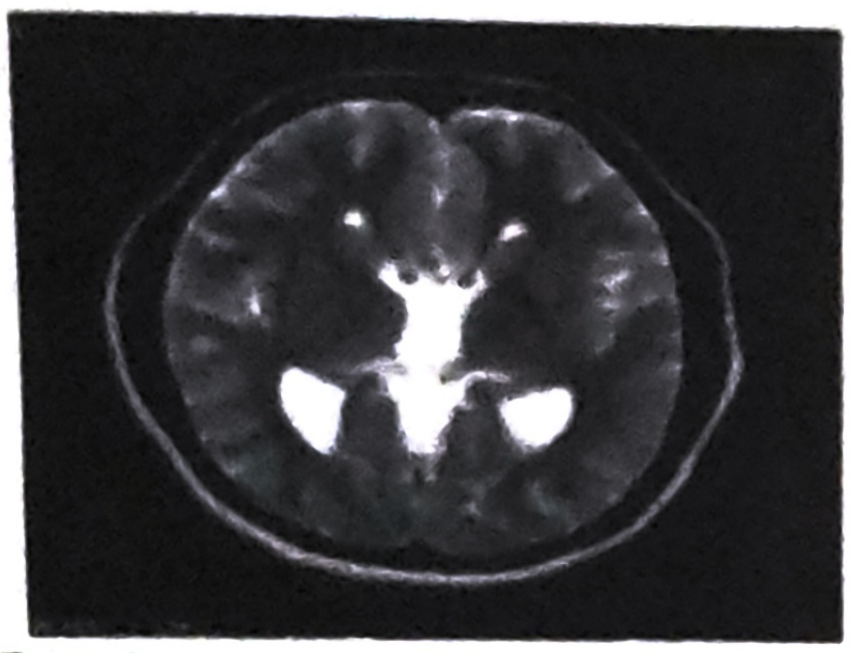

Bracket calcification - lipoma

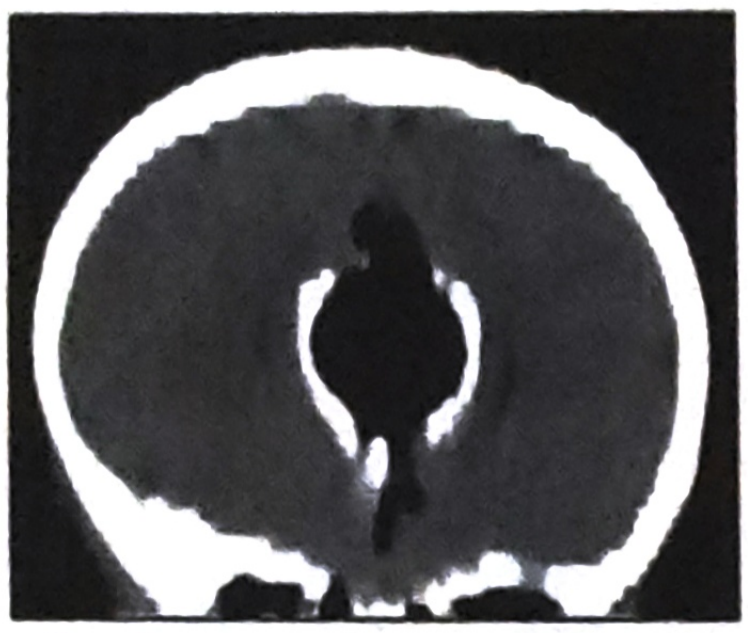

Racing ca sign - agenesis

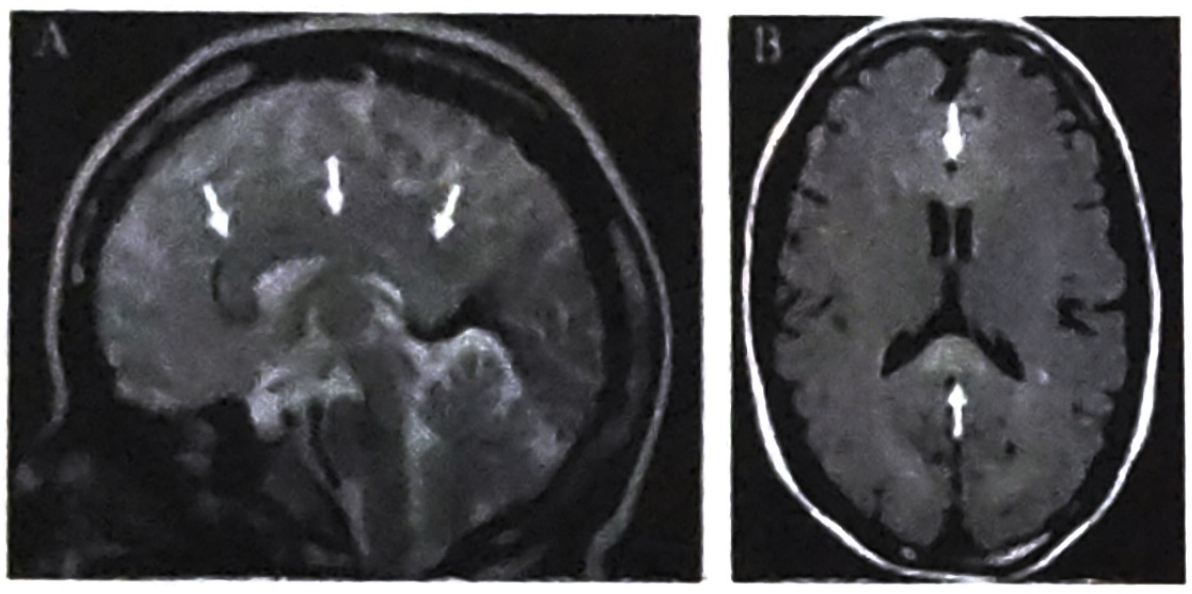

Marchiafava-Bignami disease

Sturge – Weber syndrome

00:21:30

→ Aka Trigemino - encephalic vascular malformation

- In face – port wine stain
- In leptomeningeal area – tram track appearance
- Ipsilateral hemi atrophy of the brain
- Seizure (contralateral to the port wine stain)

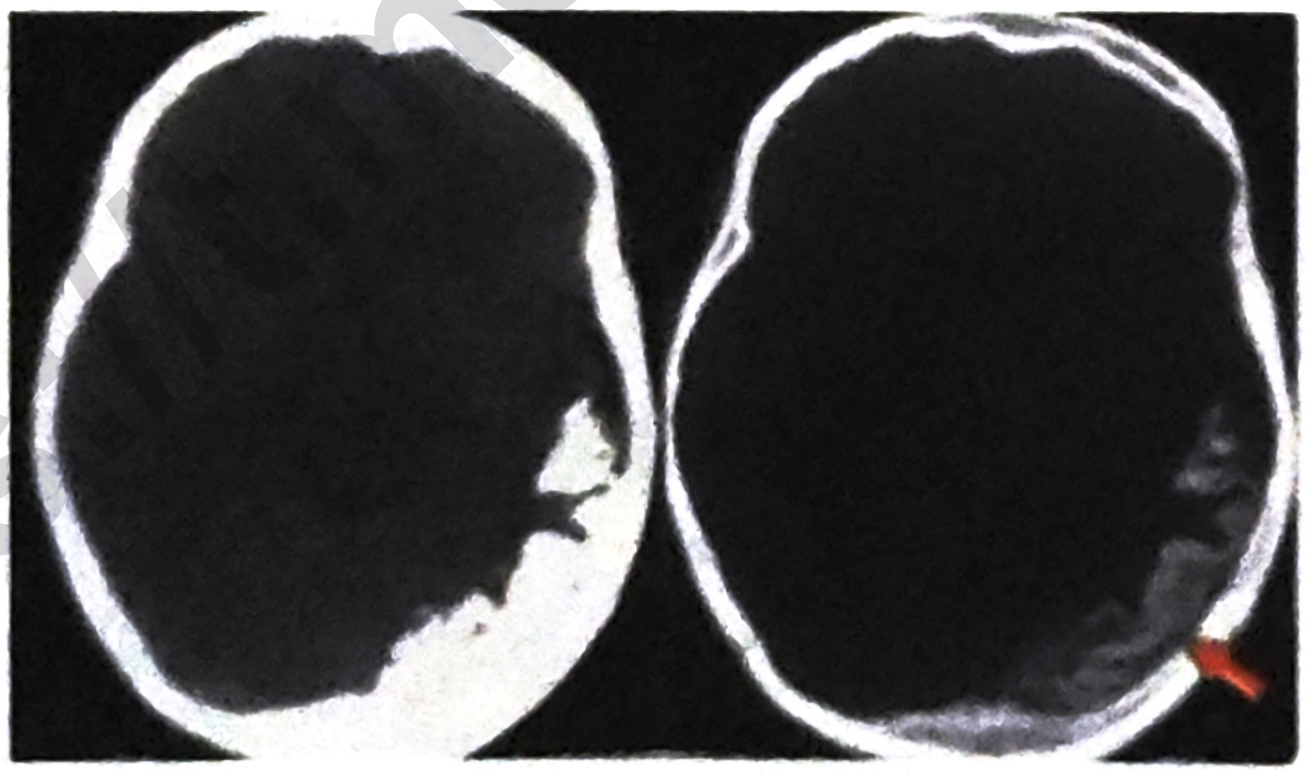

Tram track appearance - Sturge – Weber syndrome

Arachnoid cyst

→ Cystic lesion at the level of sylvian fissure (not commincating with lateral ventricle)

https://t.me/Latestneetpgnotes

PrepLadder

00:24:20

ARACHNOID CYST	EPIDERMOID CYST
→ Common at the region of Sylvian fissure	→ Common at the CP angle
→ CSF containing cyst	→ Keratin containing cyst
→ Suppressed by FLAIR	→ Not completely on suppressed by FLAIR
→ No diffusion restriction	→ Diffusion restriction
→ HIGH ADC value	→ Low ADC value
→ Dark on DWI	→ Bright on DWI

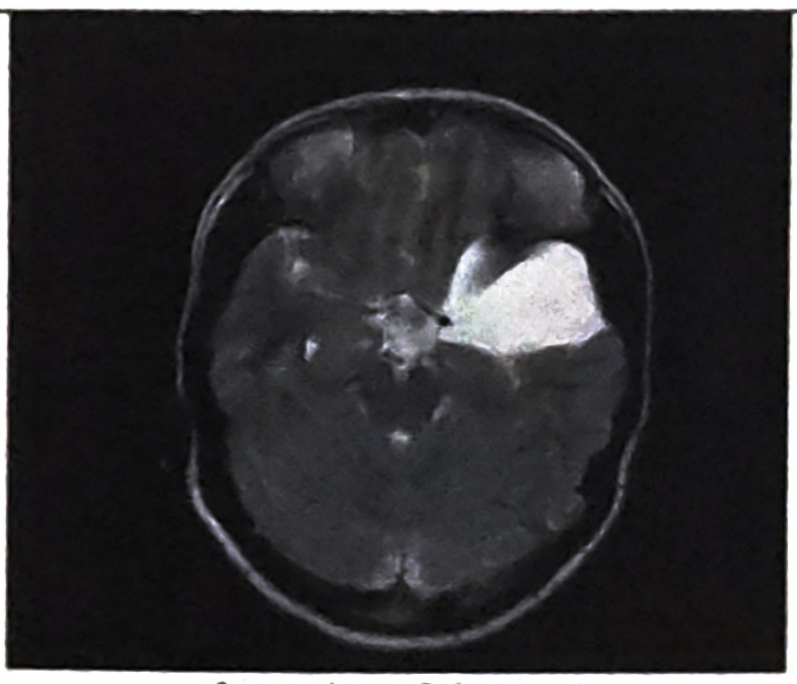

Arachnoid cyst

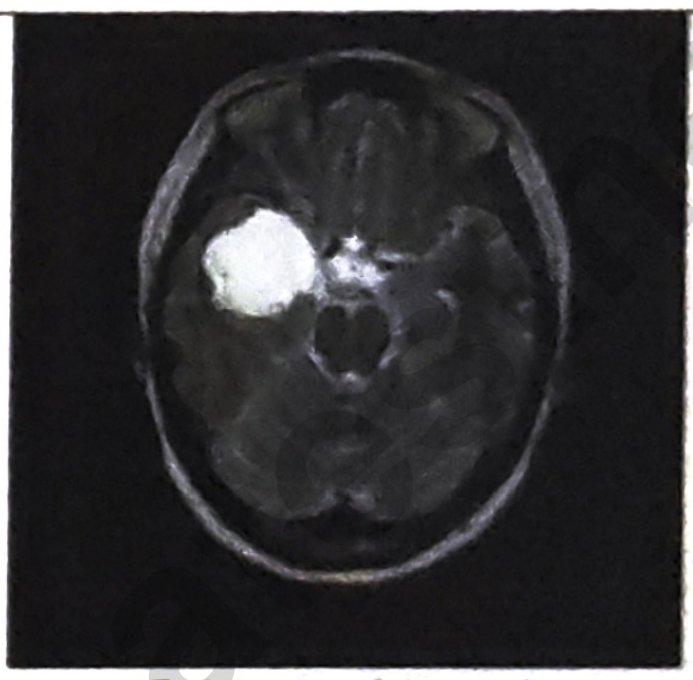

Epidermoid cyst

Signs of ↑ICT

00:27:06

→ Earliest radiological sign of ↑ICT in child – sutural diastases

→ Over a period of time there will be multiple indentation over the skull bones producing silver beaten/ copper beaten skull

→ Earliest radiological sign of ↑ ICT in adult – erosion of dorsum sella

→ Crew cut/ hair on end appearance occurring in cases of thalassemia's and severe hemolytic anemia



https://t.me/Leetpgnotes

PrepLadder

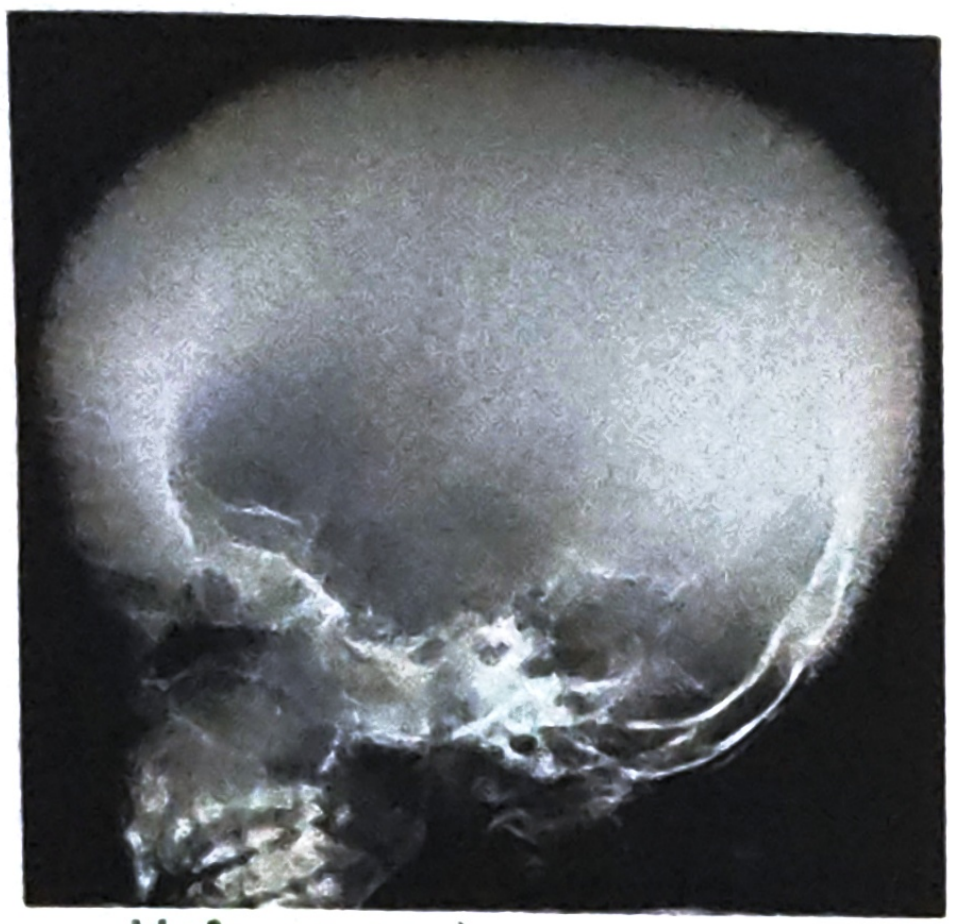
Hair on end appearance

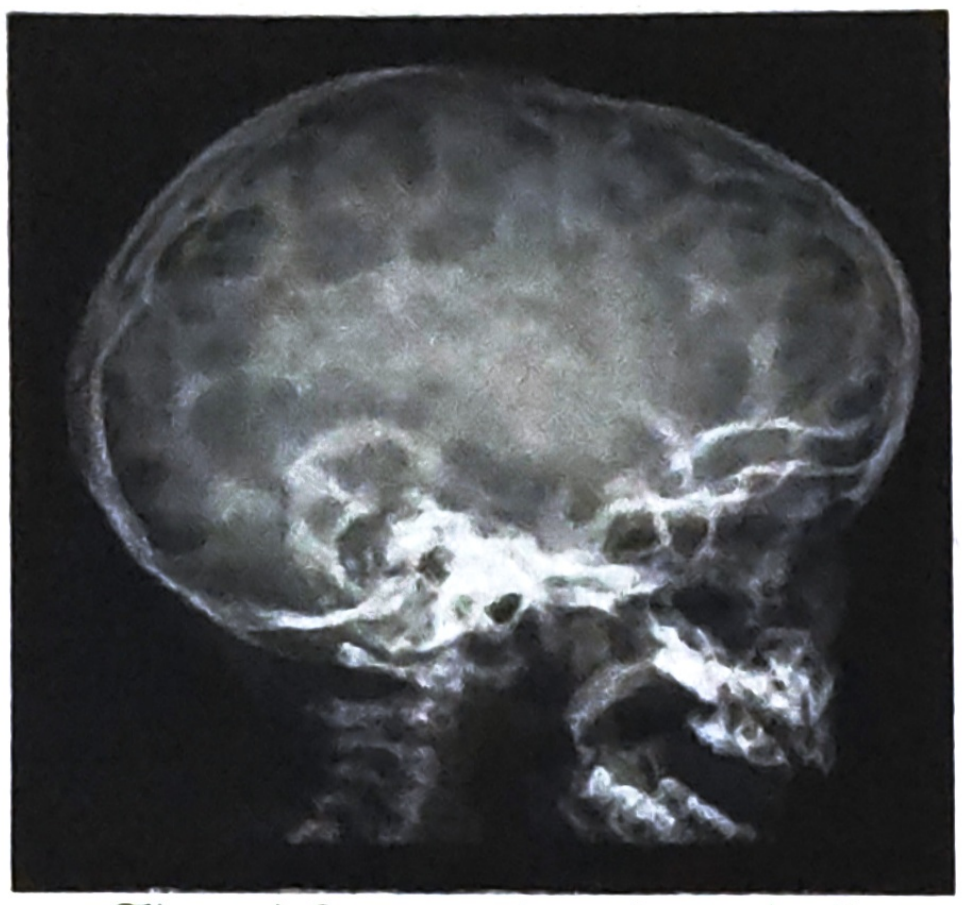
Silver/ Copper beaten skull

Craniopharyngioma

00:29:45

→ Lesion in the sella showing calcification

→ Most common calcifying brain tumor

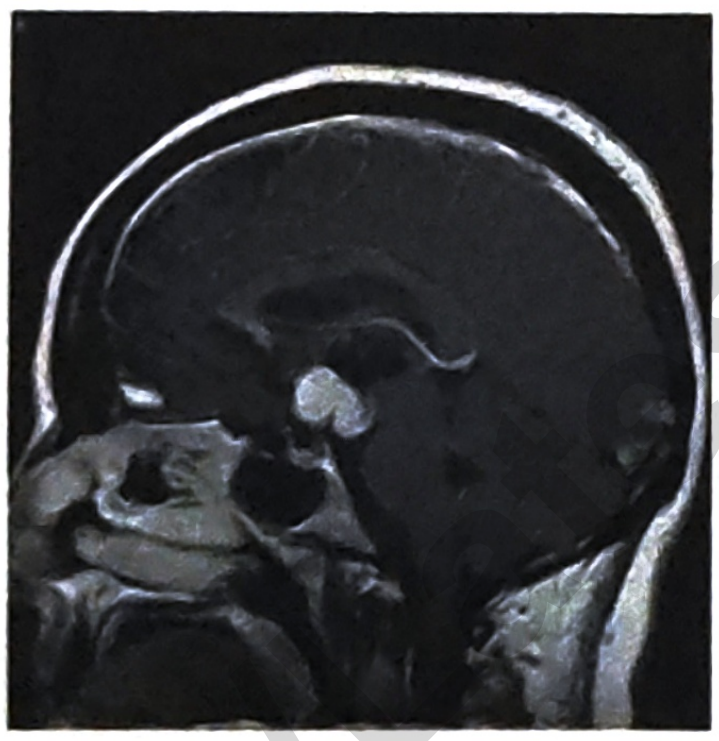

Craniopharyngioma

Pituitary macroadenoma

→ Lesion at the level of the Sella, which is solid and having classic figure of 8 or snowman appearance

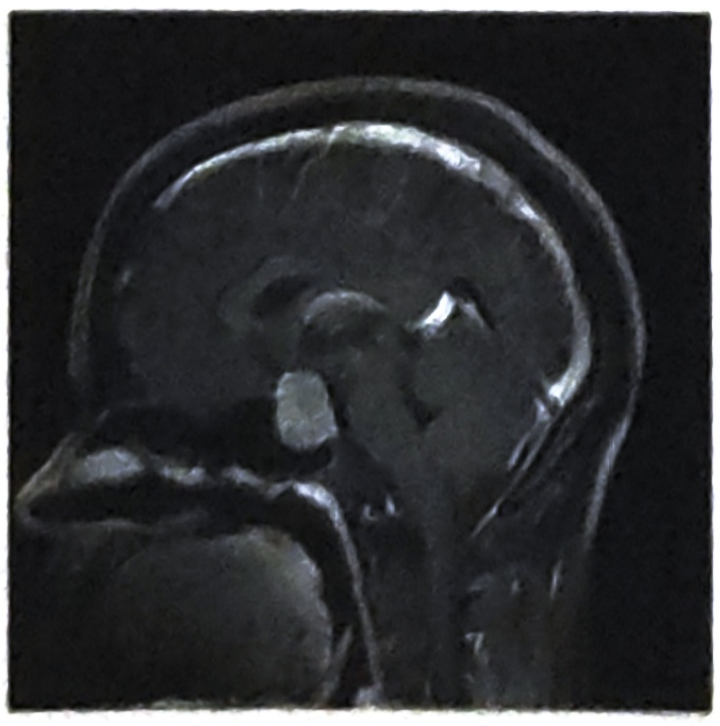

Pituitary macroadenoma

PrepLadder

Hallervorden Spatz disease

00:32:00

- → EYE OF TIGER Appearance
- → Aka 'PKAND' Pantothenate kinase associated neuro degeneration
- → Iron deposition around the Globus, Giving hypointense signal around the Globus pallidus
- → Central hyperintensity is due to gliosis

Hallervorden Spatz disease

https://t.me/Latestpgnotes

PrepLadder

Chapter 24

NEURORADIOLOGY Part 5

Myelography

00:00:22

→ Inject contrast into subarachnoid space to evaluate lesions in and around spinal cord

Intramedullary	Intradural Extramedullary	Extradural
• Tapered appearance Called as "Trouser leg" appearance	• Meniscus sign	• Feathery appearance

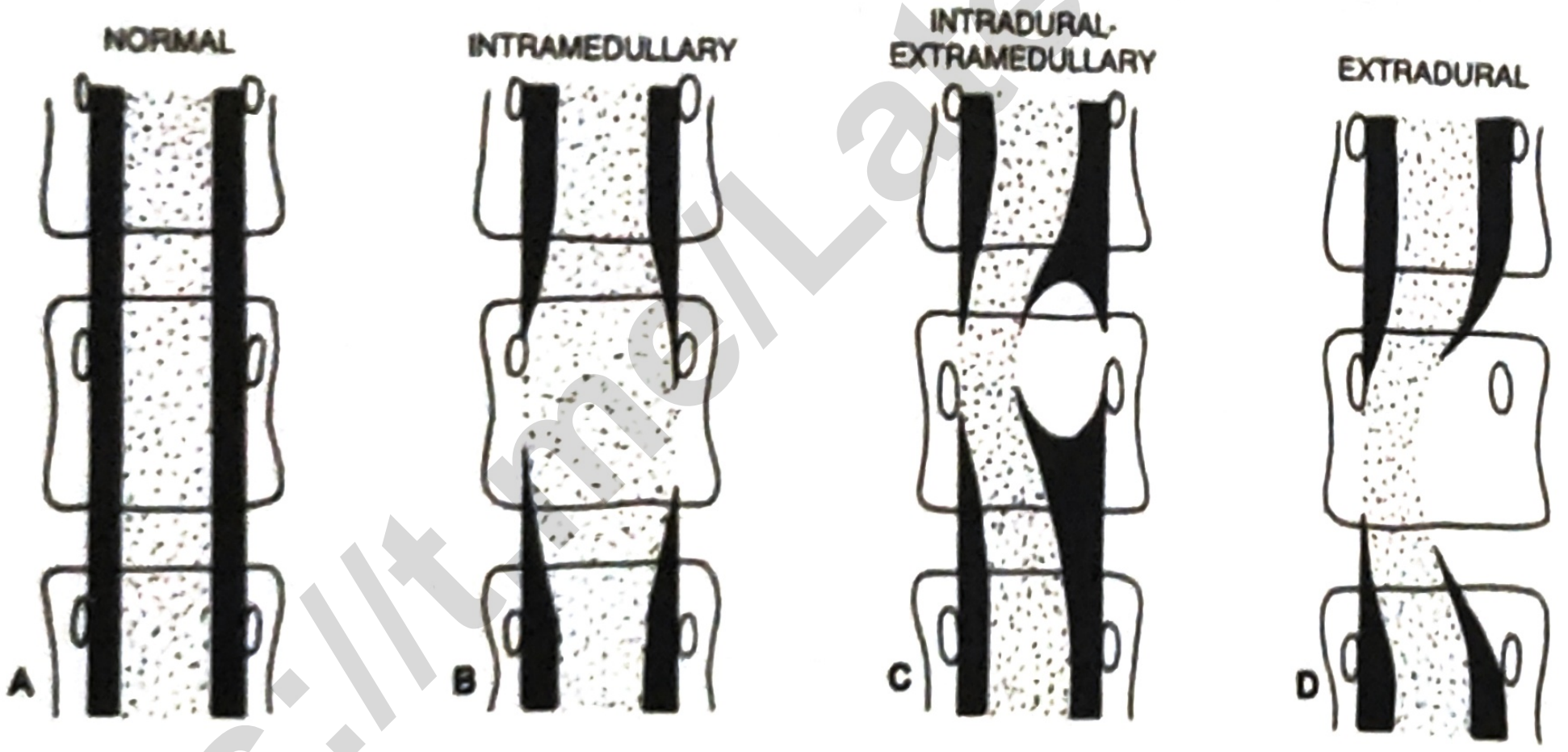

Carotid Body Tumor

00:02:30

→ On CT Scan - Enhancing vascular lesion showing splaying of external and Internal Carotid Arteries

→ Lyre Sign is seen with carotid body tumors (Splaying of external carotid artery and internal carotid artery by a carotid tumor)

→ On MRI - These carotid body tumor / paraganglioma show salt and pepper appearance

https://t.me/Latestneetpgnotes

PrepLadder

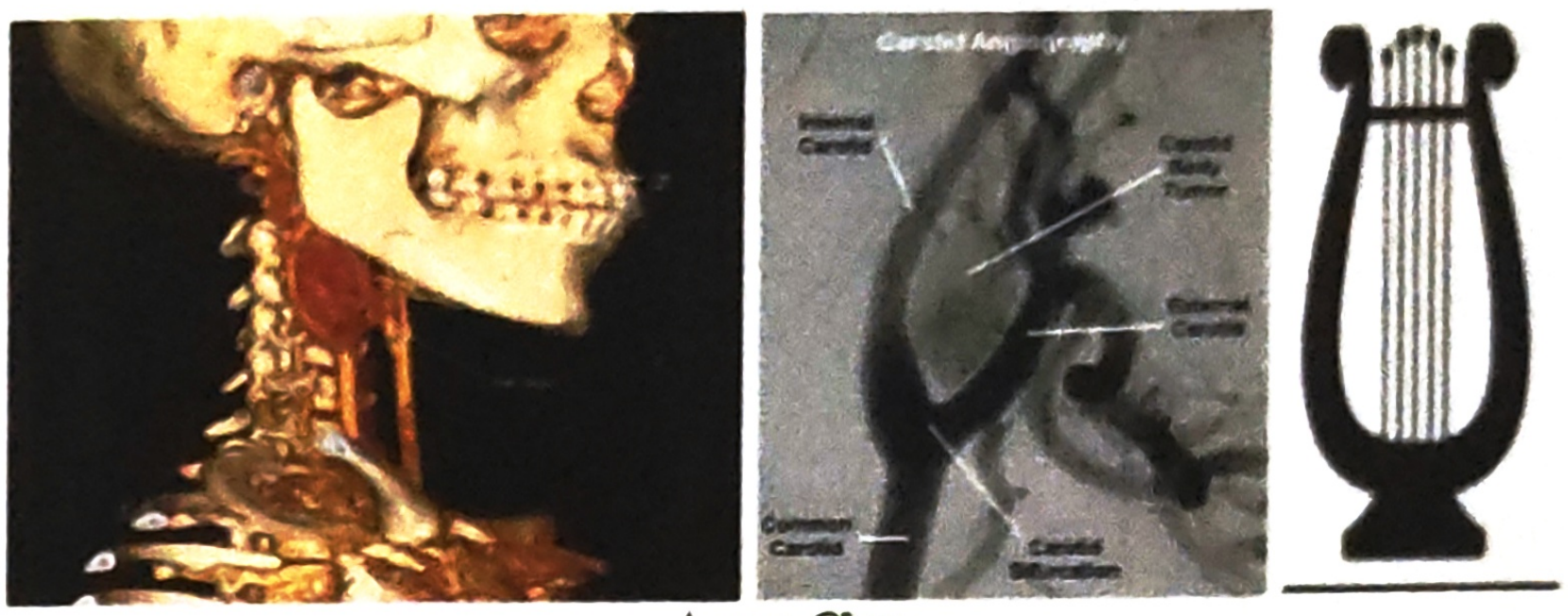

Lyre Sign

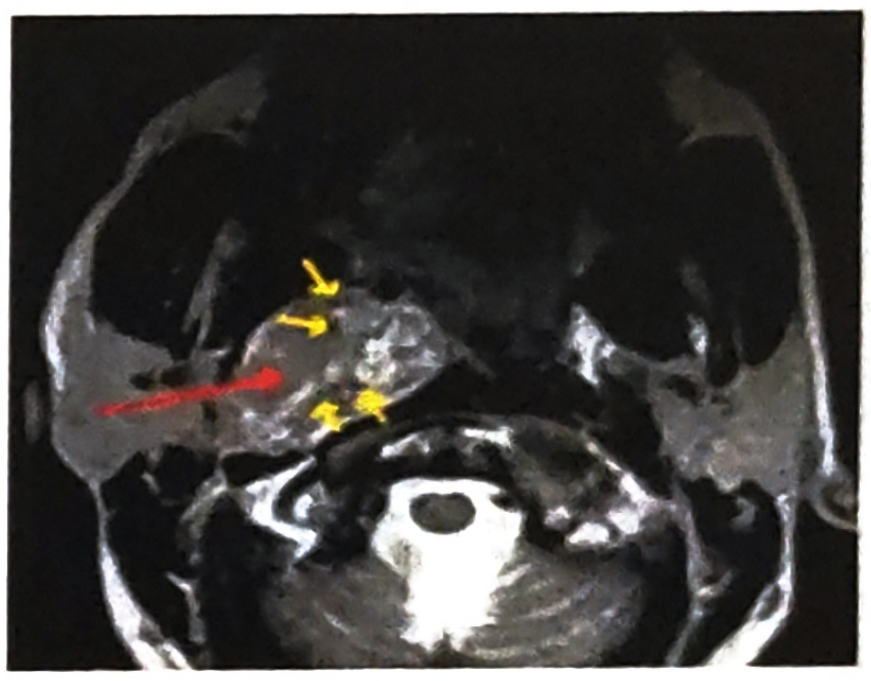

Salt and pepper Appearance

ANENCEPHALY 00:05:30

→ Acrania (absent cranial vault) and loosely arranged brain parenchyma on antenatal scan suggests Anencephaly.

→ Earliest congenital abnormality detected as early as 10th week.

→ FROG EYE Appearance (loosely arranged brain parenchyma with orbits and absent cranial vault)

Anencephaly

CHIARI MALFORMATION 00:06:40

→ BANANA SIGN - Wrapping of cerebellum around brainstem (due to herniation of vermis)

→ LEMON SIGN - Anterior bossing of frontal bone (due to hydrocephalus)

https://t.me/Latestneetpgnotes

PrepLadder

→ Banana and Lemon Sign are features of Chiari Malformation and also 'Spina Bifida'

→ Reasons for spina Bifida to have Lemon sign and Banana sign

- 100% cases of myelomeningocele have association with Chiari malformation

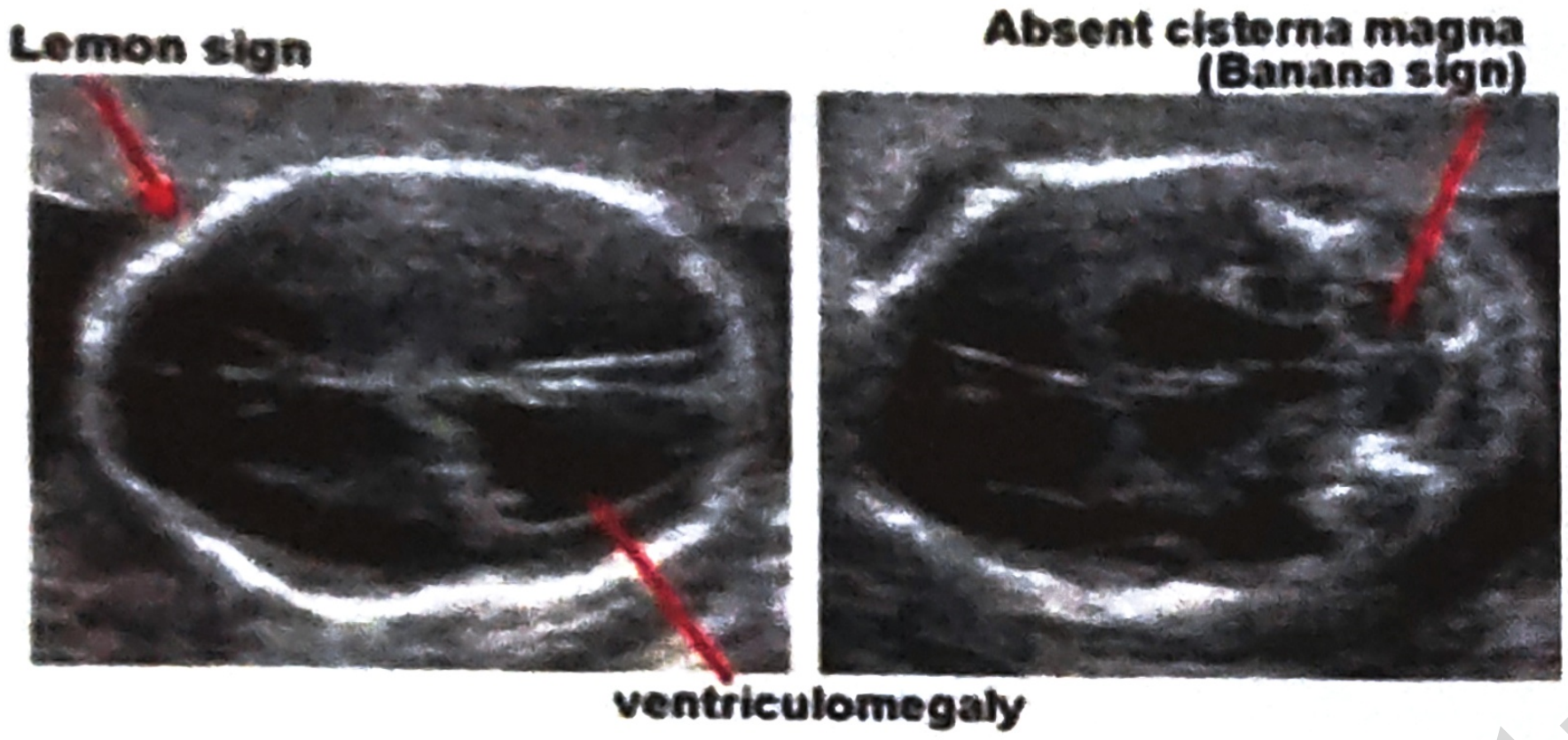

Chiari Malformation

→ Features of Chiari Malformation

- Tectal Beaking
- Vertically placed 4th ventricle
- Lacunar skull

A – Elongated brainstem that extends into the cervical spinal canal B – Downward herniation of the cerebellar tonsils into cervical spinal canal C – Small fourth ventricle D – Aqueductal stenosis E – Tectal beaking F – Large massa intermedia G – Thin corpus callosum	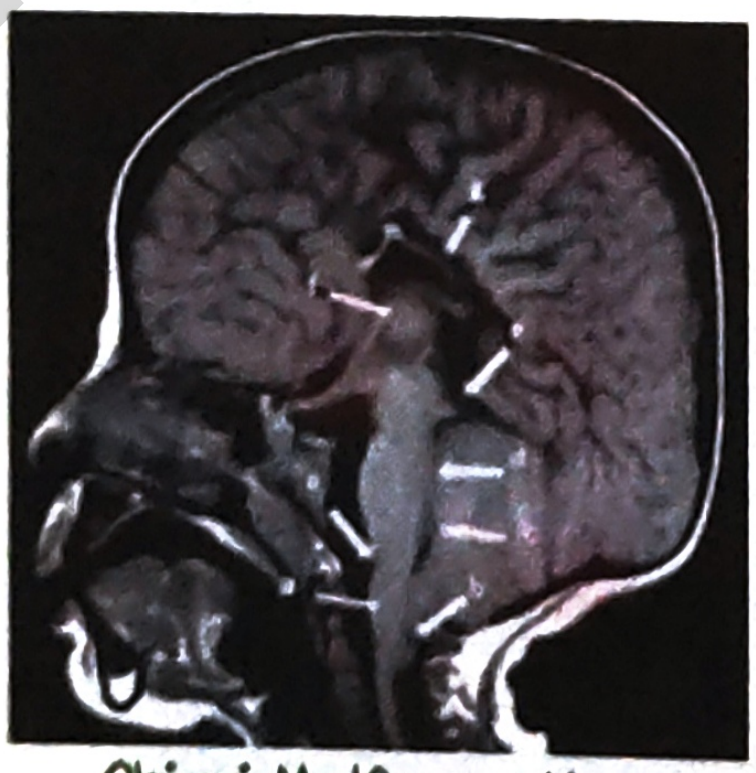 Chiari Malformation

DANDY WALKER MALFORMATION 00:10:46

→ Agenesis of cerebellar vermis which causes the fourth ventricle to communicate with cisterna magna is a feature of Dandy walker malformation

- Mega cisterna magna
- Large posterior fossa - Dandy Walker

https://t.me/Latestneetpgnotes

PrepLadder

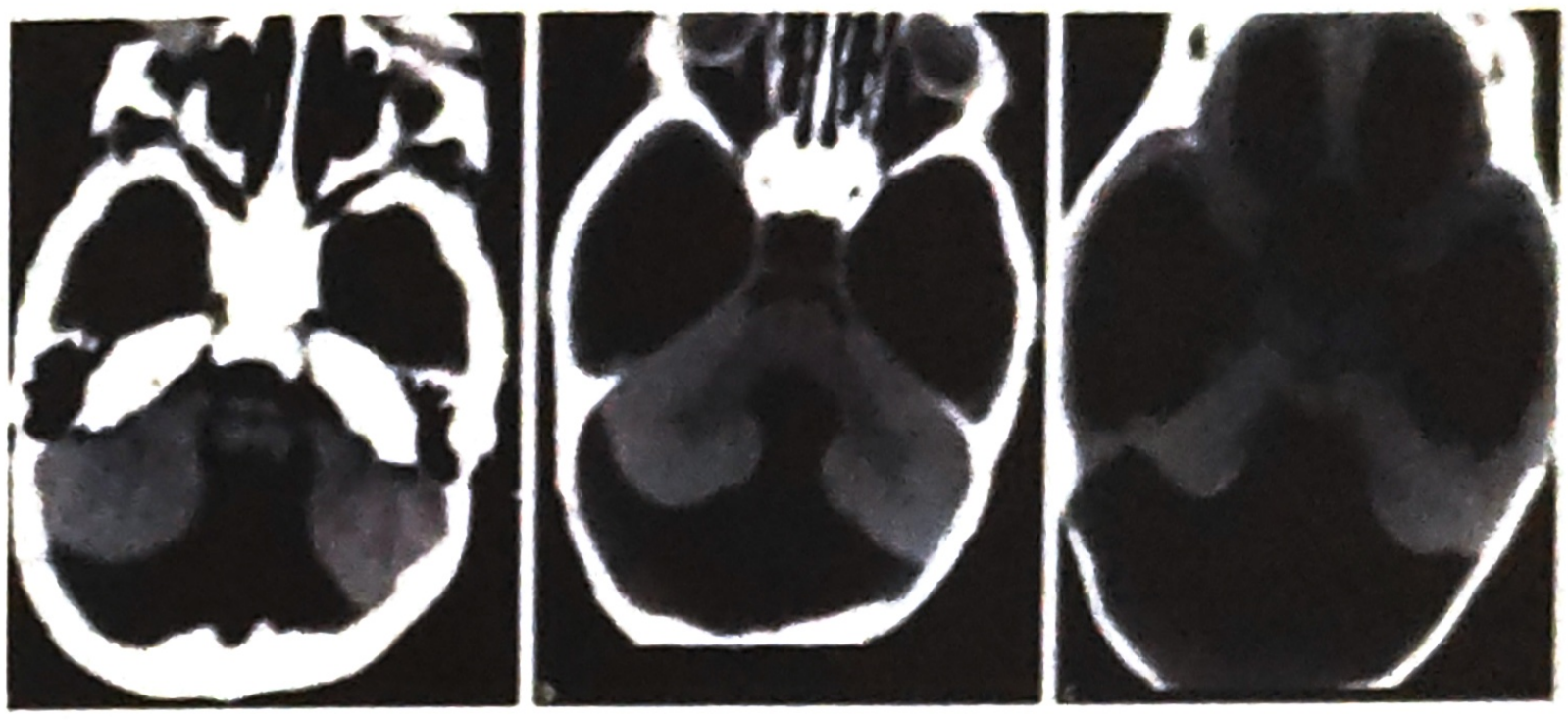

Mega Cisterna Magna

Note:

- → Small posterior fossa - Chiari malformation
- → Large posterior fossa - Dandy Walker
- → Spinal metastasis - Involvement of vertebral body and sparring of disc spaces.
- → Pott's spine - Paradiscal in nature (Involvement of disc and adjacent end plates)

Blow out fracture

- → Aka tear drop fracture
- → Contents of orbit hanging out into the maxillary sinus
- → Best view for orbital floor visualization - WATER'S view

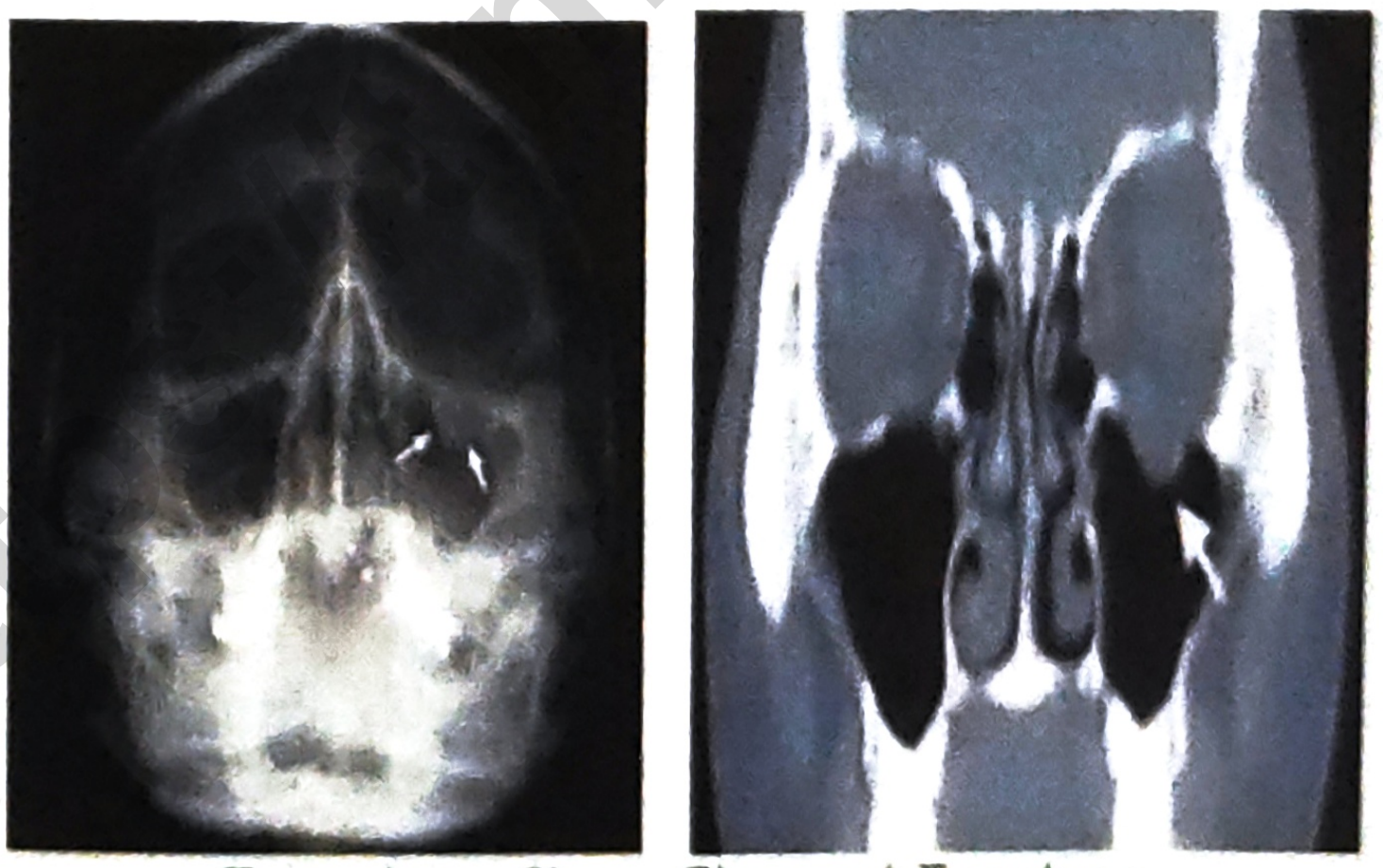

Tear drop Sign - Blow out Fracture

https://t.me/Latestpgnotes

PrepLadder

→ Agyria

- Absence of gyrations in the brain
- Aka Lissencephaly
- Figure of 8 appearance (brain looks smooth and soft)

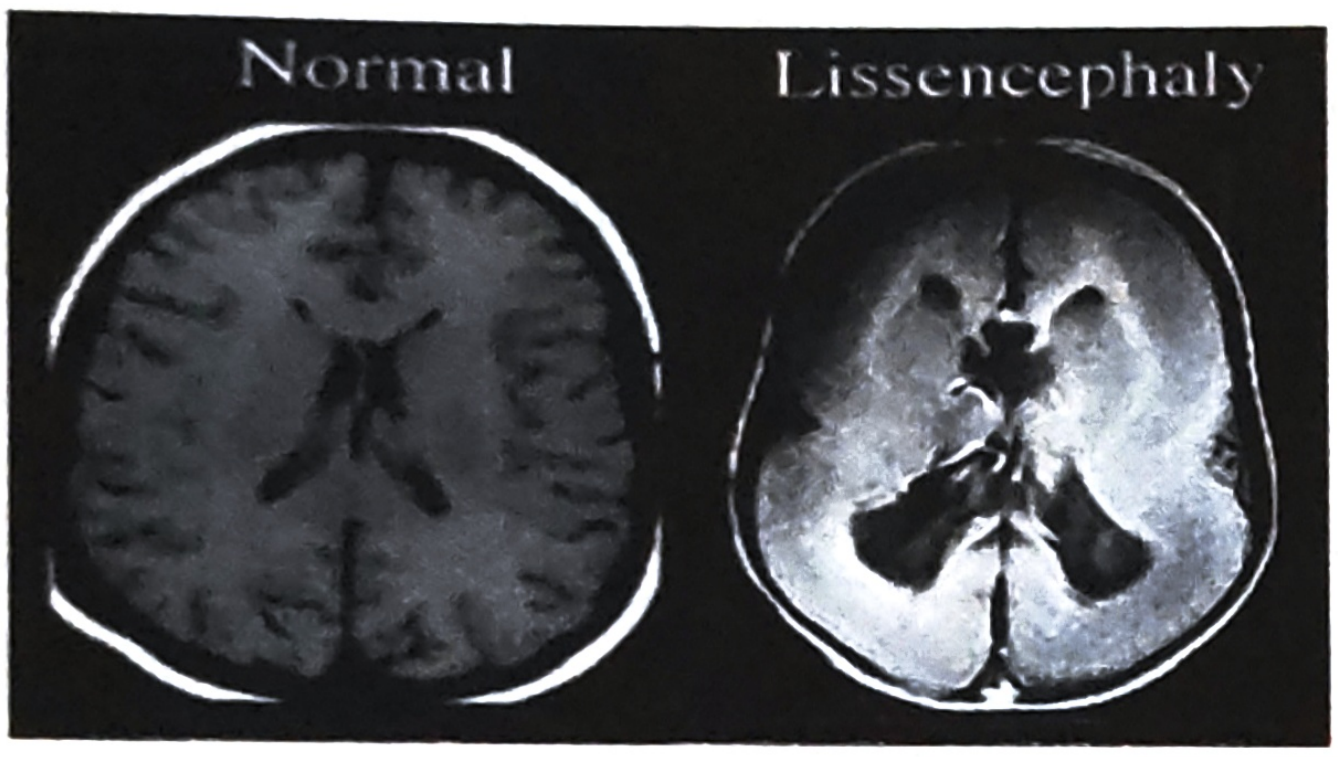

Figure of 8 appearance

→ Pachygyria - Thick and few gyri

→ Polymicrogyria - Thin, small and multiple gyri

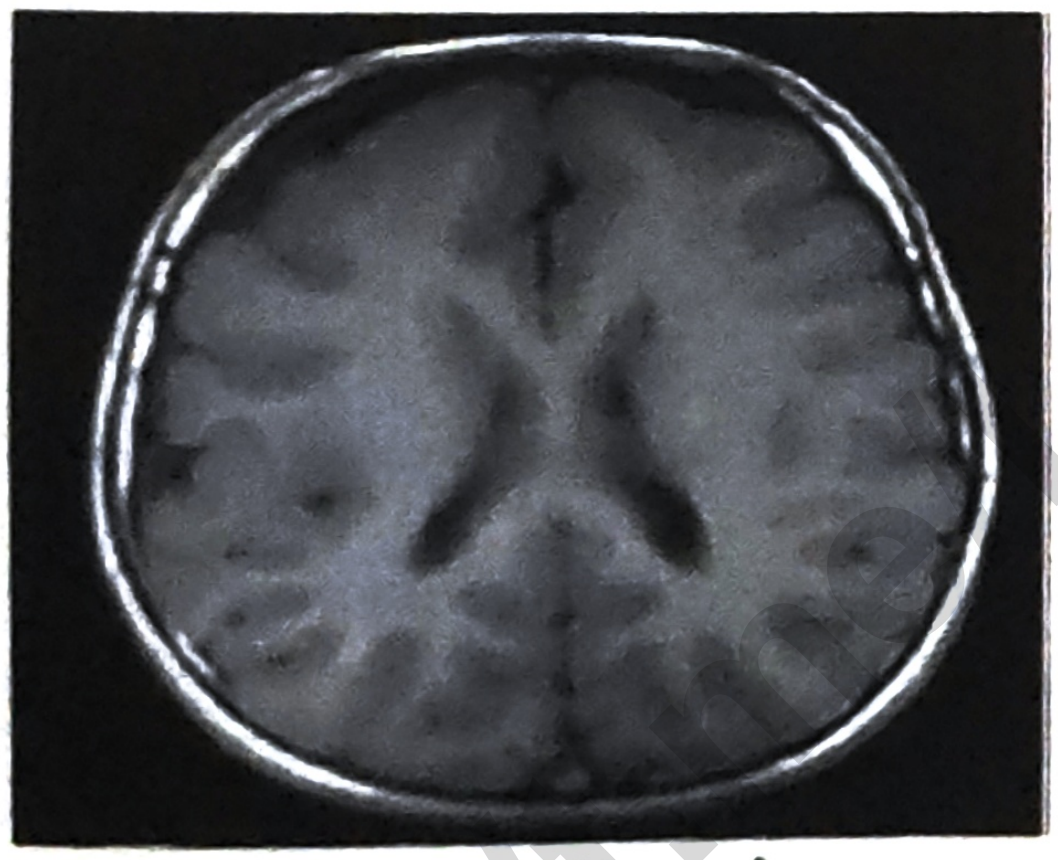

Pachygyria

Polymicrogyria

→ Heterotopia - Heterotopic tissue of grey matter present within white matter of brain

→ Holoprosencephaly

- Single lateral ventricle giving BOOMERANG ventricle or Pancake appearance
- PATAU Syndrome has Holoprosencephaly (midline defect)

PrepLadder

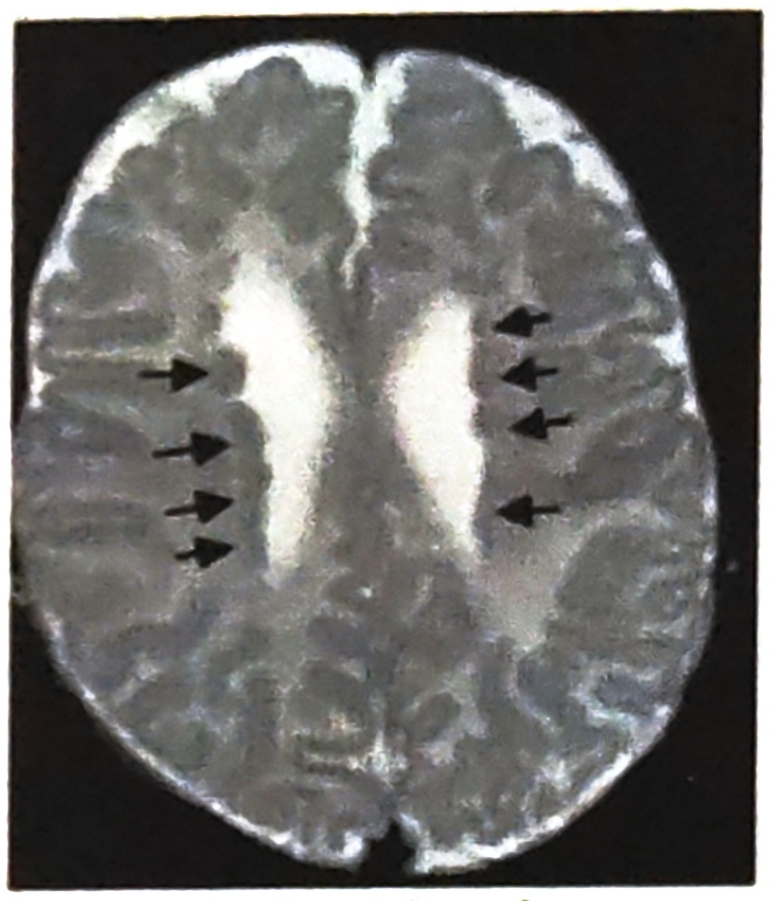

Heterotropia

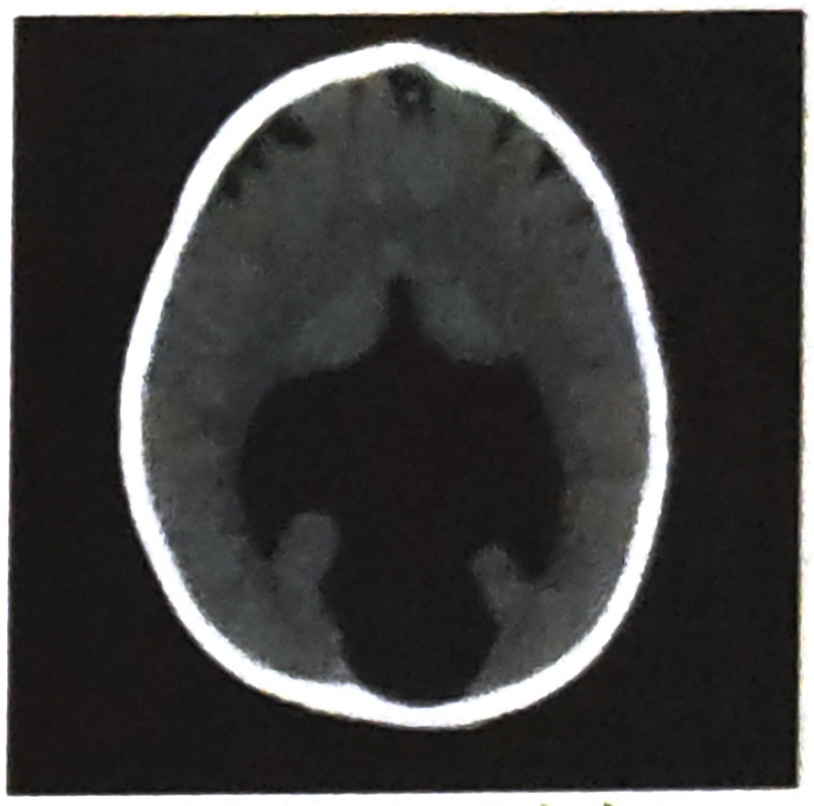

Holoprosencephaly

AV MALFORMATION

00:17:55

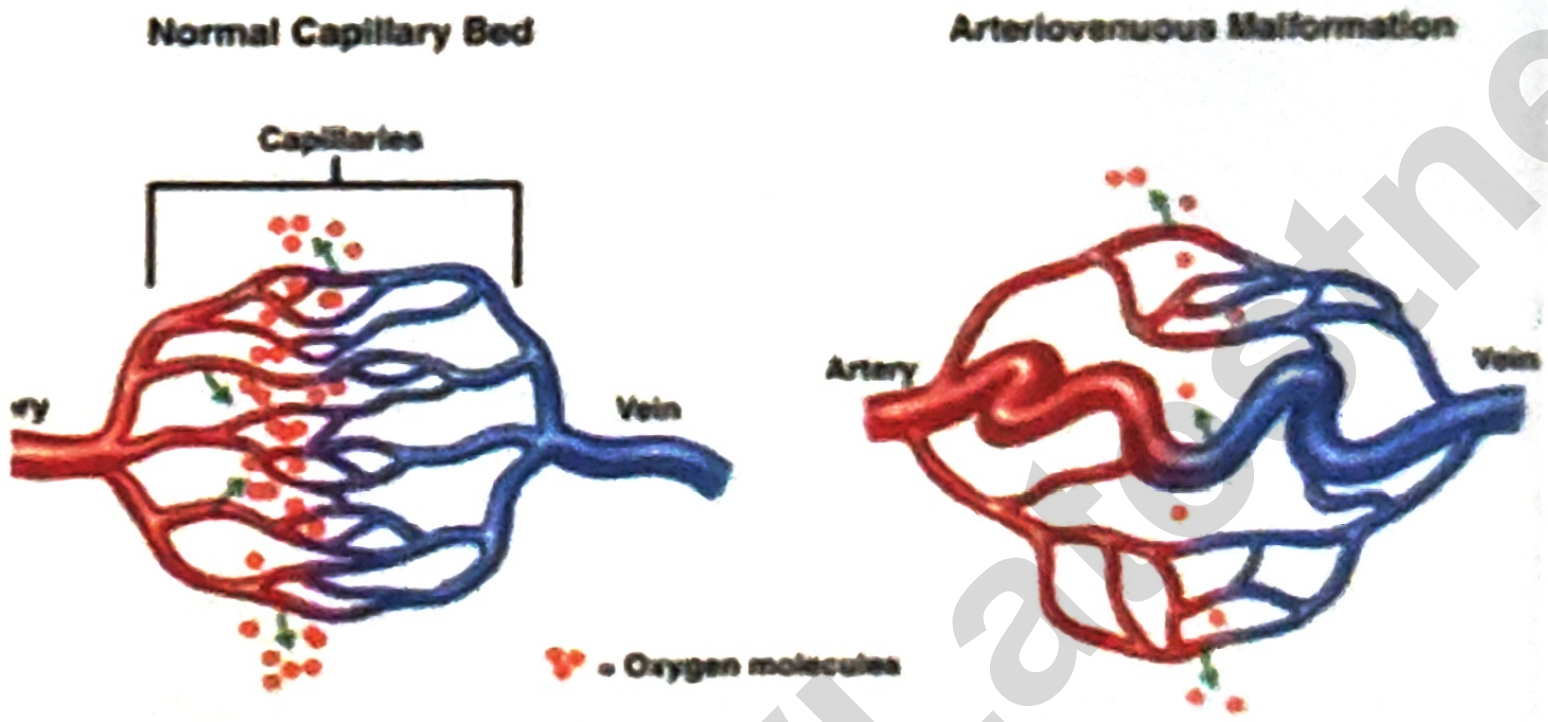

→ True AV malformation
- Has Central nidus
- Has definite Feeding artery

→ Cavernous angioma - Popcorn appearance on MRI Brain

→ Venous malformation (venous Angioma) - Caput medusa / spoke wheel appearance

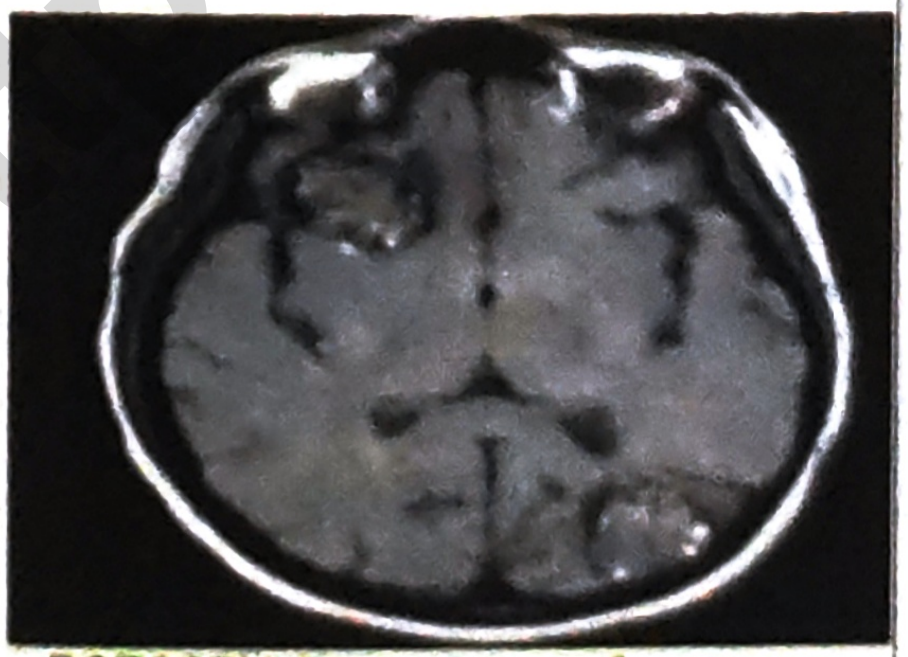

POPCORN Appearance -Cavernous Angioma

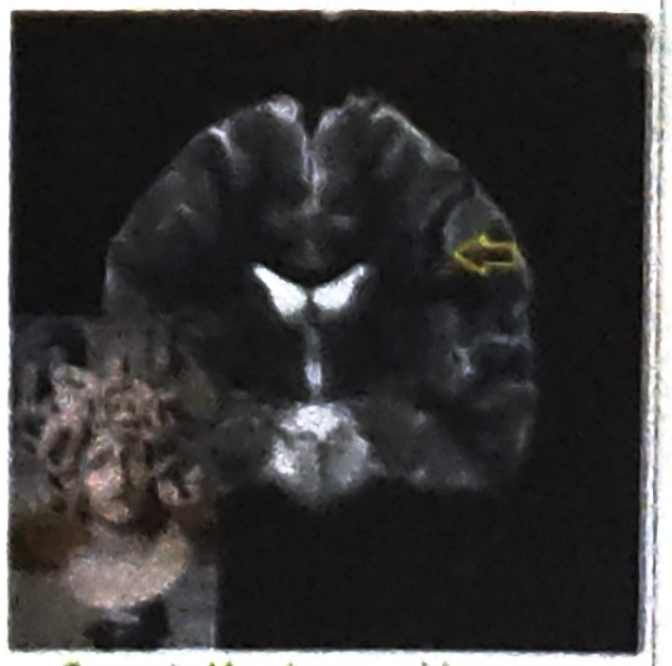

Caput Medusa - Venous angioma

https://t.me/Latestneetpgnotes

PrepLadder

Soap Bubble appearance on

→ MRI

- Brain → Cryptococcus neoformans
- On /around knee → Giant cell tumor or osteoclastoma
- Of mandible → Adamantinoma
- Of abdominal radiograph → Meconium ileus
- Of antenatal scan → Multicystic dysplastic kidney

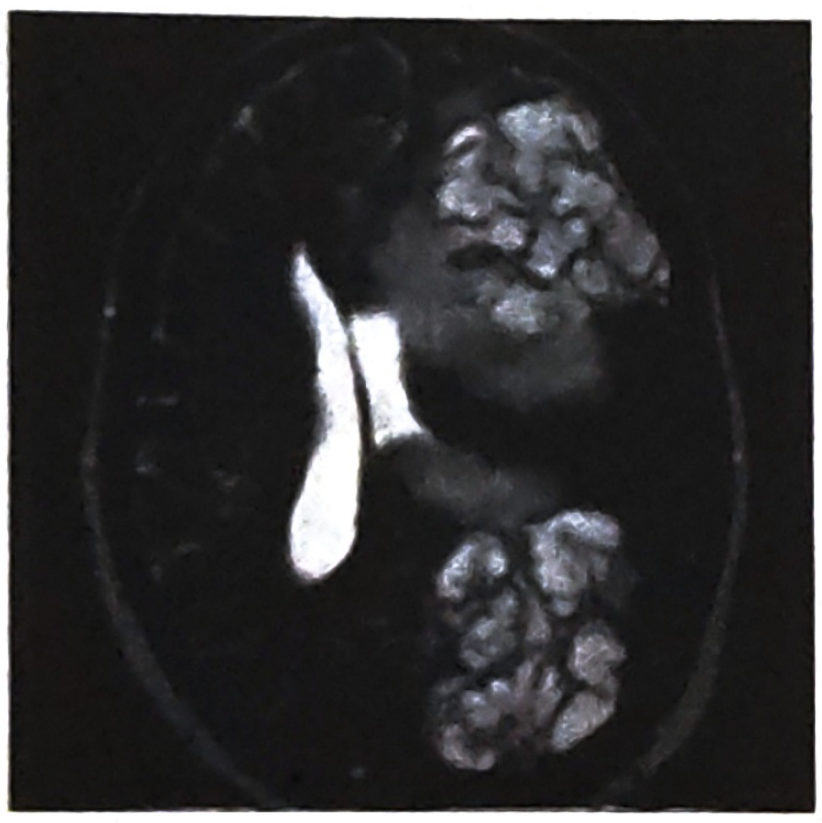

Soap Bubble Appearance Cryptococcus

Retinoblastoma 00:24:24

→ Intraorbital calcification

→ B/L Retinoblastoma + Pineal gland tumor - Trilateral retinoblastoma

→ B/L Retinoblastoma + Pineal gland tumor (Trilateral retinoblastoma) + Suprasellar mass - quadrilateral retinoblastoma

→ 2nd MC cancer in retinoblastoma- Osteosarcoma

→ Mutation of RB Gene on chromosome 13

Percutaneous Vertebroplasty

https://t.me/Latestneetpgnotes

PrepLadder

Percutaneous Vertebroplasty

- → Done to relieve pain by injecting cement in posterior eminence of vertebral body in osteoporotic fractures.
- → Cement used - PMMA, polymethyl methacrylate

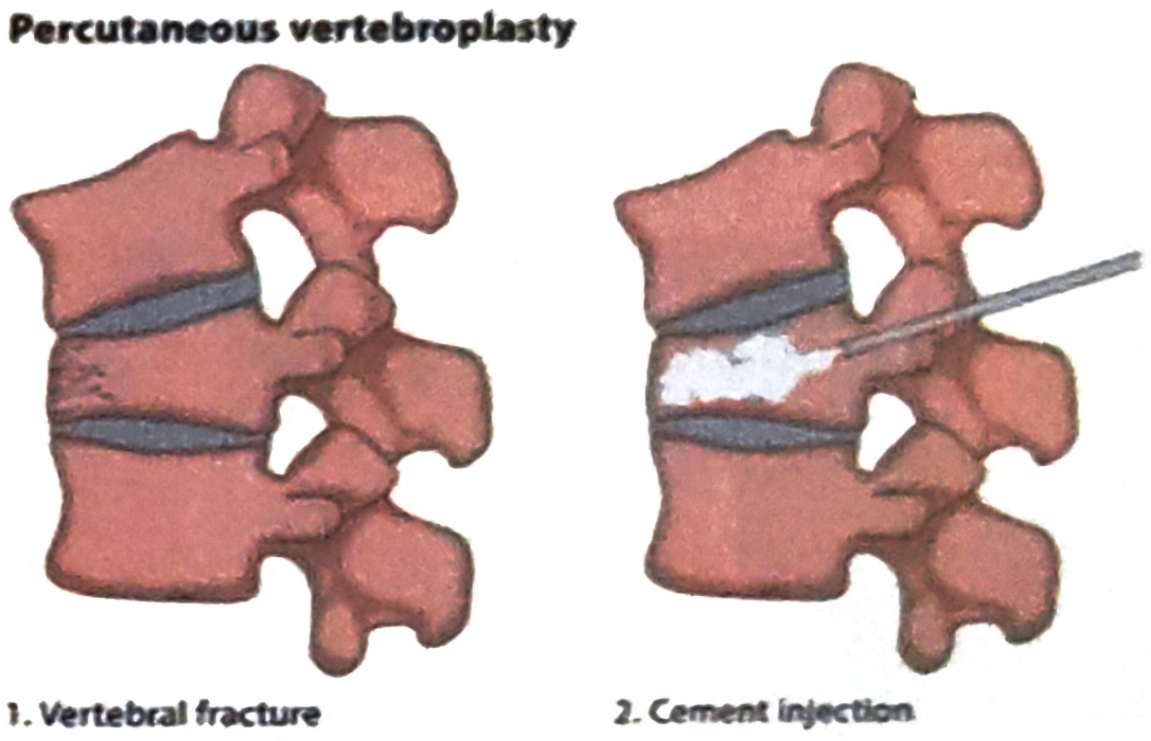

Mesencephalo - oculo - facial angiomatosis

- → Aka WYBURN - MASON syndrome / retinocephalic vascular malformation
  - Pulsatile Exophthalmos
  - Seizure
  - PORT WINE STAIN

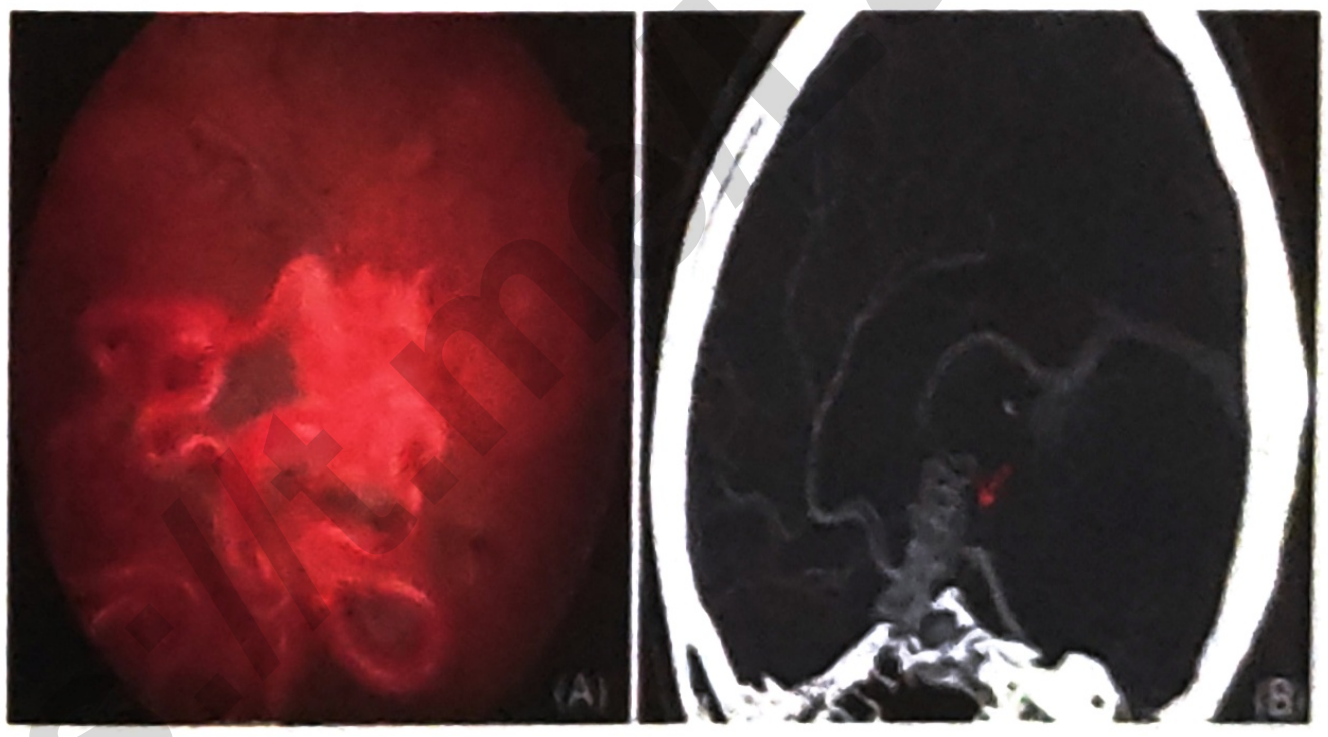

WYBURN - MASON Syndrome

Pulsatile exophthalmos

- → Also seen in Carotic cavernous fistula
- → In carotic cavernous fistula, after basal skull fracture - Communication between

https://t.me/latestneetpgnotes

PrepLadder

Carotid artery, internal cranial artery and the adjacent cavernous sinus

↓

back flow of blood from internal carotid into ophthalmic veins causing pulsatile exophthalmos along with prominent superior ophthalmic vein

SCHIZENCEPHALY

→ Cystic lesion at sylvian fissures communicating with lateral ventricles

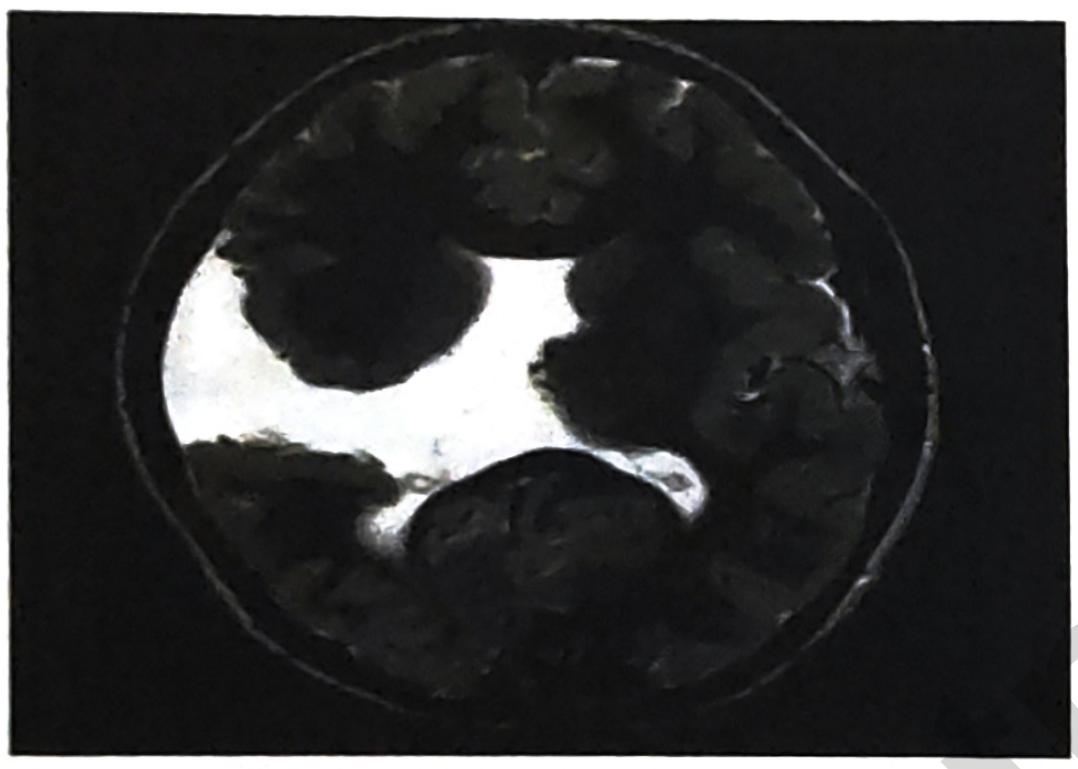

Schizencephaly - T2 weighted image

Note:

→ Cystic lesion at sylvian fissure communicating with lateral ventricle - Schizencephaly

→ Cystic lesion at sylvian fissure not communicating with the lateral ventricle – Arachnoid

Growing skull fractures 00:30:38

→ Entrapment of leptomeninges after skull fracture forming - LEPTOMENINGEAL CYST

Note:

- Tram track calcifications → Sturge Weber
- Starry sky on NCCT Brain → Neurocysticercosis
- Diffuse nodular Calcification → Toxoplasmosis
- Bracket calcification → Lipoma of corpus callosum

https://t.me/Latestneetpgnotes

PrepLadder

- Cotton wool skull → Paget's disease
- Salt and pepper skull → Hyperparathyroidism
- Lacunar skull → Chiari Malformation
- Pepper pot skull → Hyperparathyroidism
- Raindrop skull → Multiple myeloma
- Geographical skull → Eosinophilic granuloma

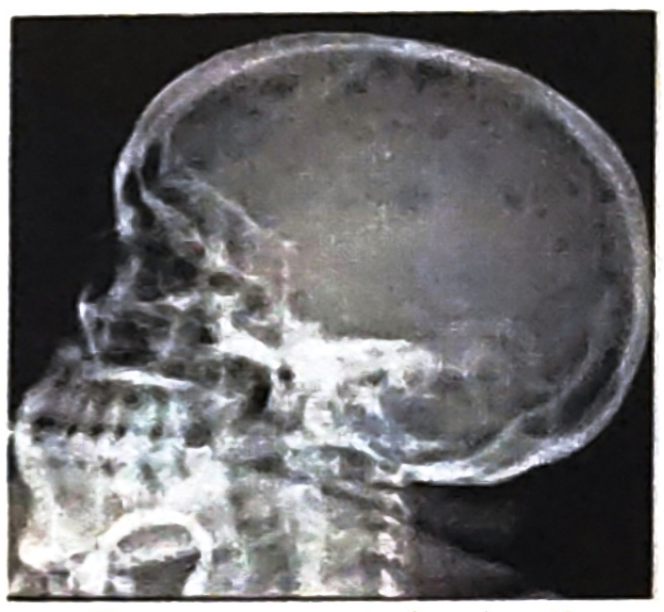 Pepper pot skull Hyperparathyroidism	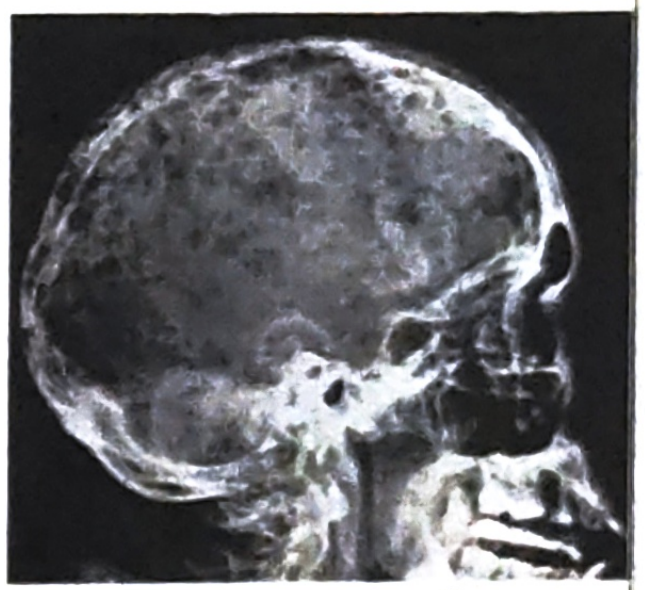 Raindrop skull → Multiple myeloma	 Geographical skull → Eosinophilic granuloma

https://t.me/Latestthepgnotes

PrepLadder

Radiological features in various skull pathologies

Cotton wool skull
Feature of paget's disease

Geographical skull
- Feature of eosinophilic granuloma

Rain drop skull
- Varying size, scattered lucency
- Feature of multiple myeloma

Pepper pot skull /Salt and pepper skull
- Uniform small Lucencies and appears like pepper pot
- Feature of hyperparathyroidism

Crew out / hair on end appearance
- Feature of thalassemia

Brain Hemorrhages

Subdural Hematoma
- Concavo convex or crescentic or banana shaped
- Cross suture lines
- Happens d/t rupture of bridging veins

Epidural Hematoma (EDH)
- Biconvex / lentiform / lemon shaped appearance seen
- Due to rupture of middle meningeal artery

Sub arachnoid hemorrhage
Shows hyper density in
- Sulcal spaces
- Sylvian fissure
- Basal cisterns
- Anterior inter hemispheric fissure

https://t.me/Latestneetpgnotes

Chapter 25

HEPATOBILIARY RADIOLOGY

Couinaud's segments of liver 00:00:20

→has 8 segments (I-VIII)

- Middle hepatic vein - divides liver into right & left halves
- Right hepatic vein - divides right lobe into Anterior & Posterior halves
- Left hepatic vein - divides left lobe into medial & lateral halves
- Portal vein - runs transversely dividing liver into 8 segment

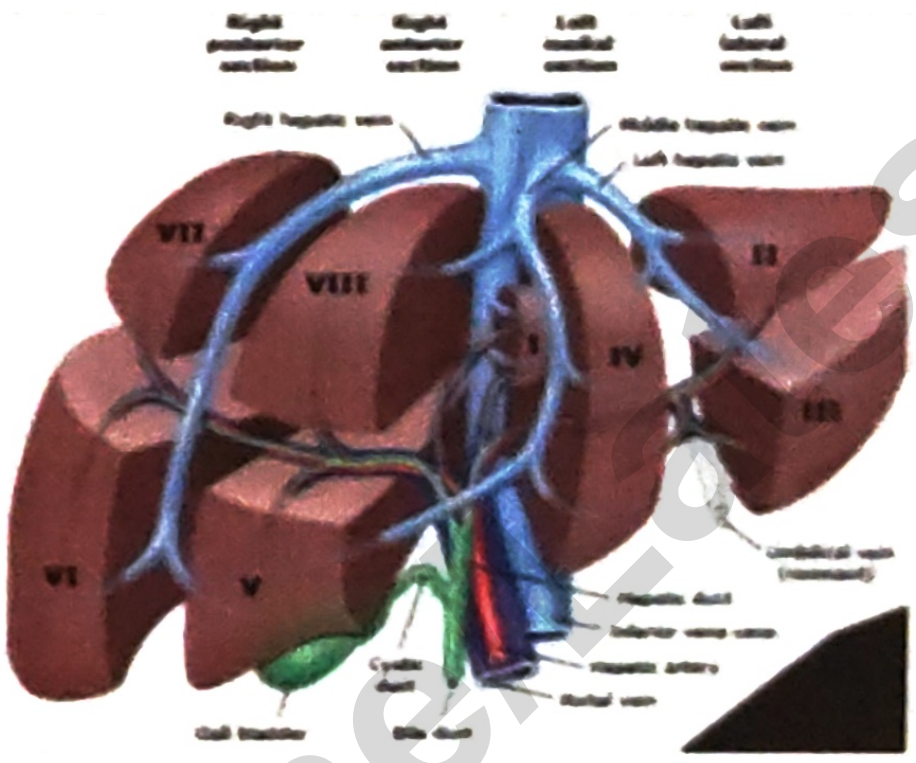

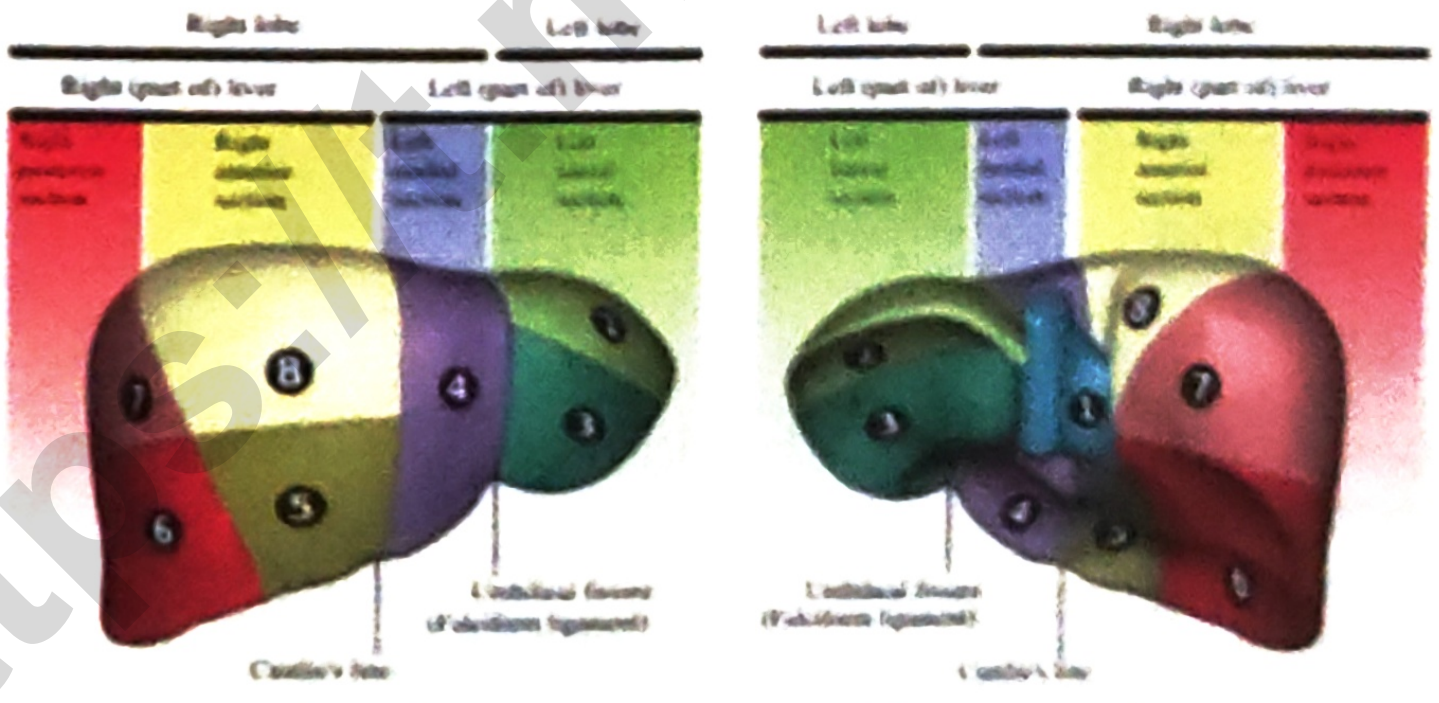

Anterior view Posterior view

Note:

→MHV, PV & Cantlie line lie in the same plane

→Falciform ligament & LHV lie in the same plane

https://t.me/neetpgnotes

PrepLadder

Hemangioma

00:05:16

→ M/C benign lesion of the liver

→ Radiological finding

- On USG → hyperechoic area
- On CECT → Delayed centripetal enhancement after initial peripheral nodular enhancement
- On T2W - MRI → light bulb appearance

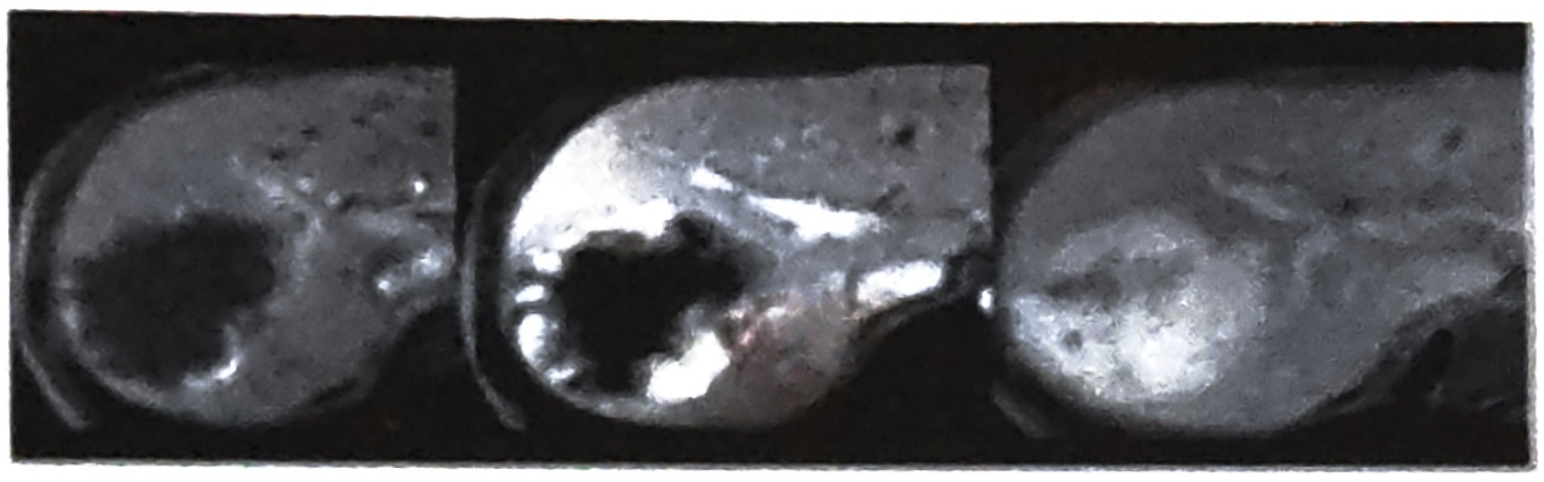

Hemangioma showing Delayed centripetal enhancement after initial peripheral nodular enhancement

Few important Enhancement patterns

→ Hemangioma → Delayed centripetal enhancement

→ HCC → derives major blood supply from Hepatic artery

→ HCC → Has early arterial enhancement with rapid washout

→ Meningioma → Early enhancement, delayed washout

→ Mother in law" sign

Light bulb appearance

→ On MRI Liver - Hemangioma

→ On MRI Abdomen - Pheochromocytoma

→ On DW-MRI Brain - Acute infarct

→ On Shoulder Radiograph - Posterior dislocation of shoulder

Radiological findings of hydatid cyst

00:07:15

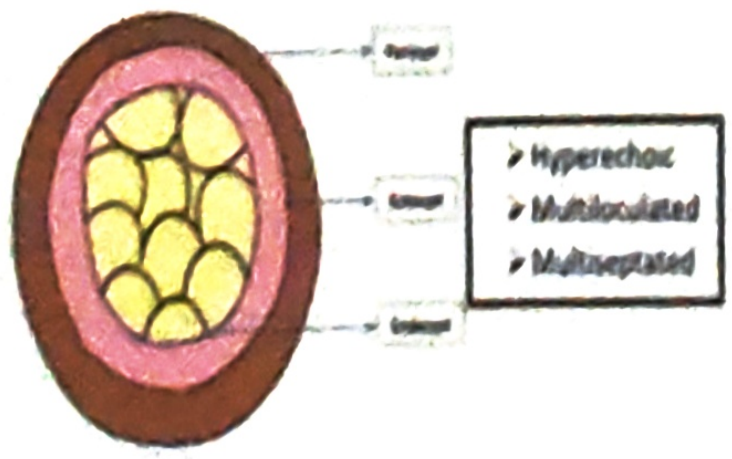

Honey comb appearance
Or Rosette appearance

https://t.me/Latestneetpgnotes

Signs of Hydatid Cyst

→ Honey comb appearance or Rosette appearance
→ Meniscus sign
→ Cumbo sign
→ Water lily sign / Camalote sign/ floating membrane sign
→ Serpent sign
→ Sunrise / Sunset sign
→ Hydatid Sand Sign

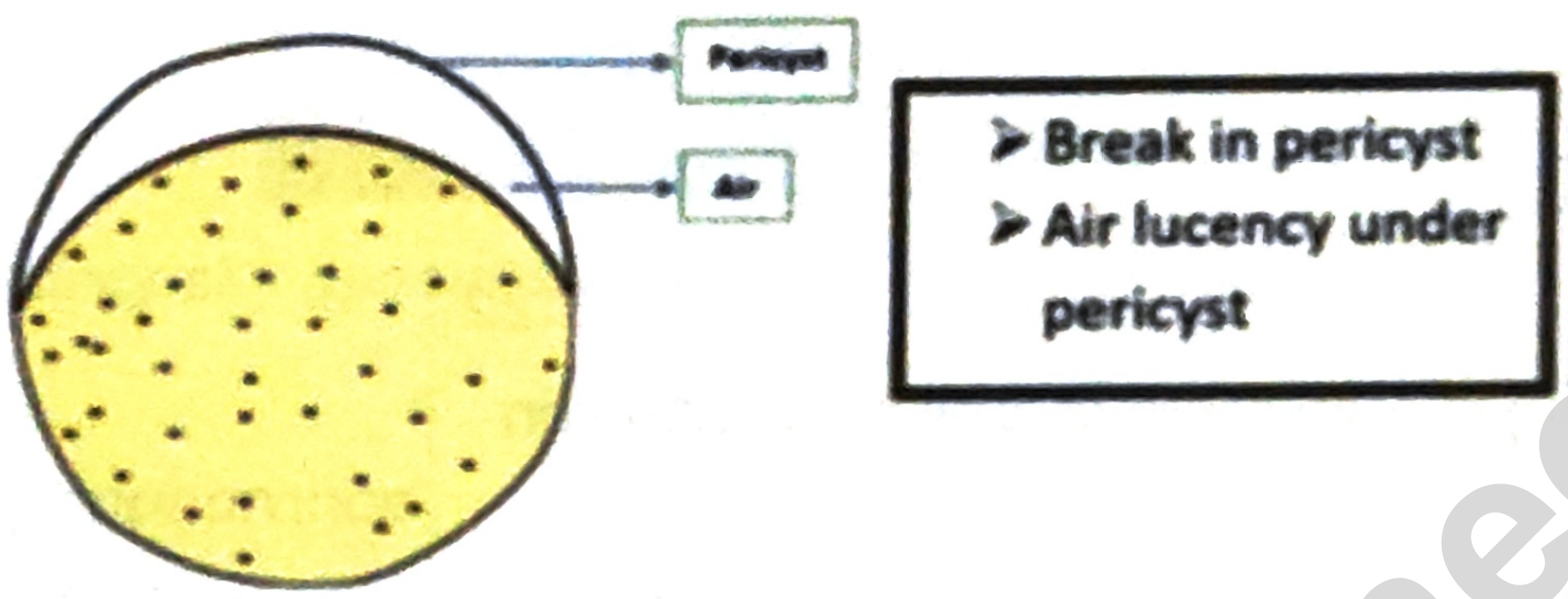

Meniscus sign

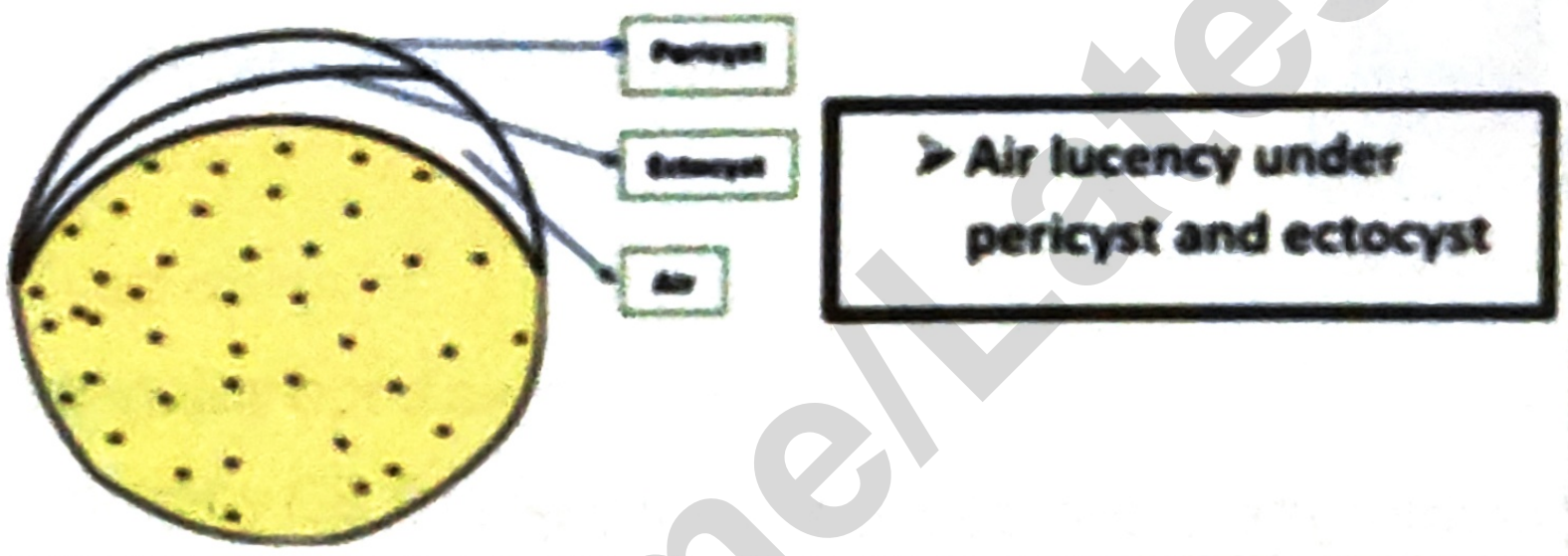

Cumbo sign



Water lily sign

https://t.me/Latestneetpgnotes

PrepLadder

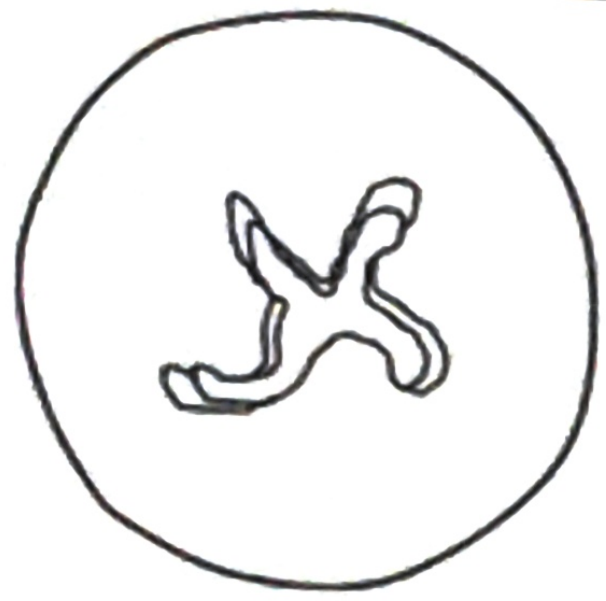 Serpent sign → Fluid lost and membrane floating	Sunrise/ Sunset sign → Membrane settle down	 Hydatid Sand sign → Cystic area with Protoscolex of echinococcus

Caroli's disease

00:09:22

- →It is a type V choledochal cyst - Intrahepatic biliary dilatation
- →"Shows central dot sign"

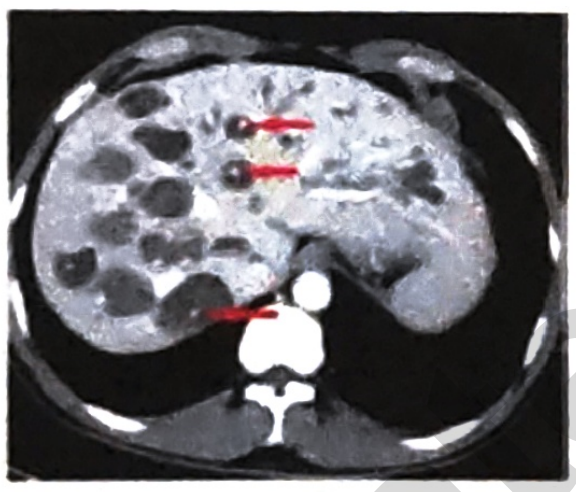

Caroli's disease

Focal nodular hyperplasia

- →Has increased number of hepatocytes, bile ducts & Kupffer cells
- →On imaging, shows Stellate scar appearance
- →On TC^{99m} - sulphur colloid shows hot uptake (because of increased Kupffer cells)

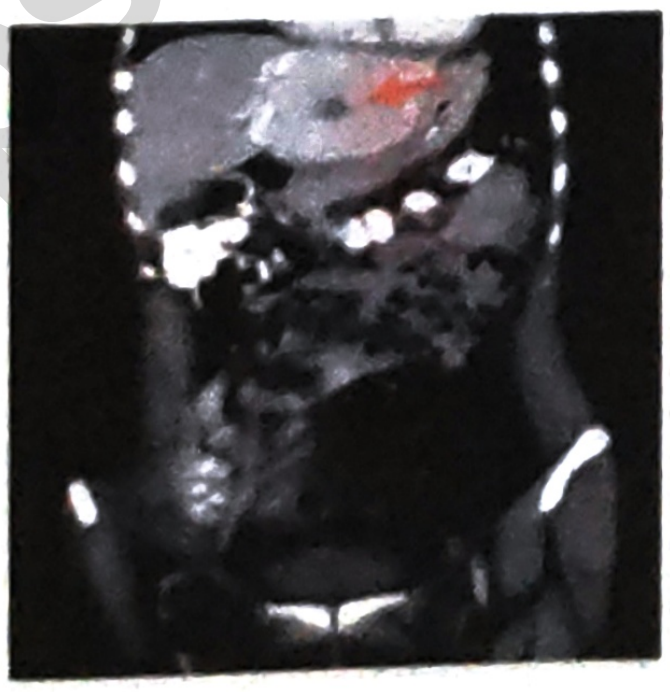 Stellate scar appearance	Hot Uptake in TC^{99m} - sulphur colloid / FNH

https://t.me/Latestneetpgnotes

PrepLadder

Acute hepatitis

→ Edematous hepatocytes along with fibrous strands around portal vein gives Starry sky appearance on USG

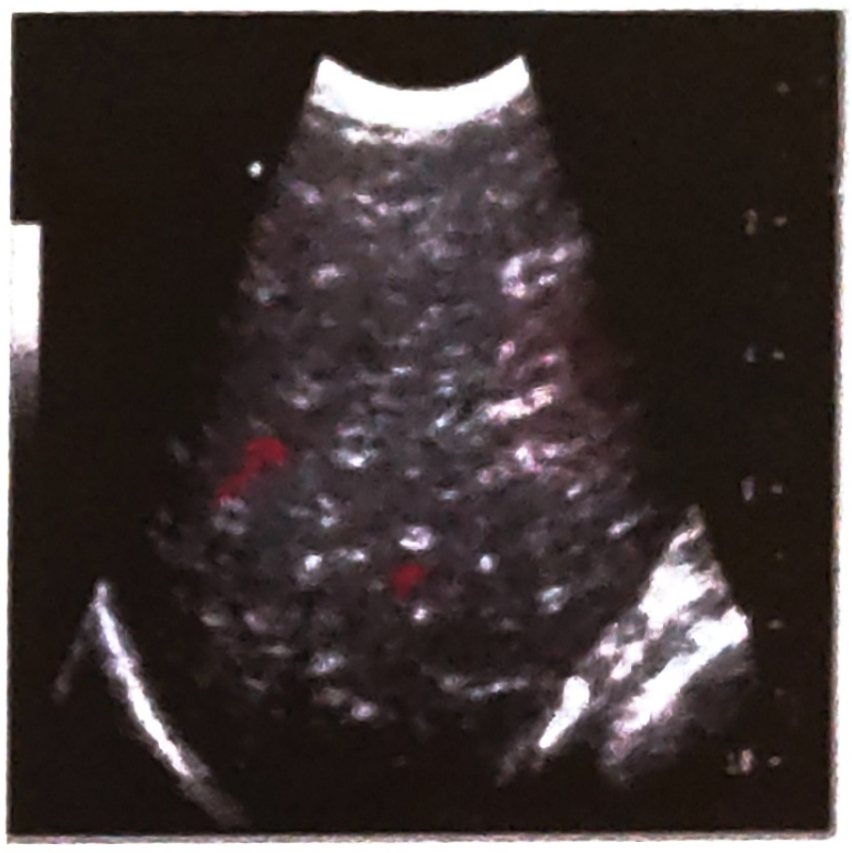

Starry sky appearance on USG - acute hepatitis

Note:

Starry sky appearance

→ On NCCT Brain - calcific nodular stage of NCC

→ On histopathology - Burkitt's lymphoma

→ On immunofluorescence - PSGN

→ On USG liver - Acute hepatitis

Biliary atresia

→ "Triangular cord sign" is seen

→ Has empty GB fossa / Ghost gall bladder

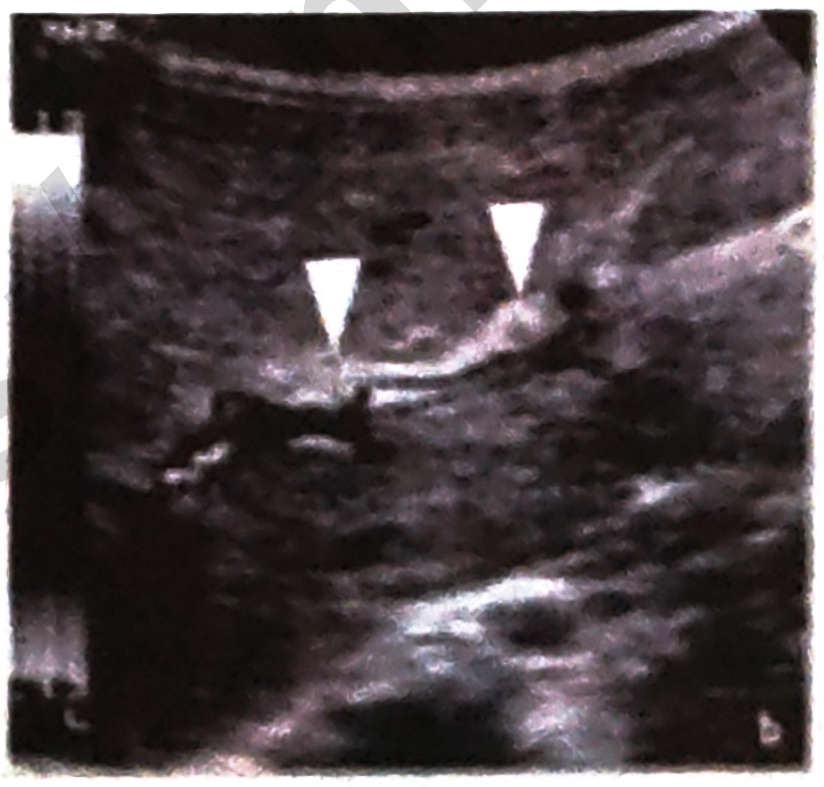

Biliary atresia

Distal CBD obstruction

→ "Double Barrel appearance" on USG due to dilated CBD

https://t.me/Latestneetpgnotes

PrepLadder

Distal CBD obstruction

Acute cholecystitis

00:15:42

→IOC is Ultrasound

→Most accurate is HIDA scan

USG Findings

→GB wall thickening

→Luminal distension

→Posterior sonographic murphy sign

→Peri cholic fluid

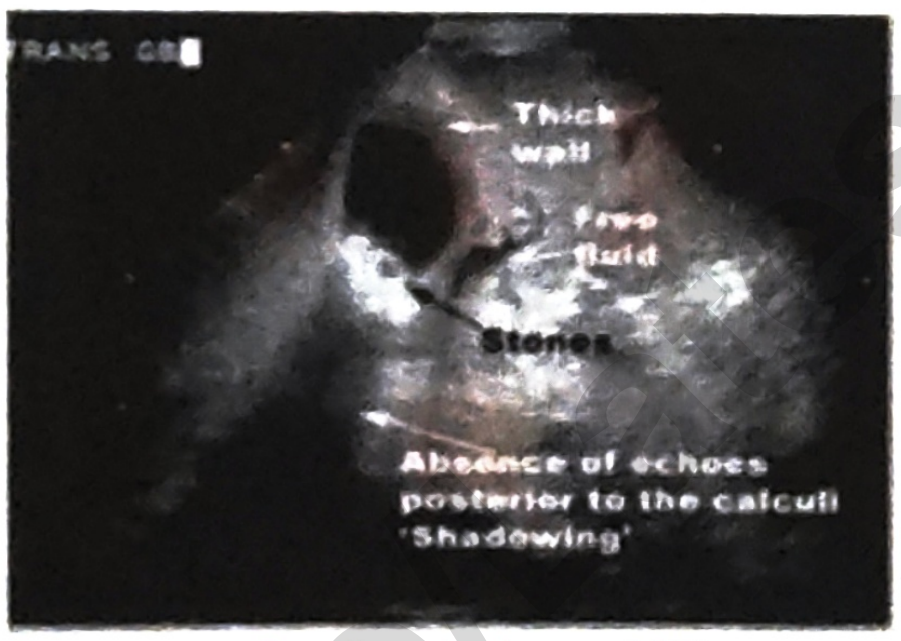

Acute cholecystitis

Porcelain GB

→It is a pre malignant condition

→Characterized by calcification of wall of GB

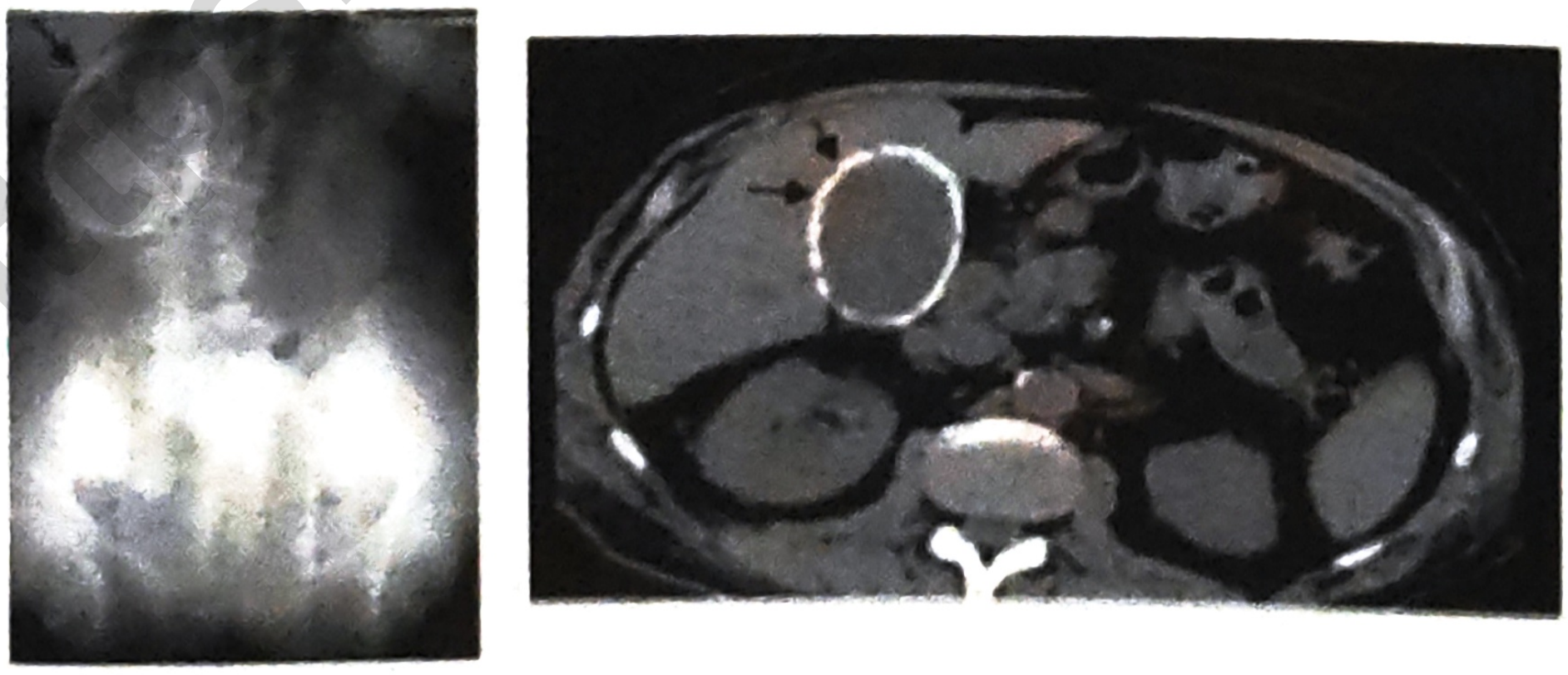

Calcified Gall bladder wall in X-ray & CT image -Porcelain GB

https://t.me/...stneetpgnotes

PrepL

Mercedes Benz Sign

→Seen when air is trapped within GB calculi

→Also Known as - Seagull / Crow feet sign



Mercedes Benz / Seagull / crow feet sign

Riglers Triad 00:18:51

→Seen in Gallstone Ileus

- Pneumobilia (air in biliary tree)
- small bowel obstruction
- Impacted ectopic gallstone

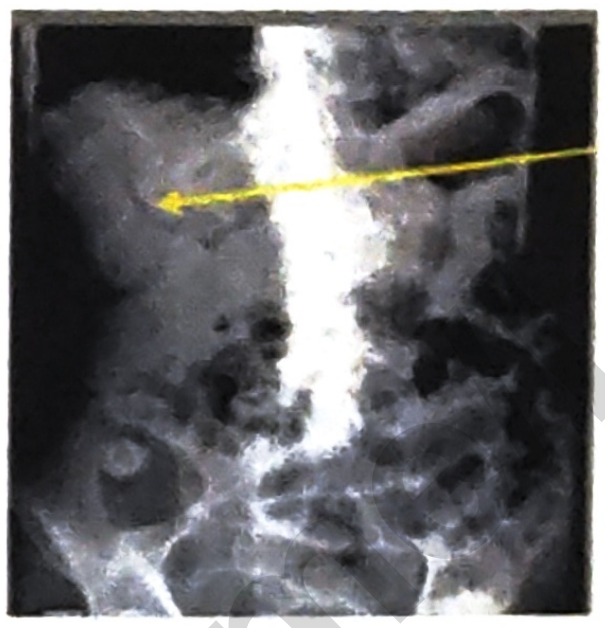

Rigler's Triad

Note:

→PTC - done for upper CBD obstruction

→ERCP - Done for lower CBD obstruction

T- tube cholangiogram

https://t.me/Latestneetpgnotes

PrepLadder

Double duct sign

00:23:05

→Seen on ERCP → Indicates Periampullary Ca

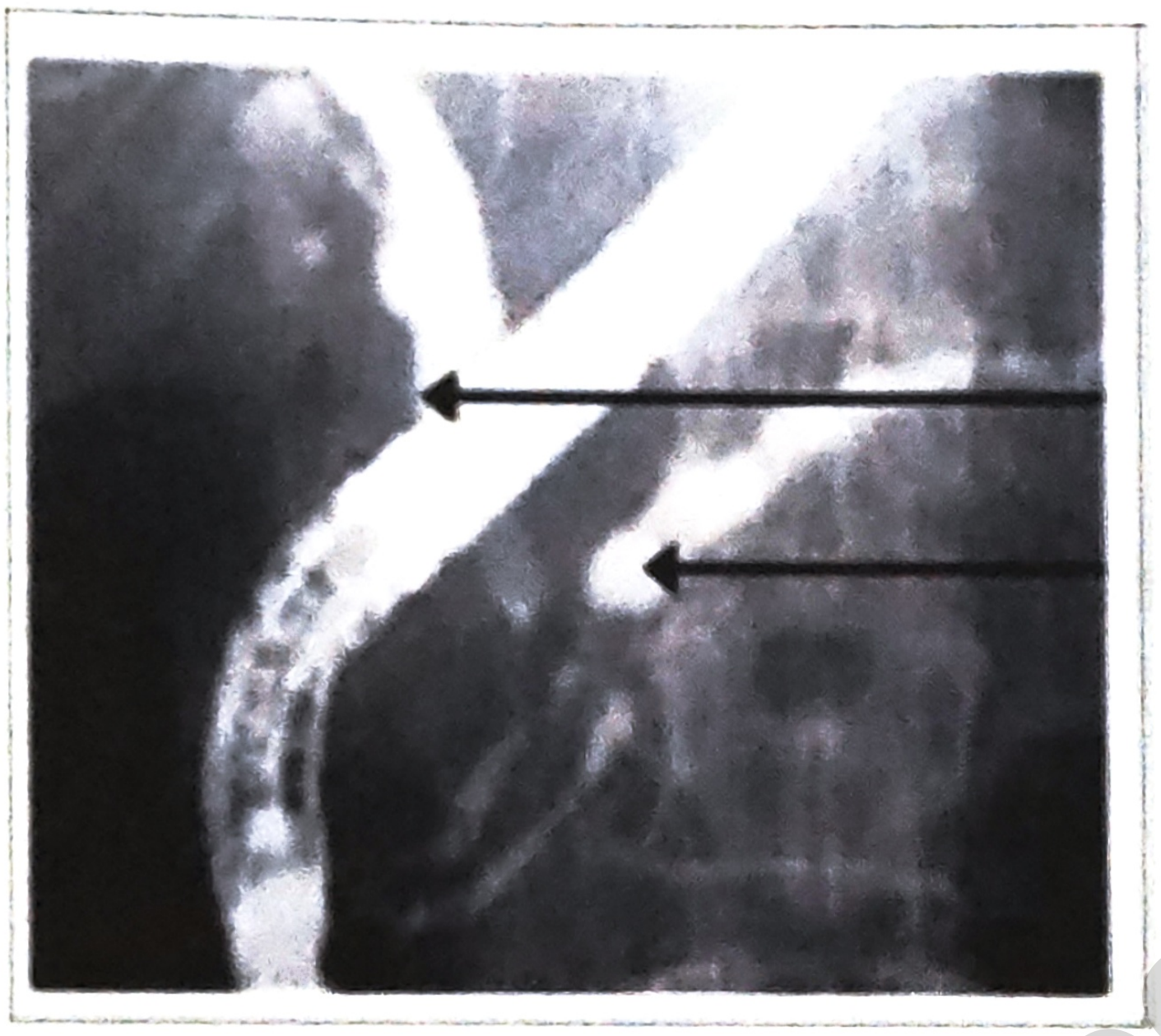

Double duct sign

https://t.me/Latestneetpgnotes

PrepLadder

Chapter 26

PANCREATIC RADIOLOGY

Acute Pancreatitis

00:00:19

→ Imaging IOC - CECT

→ Radiological signs

- Gasless abdomen: Because of repeated vomiting
- Colon cut off sign: Due to colonic spasm of transverse colon
- Sentinel Loop sign: Due to adjacent small bowel loop ileus
- Renal halo sign: On CT, perinephric fluid collection along with existing Perirenal fat gives a renal halo

Gasless abdomen

Colon cut off sign

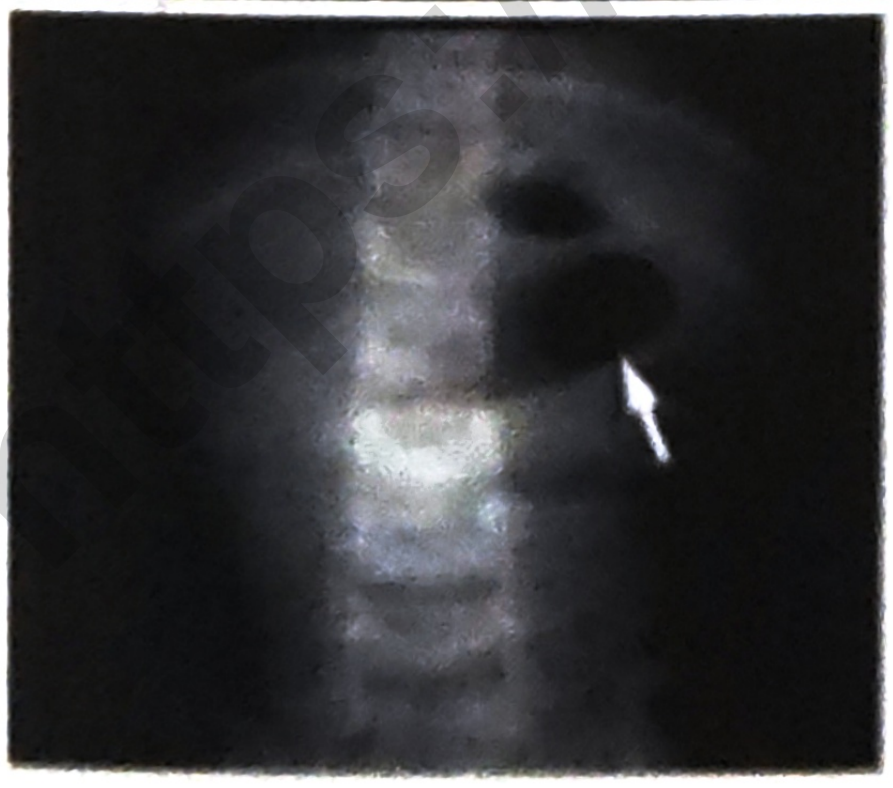

Sentinel loop sign

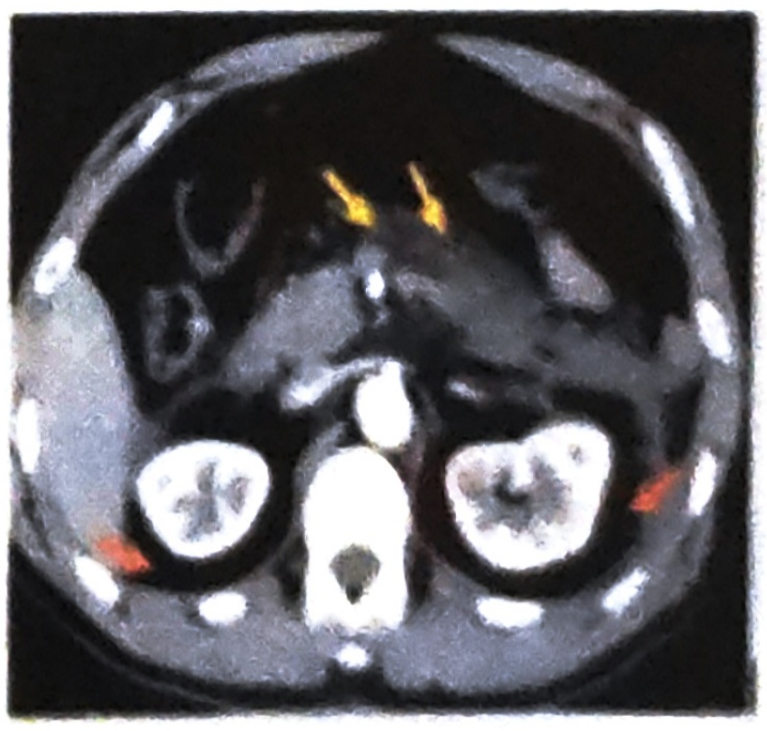

Renal halo sign

https://t.me/latestneetpgnotes

PrepLadder

For more free ebooks and notes, visit

https://t.me/Latestneetpgnotes

Or click this page to join

Chronic pancreatitis

00:07:25

→Has calcifications

→On MRCP / ERCP

- Beaded / torturous appearance of pancreatic duct
- String of Pearls / string of beads appearance
- Chain of lake appearance

→On Barium - Reverse 3 sign of Frostberg (also seen in Ca Head of Pancreas)

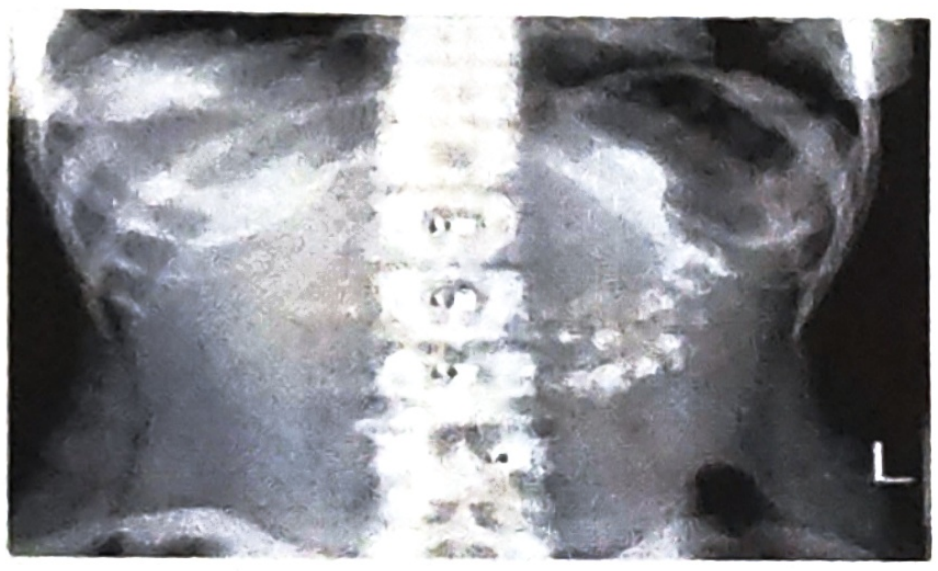

Calcifications in Pancreas

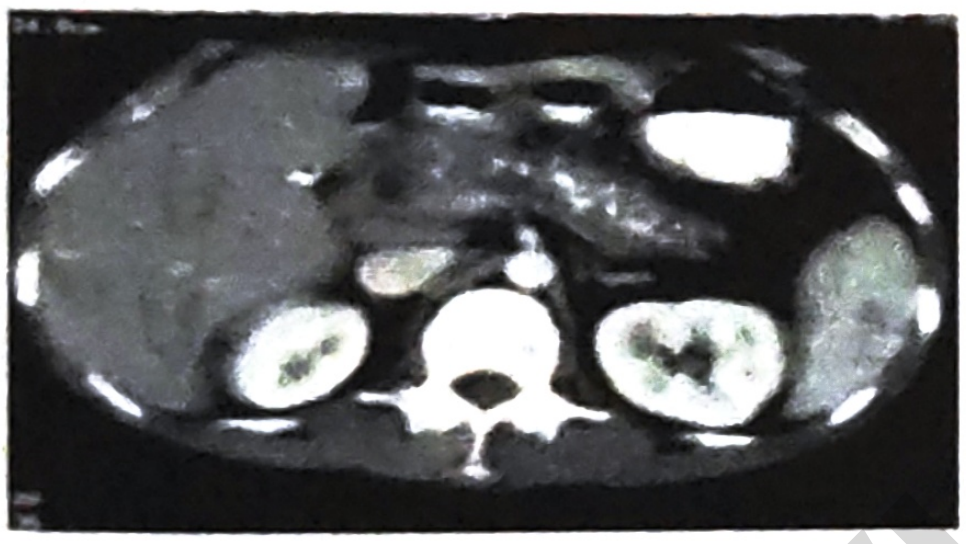

Calcifications in Pancreas



string of Pearls / string of beads appearance on MRCP

Ca head of pancreas

00:11:15

→Widening of C - Shaped loop of duodenum

→Mucosal irregularity / Rose thorning of 2nd part duodenum on medial wall

- Reverse 3 sign of Frostberg



Revers 3 sign of Frostberg

PrepLadder

https://t.me/neetpgnotes

Serous cystadenomas of pancreas 00:13:40

→Sunburst appearance of pancreas due to radiating fibres

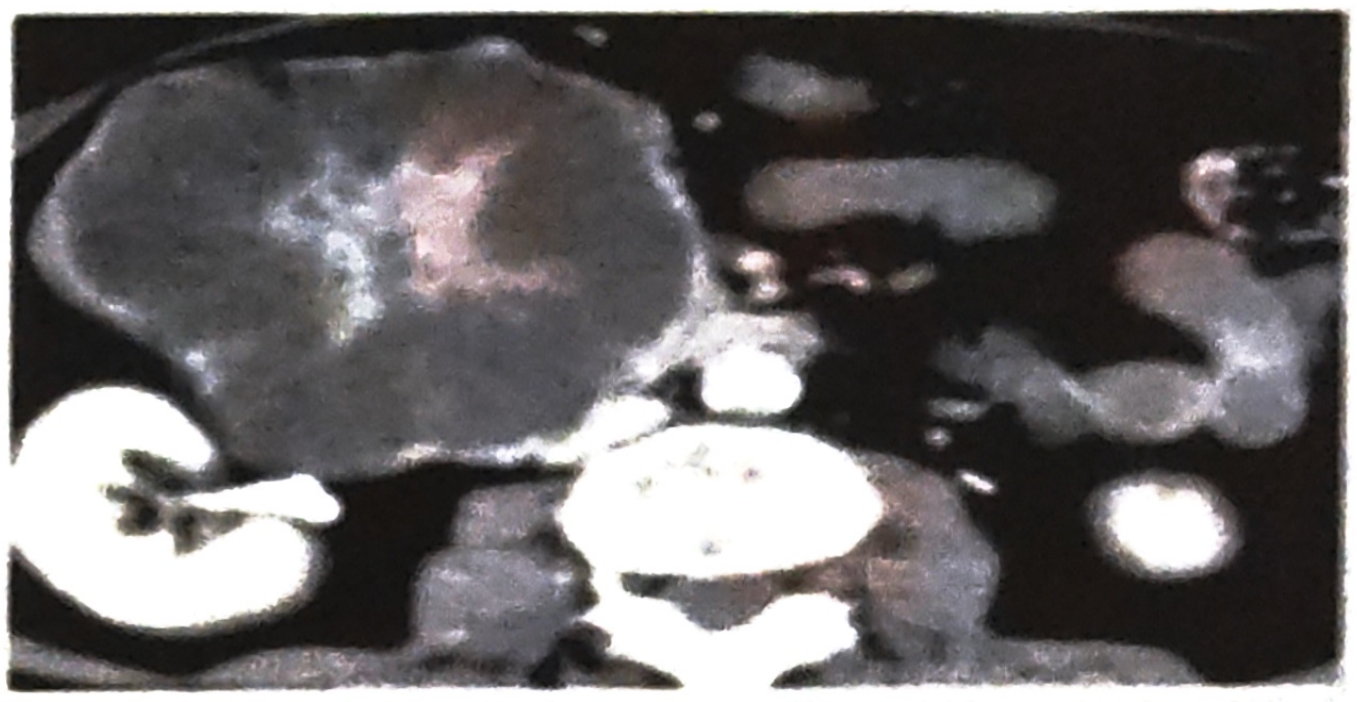

Serous cystadenomas of pancreas - Sunburst appearance

Primary Sclerosing cholangitis 00:14:36

→Prune tree appearance on ERCP / MRCP - Primary Sclerosing cholangitis

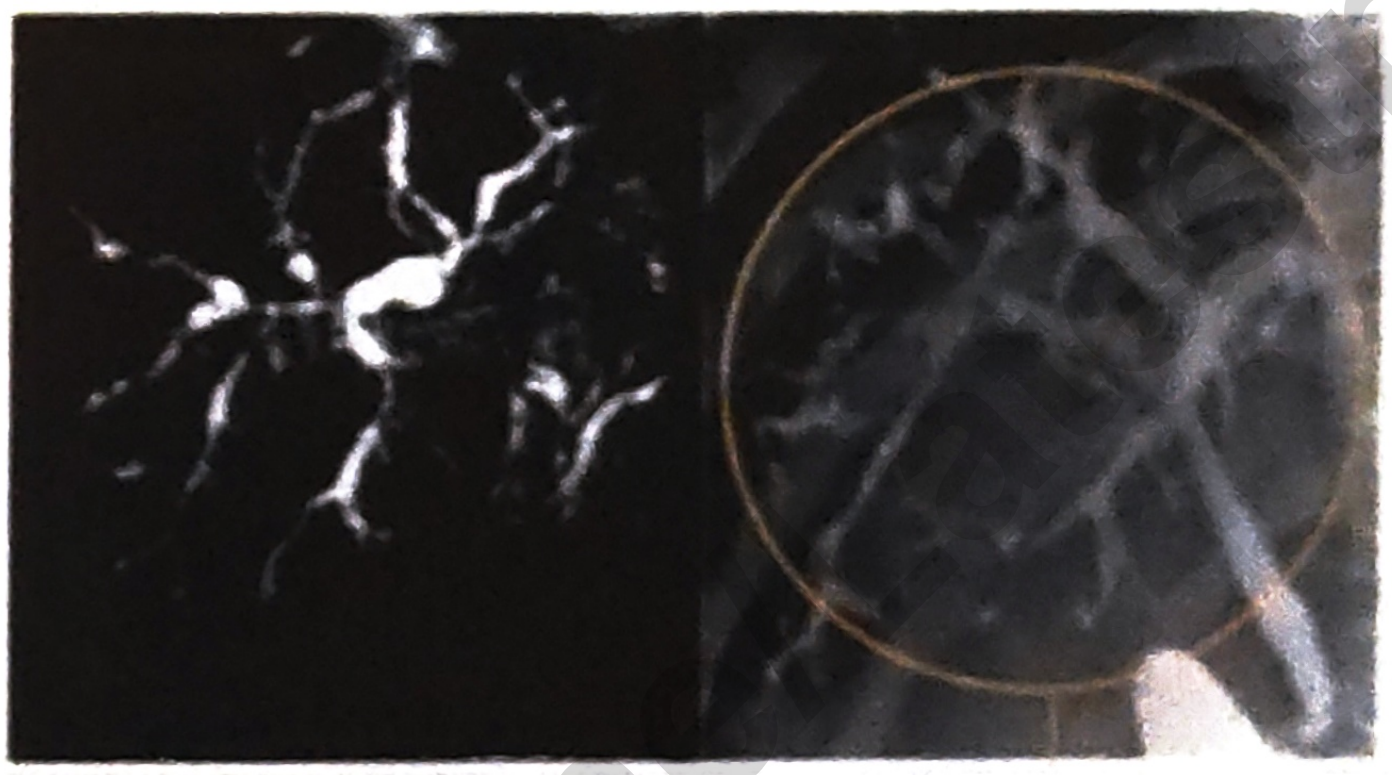

Prune tree appearance
Primary Sclerosing Cholangitis

Note:

→Prune tree appearance on CXR

- Pulmonary arterial hypertension

https://t.me/neetpgnotes

PrepLadder

Pancreatic Radiology

Acute pancreatitis

Radiological signs
- Gasless abdomen
- Colon cut off sign
- Sentinel loop sign
- Renal halo sign

Chronic pancreatitis

- Has calcifications

On MRCP / ERCP
- Beaded / tortous appearance of pancreatic duct
- String of pearls / string of beads appreance
- Chain of lake appearance

CA head of Pancreas

Radiological signs
- Widening of C-shaped loop of duodenum
- Reverse 3 sign of frostberg

https://t.me/Latestneetpgnotes

Chapter 27

GENITOURINARY RADIOLOGY

00:00:45

→ Schistosomiasis– Risk factor for SCC of Bladder	– Fetal skull like calcification of bladder
→ Neurogenic bladder	– Christmas tree app. of bladder
→ TB Bladder	– Thimble bladder
→ Extrinsic compression of bladder (by pelvic hematoma / Pelvic L.N)	– Pear shaped / tear shaped

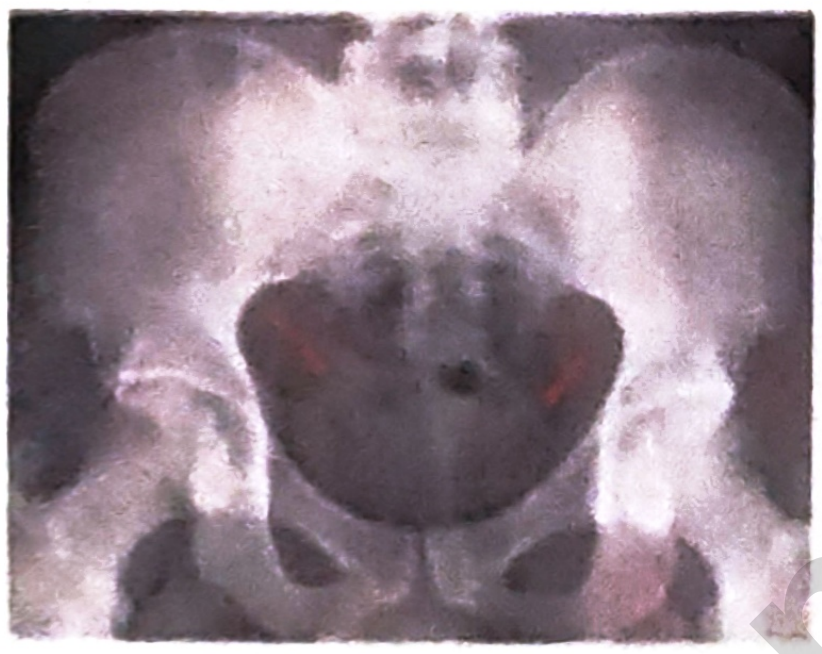

Fetal skull like calcification of bladder

Christmas tree app. of bladder

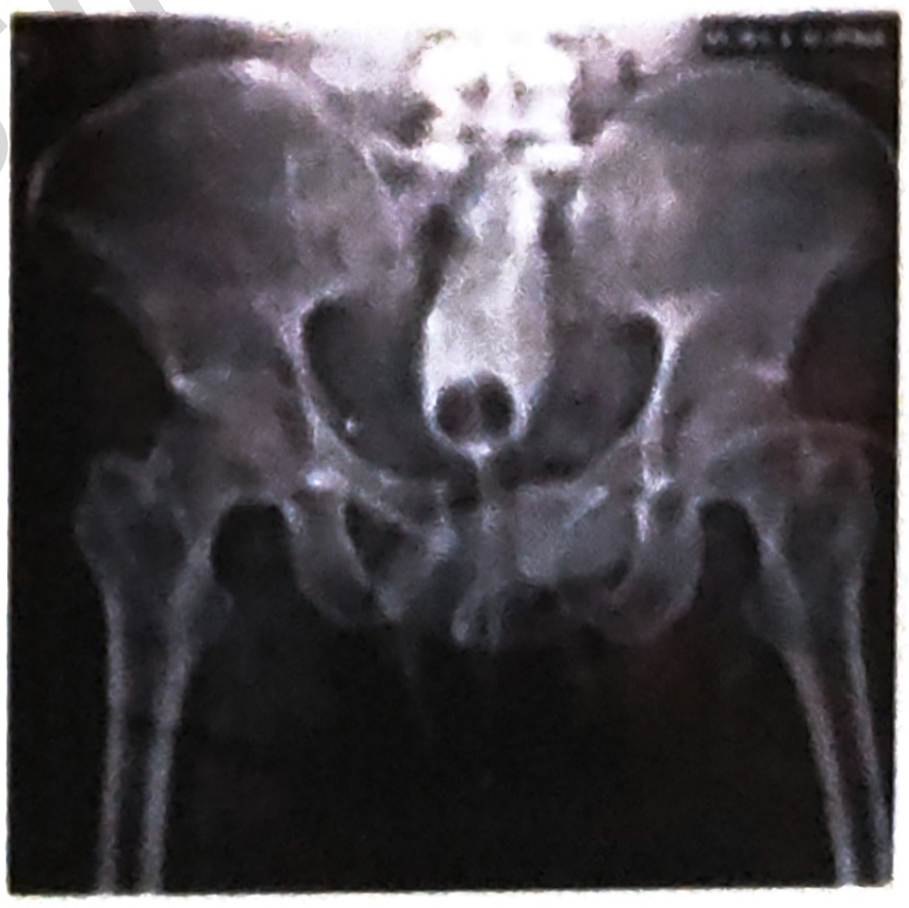

Pear shaped / tear shaped bladder

https://t.me/Latestneetpgnotes

PrepLadder

Renal TB

00:03:35

→ IOC – CECT

→ In kidney

- Earliest → Moth eaten calyces (on IVP)
- Putty kidney / Cement kidney

→ In ureter

- Tortuous / beaded appearance / cork screw appearance of ureter
- Kerr's kink
- On cystoscopy- golf hole ureteral orifice

→ In bladder

- Thimble bladder

Note:

→ IOC for renal TB = CT UROGRAPHY/CT-IVP/CECT

→ IOC for early renal TB = CT-IVP/IVP



Moth eaten calyces on IVP

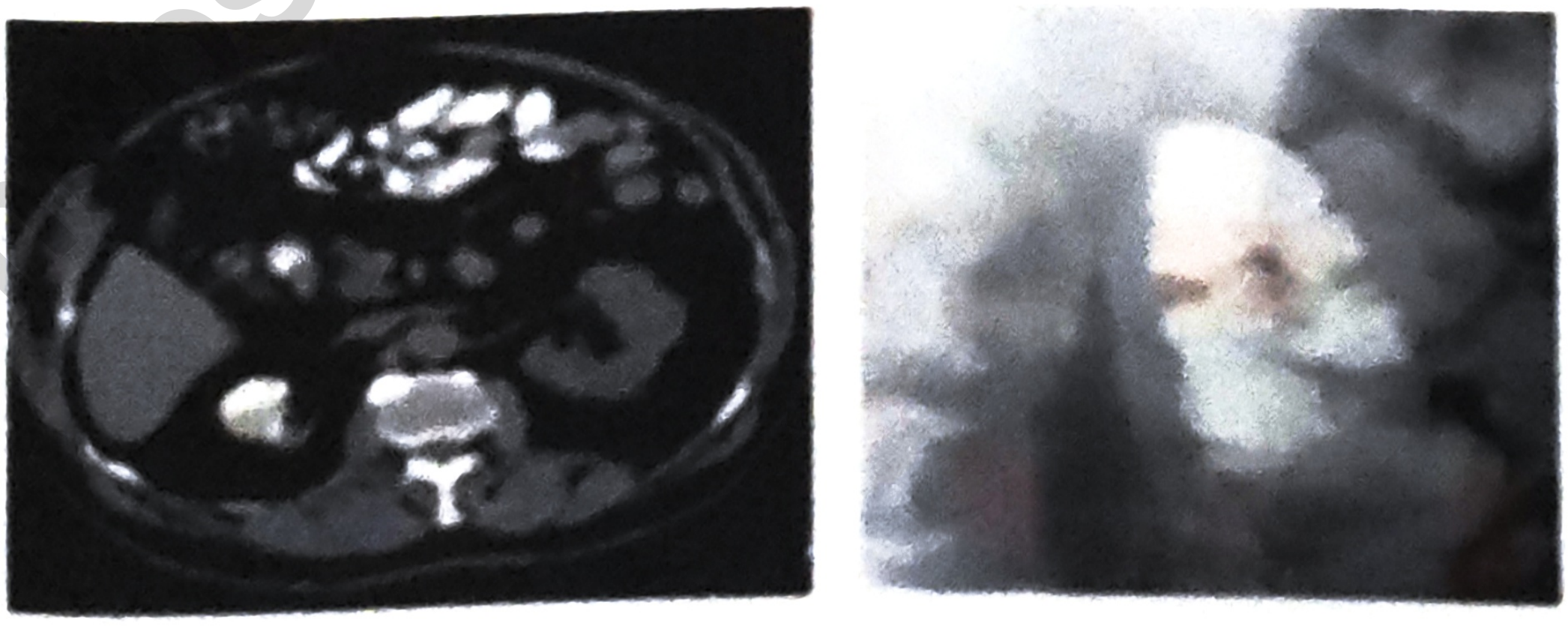

Putty kidney/ Cement Kidney

https://t.me/testneetpgnotes

PrepLa

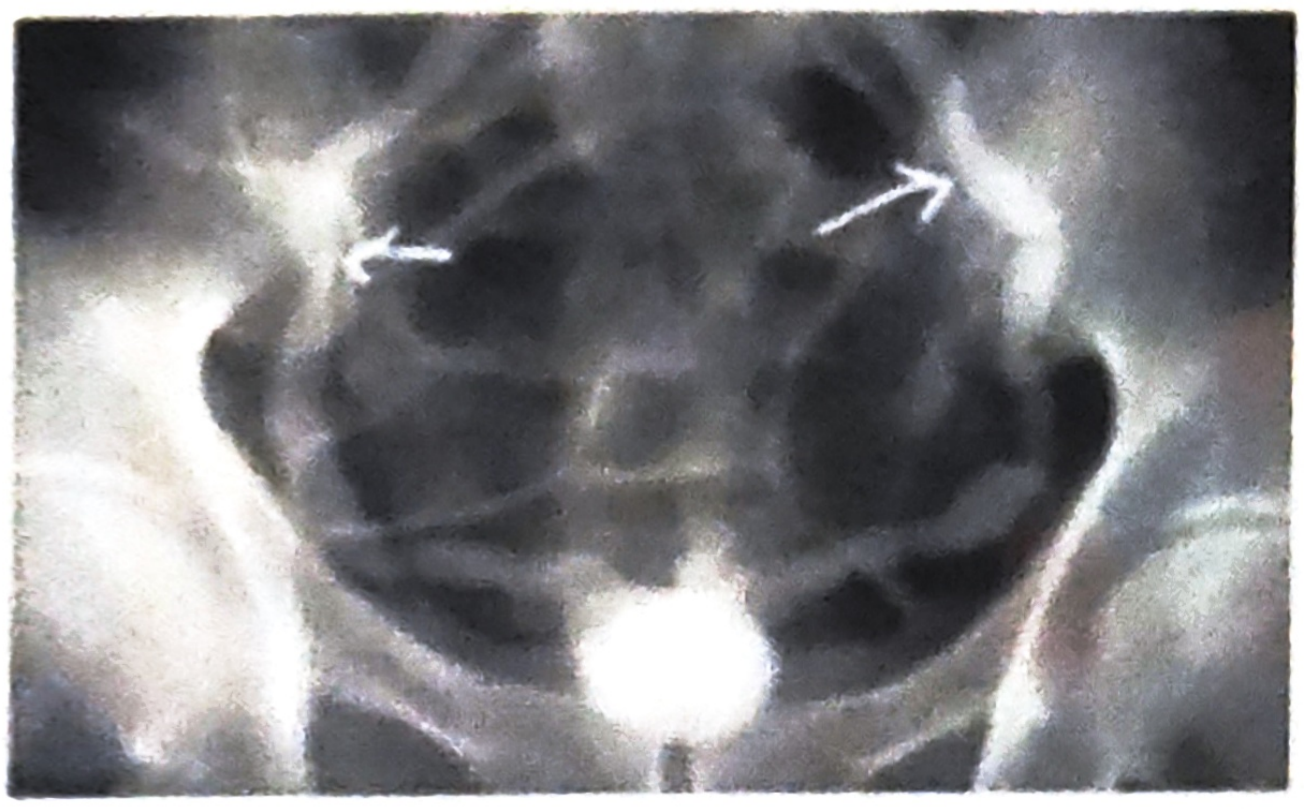

Cork screw appearance of ureter

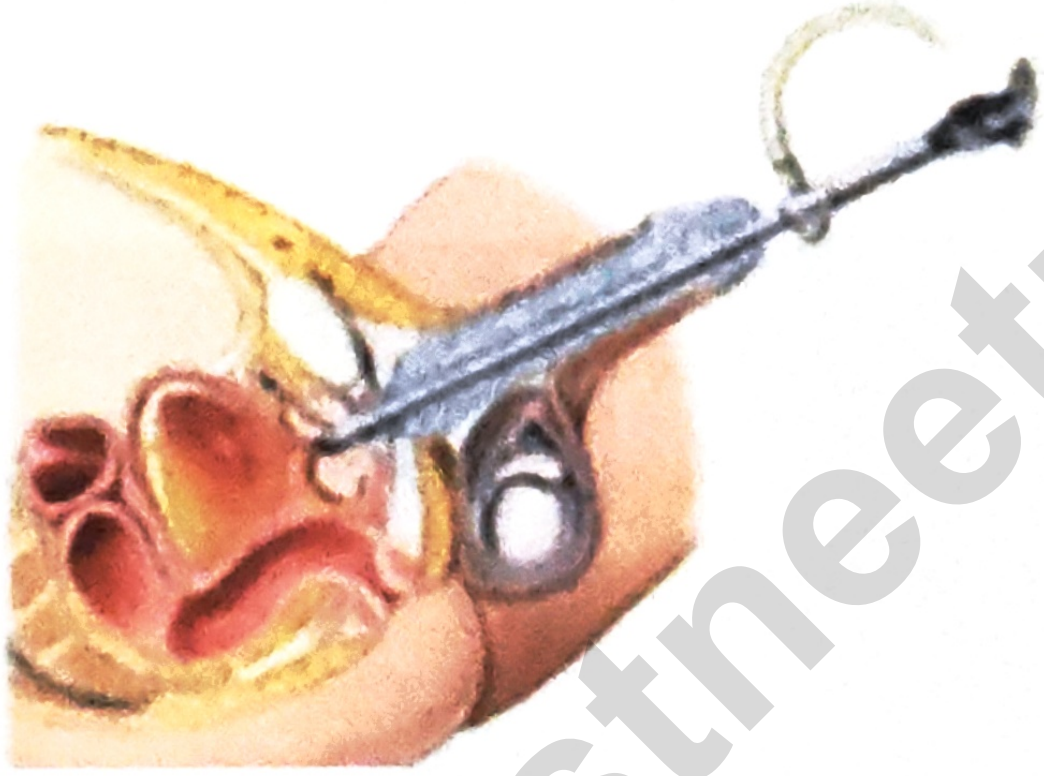

Golf hole urethral orifice

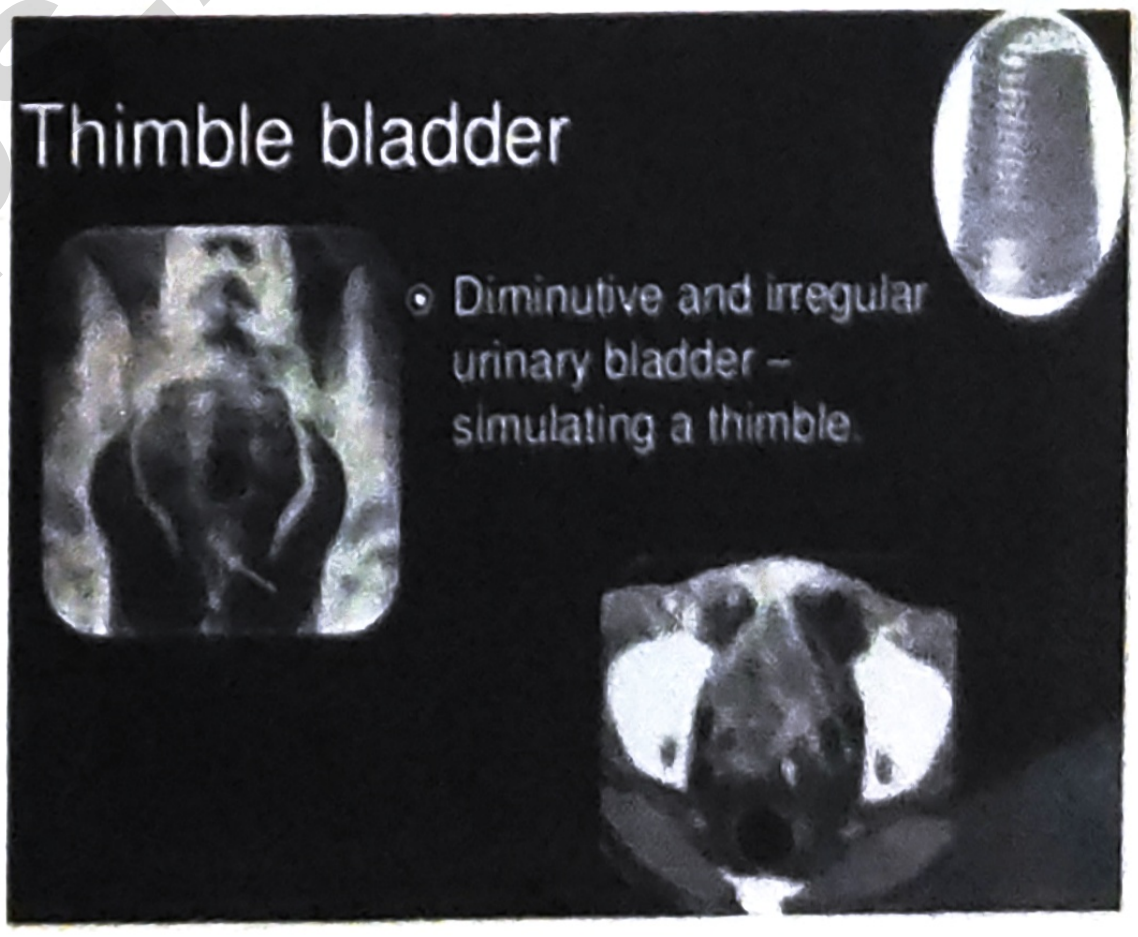

https://t.me/latestneetpgnotes

PrepLadder

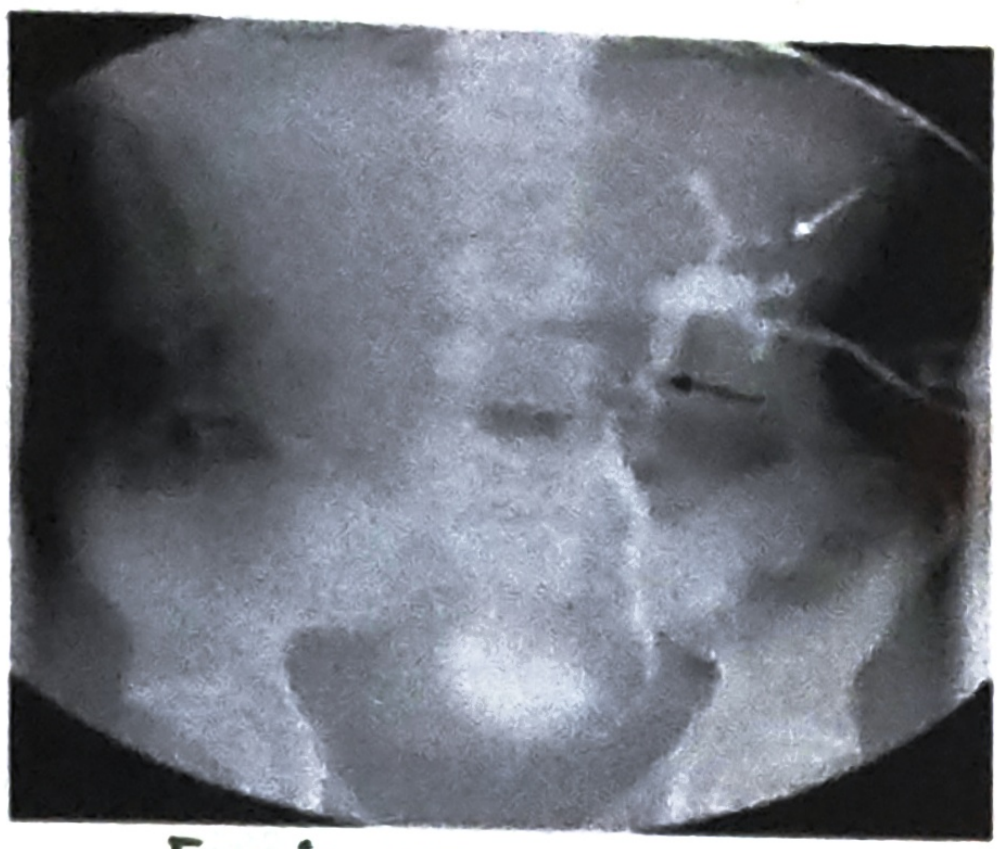

Egg in cup appearance

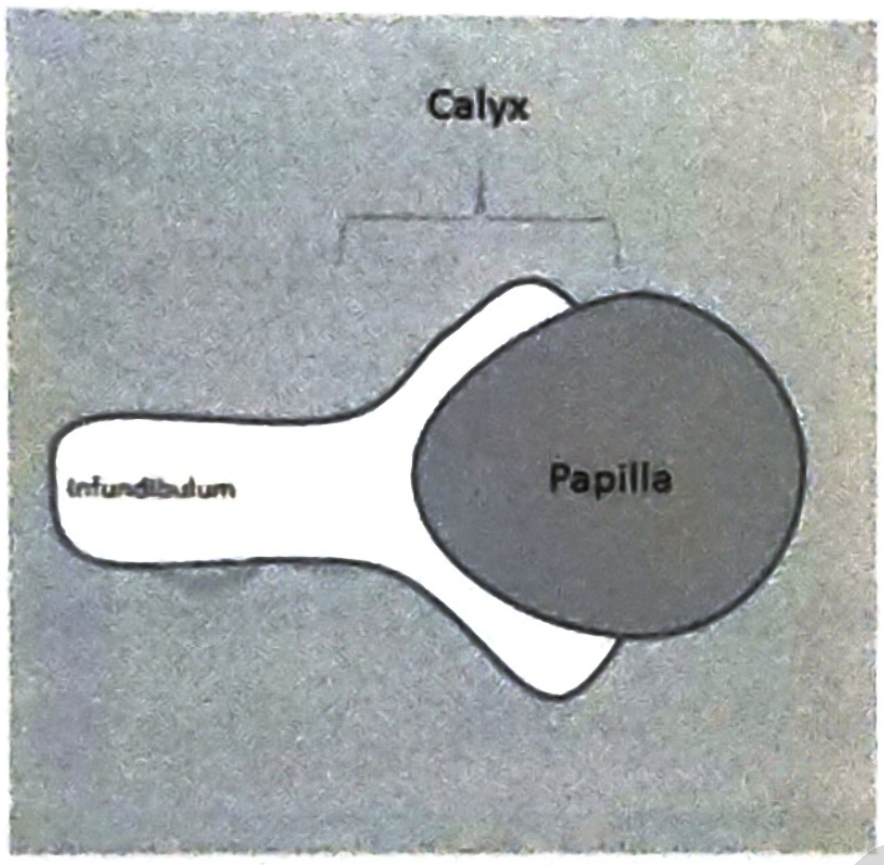

Lobster claw sign

Ring sign

Note:

→ IOC for ureteric calculi → NCCT

→ Dual energy CT → Characterize the type of kidney stone

https://t.me/Latestneetpgnotes

PrepLadder

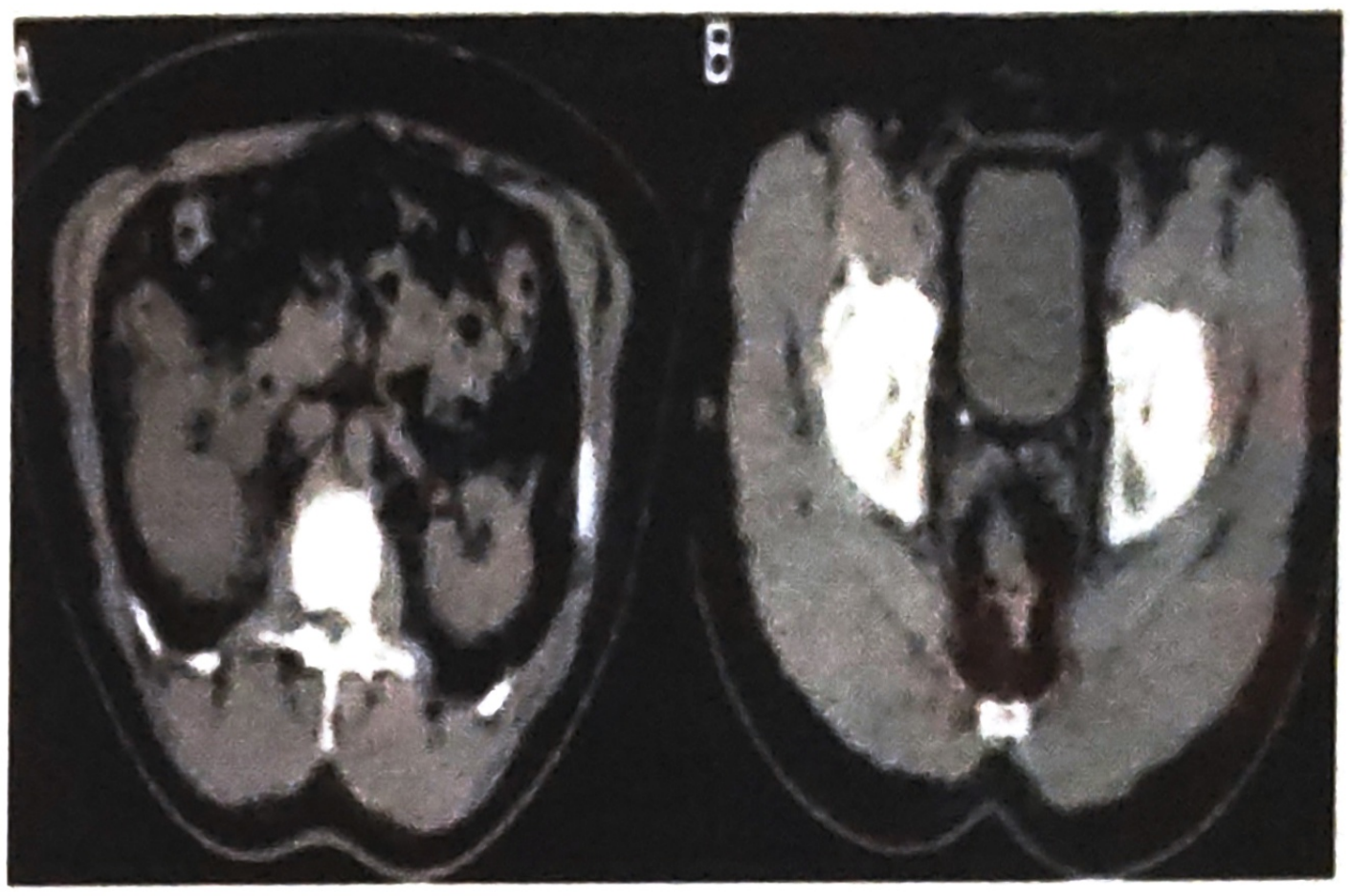

A) CT at kidney level – Right kidney is bulky and hazy
B) CT at Bladder level – Distal right ureteric calculi

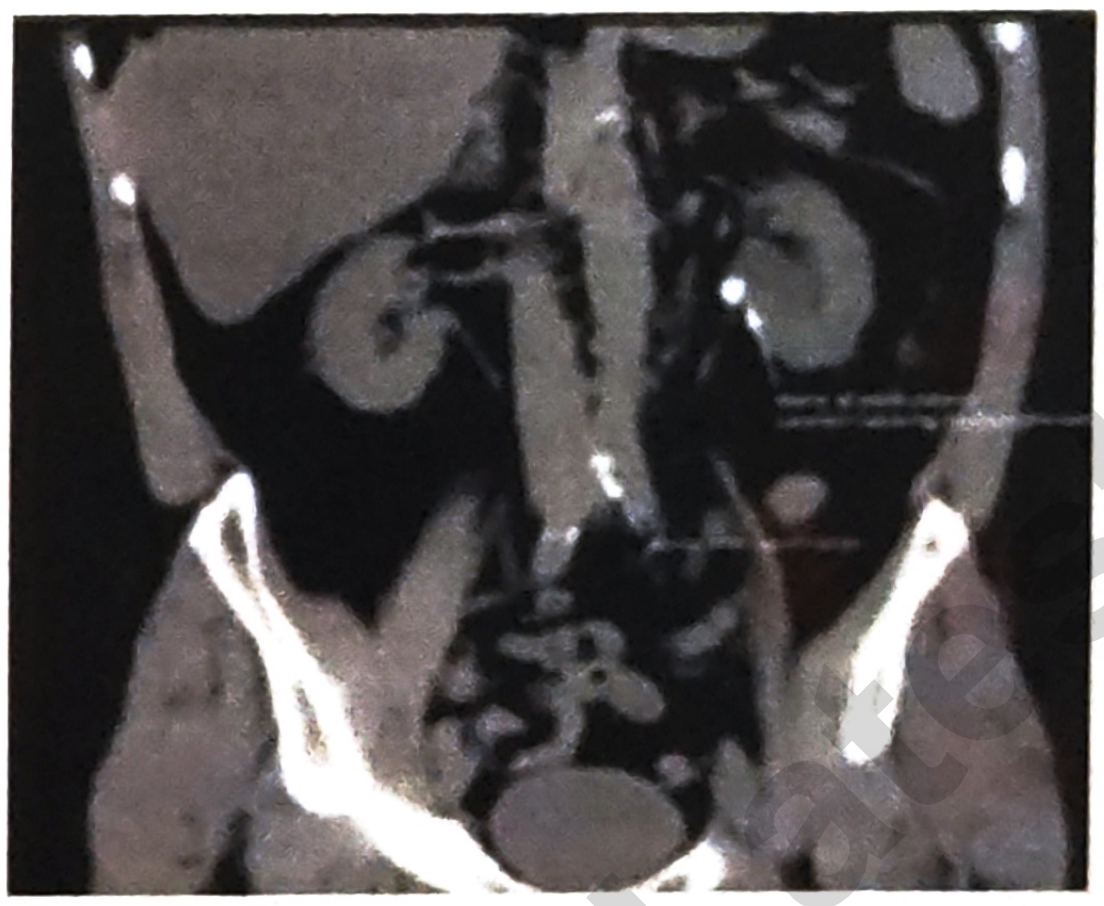

Coronal CT showing Left pelvic-ureteric junction calculi

Horse shoe kidney 00:16:14

→ Upward ascent of kidney is prevented by IMA (inferior mesenteric artery)

→ Fusion of inferior pole of both kidneys, the inferior calyces are medially oriented.

→ Gives "shaking hand sign & flower vase sign" on IVP

Horse shoe kidney	flower vase sign /shaking hand sign

https://t.me/Latestneetpgnotes

PrepLadder

Retroperitoneal fibrosis

- → Inferior calyces are laterally oriented
- → Due to fibrosis ureters are pulled medially in lumbar area giving "Maiden waist deformity"

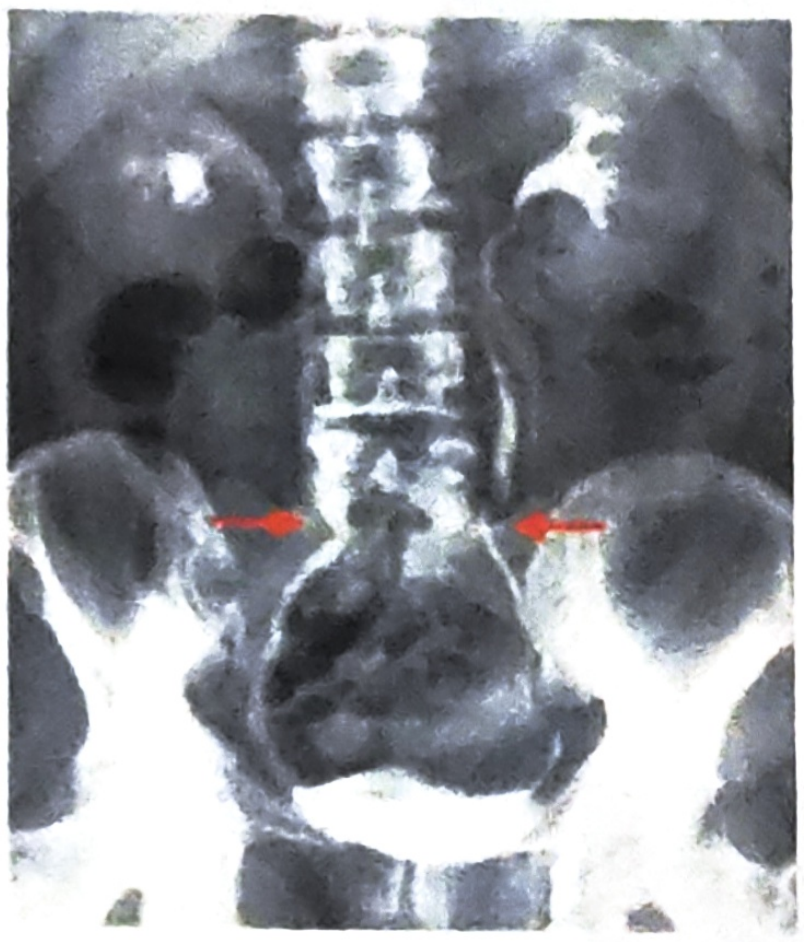

Maiden waist deformity

Ureterocele

00:20:26

- → Intra-luminal obstruction in bladder wall
- → Gives "Adder head" or "Cobra head" app. on IVP

Adder head" or "Cobra head sign

Benign prostatic hyperplasia

- → Fish hook appearance at distal ureter



Benign prostatic hyperplasia

https://t.me/Latestneetpgnotes

PrepLadder

Drooping lily sign

→ duplex kidney with non-functional upper moiety

→ RCC/ Hypernephroma / Grawitz tumor

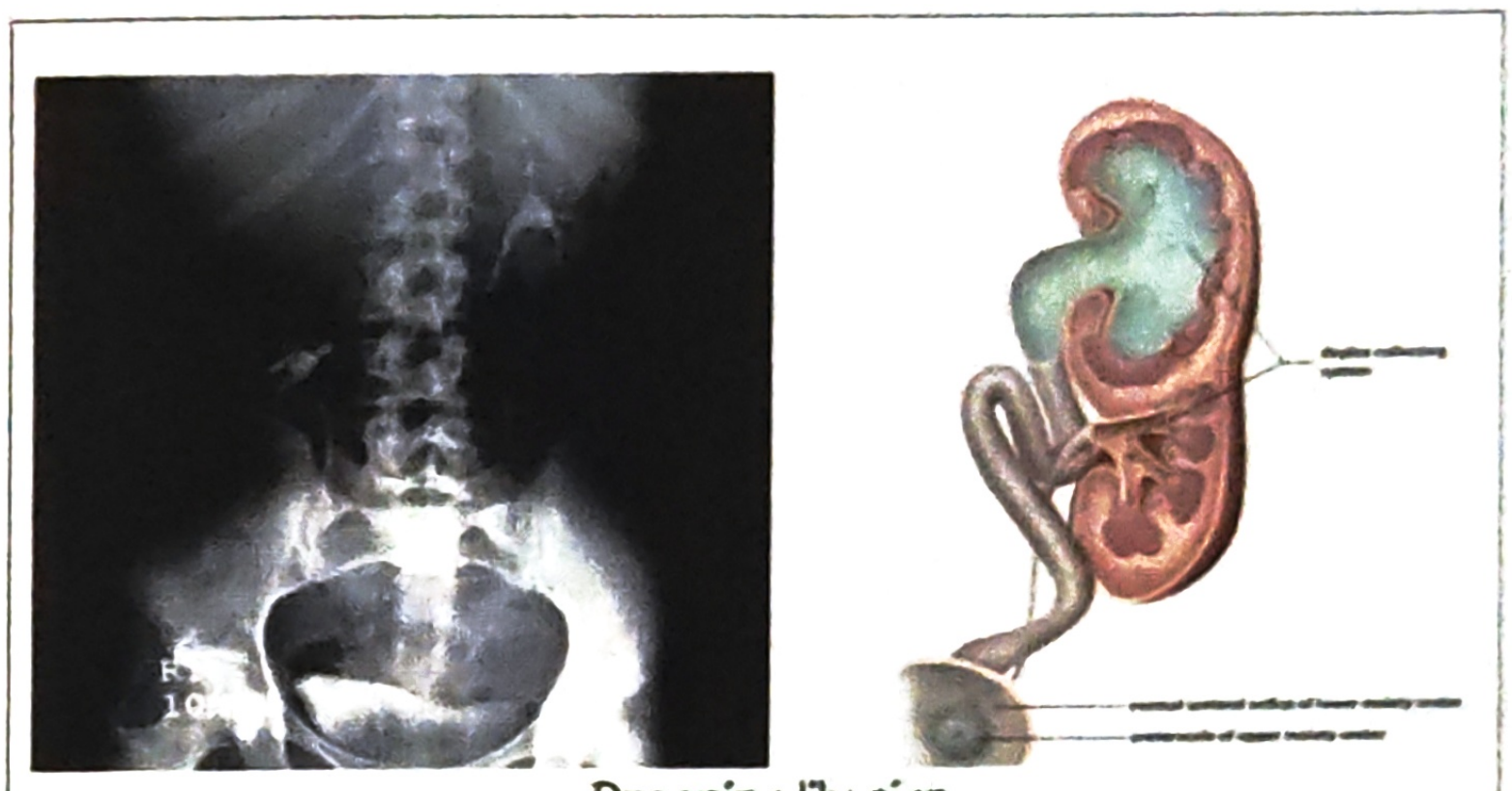

Drooping lily sign

Weigert – Meyer Rule of duplex kidney 00:24:46

→ Ureter of superior / upper pole moiety inserts inferomedial on the bladder & is more prone to obstruction, especially ureterocele

→ Inferior/ lower pole ureter inserts superolateral on the bladder & is more prone to reflux

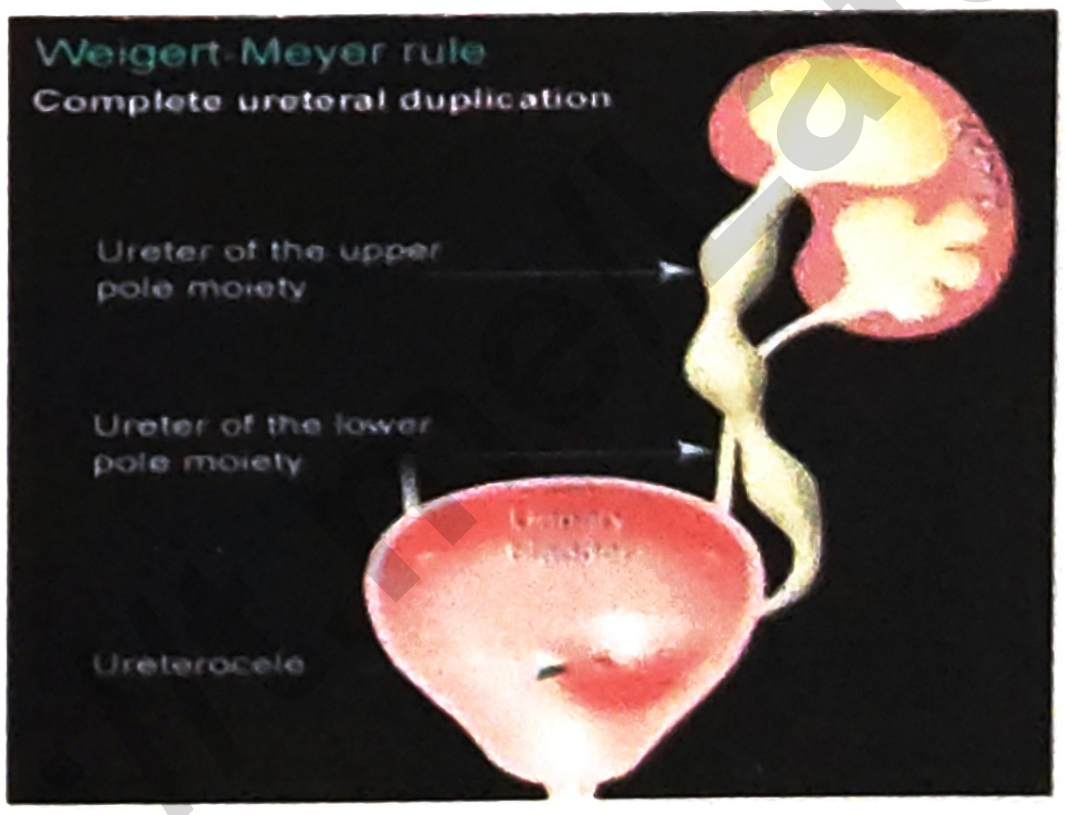

Bosniak classification 00:26:26

→ Used for Renal cysts

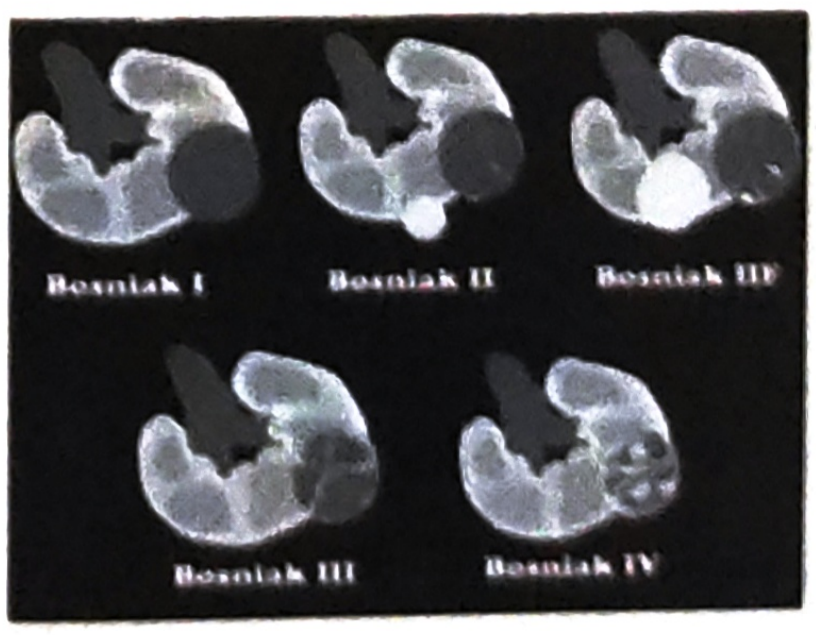

PrepLadder

Class	Description	Features
1	Simple cyst	Anechoic, imperceptible wall, round
2	Minimally complex	Single thin septation, thin calcification
2F	Minimally complex (need follow up)	Thin septation, thick calcification, hyper dense on CT
3	Indeterminate	Thick or multiple septation, mural nodule
4	Clearly malignant	Solid mass with cystic spaces

Fibromuscular dysplasia

→ On angiography -Beaded / Tortuous / Pile of plate app. of renal artery is seen

→ M/C artery involved – Renal artery

→ 2nd M/C artery involved – ICA

Pile of plate app. of renal artery on Angiography

Multicystic Dysplastic kidney 00:28:30

→ MC Cystic kidney disease

→ Mostly unilateral

https://t.me/Latestreetpgnotes

PrepLadder

Embryology of kidney development

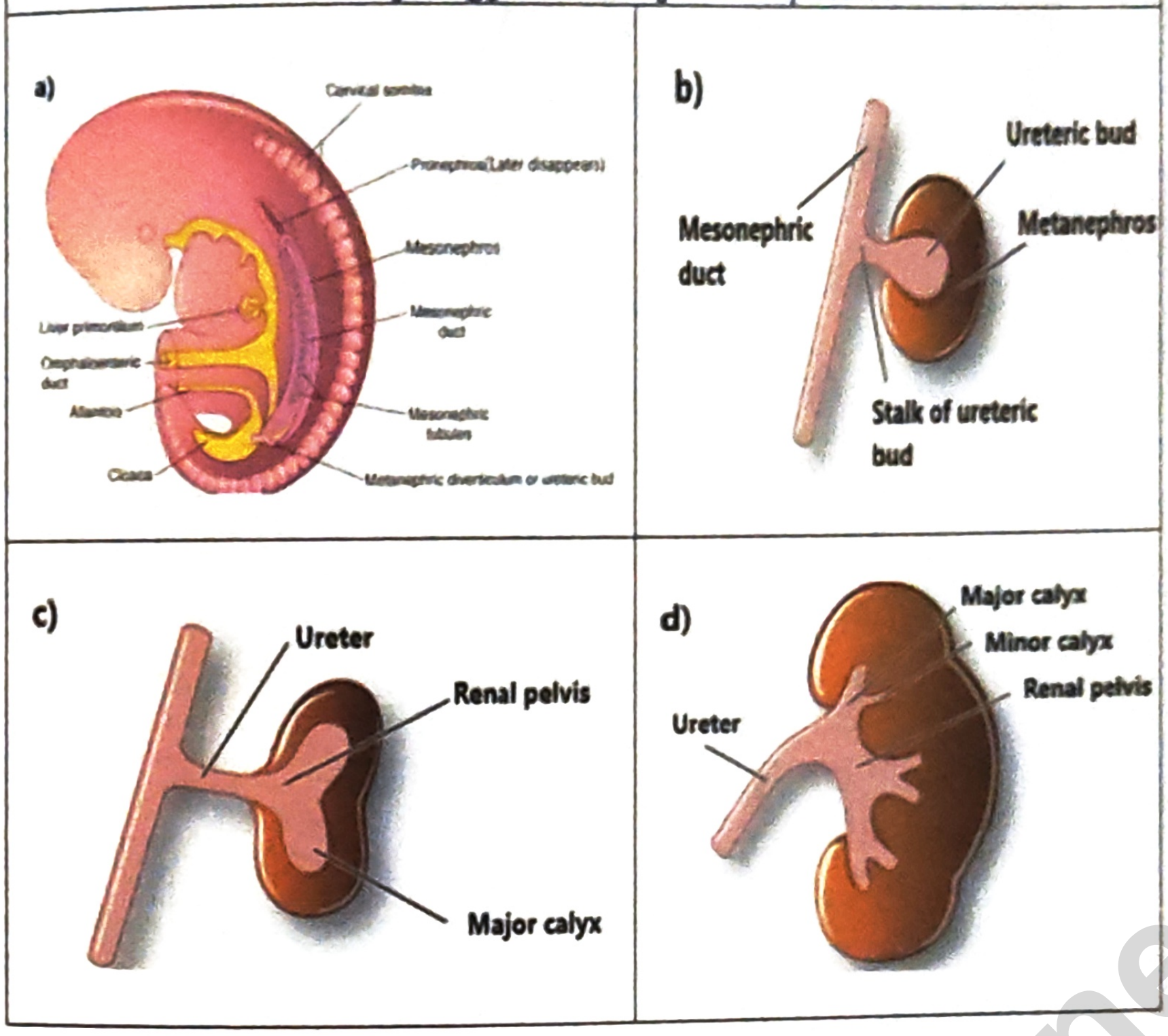

Multicystic Dysplastic kidney

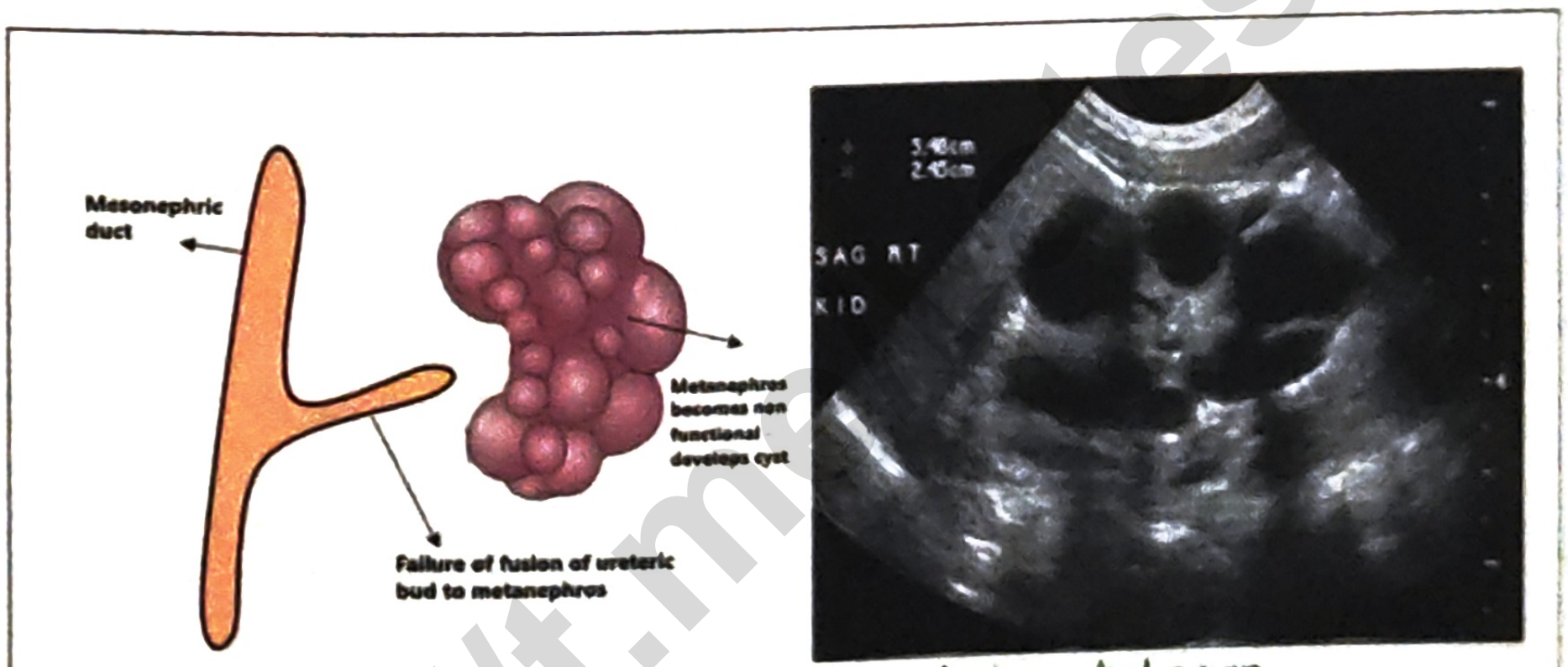

→ Shows Soap bubble appearance on Antenatal scan

Difference between ADPKD & ARPKD

00:31:35

	ADPKD (Adult)	ARPKD (Child)
Defective protein	→ Polycystin	→ Fibrocystin
Unilateral/Bilateral	→ Bilateral	→ Bilateral
Hepatic cyst	→ Present	→ Present
Hepatic fibrosis	→ Present	→ More common

https://t.me/testneetpgnotes

PrepLadder

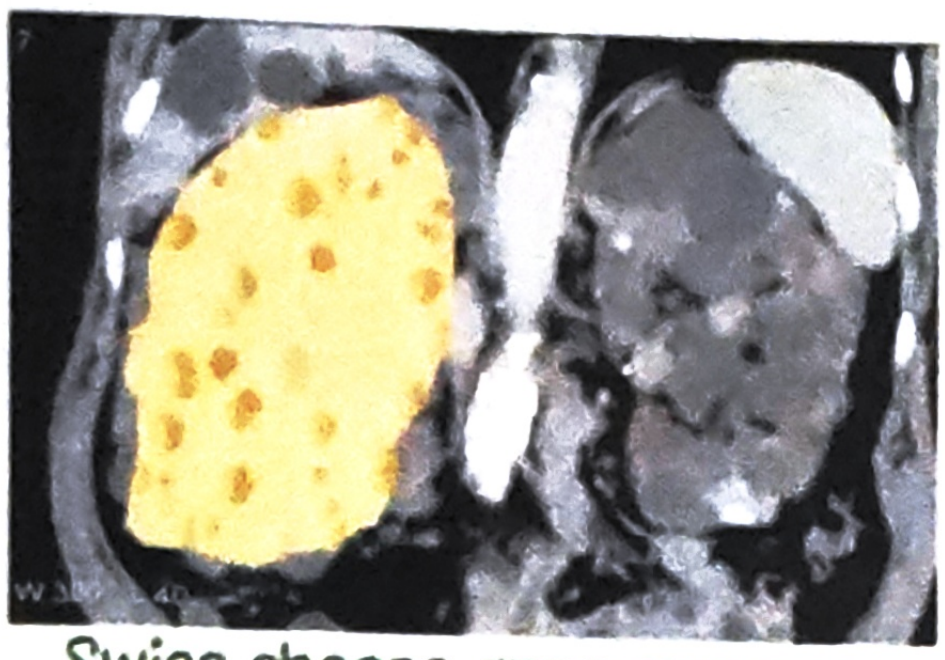

Swiss cheese appearanceon Nephrogram

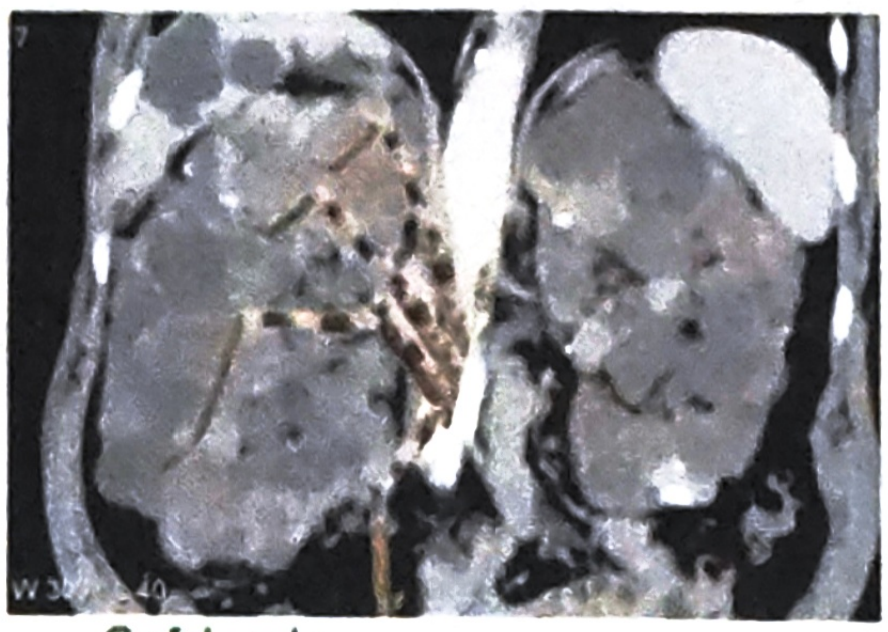

Spider leg appearanceon Pyelogram

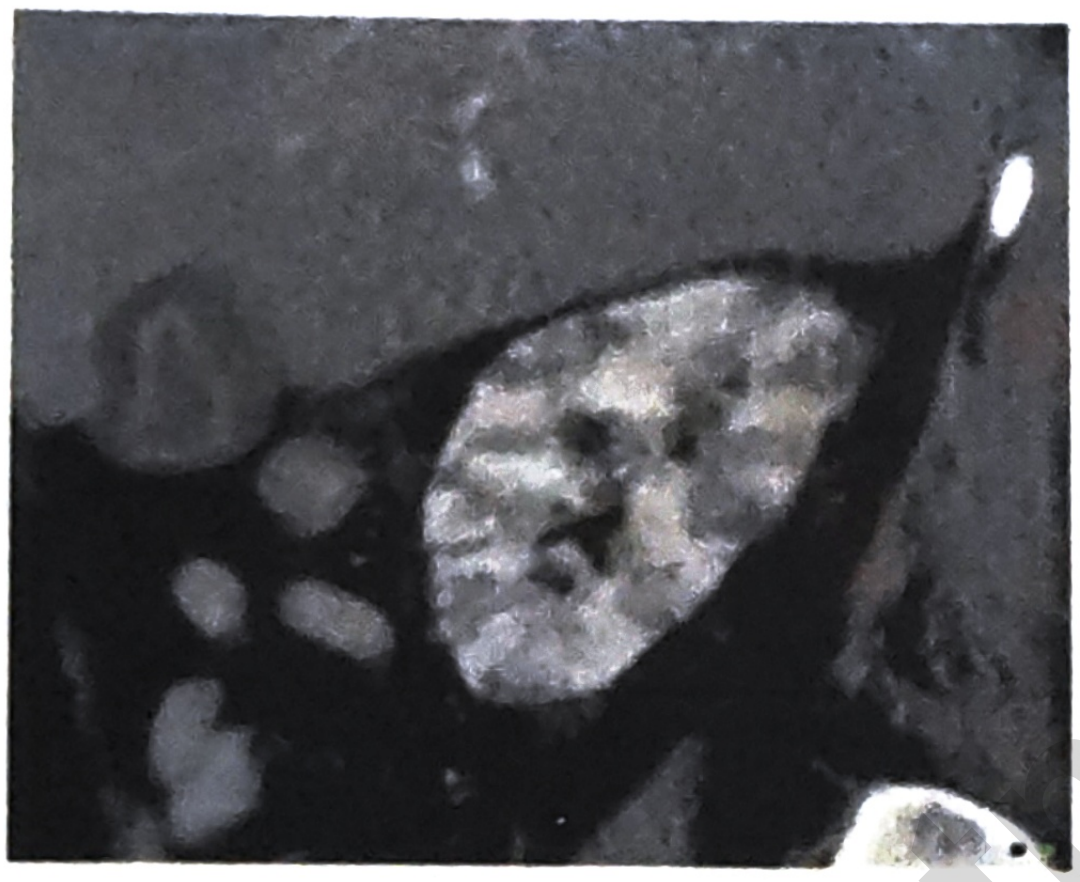

Striated Nephrogram

Medullary sponge kidney 00:37:31

→ On IVP, contrast opapcified collecting ducts gives Bouquet of fllowers appearance

Pathophysiology

In medullary spnoge kidney → Cystic dilatation of CD

Urinary stasis in the cystic spaces ↓ Medullary nephrocalcinosis	On IVP, Contrast deposition in cyctic spaces ↓ Bouquet of flowers appearnce
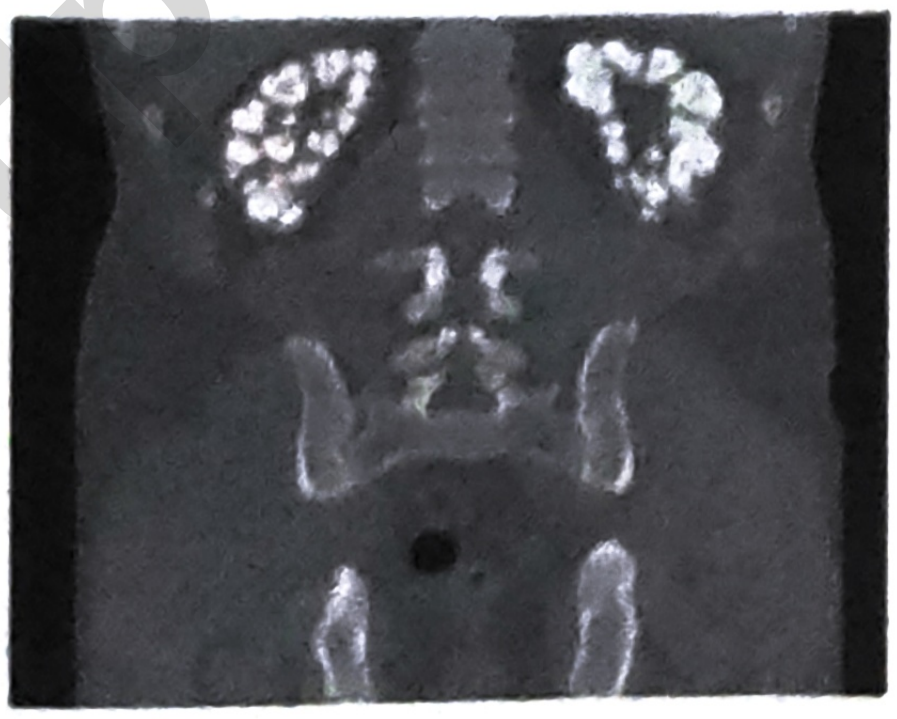	

https://t.me/Latestneetpgnotes

PrepLadder

Note:

→ Cortical Nephrocalcinosis– Seen in Alport's syndrome

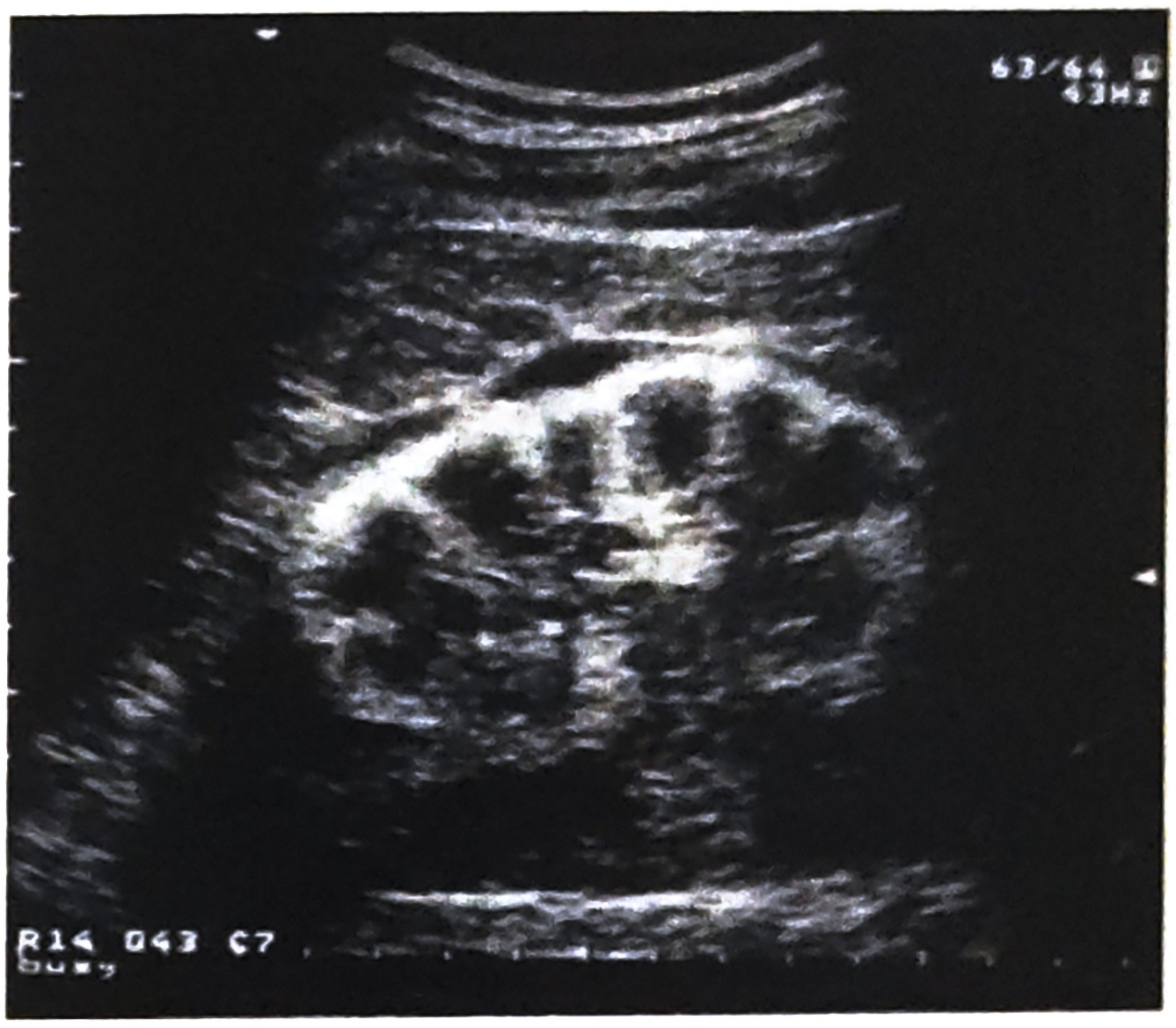

Cortical Nephrocalcinosis

Note:

→ Best to evaluate Posterior urethra –MCU (Micturating Cystourethrogram)

- IOC for Posterior urethral valve – MCU
- IOC for Vesicoureteric reflux - MCU

→ Best to evaluate Anterior urethra – RGU (Retrograde Urethrogram)

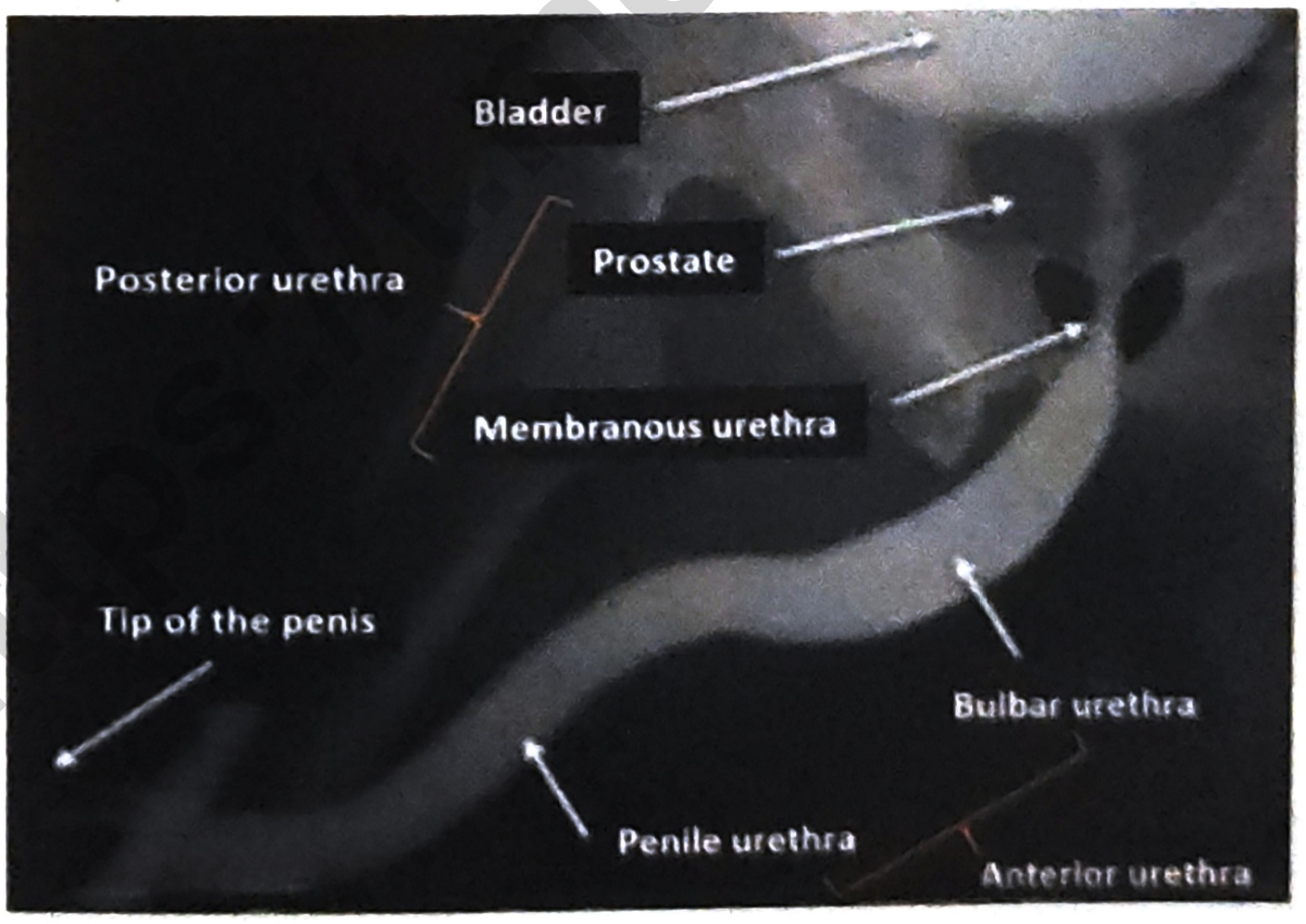

Radiographic anatomy on RGU

https://t.me/Latestneetpgnotes

PrepLadder

Voiding study showing reflux into a ureter on the left side.

Bladder injuries 00:43:44	
Intra-peritoneal Bladder rupture	Extra-peritoneal Bladder rupture
→ Contrast extravasates into the Peritoneal folds & between bowel loops	→ Contrast extravasates only in the Perineum – Gives Molar Tooth sign

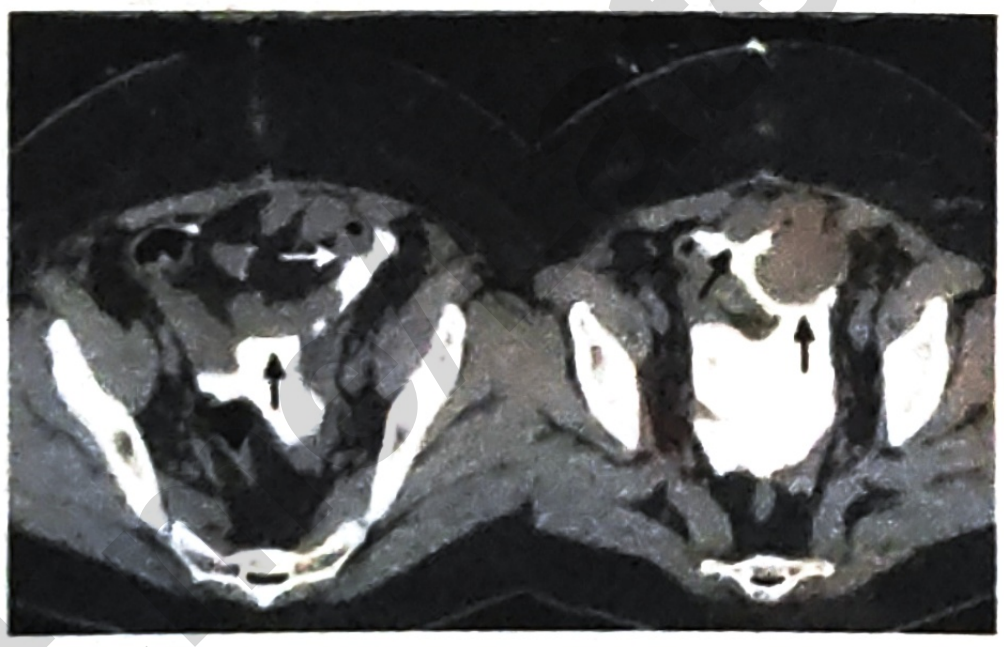

Extravasation of contrast into the Peritoneal folds & between bowel loops

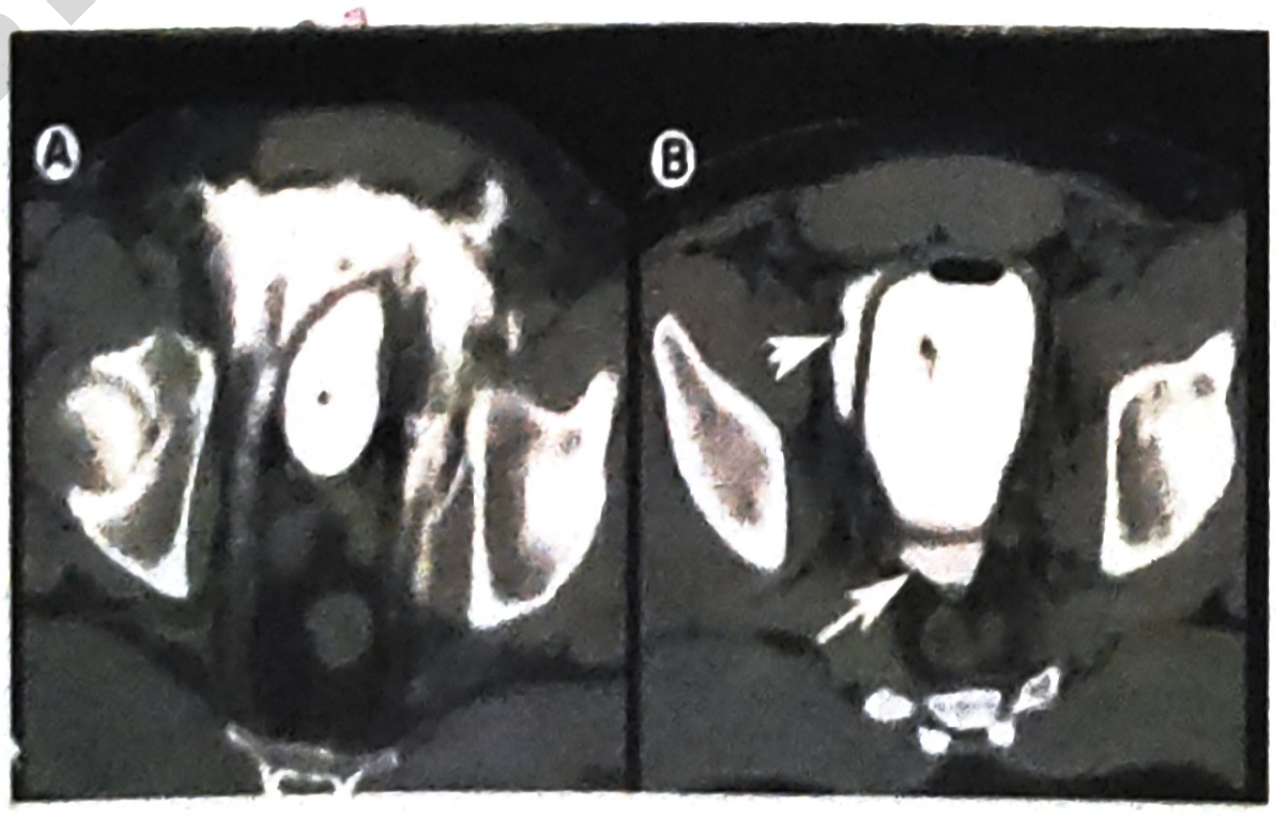

Molar Tooth sign

https://t.me/latestneetpgnotes
PrepLadder

Genito Urinary Radiology

Schistosomiasis

- Fetal skull like Calcification of bladder
- Risk factor for SCC of bladder

Horse shoe kidney

- Gives shaking hand sign & flower vase sign on IVP

Ureterocele

- Gives adder head or cobra head appearence on IVP

ADPKD

Findings
- Swiss cheese nephrogram appearance on
- Spider leg appearance on pyelogram

Renal TB

IOC for renal TB-CECT

In kidney:
- Earliest : moth eaten calyces (on IVP)
- Putty kidney / cement kidney

In Ureter:
- Beaded / tortuous / cork screw appearance
- Kerr's kink
- On cystoscopy - golf hole ureteral orifice

In bladder
- Thimble bladder

https://t.me/Latestneetpgnotes

Chapter 28

MUSCULOSKELETAL RADIOLOGY - PART 1

00:00:25

Turner's syndrome	Pseudohypoparathyroidism
→ Has short 4th Metacarpal	→ Has short 4th & 5th metacarpal

Acromegaly

00:01:35

→ Characterized by

- Broadening of the distal Phalanges - Spade like phalanges
- Increase Heel pad thickness

Spade like phalanges

https://t.me/Latestpgnotes

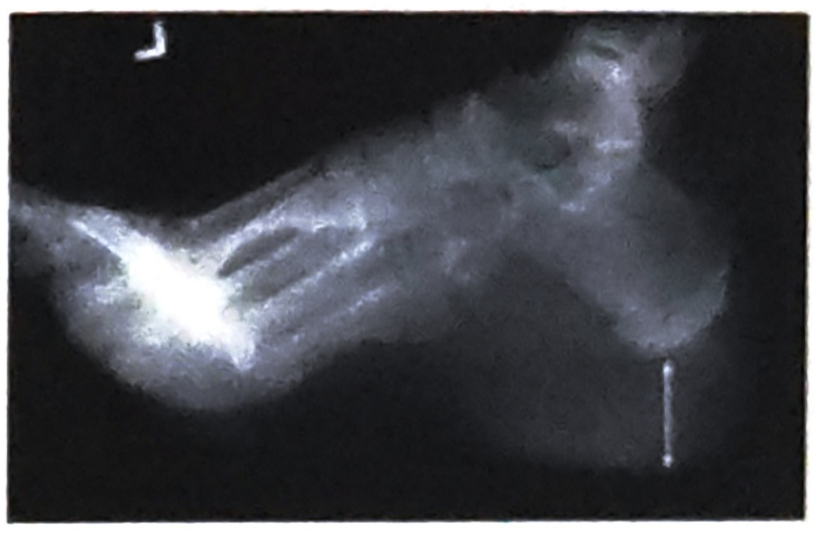

Increased Heel pad thickness

00:04:15

Matrix of Bone	
Osteoid matrix	**Chondroid matrix**
→ Has dense cloudy matrix	→ Shows 1) Rings & Arcs (O & C) 2) Stippled appearance 3) Flocculent or Popcorn appearance
 → Osteosarcoma - showing dense cloudy matrix	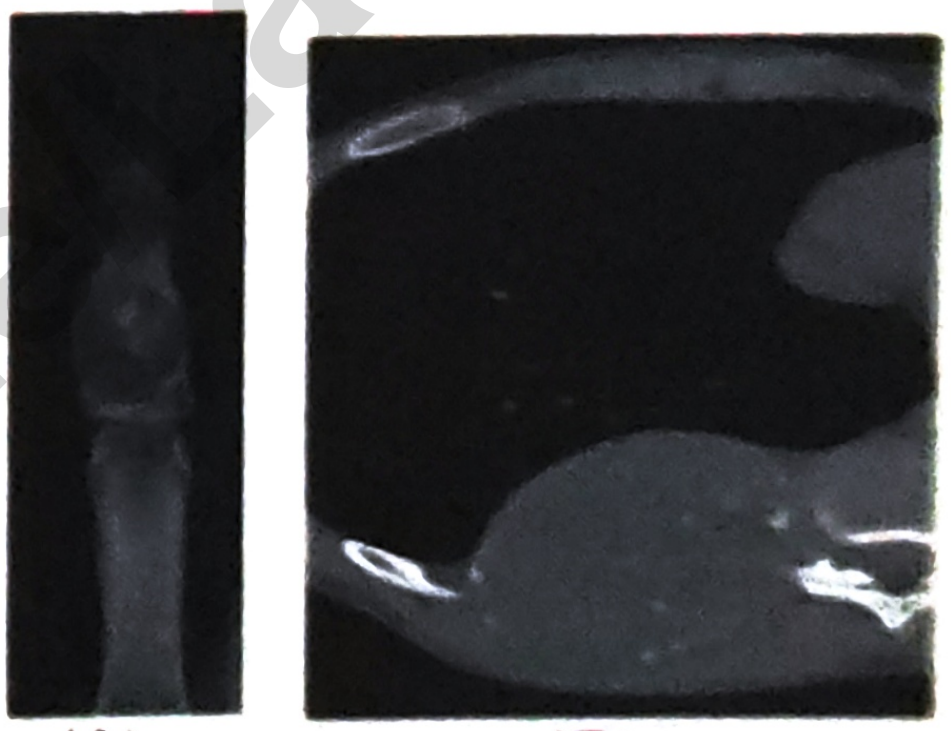 (A) (B) A. Enchondroma showing Rings & Arc B. Chondrosarcoma showing stippled Calcifications C. Chondrosarcoma showing Flocculent or calcifications

https://t.me/latestneetpgnotes

PrepLadder

Popcorn Appearance

→ On Pelvic radiograph	– Chondrosarcoma
→ On Chest radiograph	– Pulmonary hamartoma
→ On Mammography	– Fibroadenoma
→ On MRI Brain	– Cavernous angioma

Chondroblastoma

- → Aka CODMANS tumor
- → Epiphyseal in origin
- → Involves Upper end of humerus

Chondroblastoma

Periosteal reaction

00:08:28

- Benign
  - ↓ Solid Periosteal reaction
- Aggressive
  - ↓ Lamellated → Onion Peel Appearance → Ewing's sarcoma
  - ↓ Spiculated → Sunray Appearance → Osteosarcoma
  - ↓ Codman's triangle → Osteosarcoma

https://t.me/Latestneetpgnotes

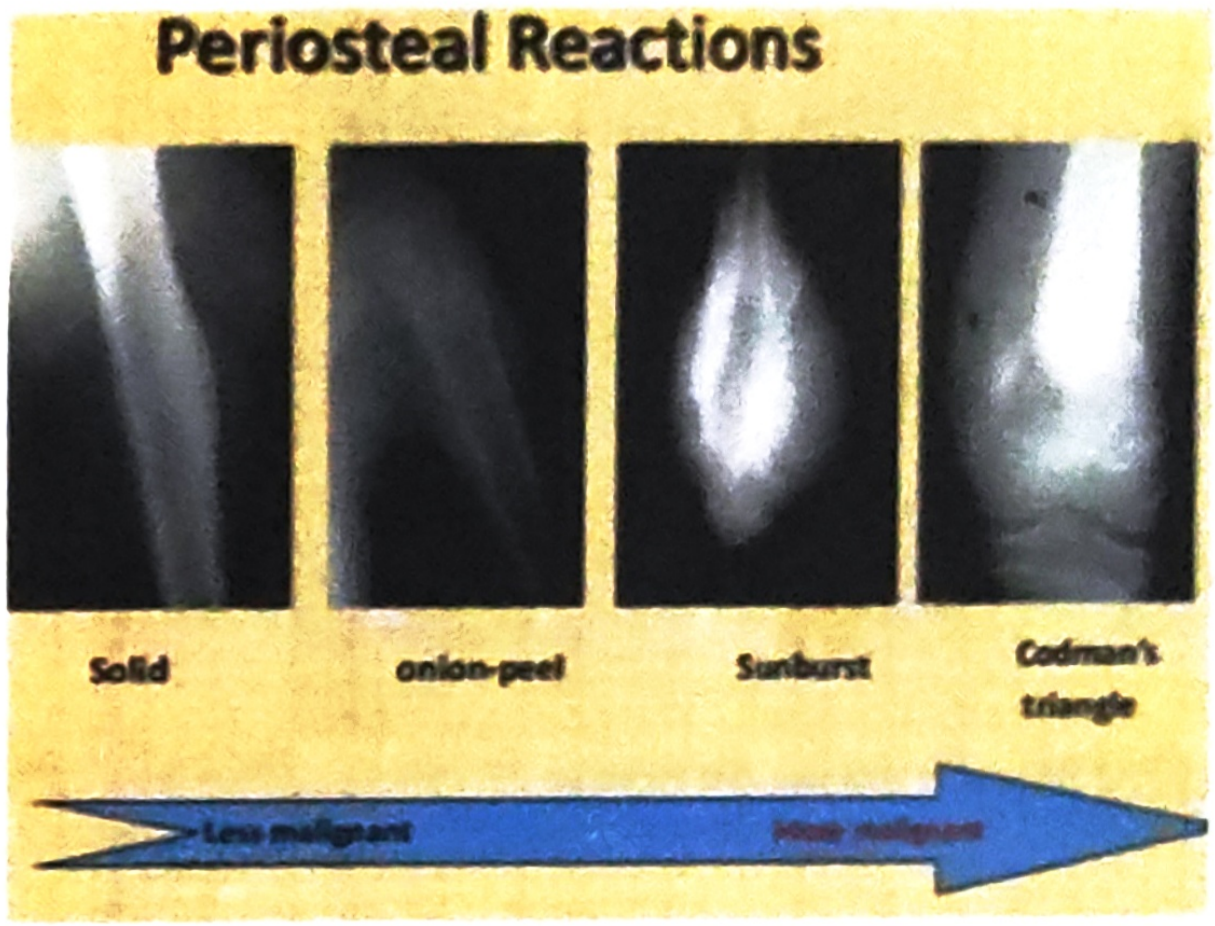

Enchondroma

- → Ring and Arc chondroid lesions present in phalanges with chondroid matrix
- → Ollier's disease - Characterized by Multiple enchondromas
- → Maffucci's syndrome - Characterized by Multiple enchondromas + Soft tissue hemangioma

Enchondroma - with multiple Rings & Arcs

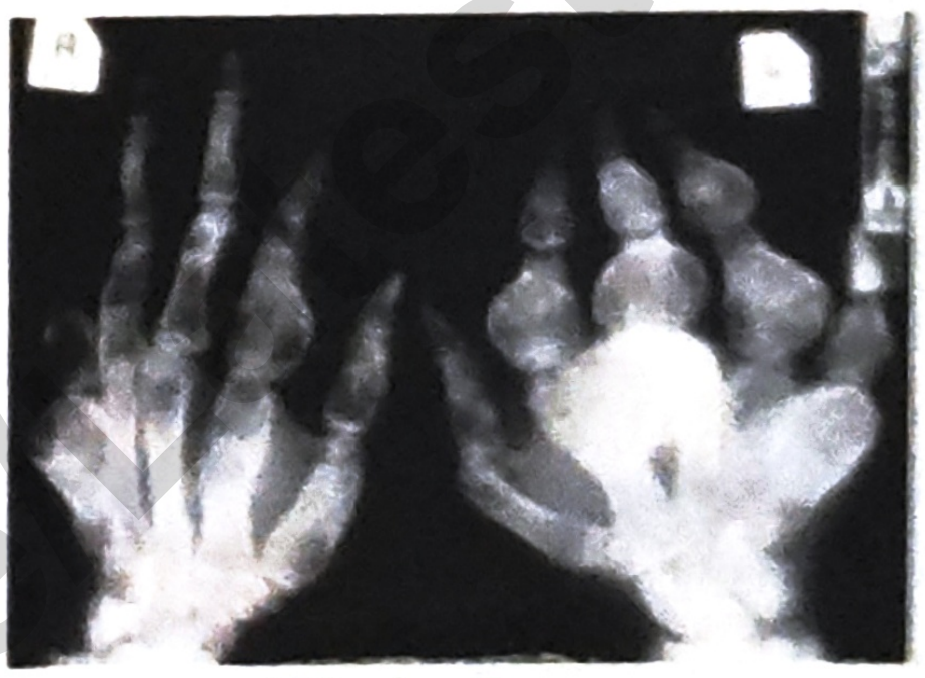

Ollier's disease

Maffucci's syndrome

https://t.me/neetpgnotes

PrepLadder

Exostosis 00:12:10

- → Triangular bony projection in upper end of tibia or lower end of femur - Known as Exostosis
- → Aka Osteochondroma
- → covered by cartilaginous cap that is evaluated by MRI
- → Cartilaginous cap has premalignant potential - can lead to Chondrosarcoma
- → Diaphyseal Aclasia - Characterized by Multiple exostosis

Exostosis / Osteochondroma

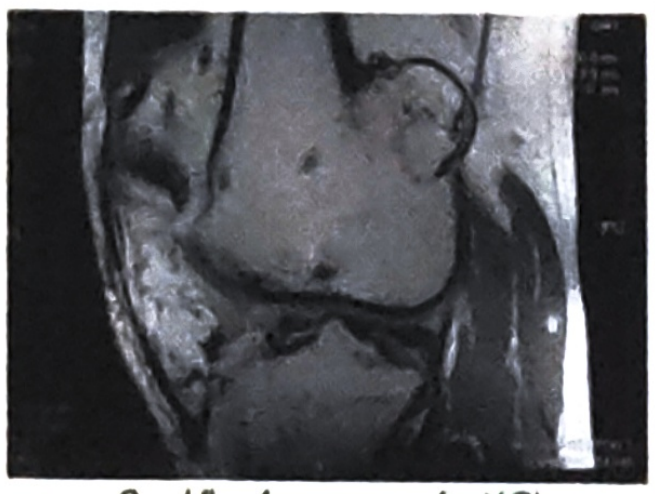
Cartilaginous cap in MRI

Diaphyseal Aclasia

Fibrous dysplasia 00:14:03

- → Characterized by
  - Ground glass opacities + Rind sign (sclerotic rim around glass opacities)
  - Shepherd crook deformity
- → Has increased proliferation of cancellous / Spongy bone
- → Shows Hot uptake on bone sign - due to increased Osteoblastic activity

Shepherd crook deformity

https://t.me/Latestneetpgnotes

PrepLadder

Ground glass opacities+
Rind Sign

Note:

→ Fibrous dysplasia + café' au lait spots + Precocious puberty in female - McCune Albright syndrome

→ Fibrous dysplasia + Intramuscular myxomas - Mazabraud Syndrome

<table>
<tr>
<td>

Vertebral Hemangioma

→ Radiological Features

- On Sagittal view - - shows vertical striation on the vertebral body Known as Corduroy appearance
- On Axial view - show polka dot sign

</td>
<td>

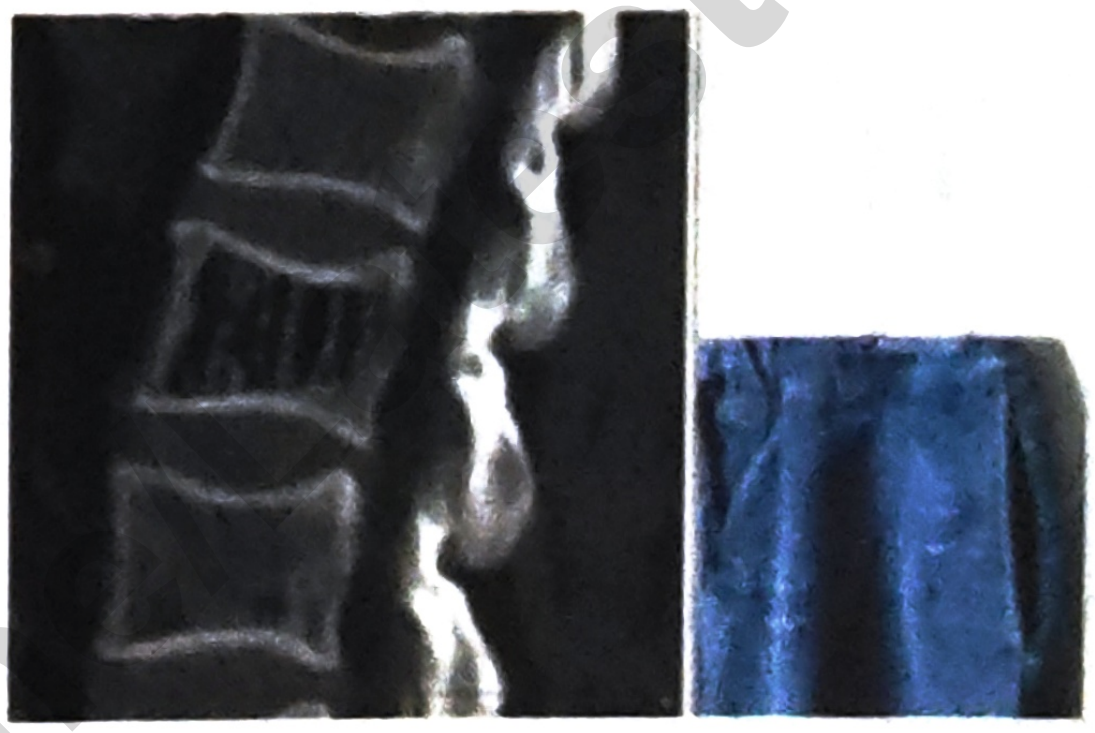

Corduroy appearance

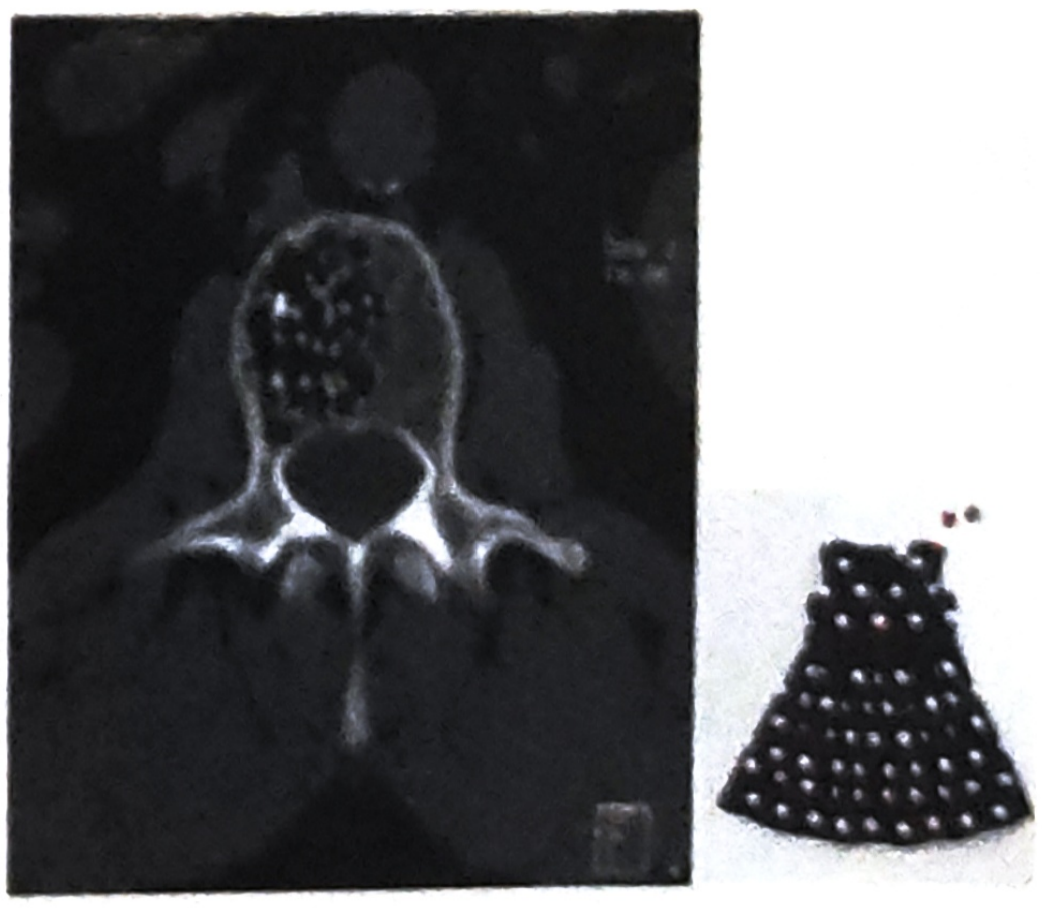

Polka dot sign

</td>
</tr>
</table>

https://t.me/neetpgnotes

Vertebral metastasis • Shows "WINKING OWL SIGN" Normally - Spinous process appears like beak of owl and pedicles appear like eye of owl • Damage to pedicles of vertebrae because of metastasis cause this sign	 Winking owl sign

Eosinophilic Granuloma 00:27:33

→ Radiological findings

- Vertebra plana - Flattening of vertebral body
- Beveled edges of skull - Asymmetric erosion of inner and outer table
- Button sequestrum - Sclerotic area in the center of beveled edges
- Floating teeth of mandible - due to lysis of mandible
- Geographical skull - multiple fusing lucencies producing map like area on the skull

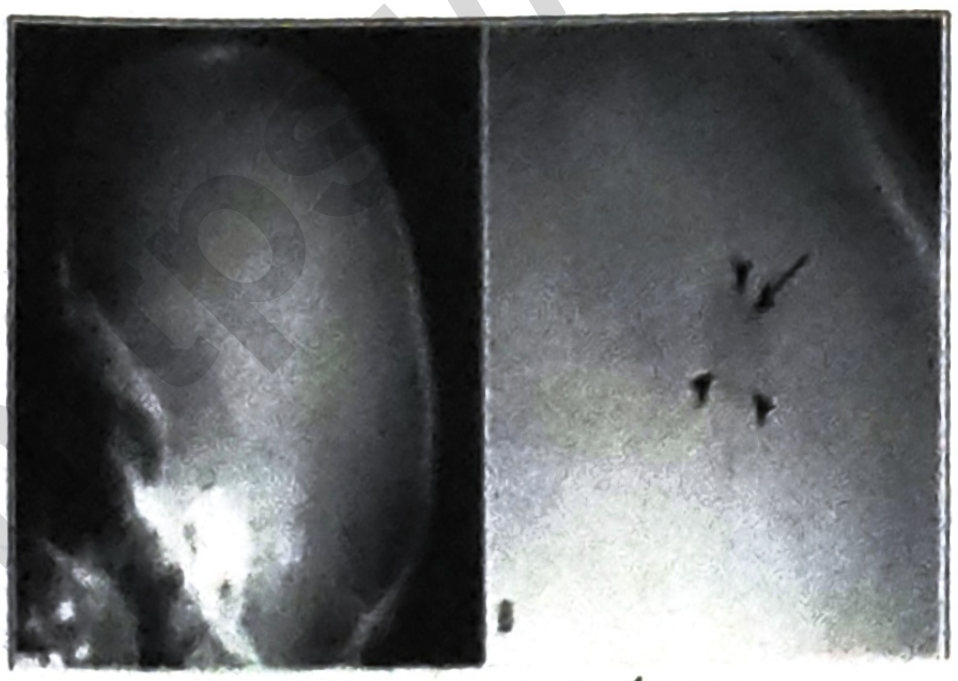 Button sequestrum	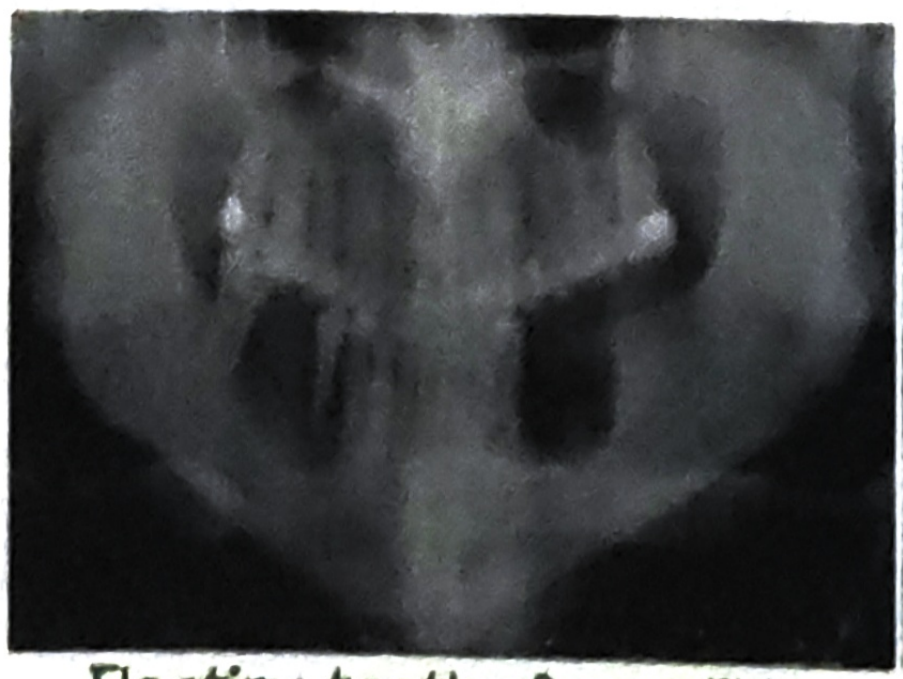 Floating teeth of mandible

https://t.me/Latestneetpgnotes

PrepLadder

Osteoporosis Circumscripta

- Focal area of osteoporosis in skull
- Feature of Paget's disease (lytic phase)

Cotton wool skull

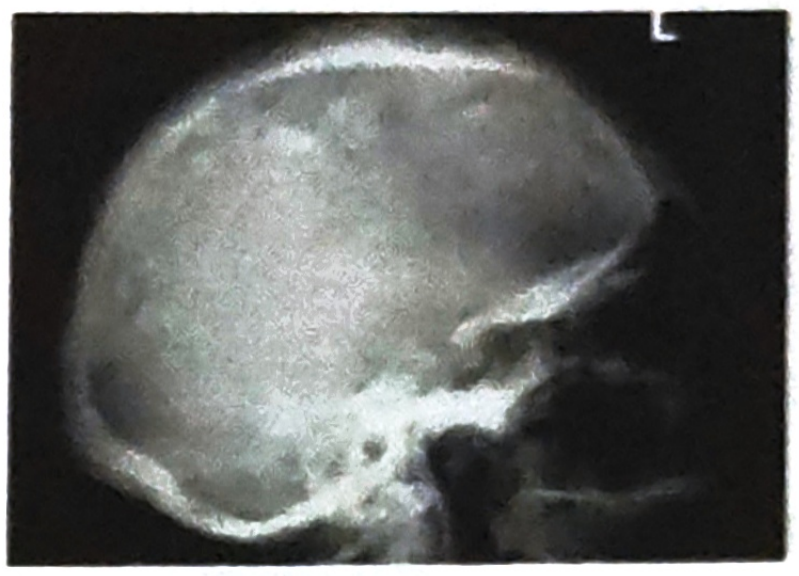

- Feature of Paget's disease (Mixed phase)

Tam'O Shanter sign (Dense sclerotic skull)

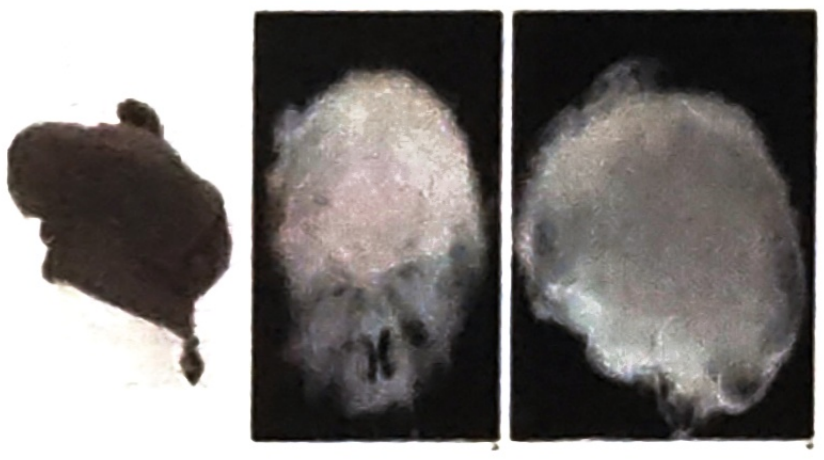

- Feature of Paget's disease (Sclerotic phase)

Geographical skull

- Feature of Eosinophilic granuloma

Raindrop skull

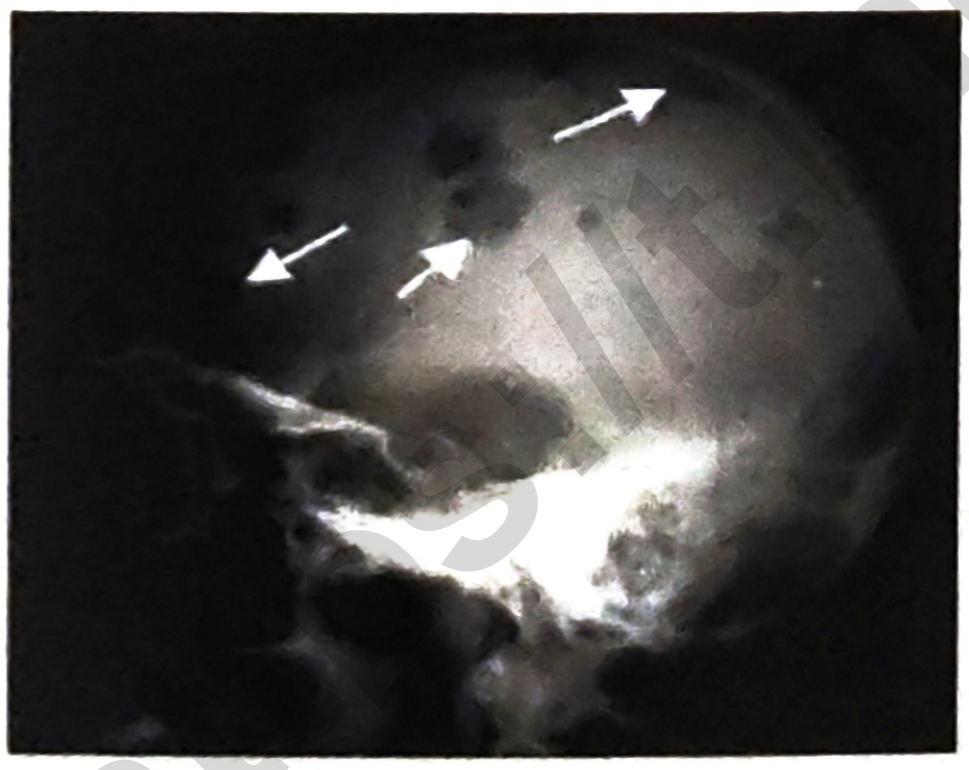

- Varying size , scattered lucency
- Feature of Multiple myeloma

Pepper pot skull

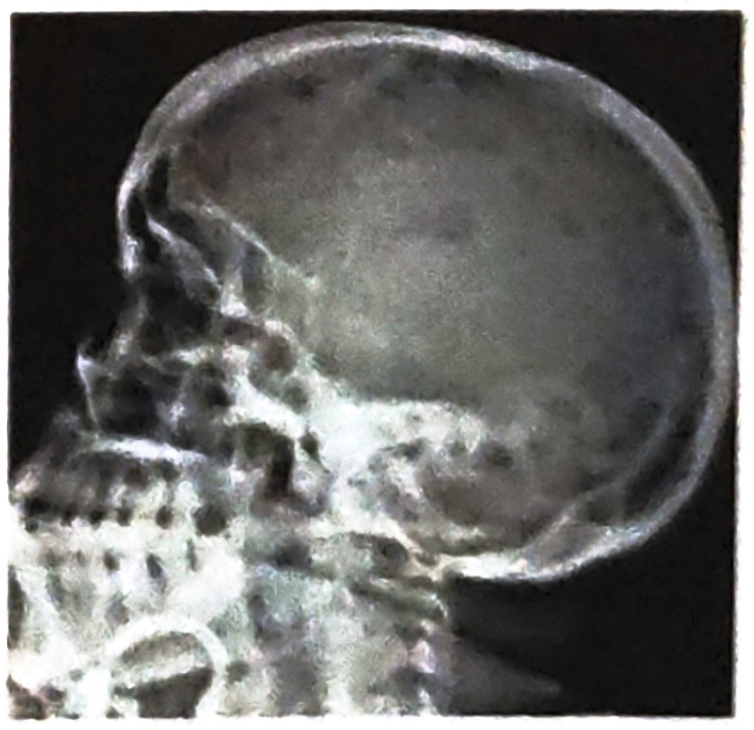

- Uniform small lucencies and appears like pepper pot
- Feature of Hyperparathyroidism

PrepLadder

Salt and pepper skull	Crew out / hair on end appearance
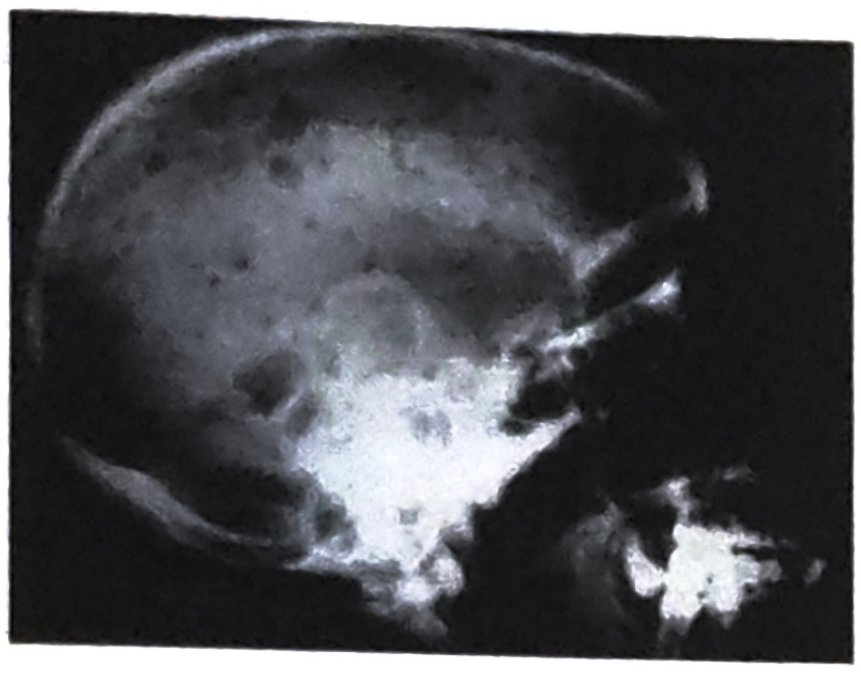 • Feature of hyperparathyroidism	• Feature of Thalassemia

Radiological features seen on Various Vertebral pathologies

H - shaped vertebra	Fish mouth / Cd fish vertebra
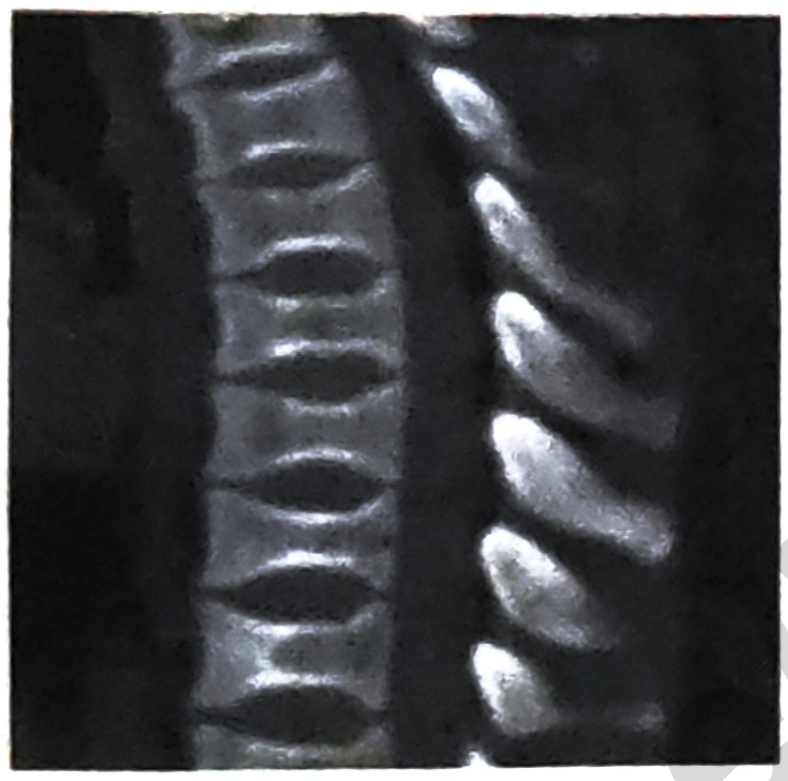 • Seen in Sickle cell anemia	• Seen in Sickle cell anemia & Osteoporosis
Bullet shaped vertebra	**Sandwich vertebrae**
• Feature of Achondroplasia	• Feature of Osteopetrosis

https://t.me/Latestpgnotes

PrepLadder

For more free ebooks and notes, visit

https://t.me/Latestneetpgnotes

Or click this page to join

Rugger jersey spine	Picture frame vertebra
 • Seen in Renal osteodystrophy & Osteopetrosis	 • Seen in Paget's disease (mixed Phase)
→ Dense sclerotic vertebra / ivory vertebra • Paget's disease (sclerotic phase) • Hodgkin's Lymphoma • Osteoblastic metastasis	

Ligaments supporting the vertebra

00:33:08

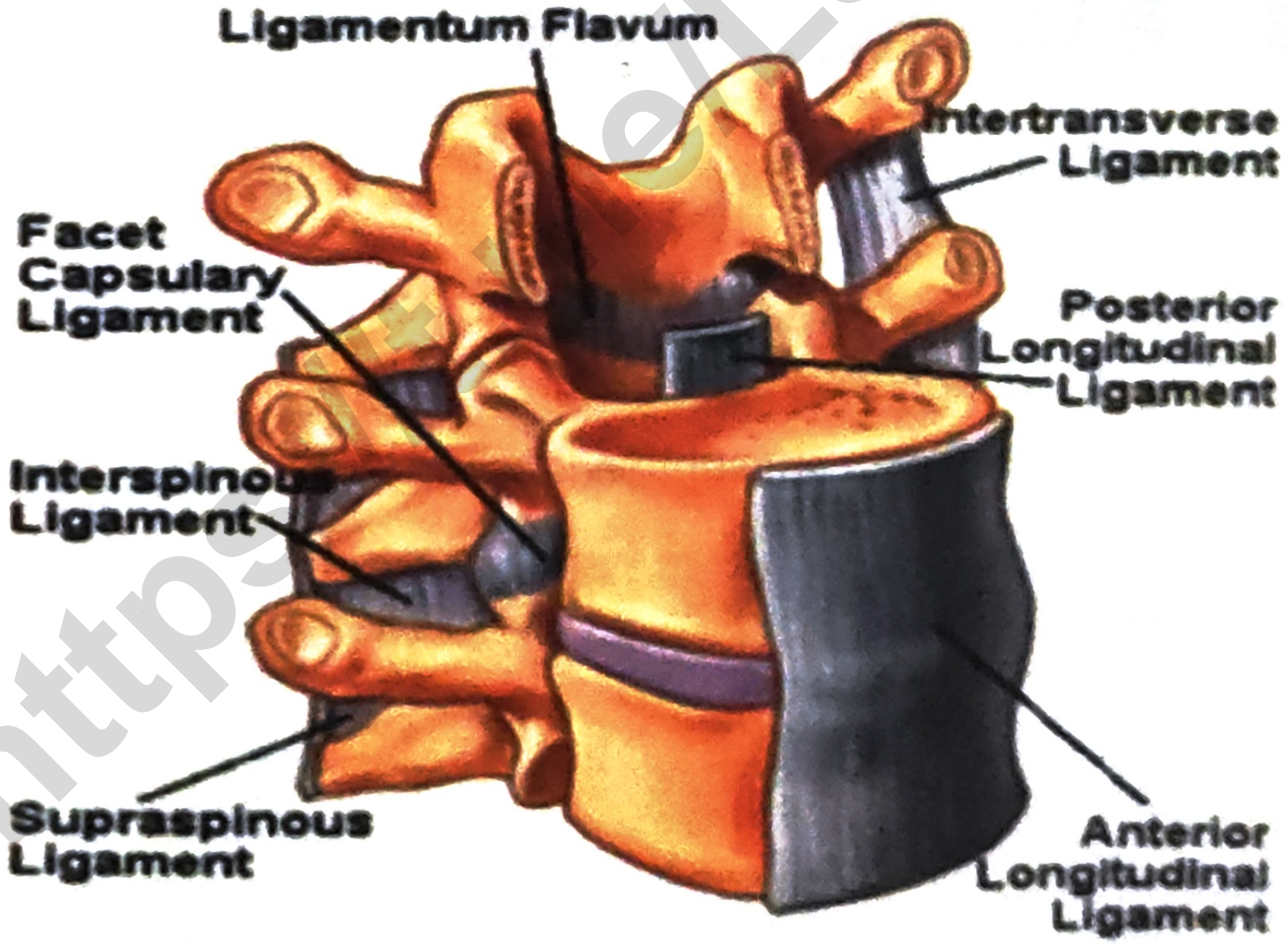

https://t.me/Latestpgnotes

PrepLadder

Calcification of Anterior longitudinal ligament → Feature of DISH (Diffuse idiopathic skeletal hyperostosis)	Calcification of posterior longitudinal ligament 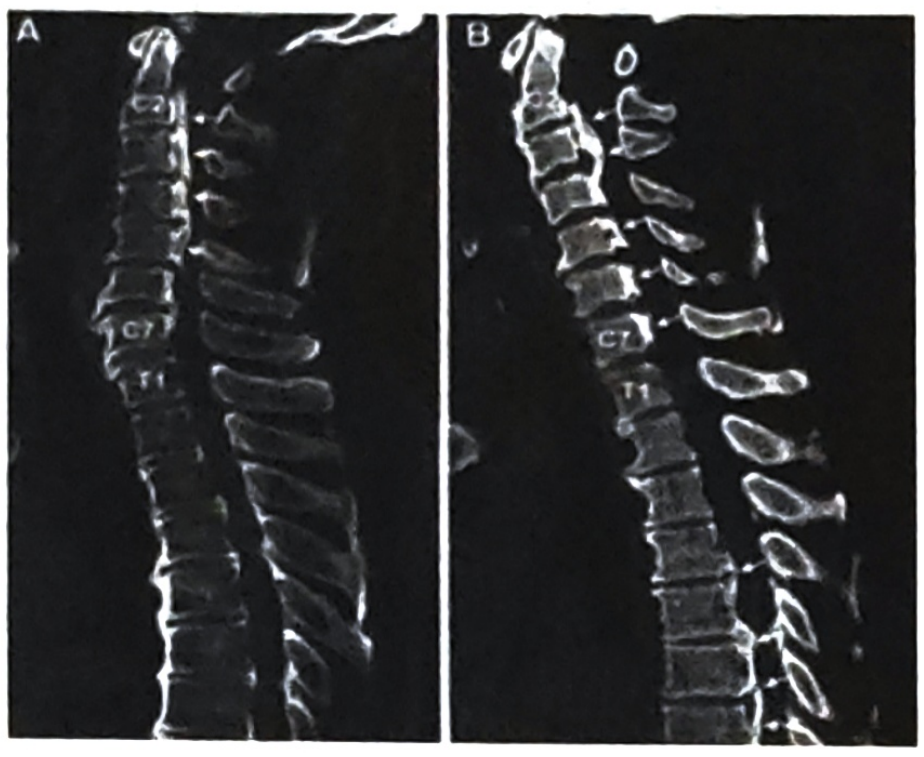 → Feature of Japan's disease - shows ossified Posterior longitudinal ligament
Calcification of interosseous membrane → Feature of Fluorosis	Meniscal calcification 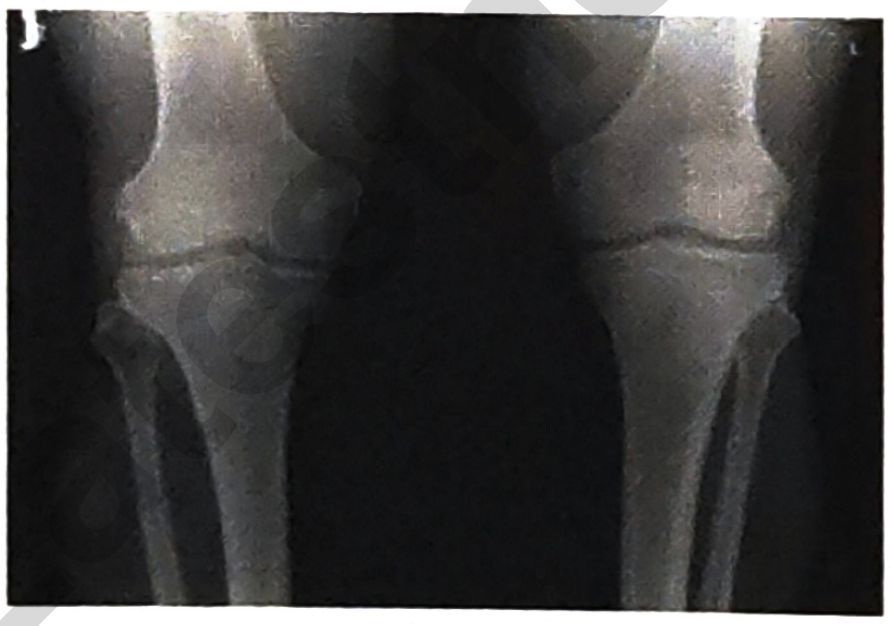 → Feature of Pseudogout / Chondrocalcinosis → MC site involved in pseudogout - knee Joint → Calcium pyrophosphate is deposited which is responsible for calcification.

Intervertebral disc calcification

- → Feature of Alkaptonuria / Onchronosis (deficiency of Homogentisate dioxygenase)
- → Also seen in Ankylosing spondylitis (But only periphery of intervertabral disc is calcified - gives bamboo spine appearance)

https://t.me/Latestneetpgnotes

PrepLadder

Alkaptonuria

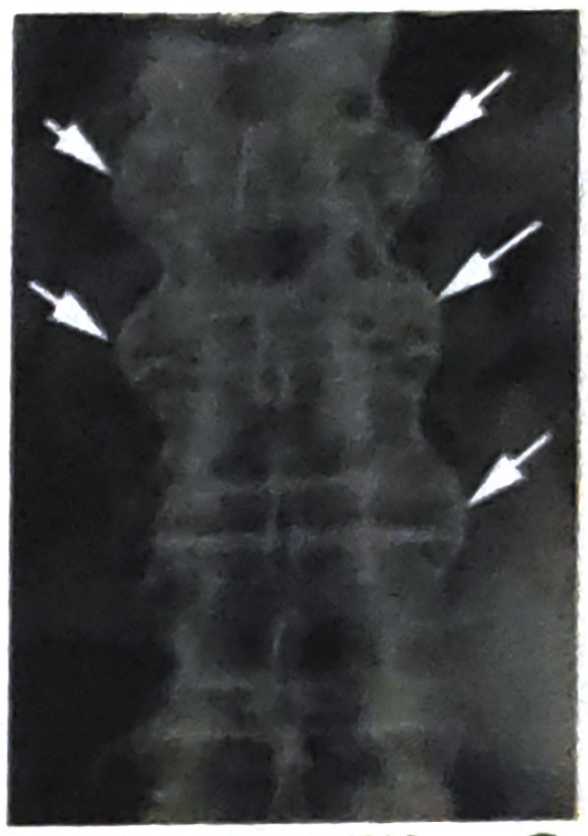

Ankylosing spondylitis – Bamboo spine

Ankylosing spondylitis

00:38:00

→ Earliest finding - Sacroiliitis

→ IOC for diagnosis - STIR - MRI

→ Radiological findings

- Bamboo spine
- Dense Calcification of interspinous ligament - Dagger spine
- Trolley track / Tram track appearance - Peripheral calcification of intervertebral disc & calcification of interspinous ligament
- On MRI - Shows Bilateral symmetrical Sacroiliitis

→ Other features seen are

- Enthesitis
- Romanus lesion
- Shiny corner sign
- Squaring of vertebra

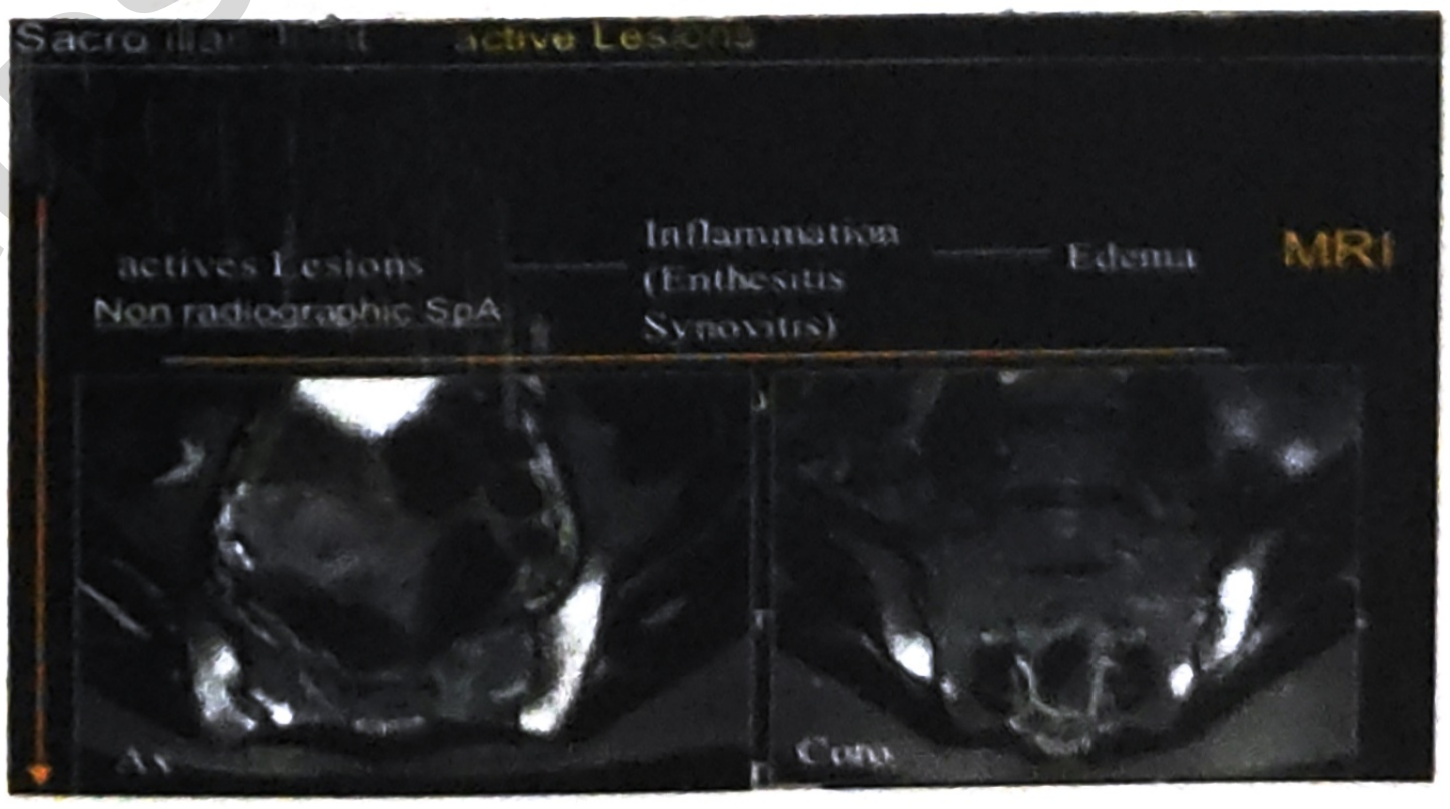

https://t.me/Latestneetpgnotes

PrepLadder

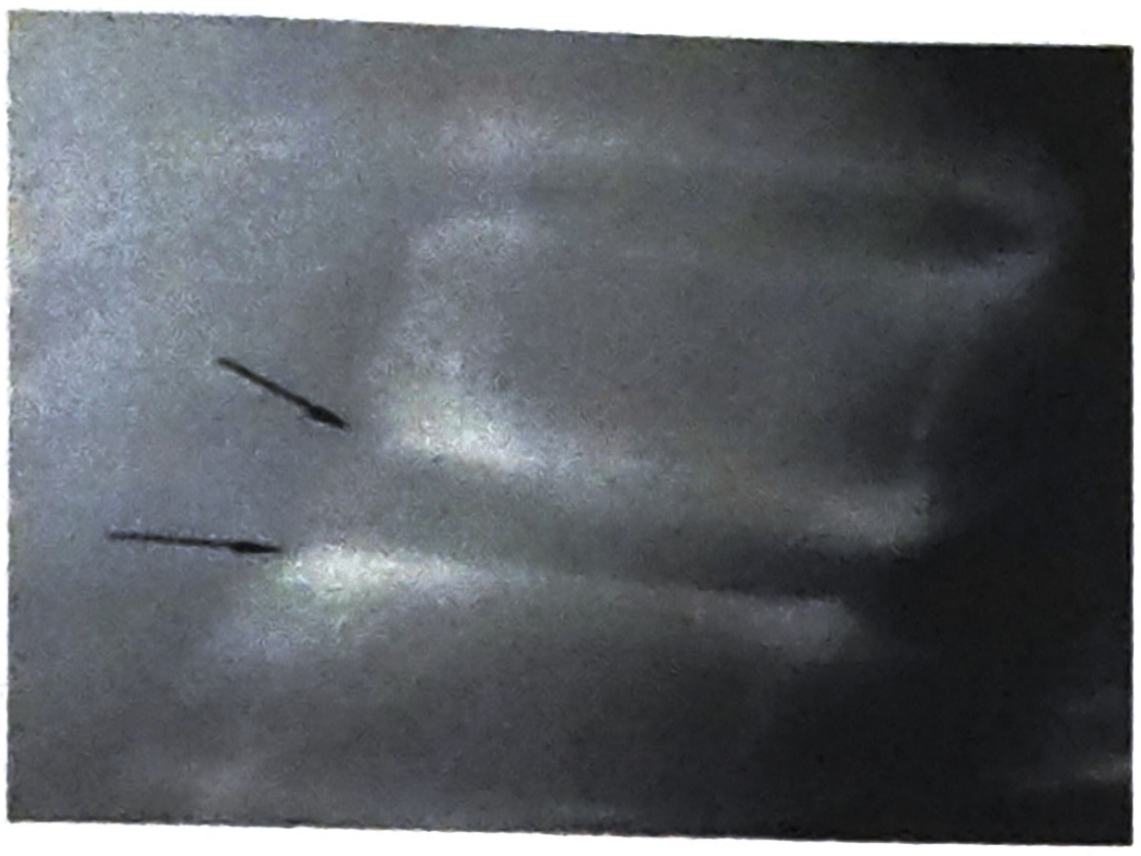	
Romanus lesion	Dagger spine

Sequence of vertebral changes in Ankylosing spondylitis

Enthesitis ↓	Inflammation along site of insertion of tendons and ligaments or vertebrae	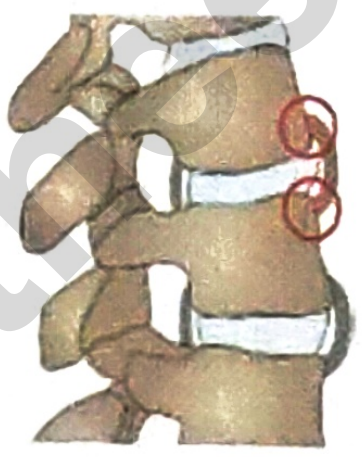
Romanus lesion ↓	Erosions along the edges of vertebra	
Shiny corner sign ↓	After repair, sclerosis occurs in corner of vertebra	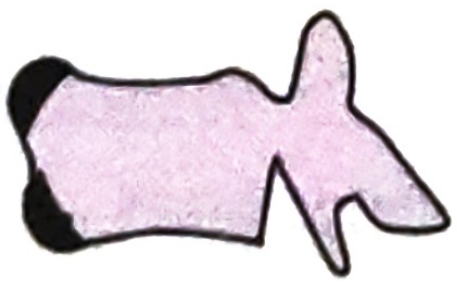
Squaring of vertebra	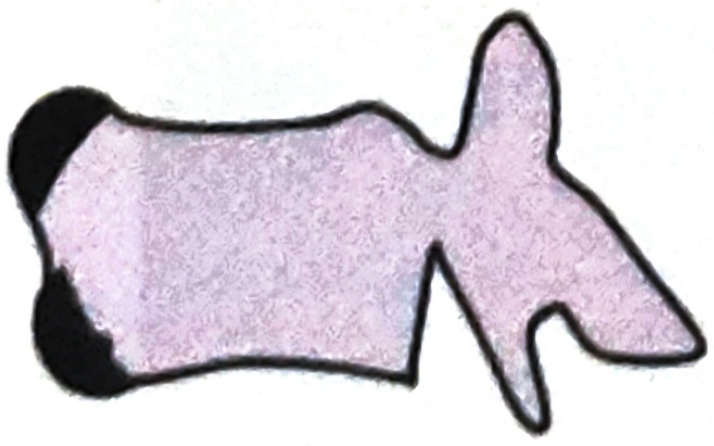	

https://t.me/Latestpgnotes

PrepLadder

Note:

	Vertebral morphology	Seen in
	• Antero inferior beaking of vertebrae	→ Hurler's syndrome (MPS)
	• Central breaking of vertebrae	→ Morquio syndrome (MPS)
	• Posterior scalloping of vertebral body	→ Intramedullary tumors (spinal cord tumor) → Neurofibroma → Achondroplasia
	• Anterior scalloping of vertebral body	→ Aortic aneurysm

Osteomyelitis

→ **Acute Osteomyelitis**

- MCC of Acute Osteomyelitis - Staph aureus
- IOC for Acute Osteomyelitis - MRI

→ **Chronic osteomyelitis**

- Dead dense bone in center known as sequestrum
- Periosteal new bone formation – Involucrum

Chronic osteomyelitis

PrepLadder
https://t.me/Latestneetpgnotes

Tuberculous Arthritis

→ Characterized by - Phemister Triad

- Decreased by Joint space
- Erosions
- Osteopenia

→ TB Hip

- Radiological findings
  - Wandering acetabulum
  - Mortar or Pestle appearance

Decreased Joint

Erosions

Osteopenia

Mortar or Pestle appearance

https://t.me/Latestpgnotes

Chapter 29

MUSCULOSKELETAL RADIOLOGY - PART 2

Rickets 00:00:18

→ Vitamin D deficiency

→ Decreased mineralization of bones

→ Earliest finding of Rickets

- Loss of Provision zone of calcification

↓

Epiphysis compresses over metaphysis causing metaphysis to undergo

- Cupping (deepening of metaphysis)
- Splaying (broadening of metaphysis)
- Fraying (irregularities to metaphysis)

→ Widening of growth plate

→ In Rickets the acetabulum is pulled medially inward known as Protrusio acetabuli

→ Triradiate Pelvis

→ There is combination of gene valgus and genu varus Known as wind swept deformity of Knee.

→ Anterior flaring of ribs (broadening of anterior end attached to costal cartilages) - Rachitic rosary

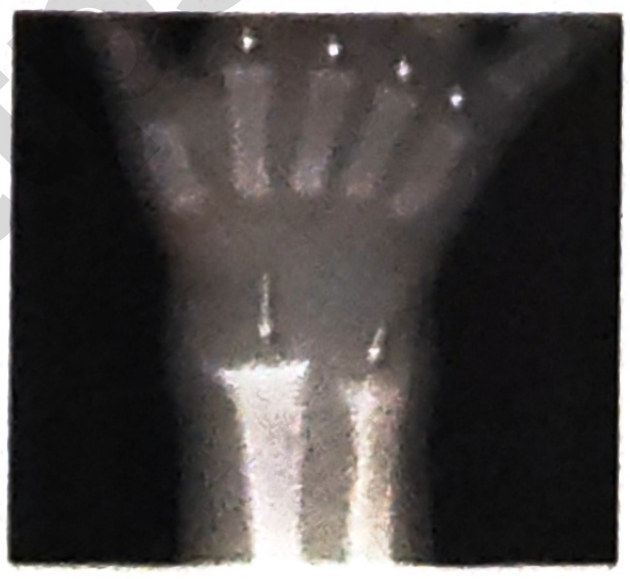

Widening of growth plate, Cupping Splaying and Fraying

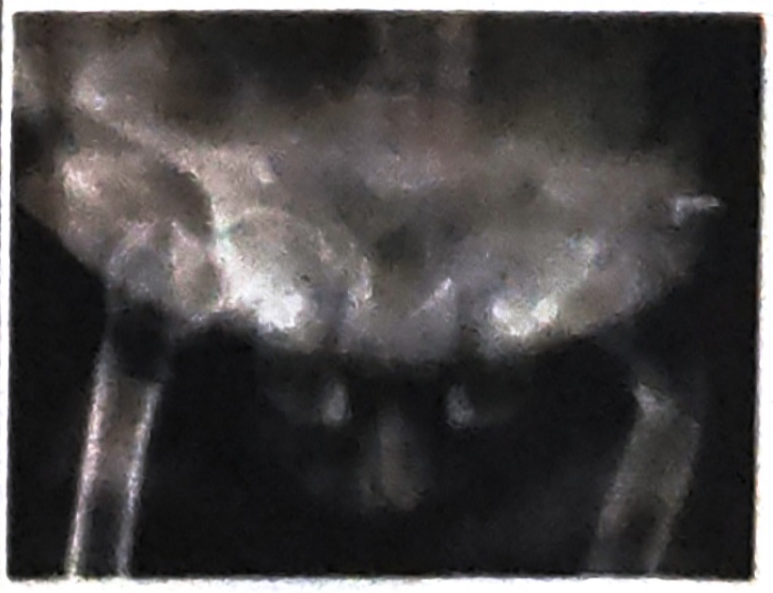

Protrusio Acetabuli & Triradiate Pelvis

https://t.me/Latestneetpgnotes

PrepLadder

Wind swept deformity	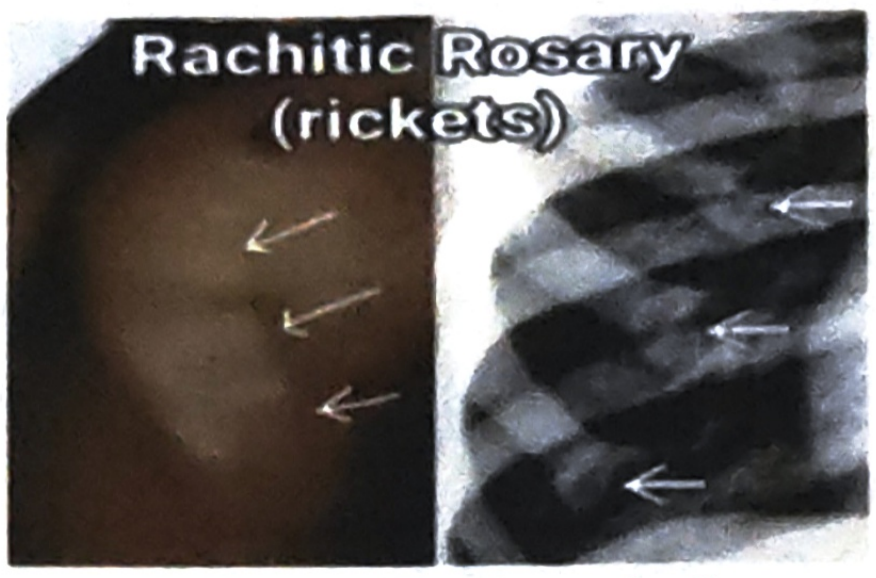 Anterior Flaring of rib

Osteomalacia 00:04:30

→ LOOSER ZONE (lucent weight bearing area involving cortex

→ Aka Pseudo fracture / Milkman fracture

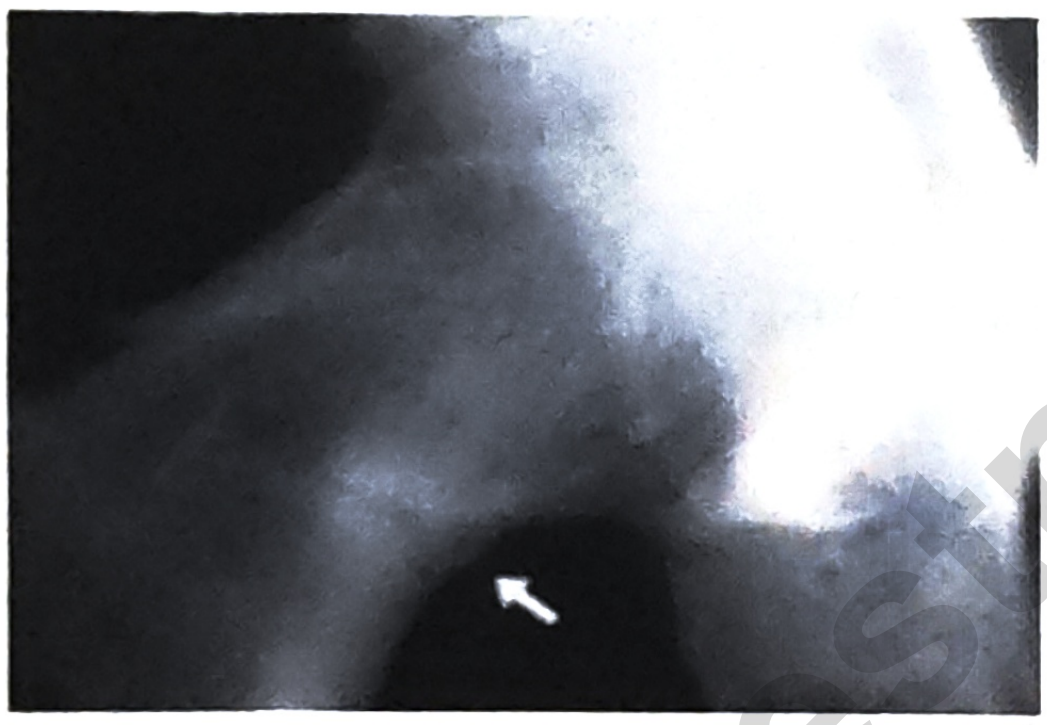

Osteomalacia

00:07:05

Juvenile Rheumatoid Arthritis / stills disease → Epiphyseal enlargement	Epiphyseal enlargement 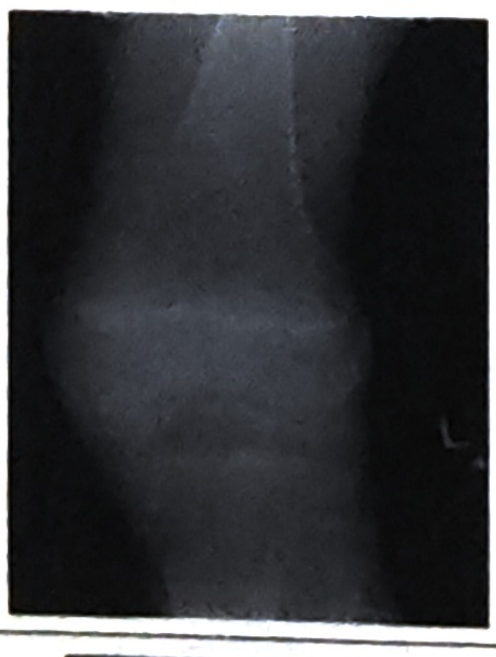
Hypothyroidism → Epiphyseal dysgenesis	Epiphyseal dysgenesis

https://t.me/Latestneetpgnotes

PrepLadder

Wormian bones → Intra sutural bones associated with • Osteogenesis imperfecta • Hypothyroidism	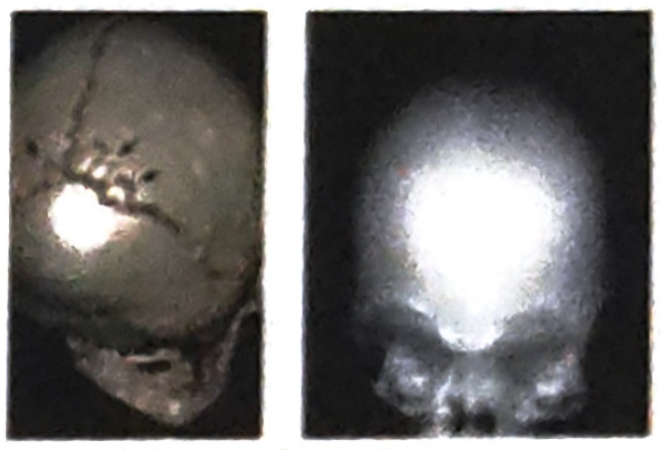 Wormian bones

Scurvy

00:10:58

→ Deficiency of Vitamin C

→ Vitamin C is responsible for lysine and Proline hydroxylation associated with Collagen synthesis

→ Therefore, Defect in collagen Synthesis and Defect in osteoid matrix

→ Radiological findings

- Pencil thin cortex
- Dense provisional zone of calcification.
- White line of Frenkel
- Pelkan spurs
- Trummerfeld zone
- Sub periosteal Hemorrhages
- Wimberger ring

→ Subperiosteal Erosion- feature of Hyperparathyroidism

→ Subperiosteal hemorrhages- feature of Scurvy

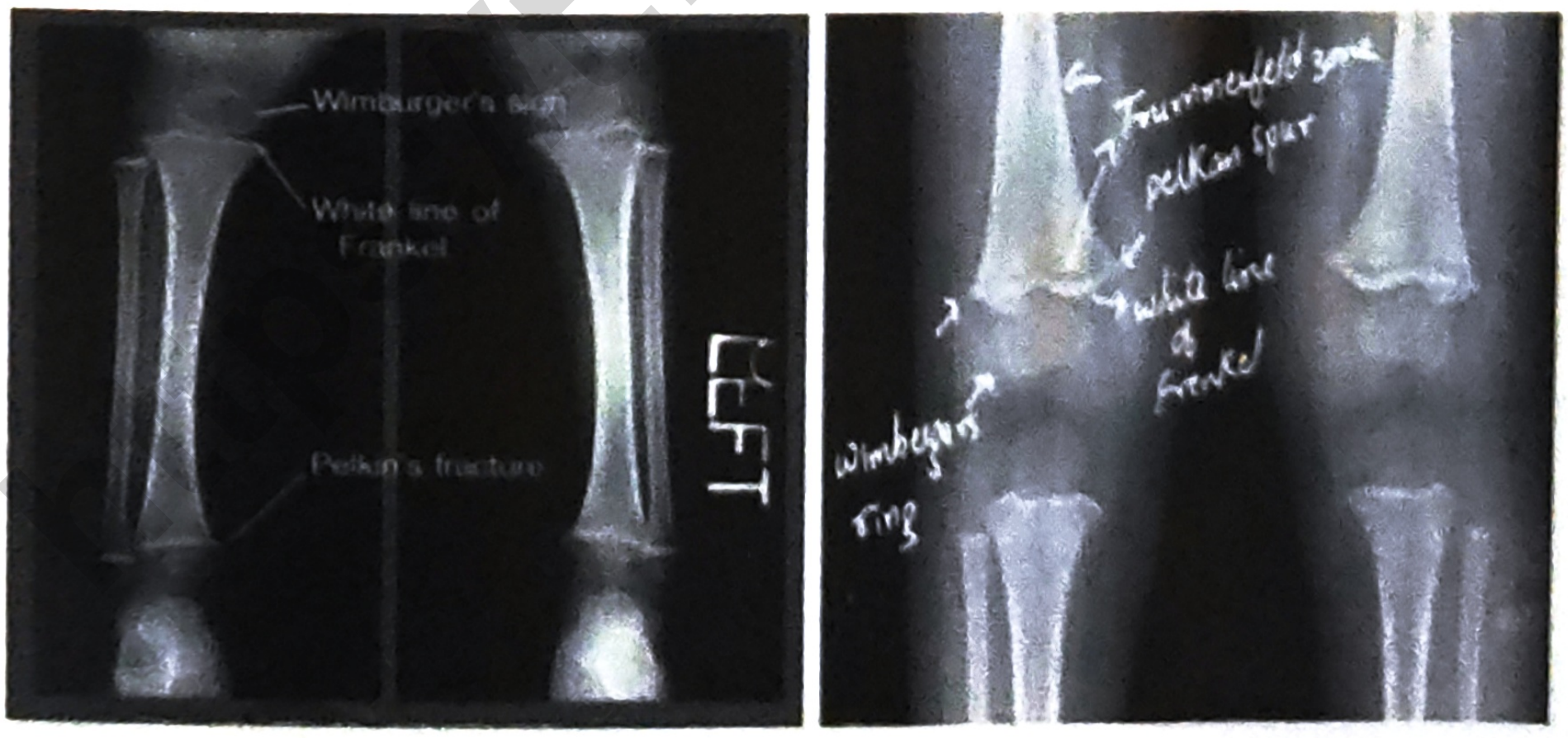

Scurvy

t.me/Latestneetpgnotes

PrepLadder

Radiological Findings in Congenital Syphilis and Rubella 00:14:01

→ Erosion of medial tibial condyle seen in Congenital syphilis

→ In congenital syphilis,

- Sabre tibia – Anterior bowing of tibia
- Clutton Joints – swollen Knee joints

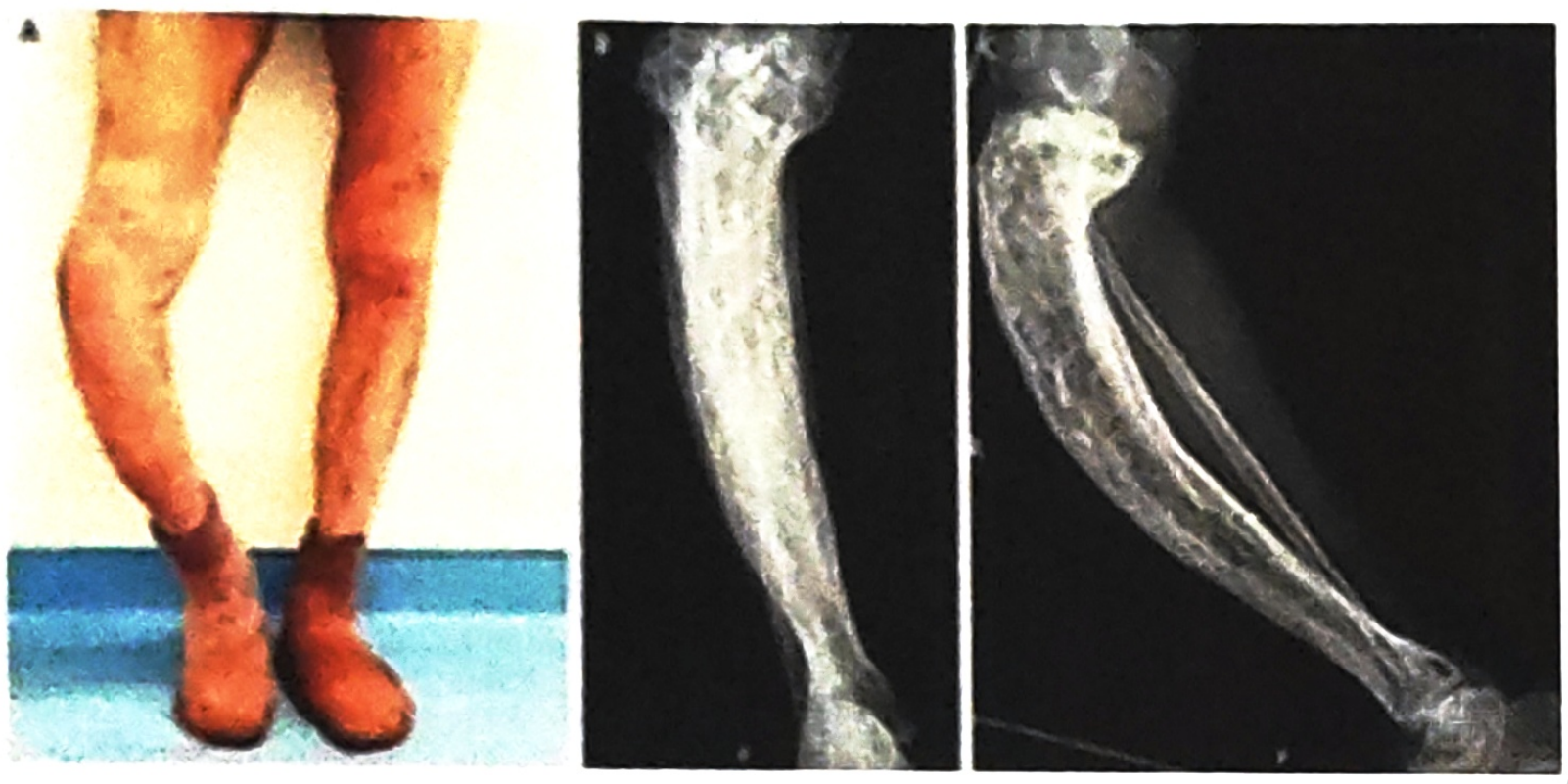

Sabre tibia

Celery stalk appearance

→ Vertical striations at end of long bone

→ Feature of Congenital rubella

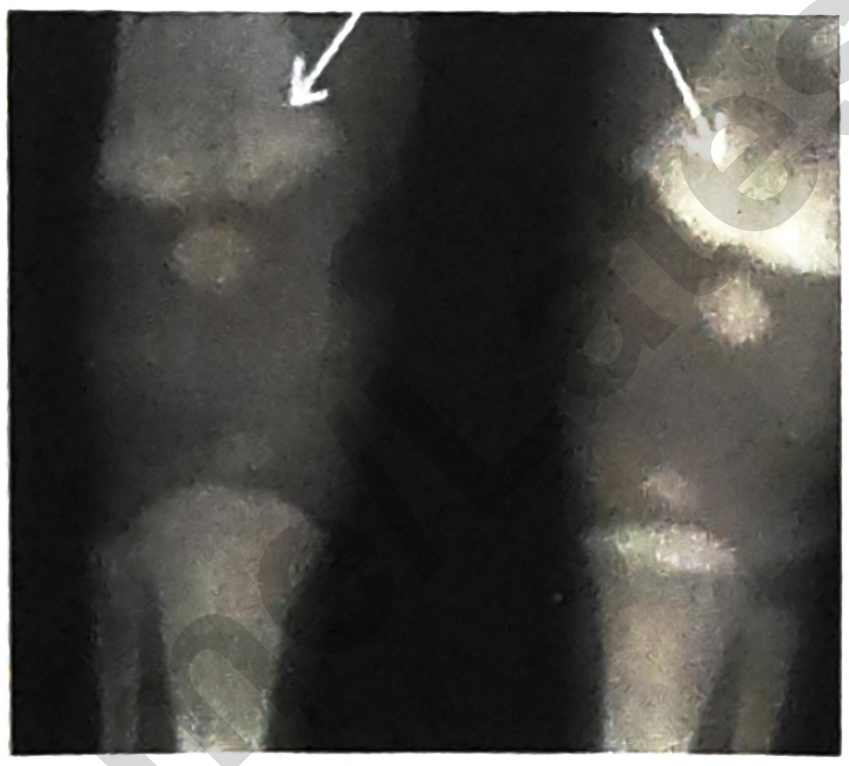

Celery stalk appearance

Fish mouth / Cod fish vertebrae

→ It is a feature of Osteoporosis / Sickle cell anemia

Fish mouth vertebrae

https://t.me/latestneetpgnotes

PrepLadder

Scottish Dog appearance

→ Normal appearance of lumbar spine on posterior oblique view

Scottish Dog Collar Sign

→ Seen in Spondylosis – is Pars interarticularis fracture

Scottish dog appearance	Scottish dog collar sign

Beheaded Scottish dog appearance

→ Along with the fracture of pars interarticularis there is an anterolisthesis

→ Feature of spondylolisthesis

Normal	Spondylosis	Spondylolisthesis

Inverted Napoleon Hat sign

→ Bilateral severe L5, listhesis over S1

→ Spondylolistheses on Frontal view

https://t.me/Latestneetpgnotes

PrepLadder

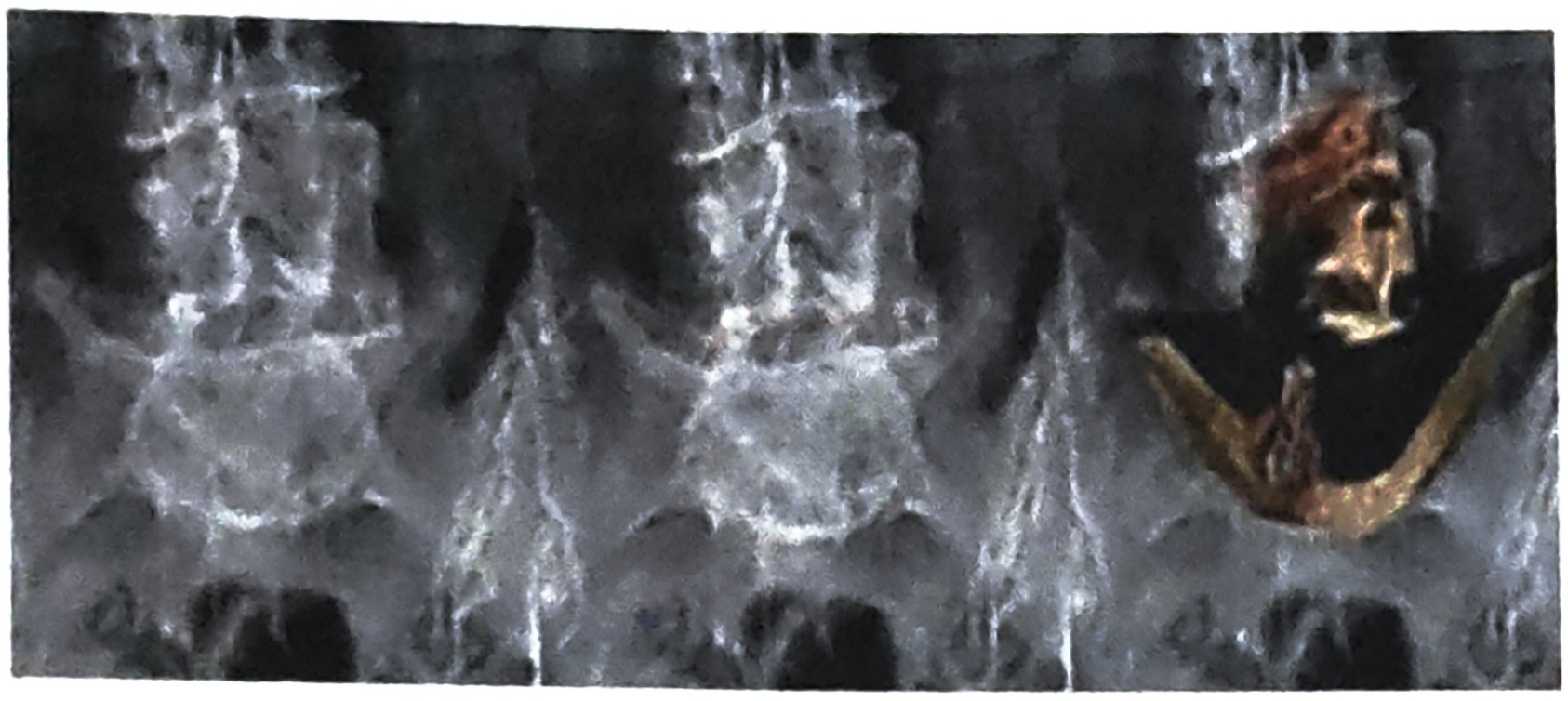

Inverted napoleon hat sign

Osteoporosis

00:19:35

→ ↓ Bone mineral density

→ Bone mineral density is measures by

- DEXA scan (females › 65 years)

DEXA scan	
T-score (Healthy young individual) ↓ Defined by WHO(	Z-score (same age group)

Osteoclastoma/ Giant Cell Tumor

00:22:32

→ Soap bubble appearance around the Knee Joint

→ Epiphysiometaphyseal, Subarticular, eccentric

→ Occurs only after fused growth plate is › 20 years age

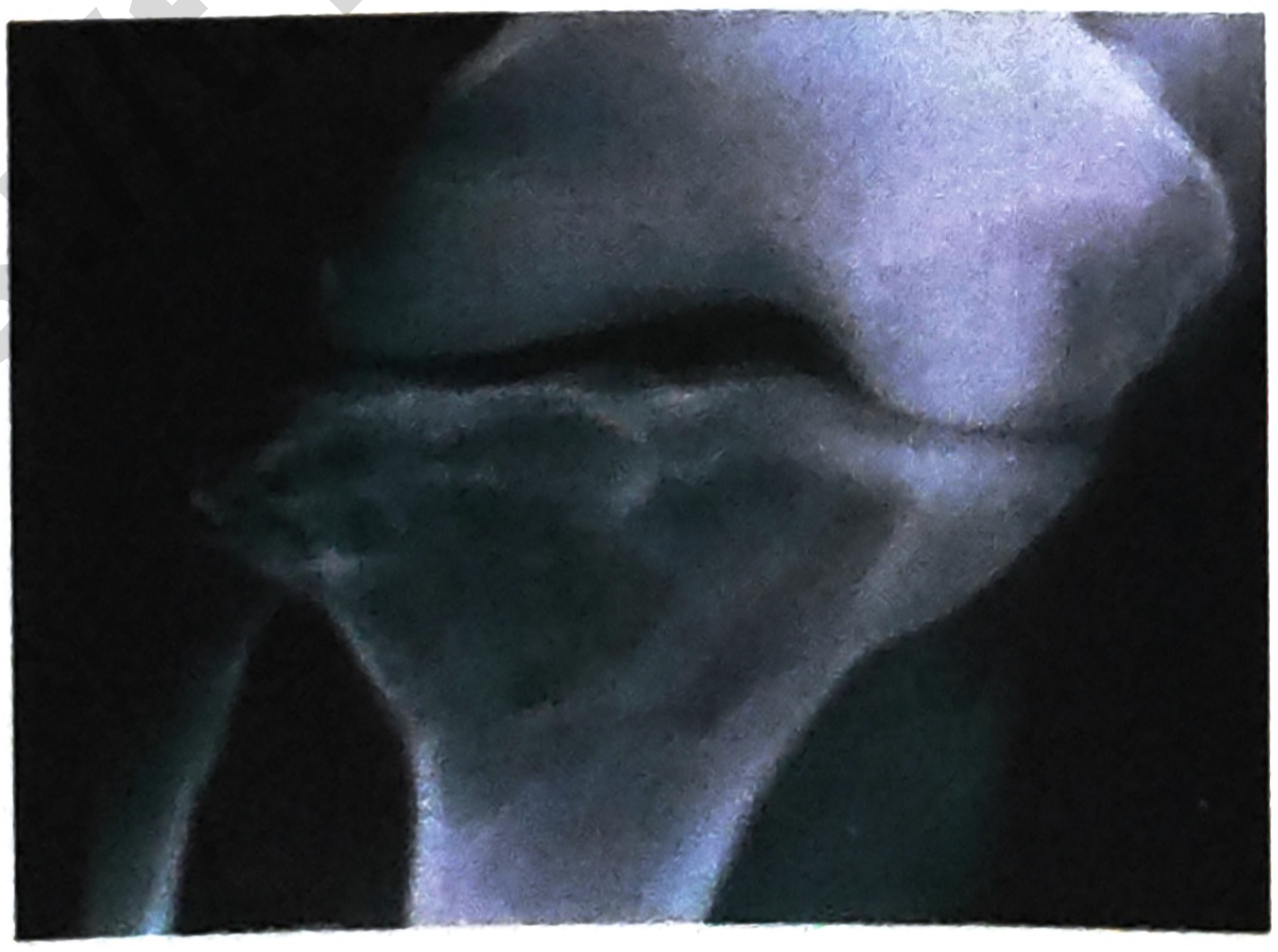

Giant cell tumor

https://t.me/Latestneetpgnotes

PrepLadder

Aneurysmal Bone cyst

00:23:35

→ Metaphysis – Multiloculated

→ Unfused growth plate

→ Fluid – fluid level on MRI (Also seen in telangiectatic Osteosarcoma, GCT)

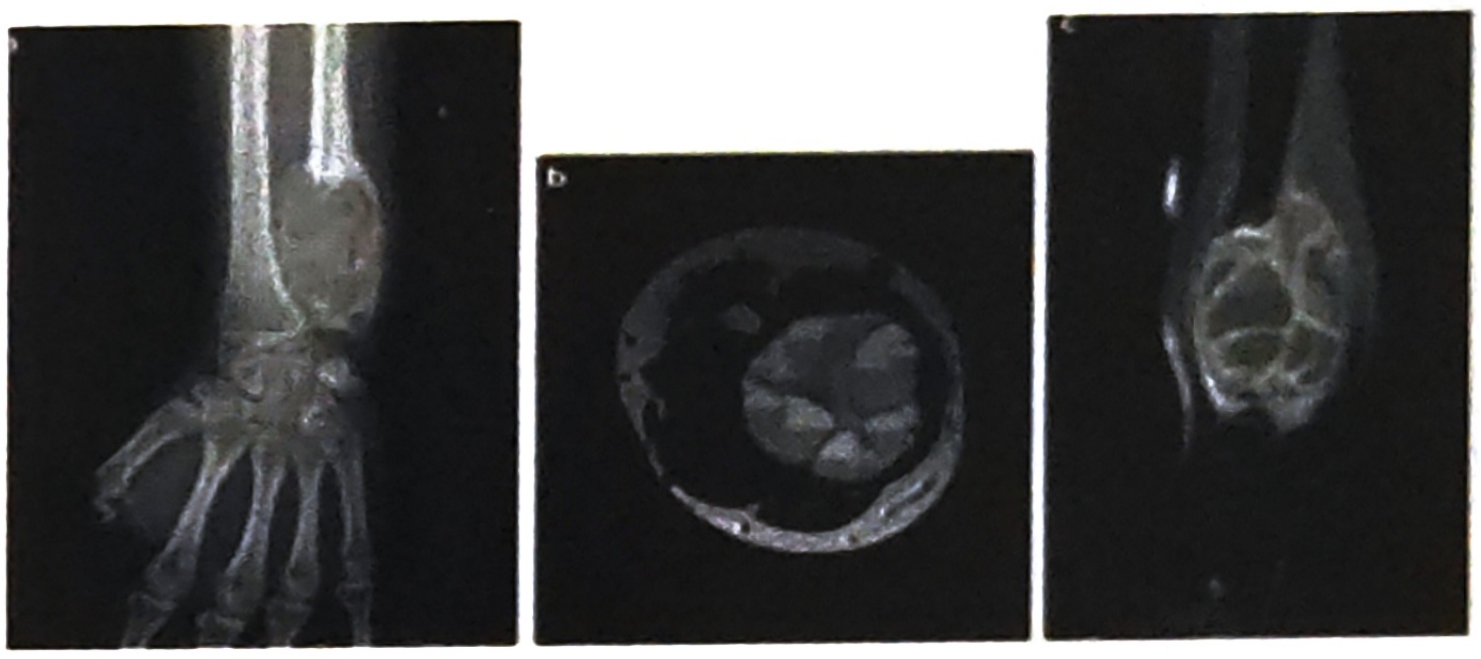

Aneurysmal bone cyst

Giant Cell tumor	Aneurysmal Bone cyst
→ Fused growth plate	→ Unfused growth plate
→ > 20 – 40 Years	→ < 20 Years
→ Epiphyses metaphyseal subarticular	→ Metaphyseal

Soap Bubble lesion in MANDIBLE

→ It is a features of Adamantinoma / Ameloblastoma

Note:

→ Soap Bubble appearance

- Around the Knee → Osteoclastoma / GCT
- Mandible → Adamantinoma
- Antenatal Scan → Multicystic dysplasia Kidney
- MRI Brain → Cryptococcus neoformans
- Abdominal radiograph → Meconium ileus

https://t.me/Latestneetpgnotes

PrepLadder

Simple bone cyst/Unicarmel bone cyst

- → Fallen leaf/fallen fragment sign
- → Unfused growth plate metaphysical lesion
- → Unilocular

Fallen leaf/ Fragment sign

Terry Thomas sign

- → Seen in Scapho-lunate dislocation

Terry Thomas sign

Metaphyseal Densities

- → Lead poisoning
- → Scurvy
- → Healing rickets

Metaphyseal lucencies

- → Leukemia

Metaphyseal densities

https://t.me/neetpgnotes

PrepLadder

Bankart lesions

00:29:00

→ Repeated shoulder dislocation

→ Erosion in anterior inferior aspect of glenoid Cavity

Hill Sachs lesions

→ Seen in recurrent shoulder dislocation

→ Lesion on the posterolateral aspect of the humerus

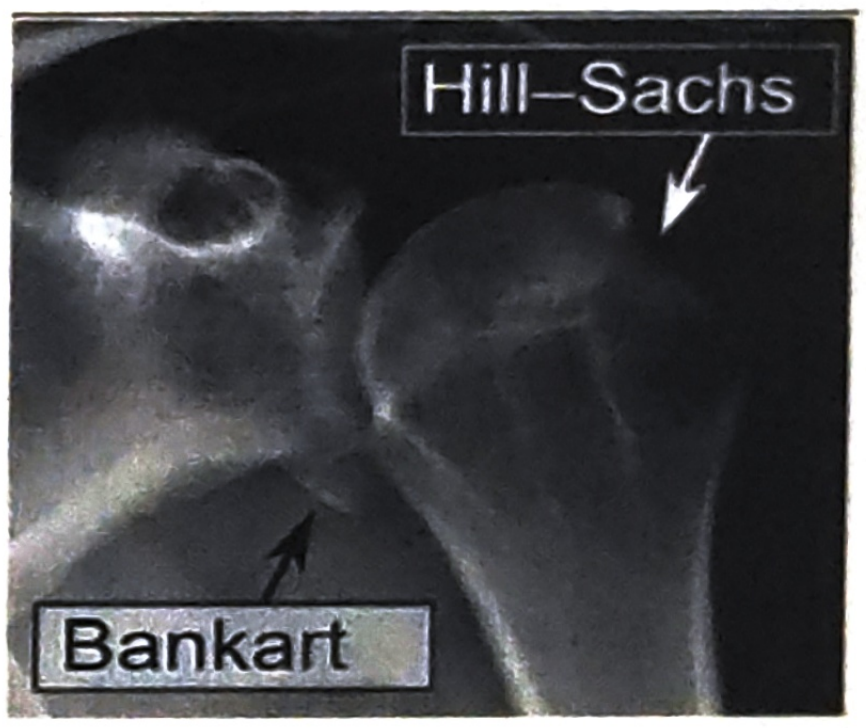

Note:

→ Subscapularis muscles – 'Forgotten muscle'

→ MC muscle involved in ROTATOR CUFF syndrome – *supraspinatus*

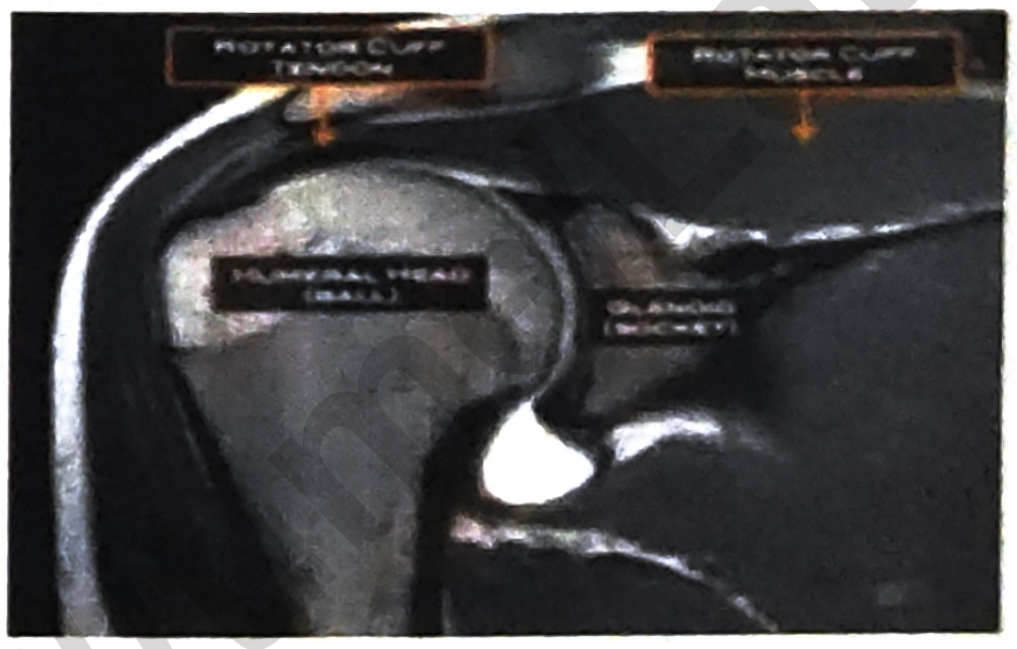

Normal rotator cuff

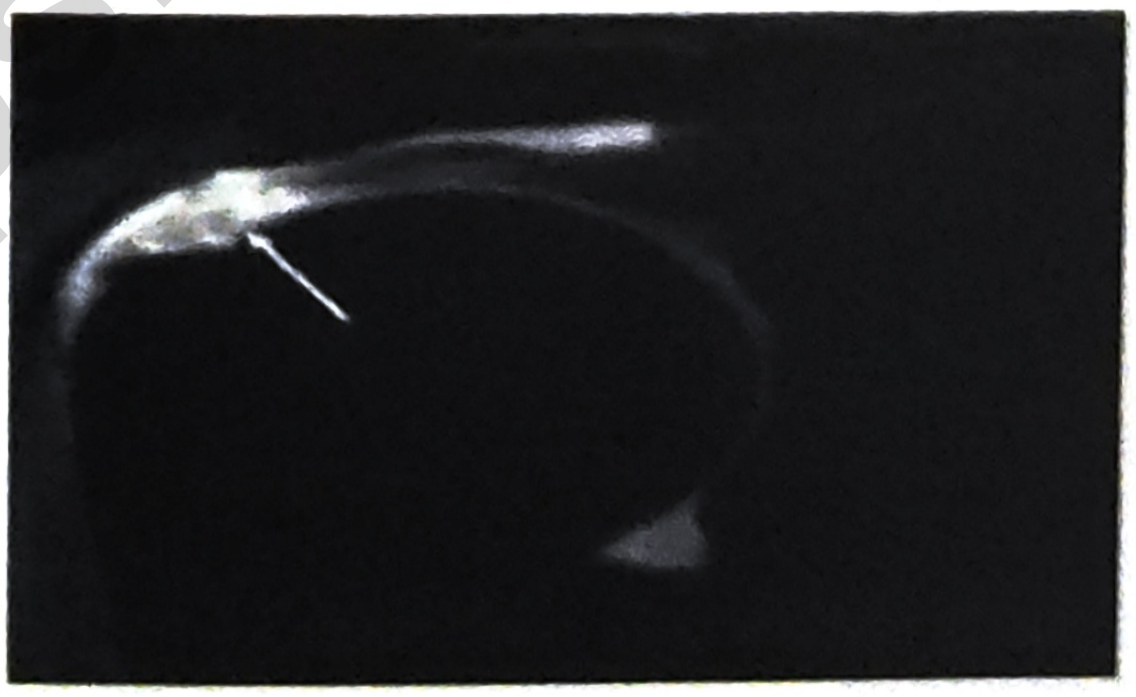

Rotator cuff tear

https://t.me/latestneetpgnotes

PrepLadder

Myositis ossificans

00:31:26

→ Most common joint involved is elbow

→ Peripheral calcification with central lucency

→ Egg shell calcification

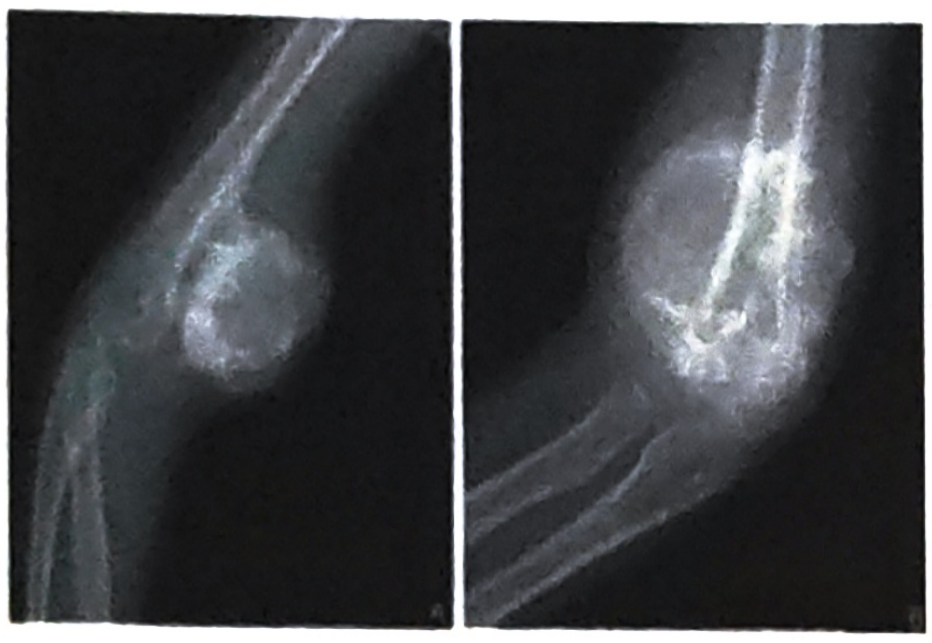

Myositis ossificans

Parosteal osteosarcoma

→ Central calcific area surrounded by lucency

→ Commonly in posterior aspect of lower end of femur

Parosteal osteosarcoma

Monteggia's Fracture

00:33:40

→ Upper end of ulna

→ Superior radioulnar joint dislocation

→ ANTERIOR MONTEGGIA'S (MC)

→ Mnemonic – "MUSA"

Monteggia's fracture

https://t.me/bestneetpgnotes

PrepLadder

Galeazzi Fracture

→ Fracture of distal end of radius with dislocation of Inferior radio ulnar joint

→ Mnemonic – "GRI"

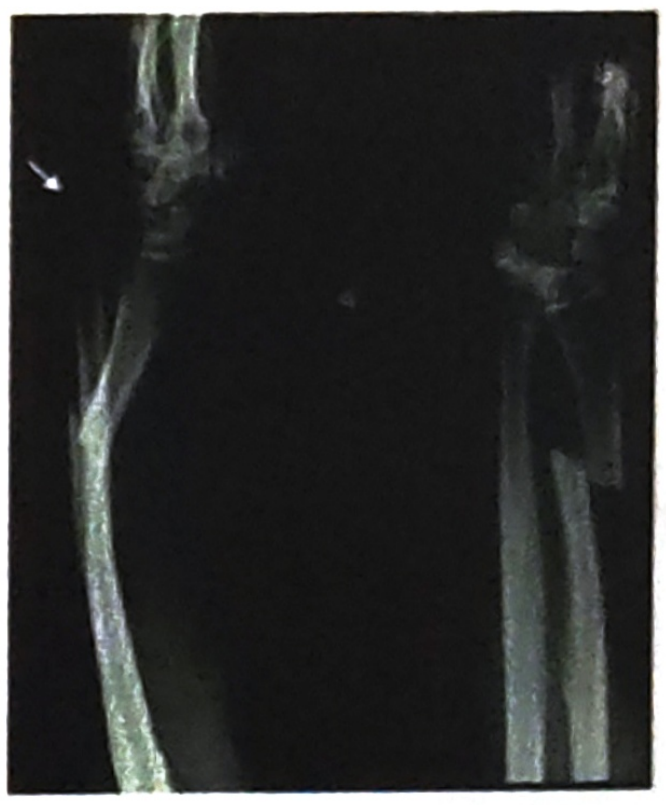

Galeazzi fracture

Hand radiograph

→ Carpal bones are arranged in two rows from lateral to medial (Mnemonics – "She Looks Too Pretty Try To Catch Her")

→ Medial bones – Hamate & Pisiform

→ Lateral bones – Scaphoid & Trapezium

→ Thumb rotates over Trapezium

→ Largest carpel bone – Capitate

→ MC Fracture carpel bone – Scaphoid

→ MC dislocated carpal bone – Lunate

Carpal bones

https://t.me/Latestneetpgnotes

PrepLadder

Scaphoid Fracture

→ Avascular necrosis of base and proximal portion of scaphoid (because blood supply is retrograde)

→ Most common site of fracture - waist of scaphoid

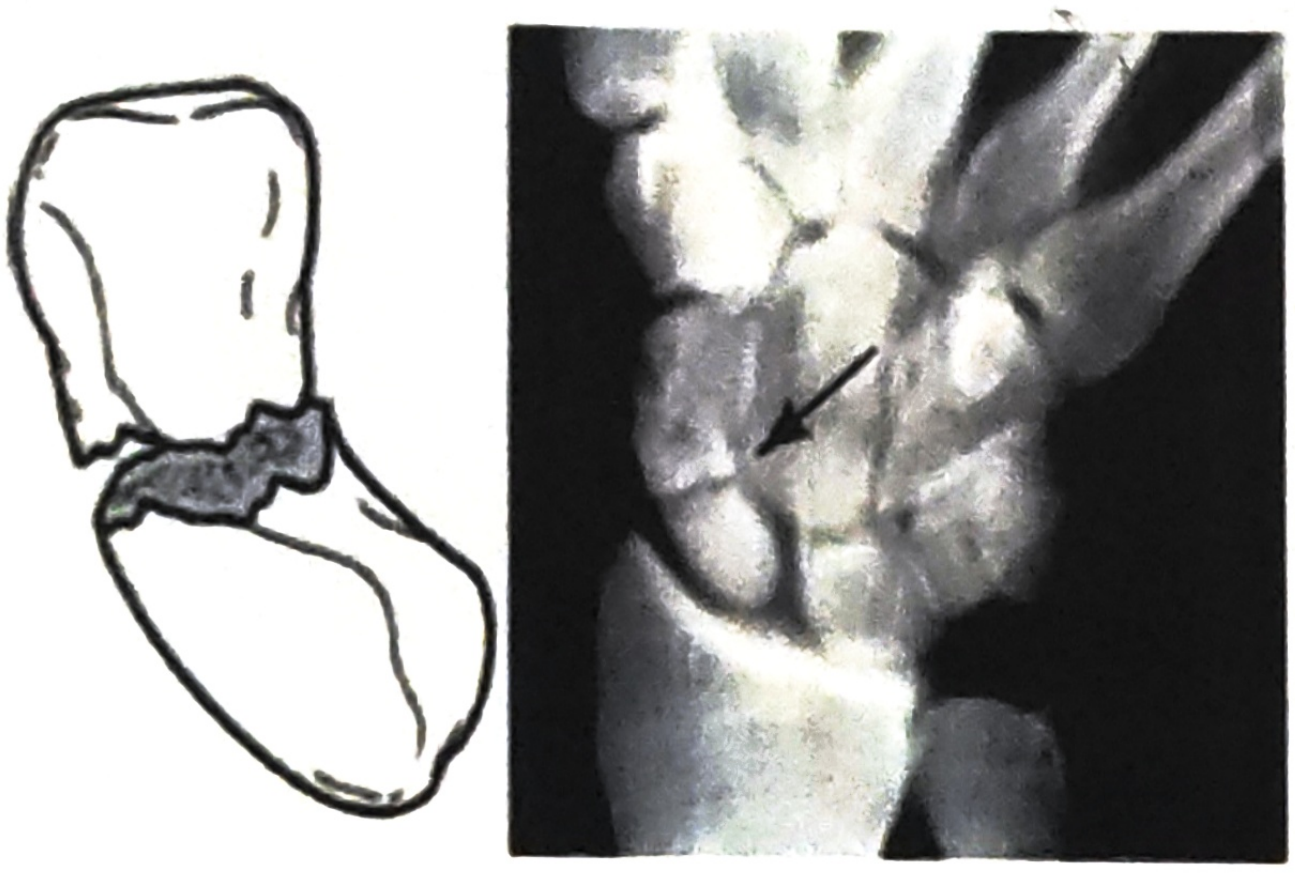

Scaphoid fracture

Proximal pointing of metacarpals

→ Features of MUCOPOLYSACCHARIDOSIS / Hurler syndrome

→ Other findings in hurler syndrome

- Oar shaped ribs
- Anteroinferior beaking of vertebra
- J shaped Sella/macrocephaly

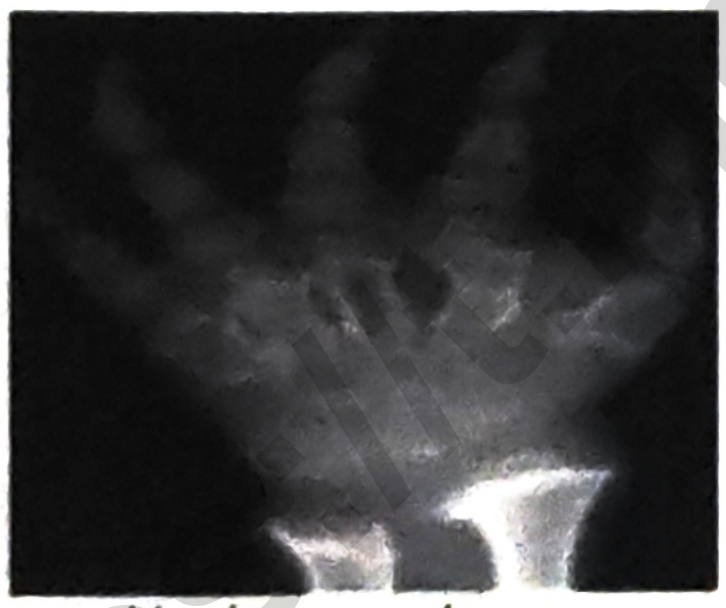

Hurler syndrome

Oar shaped ribs

https://t.me/Latestneetpgnotes

PrepLadder

Nail Patella syndrome

→ Iliac horns

→ Absent patella

→ Nail defects

Psoas abscess

→ Fluid filled psoas as well as swollen psoas muscle is seen

Colles Fracture

→ Fracture at distal end of radius in the corticocancellous junction

→ Reflex sympathetic dystrophy - Osteopenia (Sudeck's Dystrophy)

Telephone Handle appearance in femur

→ Feature of Thanatophoric Dysplasia

Dot in Circle appearance in MRI

→ Feature of Madura mycosis

→ Fungal element in the Centre with surrounding granulation tissue

Osteoid Osteoma

→ Central lucent nidus < 2 cm

→ Surrounded by Sclerotic rim

→ Commonly involves diaphysis

→ Double density sign on nuclear scan

https://t.me/Latestneetpgnotes

PrepLadder

Chapter 30

MUSCULOSKELETAL RADIOLOGY PART 3

Rheumatoid arthritis

00:00:18

- → Most commonly involved joints Is MCP (metacarpophalangeal joint)
- → Erosion of lateral end of clavicle
- → Osteopenia
- → Swan neck deformity – Flexion of DIP & Extension of PIP
- → Boutonniere deformity – Flexion of PIP and Extension of DIP
- → Hitch hikers thumb (boutonniere deformity Involving the thumb)
- → Atlantoaxial subluxation

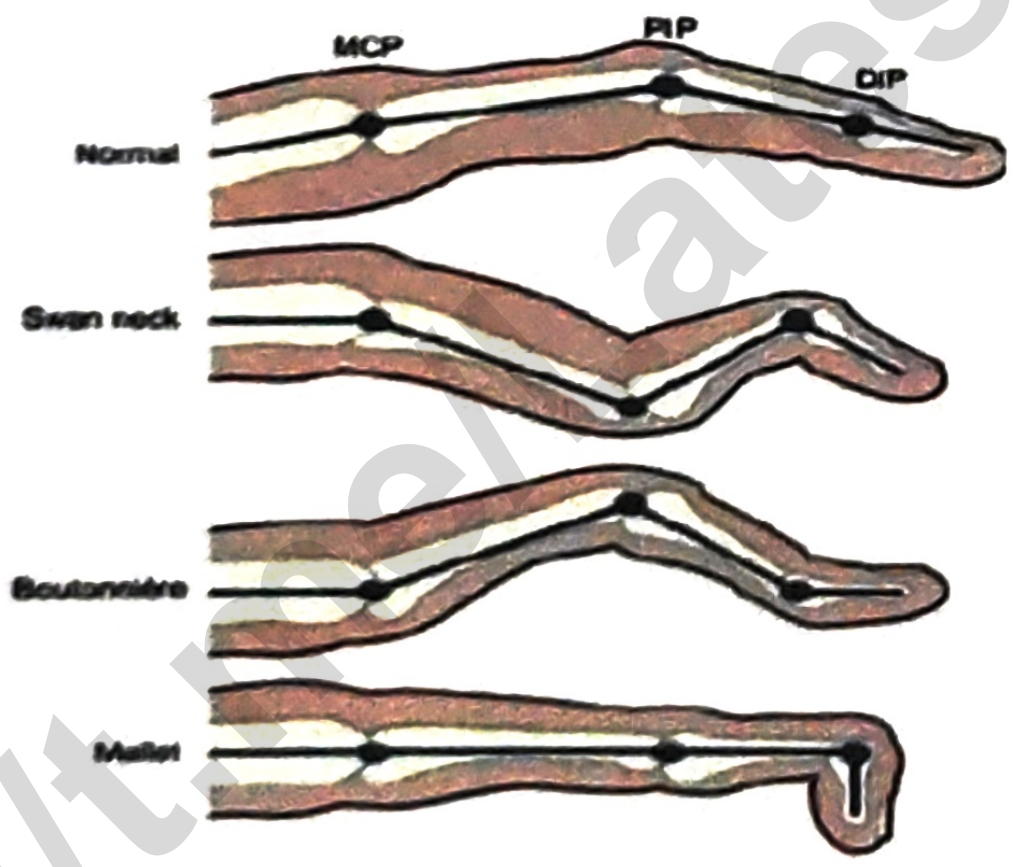

Rheumatoid arthritis

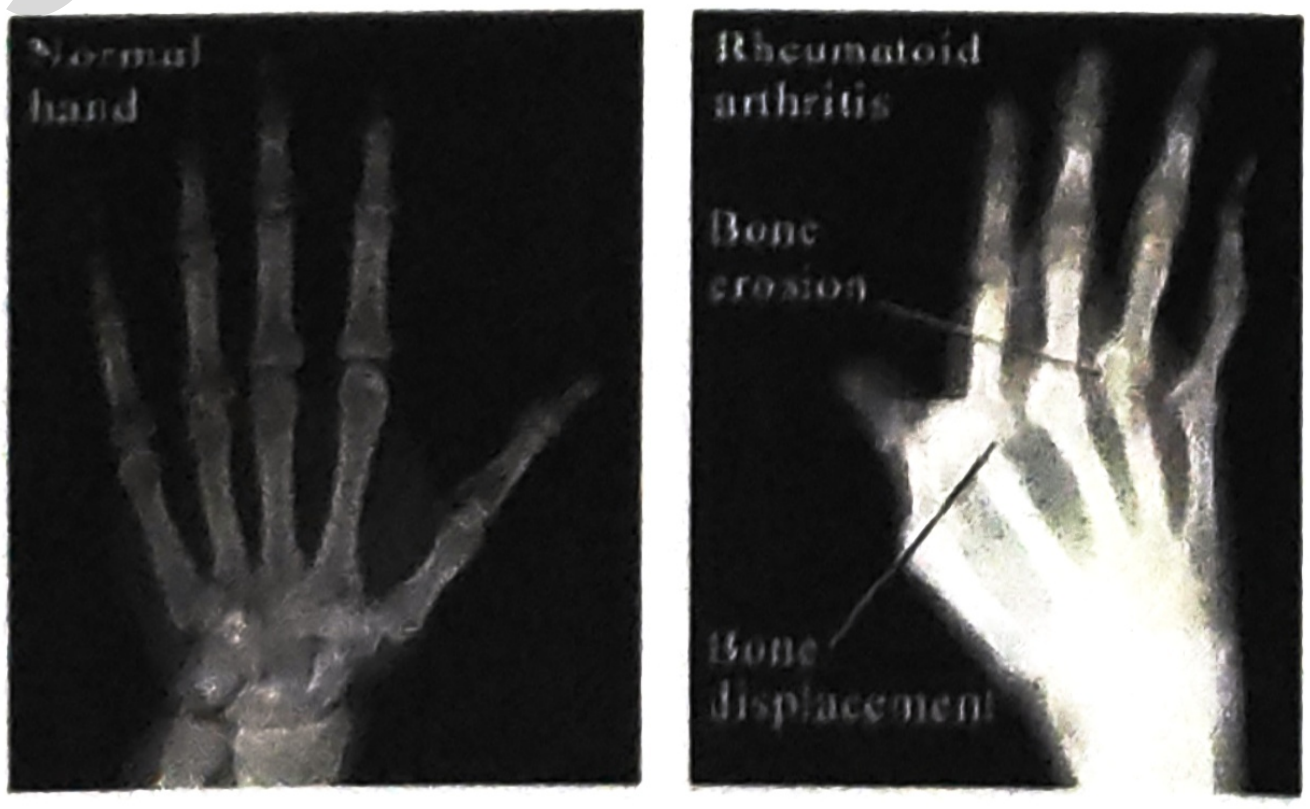

https://t.me/latestneetpgnotes

PrepLadder

Erosion of clavicle

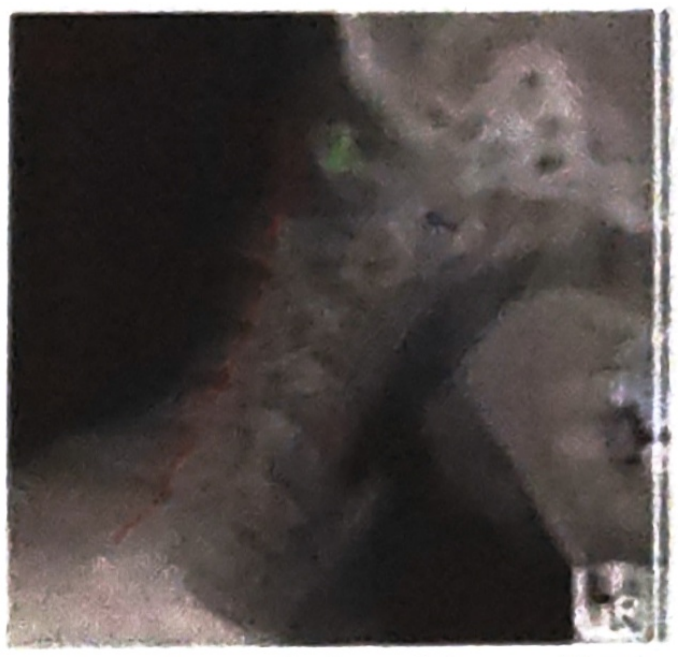

Atlantoaxial subluxation

Felty's Syndrome

00:05:20

→ RA + splenomegaly + neutropenia

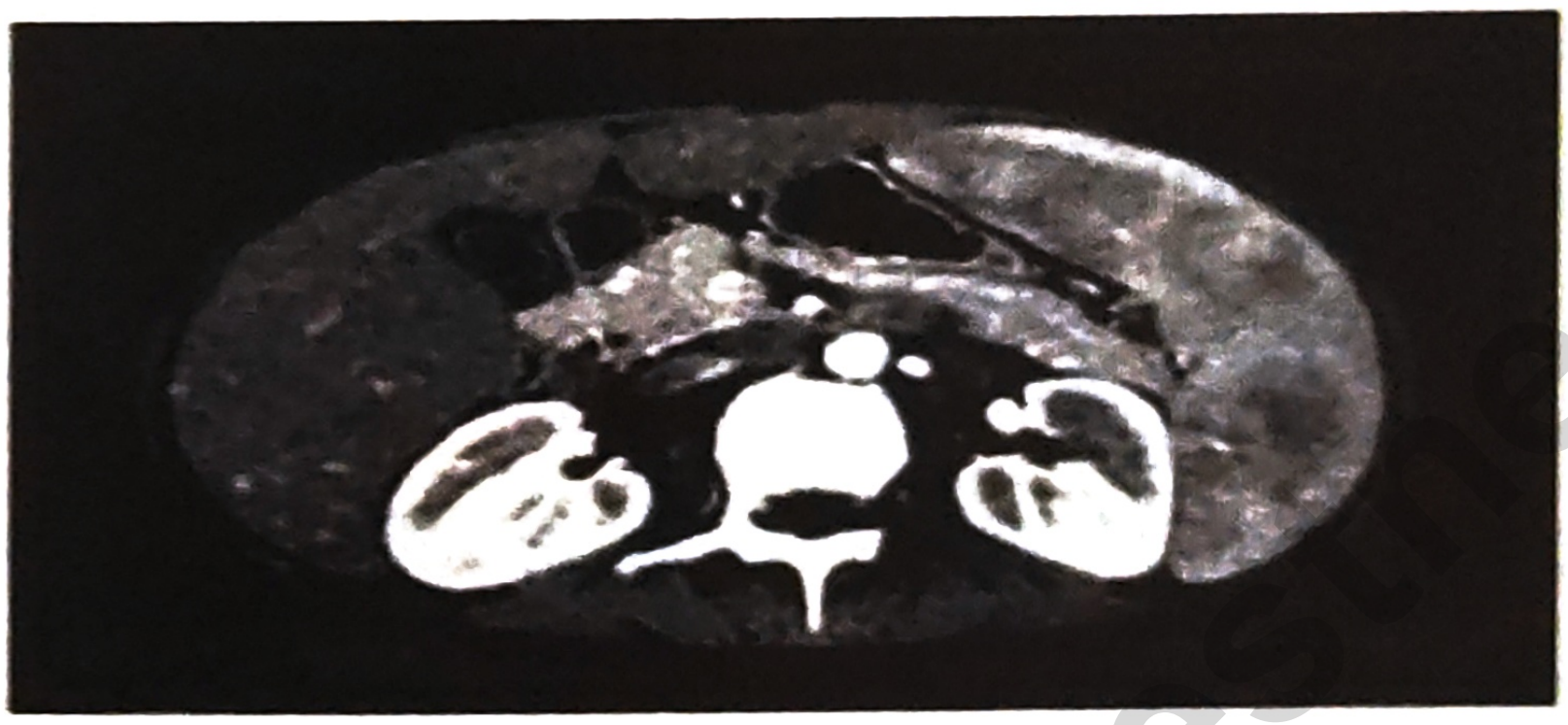

Splenomegaly (Felty's syndrome)

Osteoarthritis

00:06:30

→ Narrowing of medial ends of Knee joint
→ Subchondral sclerosis
→ Reduced joint space
→ Bouchard's Node – OA involving PIP
→ Heberden's Node – OA involving DIJ
→ Gull wings sign – seen commonly in erosive Osteoarthritis

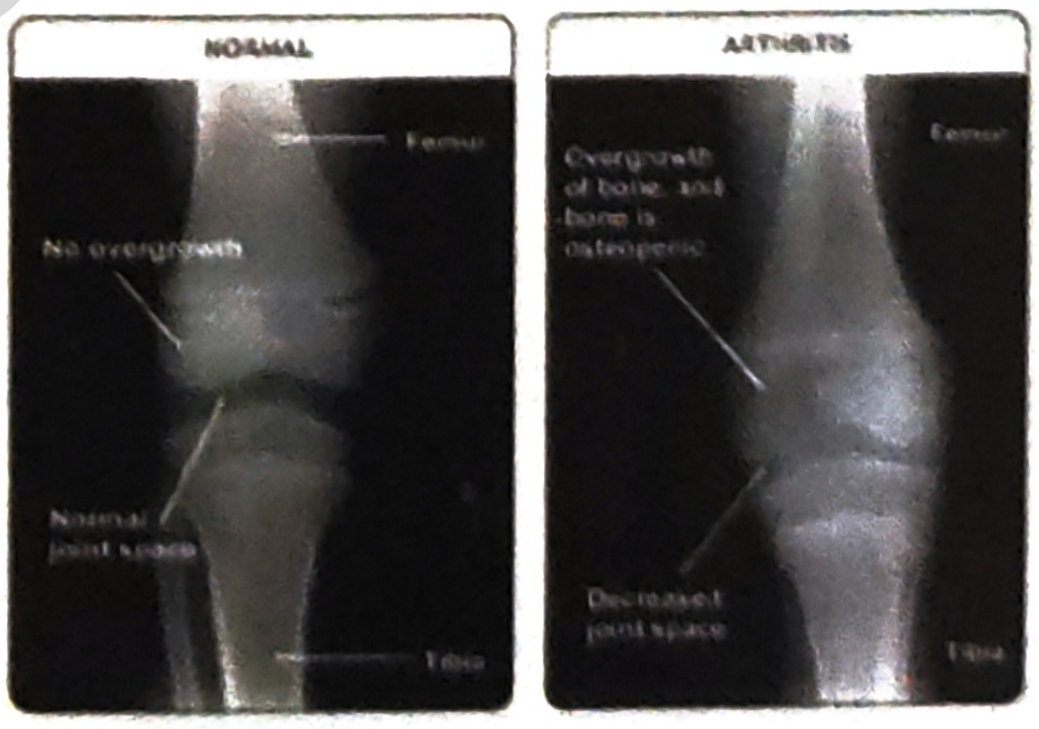

Osteoarthritis

https://t.me/Latestneetpgnotes

Gull wings sign

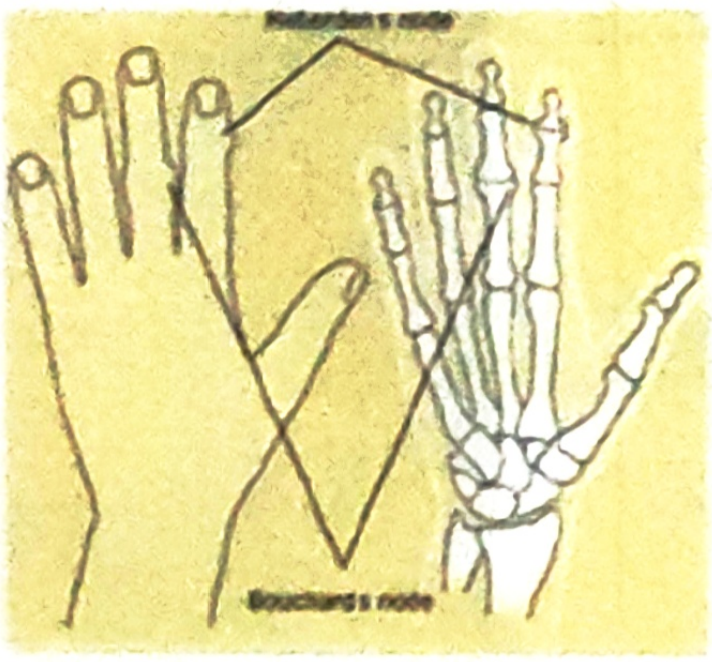

Heberden's and Bouchard's

Psoriatic arthritis

00:09:17

- → Involvement of PIP joints (interphalangeal)
- → Radiological findings
    - Saucerization of digits
    - Tapering of Phalanges
    - Pencil in cup deformity
    - Telescoping sign positive
    - Arthritis mutilans/erosive arthritis
    - Opera glass deformity (La Main en Lorgnette)
    - Mouse ear sign
    - Periostitis at edge of bone

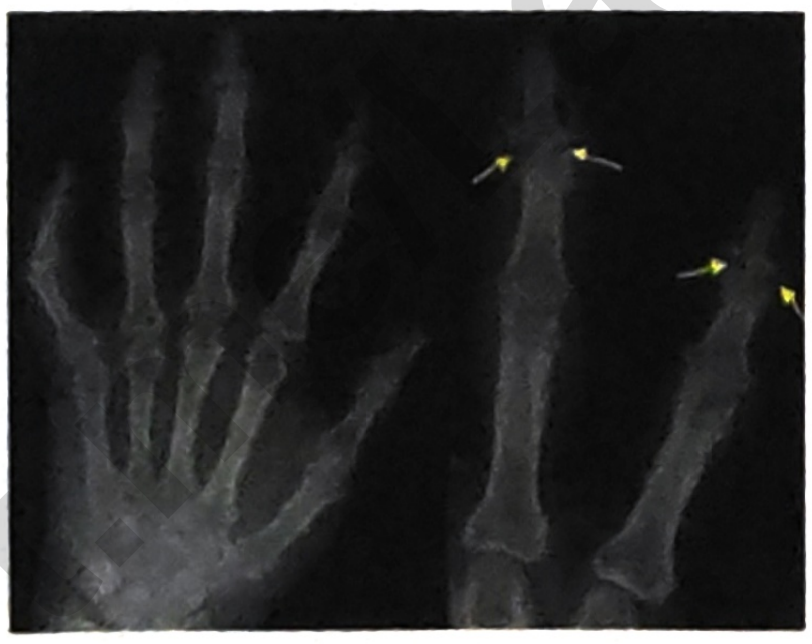

Psoriatic arthritis

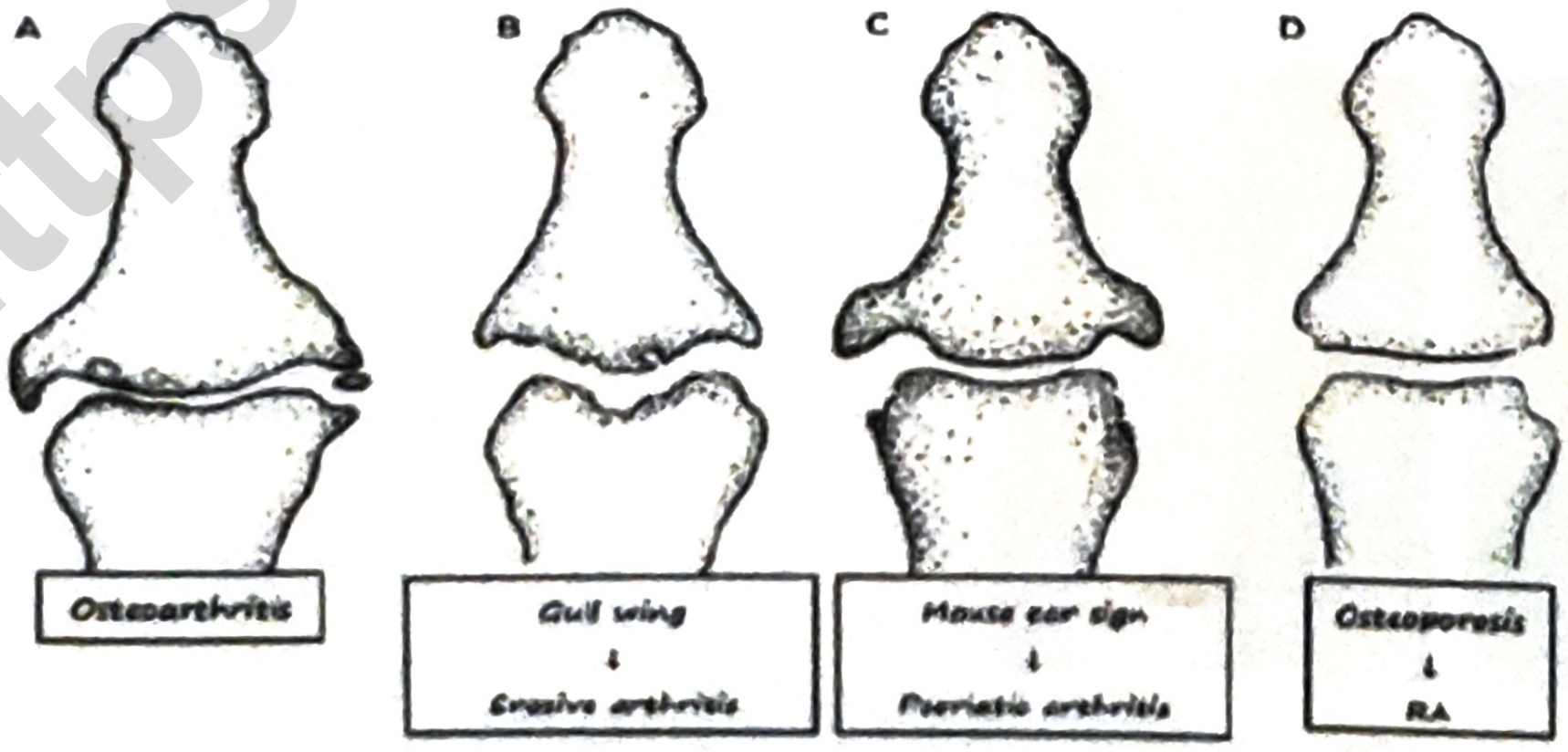

https://t.me/latestneetpgnotes

PrepLadder

Opera glass deformity

Gouty arthritis 00:13:54

→ Rat bite erosions

→ Overhanging edges – MARTEL'S SIGN

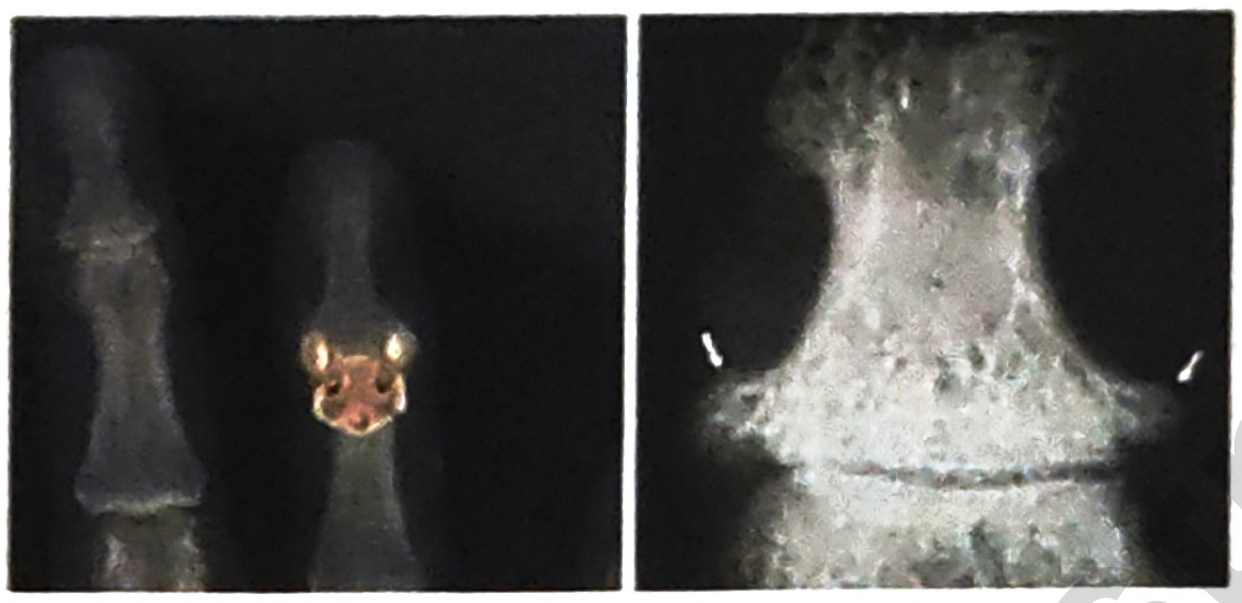

Mouse ear sign

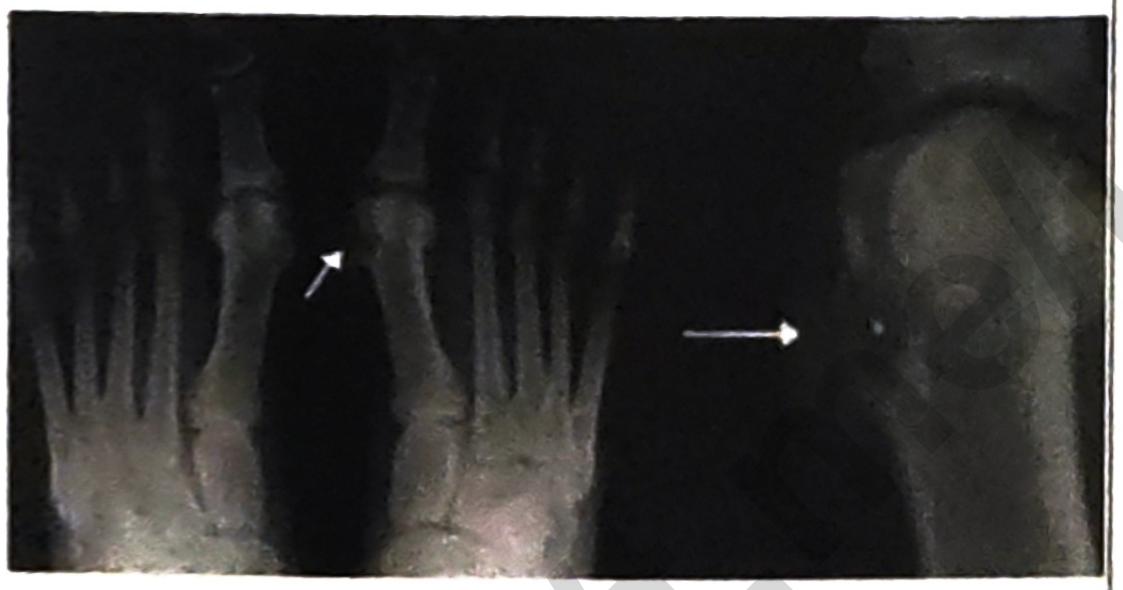

MARTEL'S Sign

Rat bit erosions

Normal Knee Joint

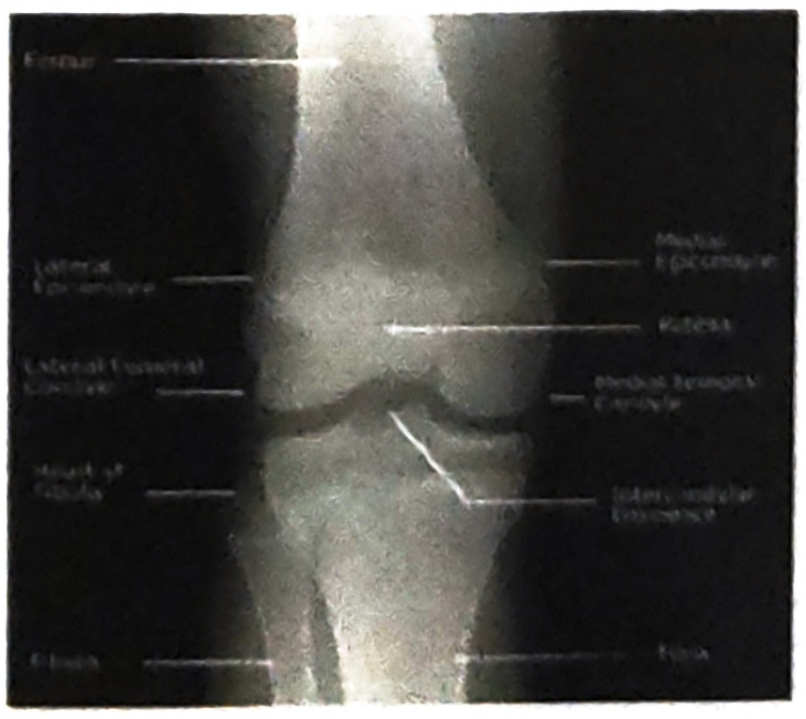

https://t.me/Latestneetpgnotes

PrepLadder

Haemophilic arthropathy

→ Deep intercondylar Notch

→ MC involves – Knee Joint

Deep intercondylar notch

Hyperparathyroidism

→ Erosion of radial end of middle phalanx

→ Resorption of distal phalanges called acroosteolysis

→ Salt and pepper skull-"Pepper Pot Skull"

→ Loss of lamina dura of teeth

→ Osteitis fibrosa cystic / brown tumours

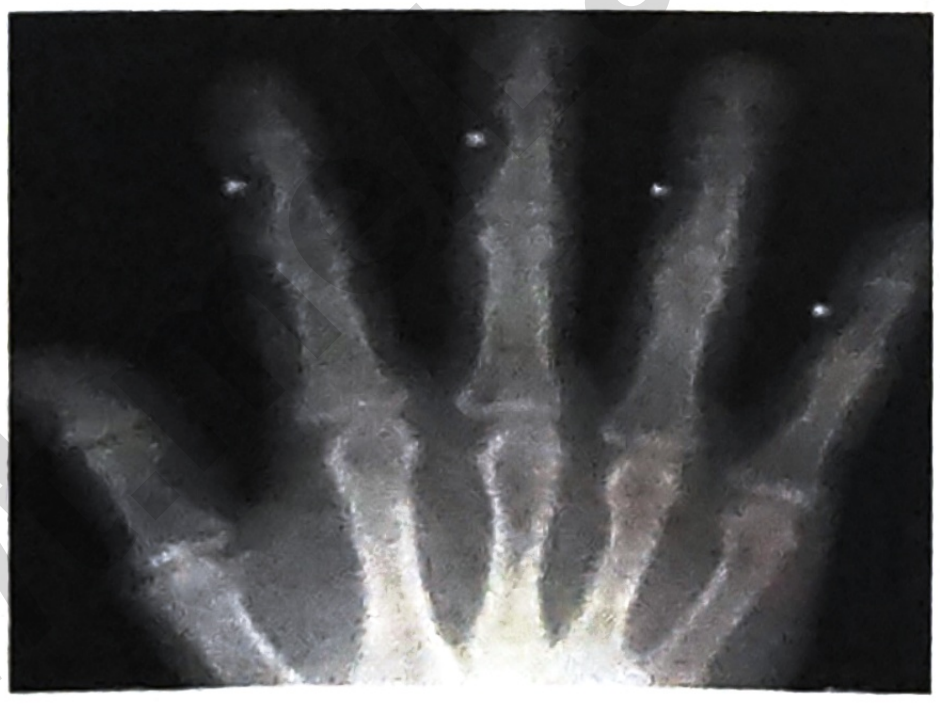

Acroosteolysis and erosion of middle phalanx

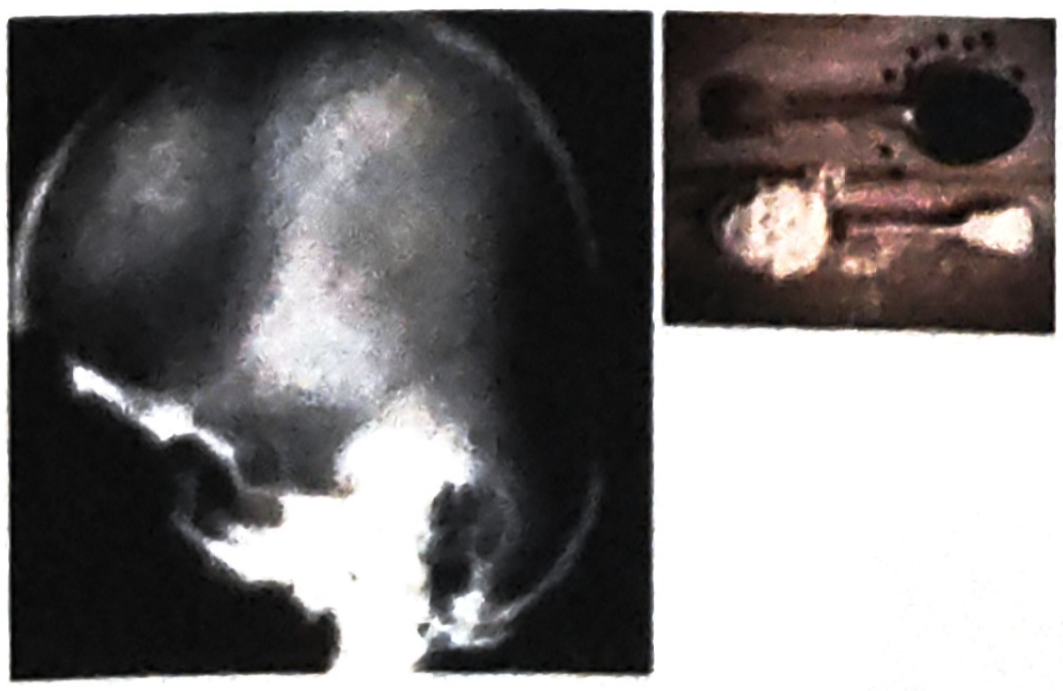

Salt and pepper skull

https://...atestneetpgnotes

PrepLadder

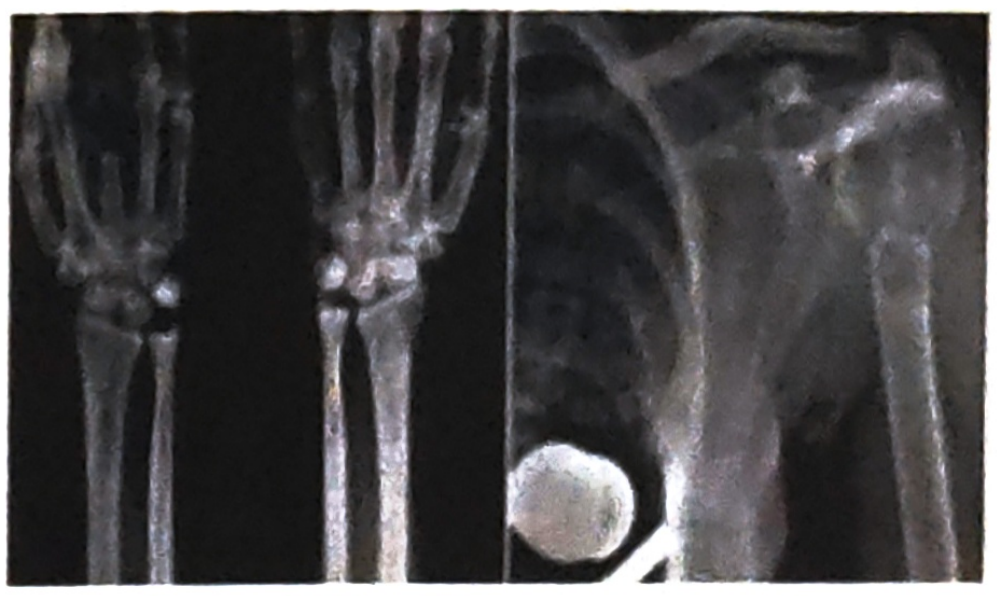

Osteitis fibrosa cystica

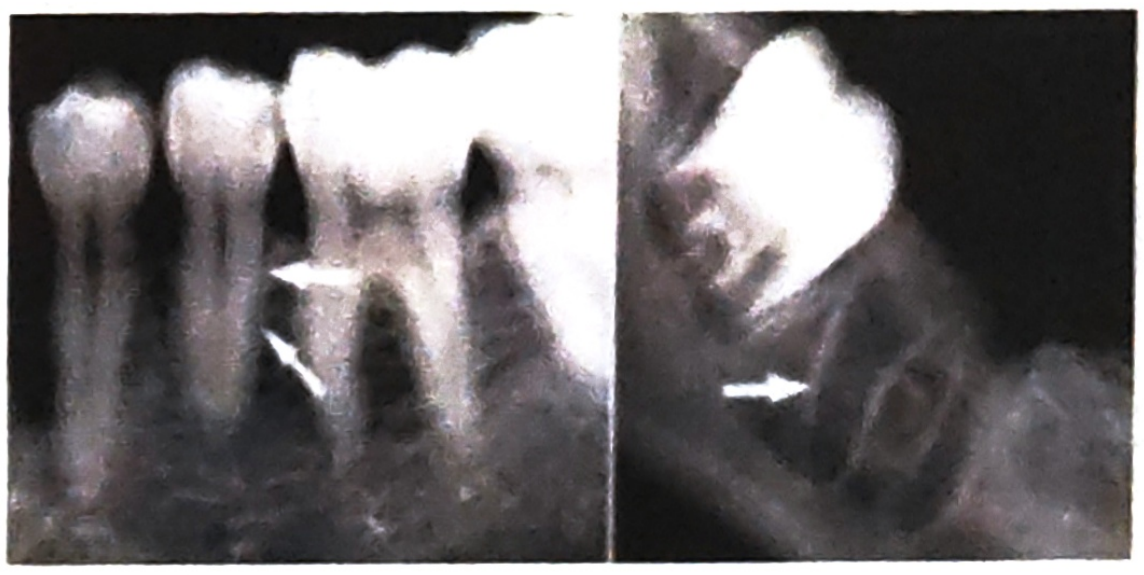

Lamina dura of teeth

Melorheostosis

00:19:16

→ Molten wax like ossification of long bones



Melorheostosis

Paget's disease

Altered bone remodeling		
Lytic	Mixed	Sclerotic
• Osteoporosis circumscripta	• Mosaic/Jigsaw	• TAM o SHANTER sign
• Blade of Grass/flame sign	• Cotton wool skull • Picture frame vertebra	• Ivory vertebrae

PrepLadder

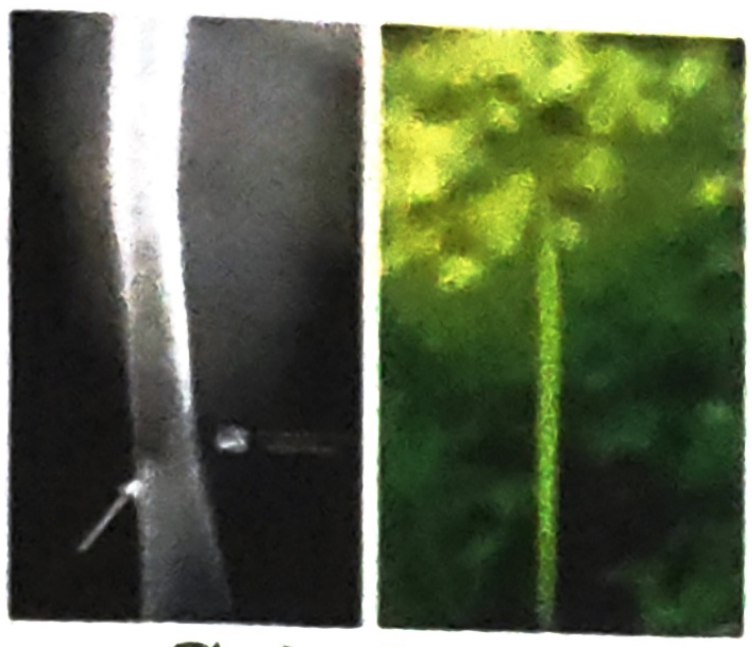

Blade of grass



Picture frame vertebrae

Ivory vertebrae

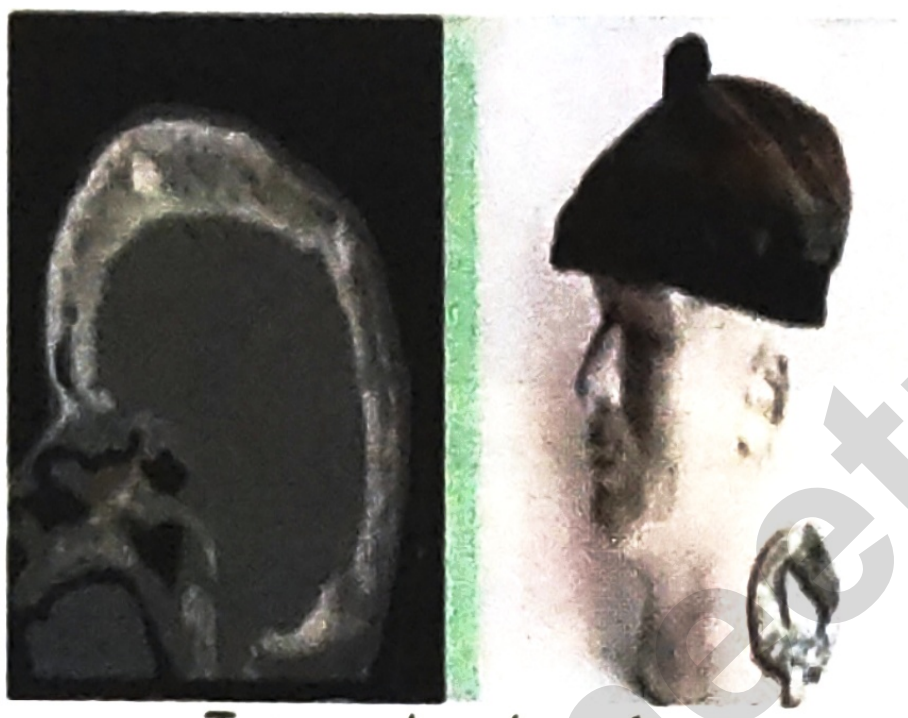

Tam o shanter sign

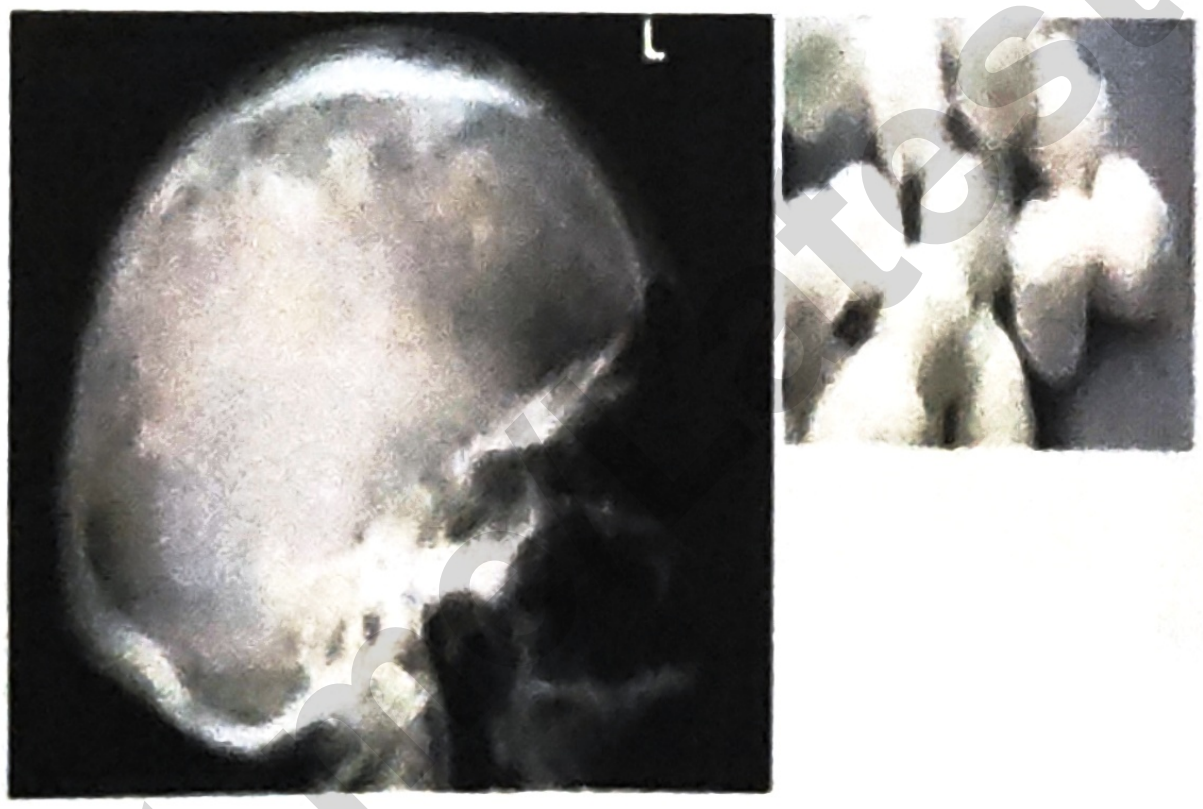

Cotton wool skull

Note:

→ Ivory Vertebra is also seen in lymphoma and osteoblastic metastasis.

Osteopetrosis 00:26:20

→ Defective osteoclastic resorption

→ Dense sclerosis of the superior and inferior end plates of the vertebral body produce Sandwich Vertebra

https://t.me/neetpgnotes

PrepLadder

For more free ebooks and notes, visit

https://t.me/Latestneetpgnotes

Or click this page to join

→ Bone within bone appearance

→ Hazy sclerosis of the superior and inferior aspect of the vertebral body is called as Rugger Jersey spine

→ Rugger Jersey Spine seen with Renal osteodystrophy and osteopetrosis

→ Expansion of metaphyseal ends of the bone is called as Erlenmeyer flask deformity

→ Dense sclerosis of the superior and inferior end plates of the vertebral body produces Sandwich vertebra or rugger Jersey spine

Sandwich vertebrae

Rugger Jersey spine

Achondroplasia

00:27:33

→ Defect in enchondral Ossification

- Trident hand
- Rhizomelic dwarfism
- Large skull and narrow skull base
- Horizontal acetabulum
- Tombstone iliac bone

Trident hand

Rhizomelic dwarfism

PrepLadder
https://t.me/Latestneetpgnotes

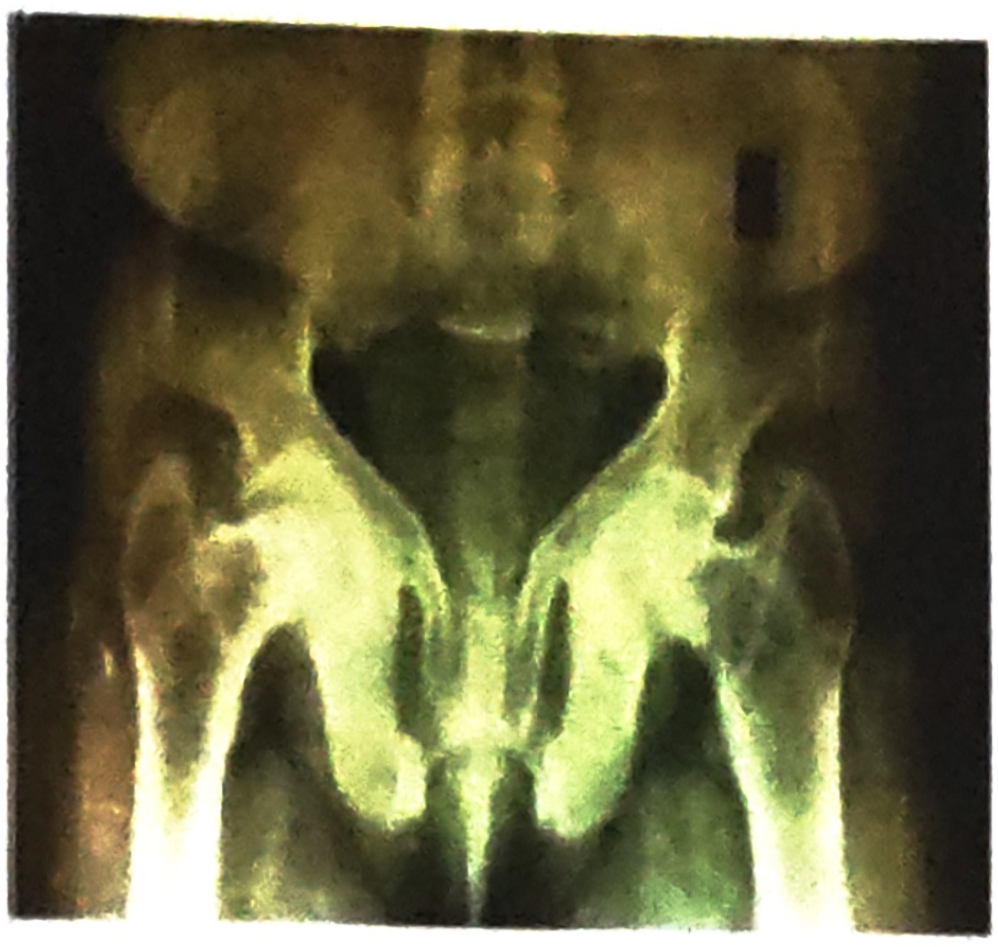

Champagne glass pelvis

Erlenmeyer Flask deformity

00:31:40

→ Seen in

- Osteopetrosis
- Thalassemia
- Gaucher's disease

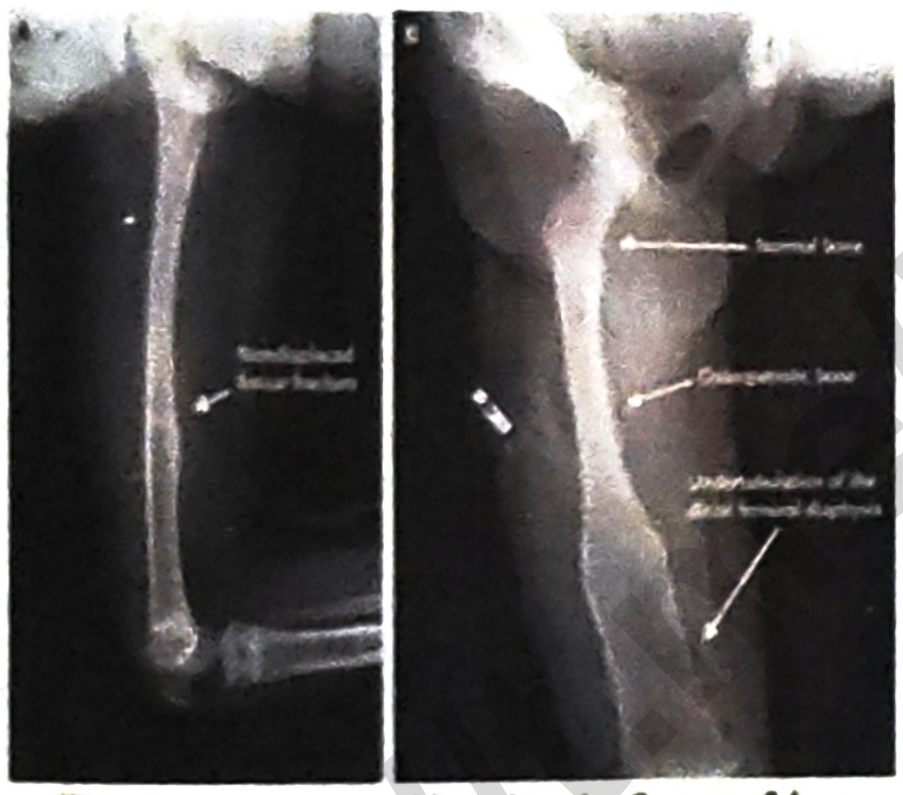

Erlenmeyer flask deformity

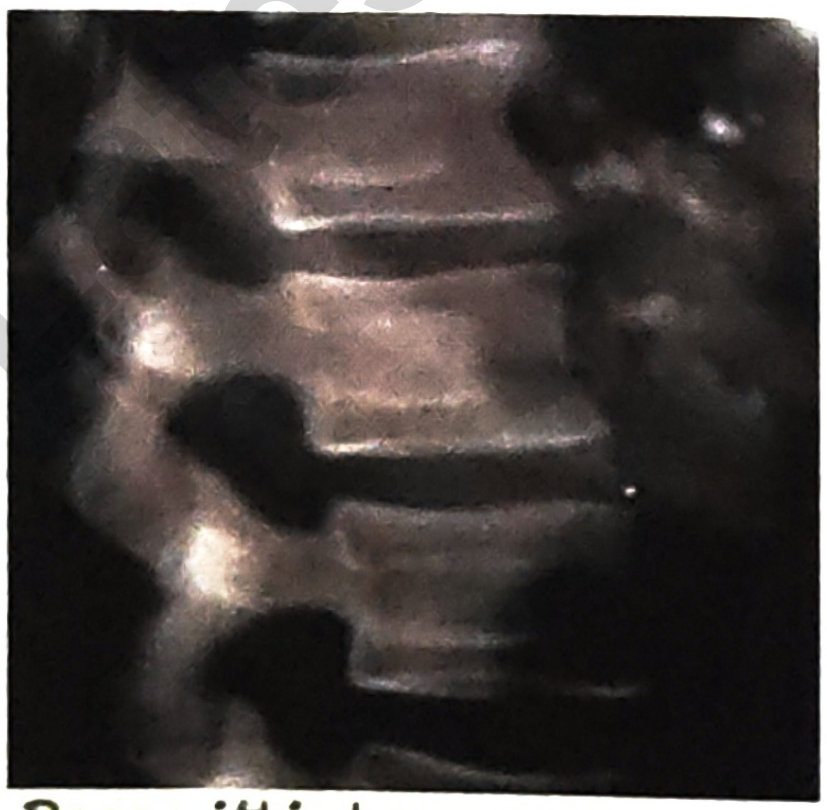

Bone within bone appearance

https://t.me/bestneetpgnotes

Chapter 31

Musculoskeletal Radiology PART-4

Mucopolysaccharidosis   00:00:15

Hurler's syndrome

→ Autosomal recessive

→ Clinical features

- Mental Retardation
- Cloudy cornea
- Deafness
- Oar shaped ribs
- Macrocephaly, J-shaped Sella
- Proximal pointing of metacarpals
- Short & wide long bones
- Antero-inferior beaking of vertebral bodies

Anterior inferior beaking of VB

Macrocephaly

Morquio's syndrome   00:04:23

→ Autosomal recessive

→ Clinical feature

- Severe dwarfism (<4 foot)
- Platyspondyly (A)

https://t.me/Latestneetpgnotes

PrepLadder

- Anterior-Central beaking of vertebral bodies (B)
- Proximal pointing of metacarpals (C)
- Short & wide long bones (D)

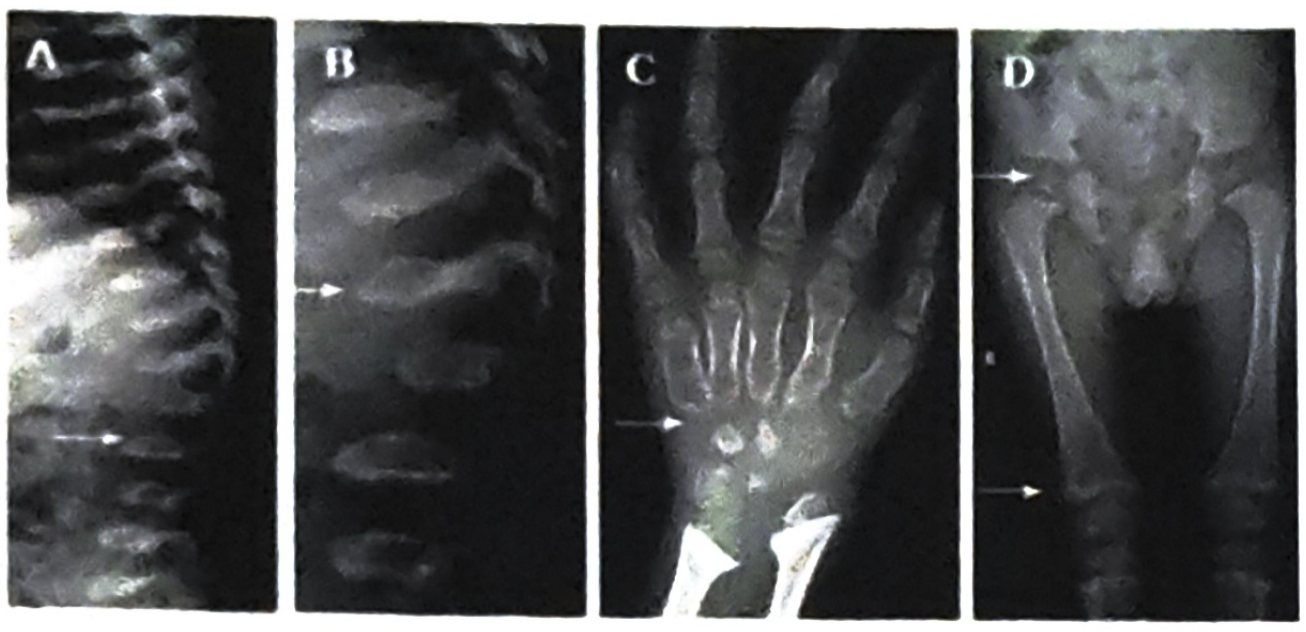

Morquio's syndrome

Rickets

→ Shows Rachitic Rosary – Flaring of Anterior of ribs

Nail-Patella syndrome

00:06:23

→ Characterized by

- Triangular lunula
- Absent Patella
- Radial head deformity
- Presence of Iliac horns / Fong prongs

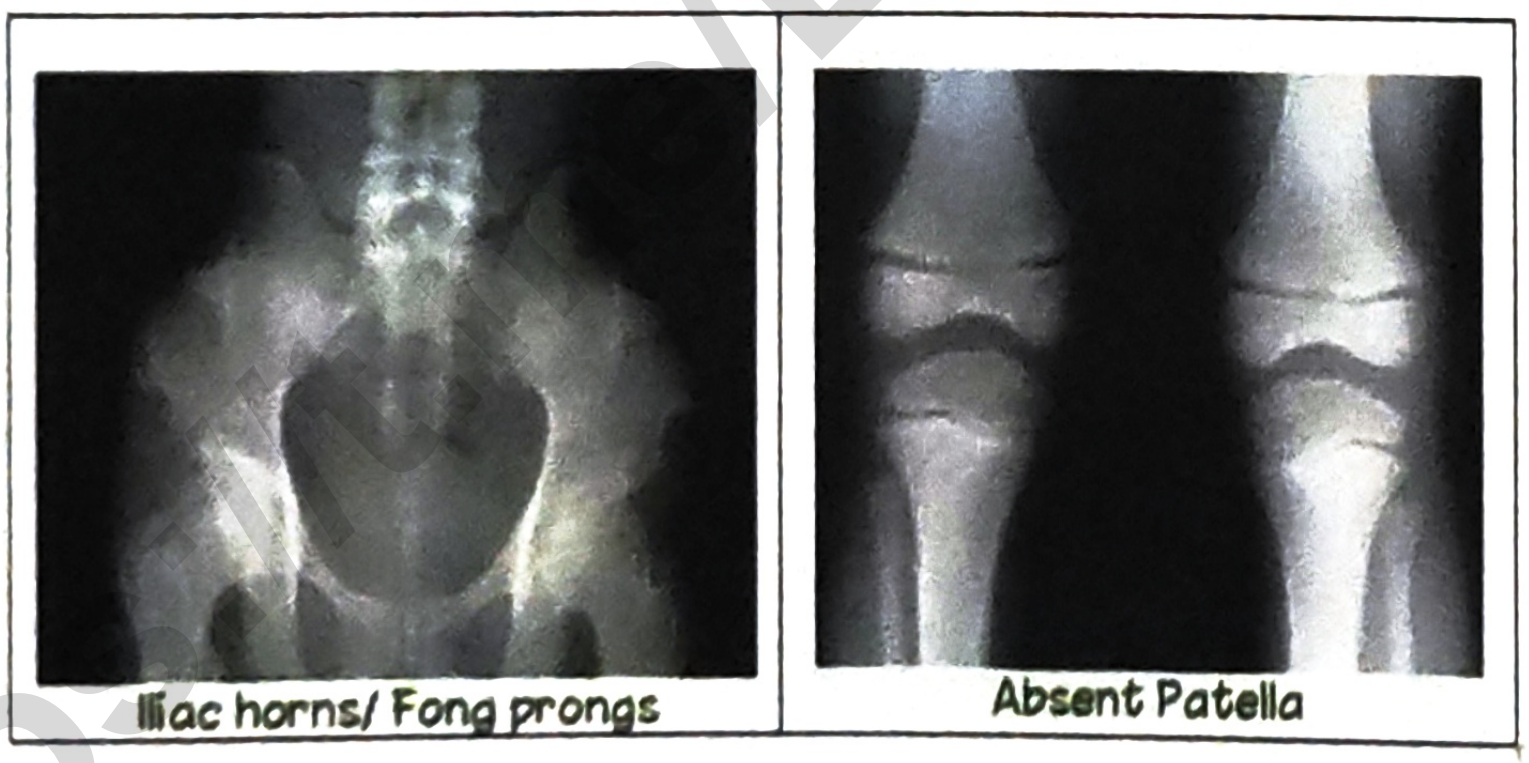

Iliac horns/ Fong prongs | Absent Patella

Triangular lunula

https://t.me/Latestneetpgnotes

PrepLadder

Psoas Abscess

00:08:20

→ Psoas major muscle - Present on either side of vertebral body

→ Altered signal on Psoas muscle - Indicates Psoas abscess

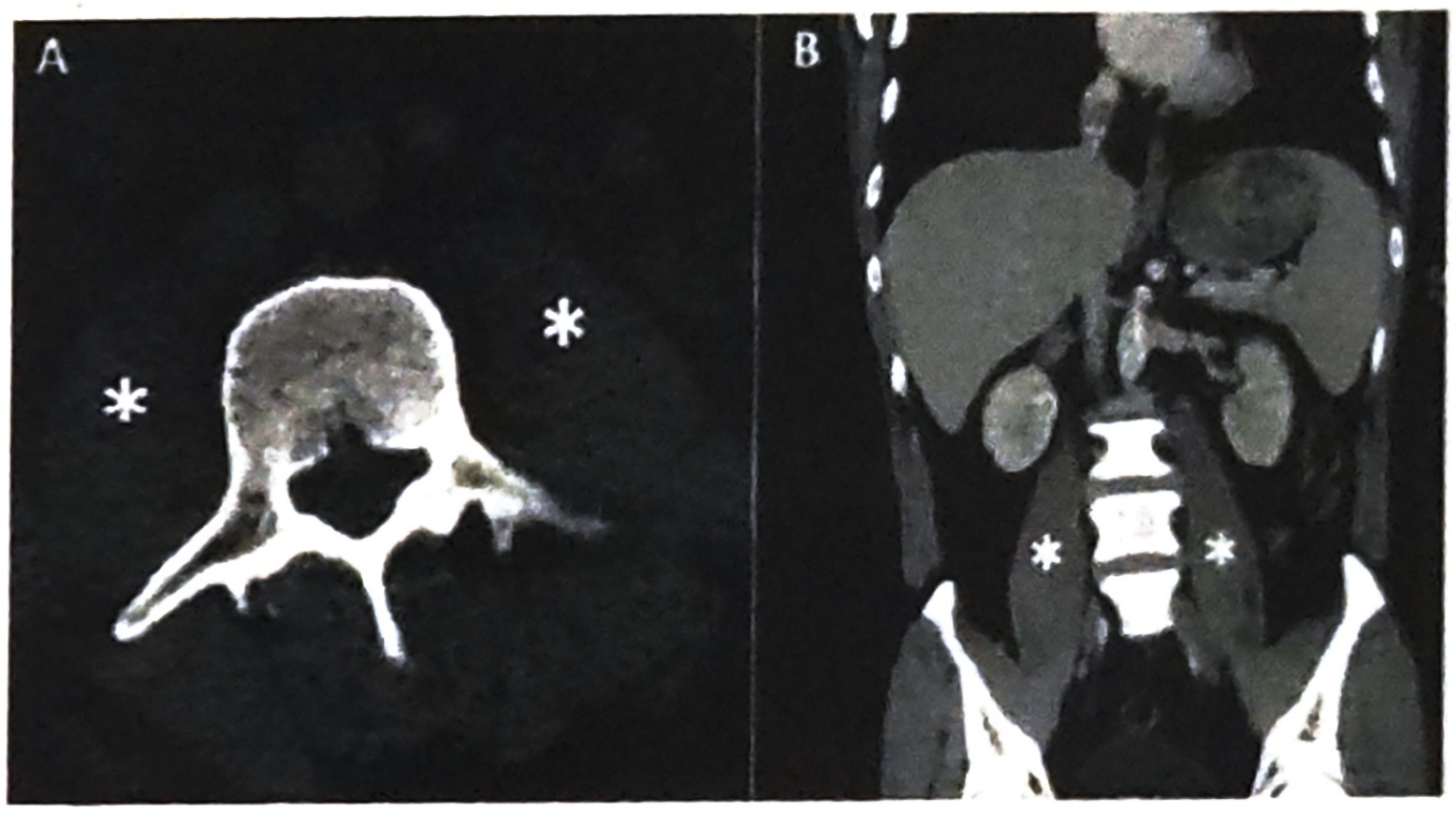

Psoas major muscles (A) Sagittal view (B) Coronal view

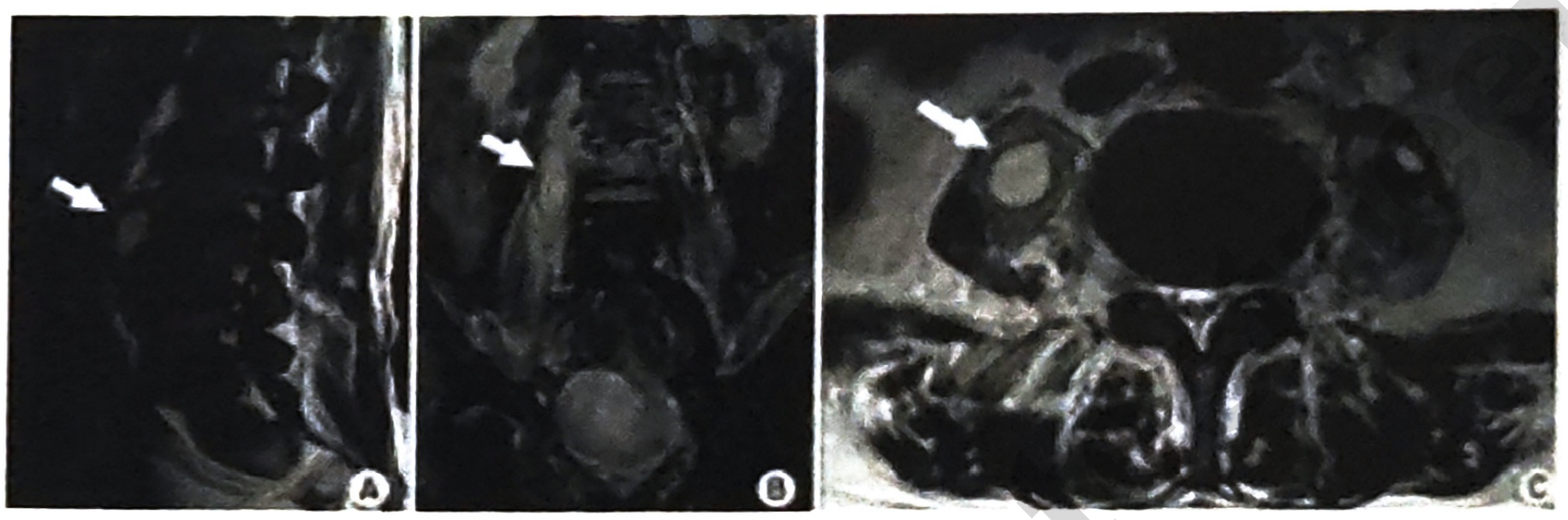

Psoas Abscess

Sudeck's dystrophy

00:09:18

→ Aka Reflux sympathetic dystrophy (RSD)

→ Characterized by

- Periarticular Osteopenia
- Hx. Of Trauma
- Ass. With Colle's fracture

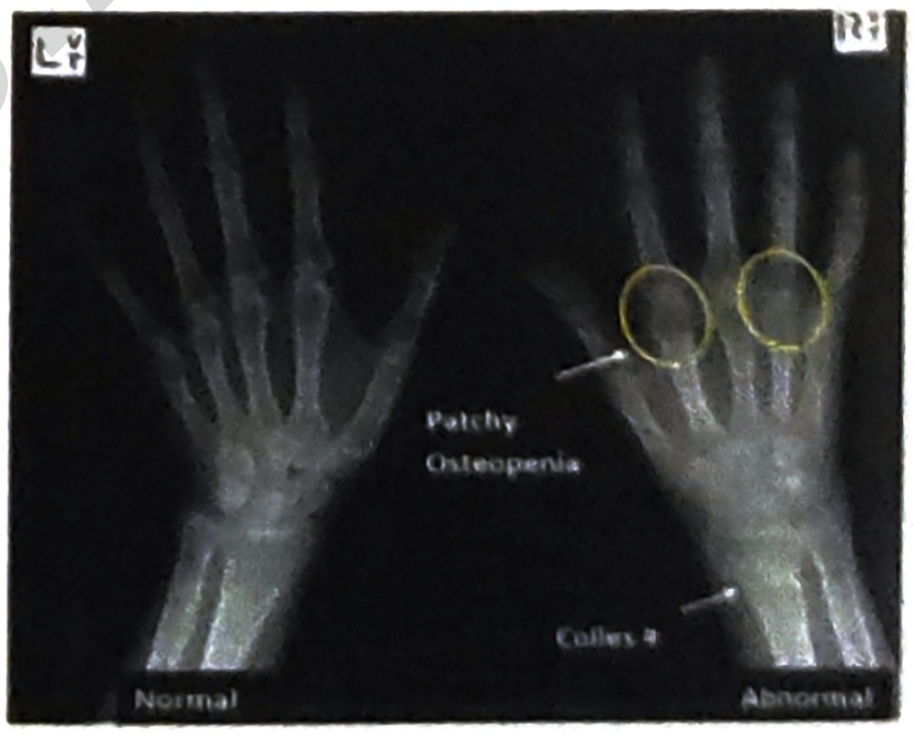

Sudeck's dystrophy

https://t.me/Latestpgnotes

PrepLadder

Thanatophoric Dysplasia 00:10:23

→ MC lethal skeletal dysplasia

→ Has defect in Fibroblast GF receptor - 3

→ Has 2 Subtypes

- Type 1 – has Skeletal Underdevelopment & Telephone handle Appearance of femur
- Type 2 – has clover leaf skull

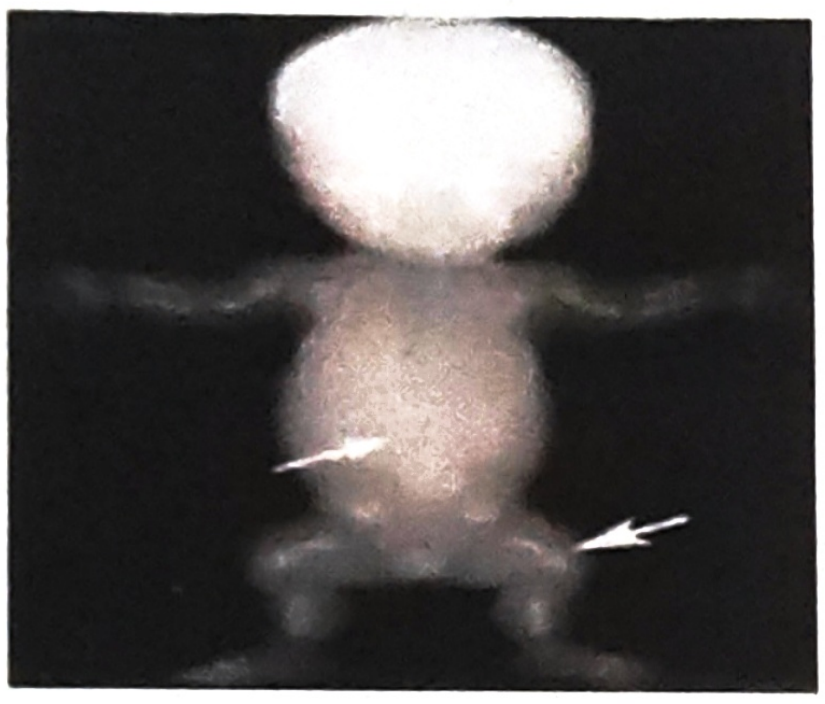

Telephone handle appearance of femur

GCT/Osteoclastoma

→ Characterised by Soap bubble lytic lesion in Epiphyseo-metaphyseal region

→ Occurs only with a fused growth plate

→ Peak incidence between 20-30 yrs of age

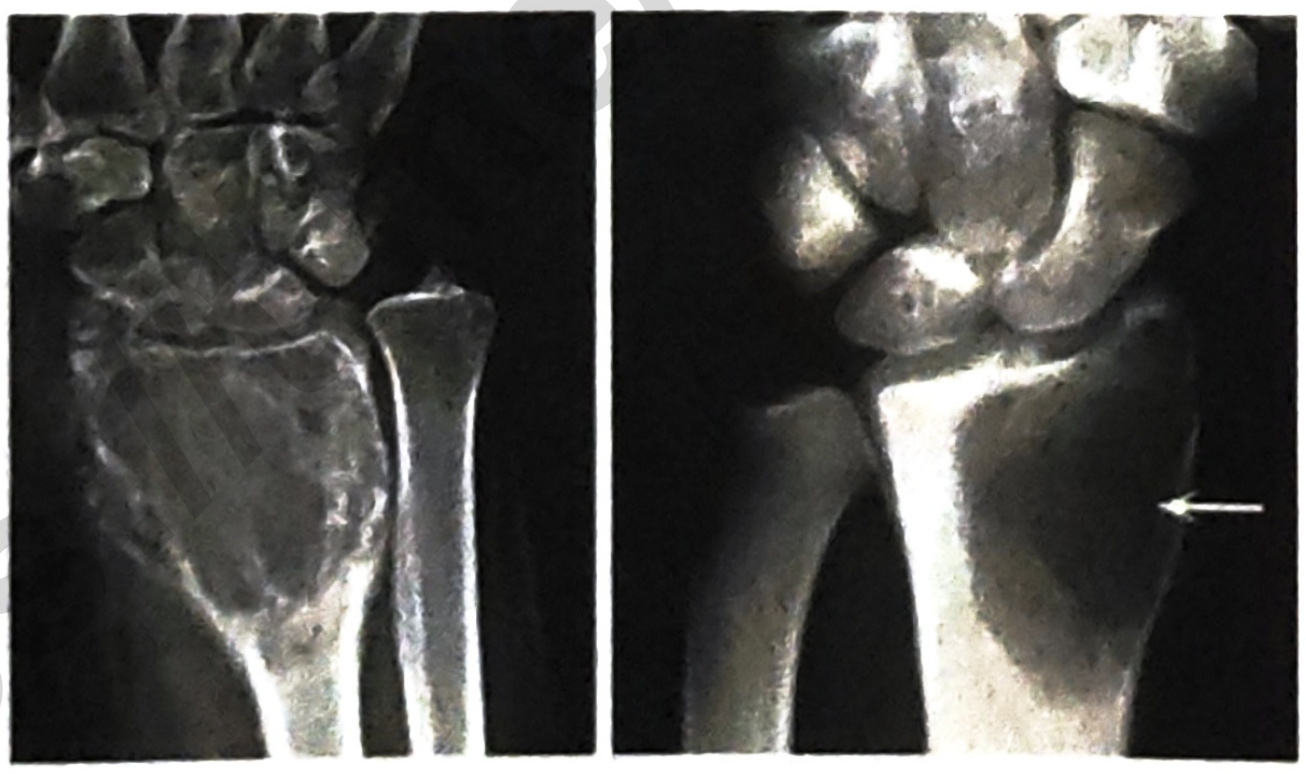

Osteoclastoma

Aneurysmal bone cyst

→ Eccentric, Expansion lytic lesion that elevates the Periosteum but remains Contained by a thin shell of cortical bone

→ Seen only with a non - fused growth plate

→ Shows Fluid -fluid level in MRI

https://t.me/Latestneetpgnotes
PrepLadder

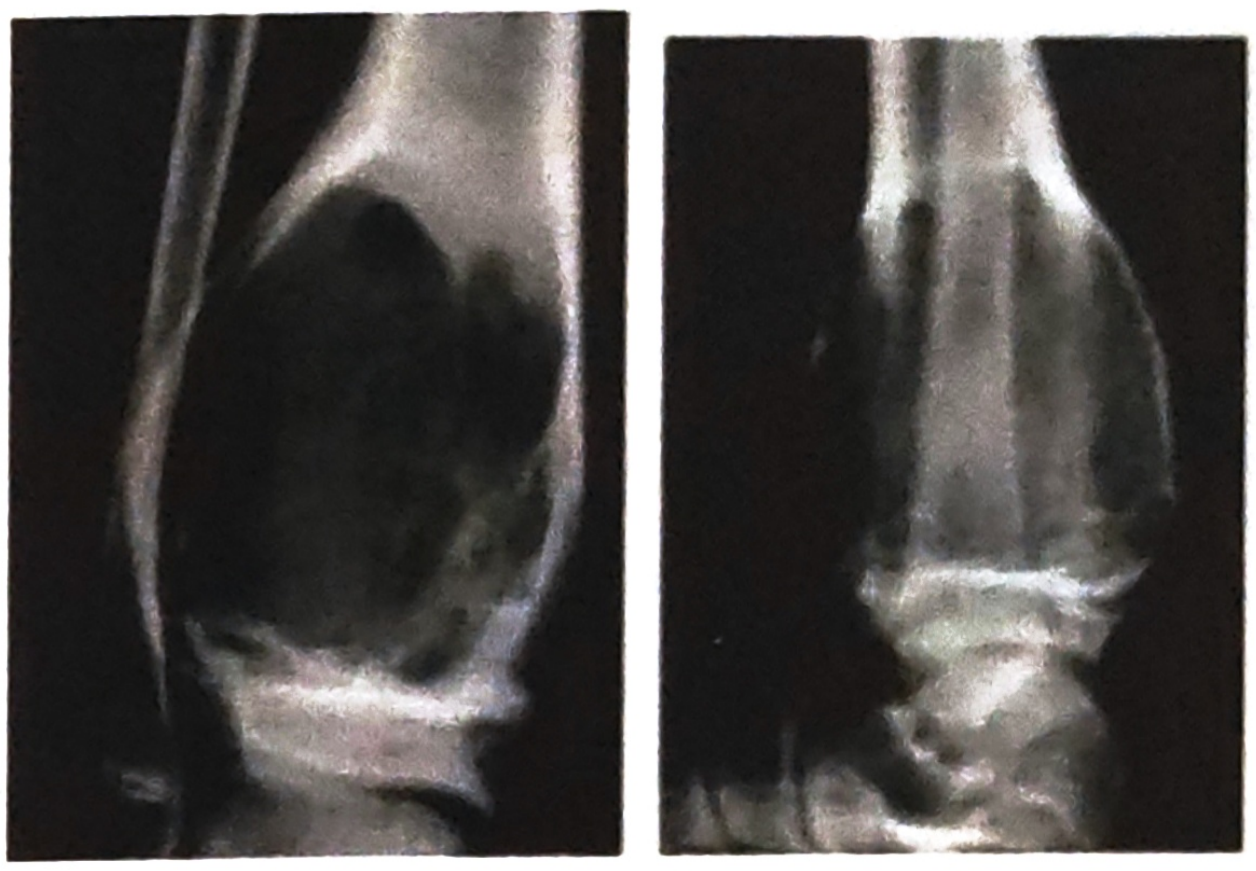

Aneurysmal bone cyst

Madura mycosis 00:13:30

→ Metatarsal region shows
- Granulations – hyperintense circle
- Fungal element – central dot

→ Gives Dot in circle sign on T2W MRI of Foot

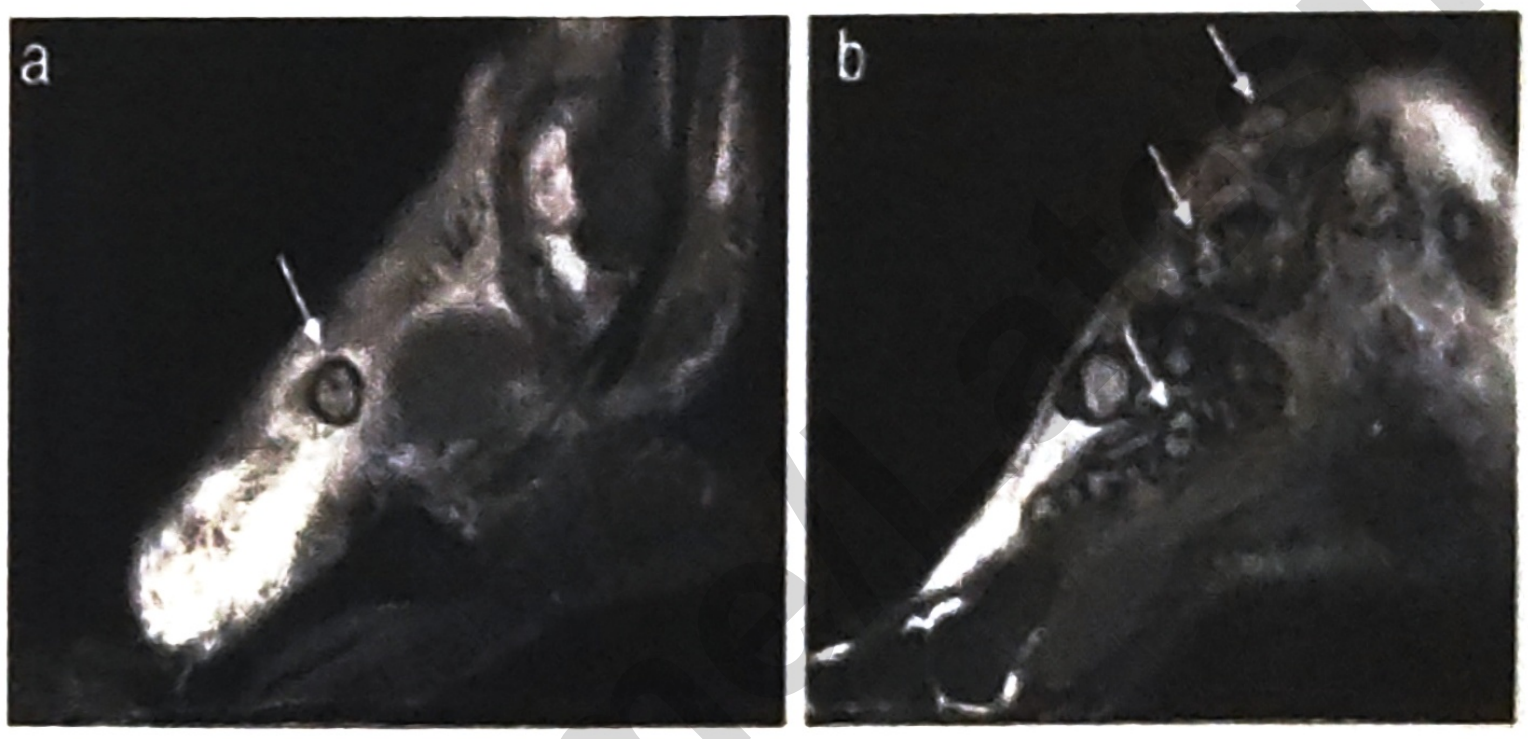

Don't in circle sign (T_2W MRI)

Osteoid Osteoma 00:15:13

→ It is cortical based

→ They have characteristic Central lucent nidus (< 2 cm) within surrounding sclerotic reactive bone

→ Clinically cause night pain that is relieved by use of aspirin

→ On Scintigraphy / Bone scan – shows Double density sign
- Central focus – shows intense Hot Uptake
- Surrounding Sclerotic Area – Also shows hot uptake (But comparatively less)

https://t.me/neetpgnotes

PrepLadder



Osteoid Osteoma

Sacrococcygeal Chordoma 00:17:00

→ Large MC Primary malignant tumors developing at the Sacrococcygeal region

→ Arises from Notochord remnant

→ Most common site – Sacrococcygeal area

→ 2nd MC site – Clivus (Spheno-occipital region)

→ Characteristic features

- soft tissue tumors
- Centrally located
- Destructive & Lytic
- Intra-tumoral calcifications

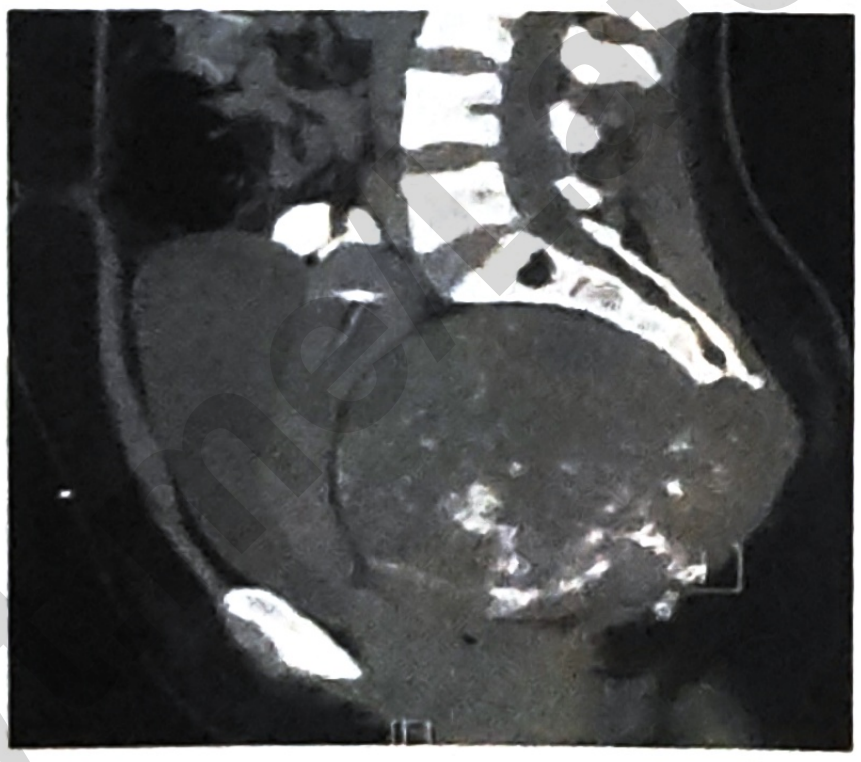

Sacrococcygeal chordoma



Clivus chordoma

https://t...testneetpgnotes

PrepLadder

Osteogenesis imperfecta

00:19:01

→ Aka Lobstein's disease

→ Has Defect in Type I collagen

→ Characteristic features

- Defect in Osteoid matrix formation – Pencil thin cortex
- Multiple transverse diaphyseal fractures
- Presence of Antenatal fracture (Pathognomic)
- Wormian bones
- Blue Sclera

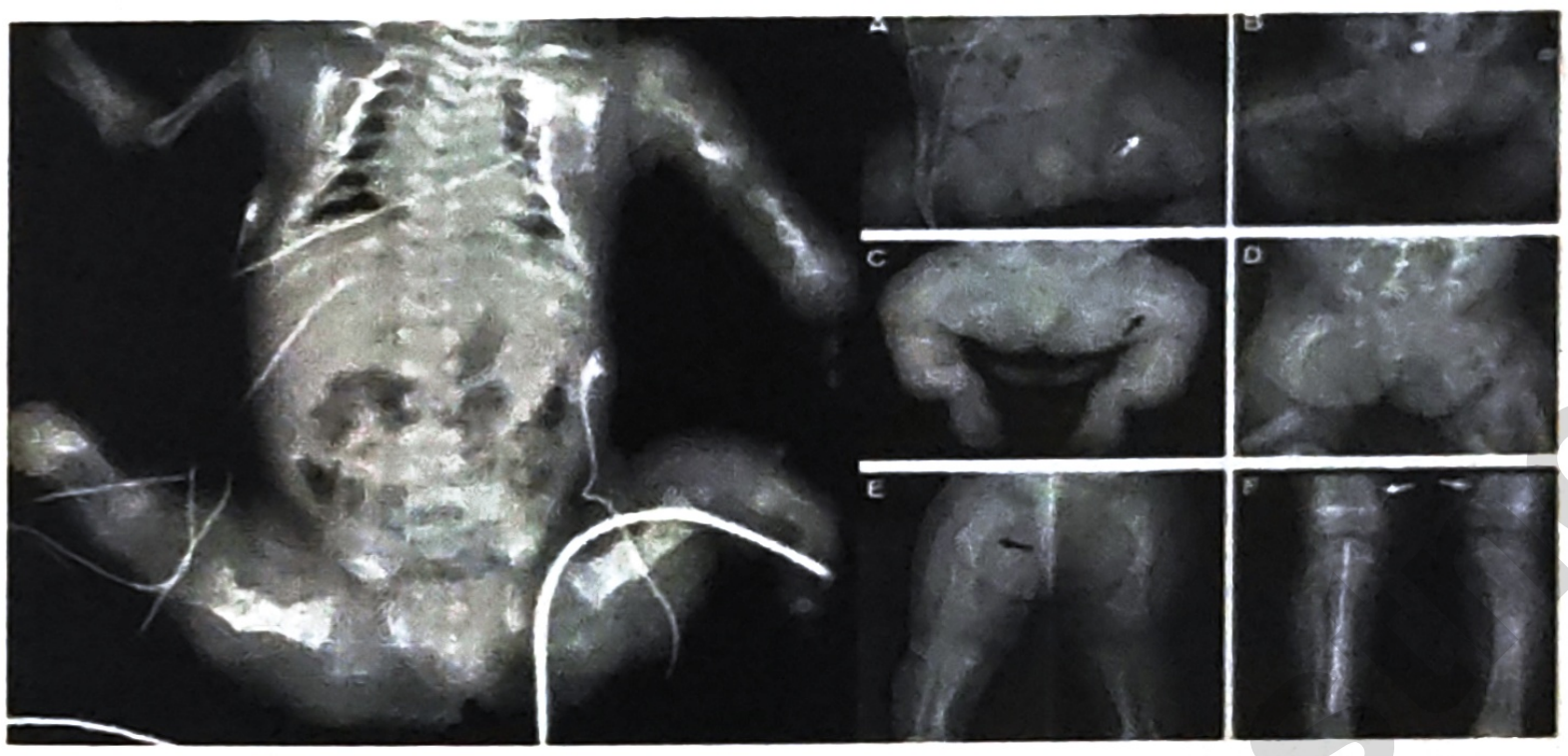

Osteogenesis imperfecta

00:21:05

Osteogenesis imperfecta	Battered baby syndrome / child abuse
→ Blue sclera	→ Absent
→ Dentigerous imperfect	→ Absent
→ BMD↓	→ Normal BMD
→ Wormian bones (intra sutural bones	→ Absent
→ Antenatal fracture	→ Absent
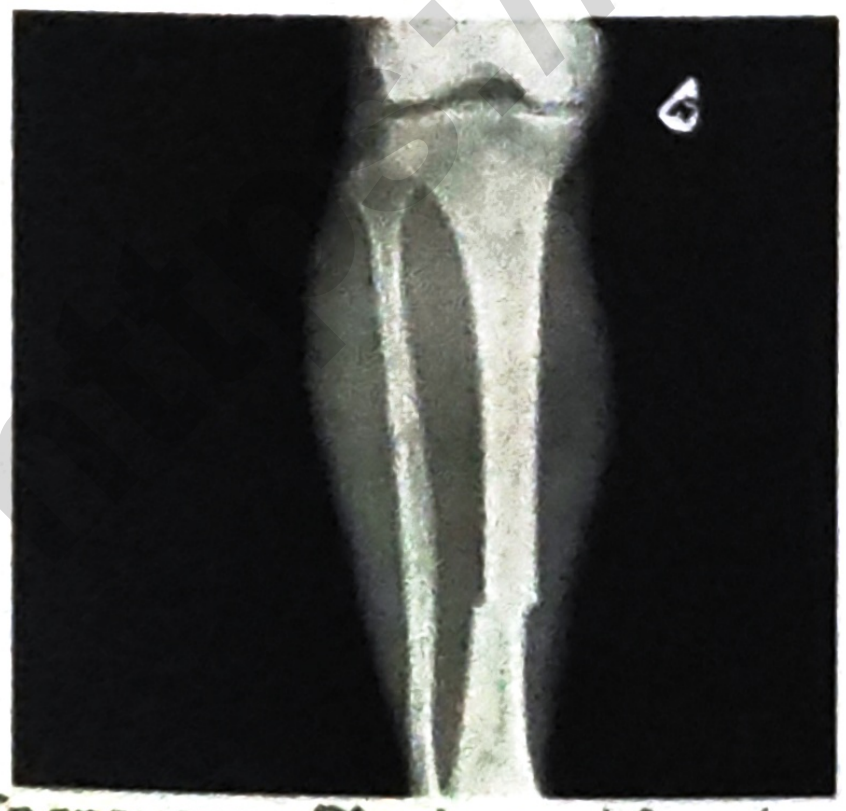 Transverse Diaphyseal fracture	Metaphyseal corner fracture

https://t.me/Latestneetpgnotes

PrepLadder

Chapter 32

Dexa Scan

Dual Energy X-ray absorptiometry

00:00:45

→ The standard of reference for

- Diagnosis of osteoporosis
- Assessment of risk of fractures
- Monitoring response to treatment

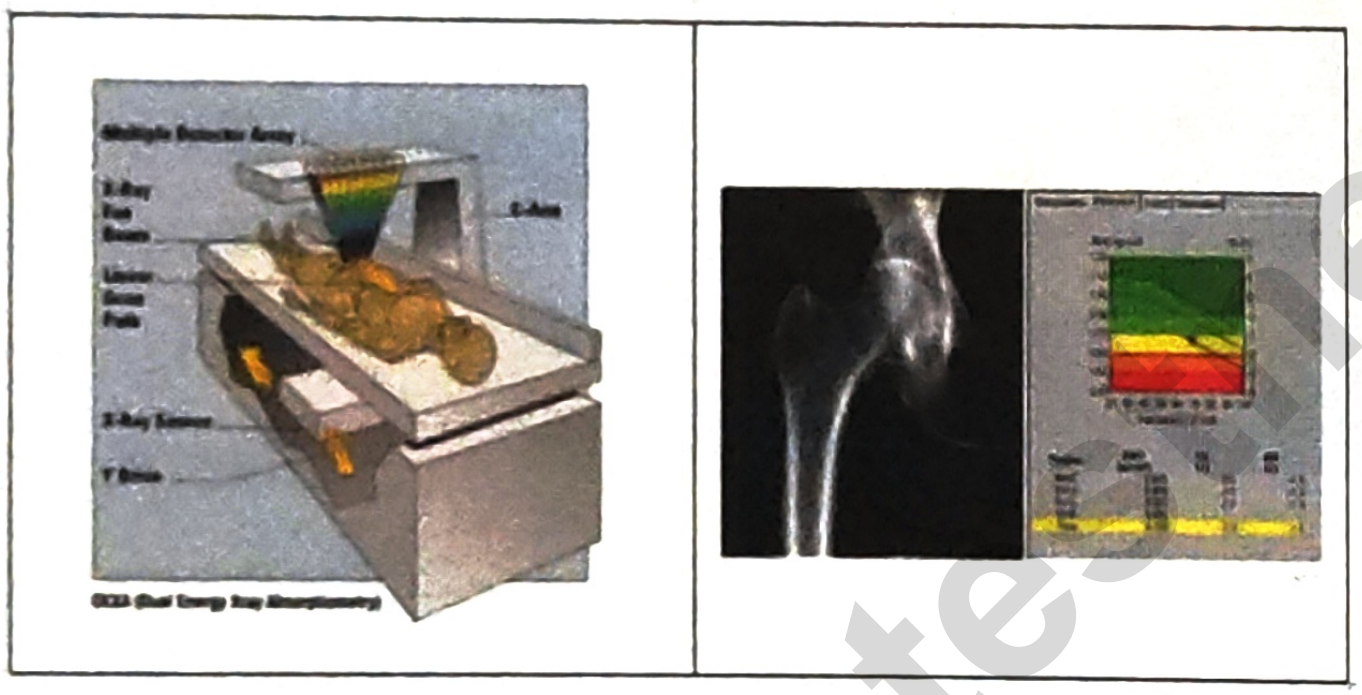

Benefit of DEXA Scan

00:01:18

→ Quantitative

→ High accuracy

→ Reliability

→ Non invasive

→ Low radiation

→ Lean mass fat amass and Bone mineral content

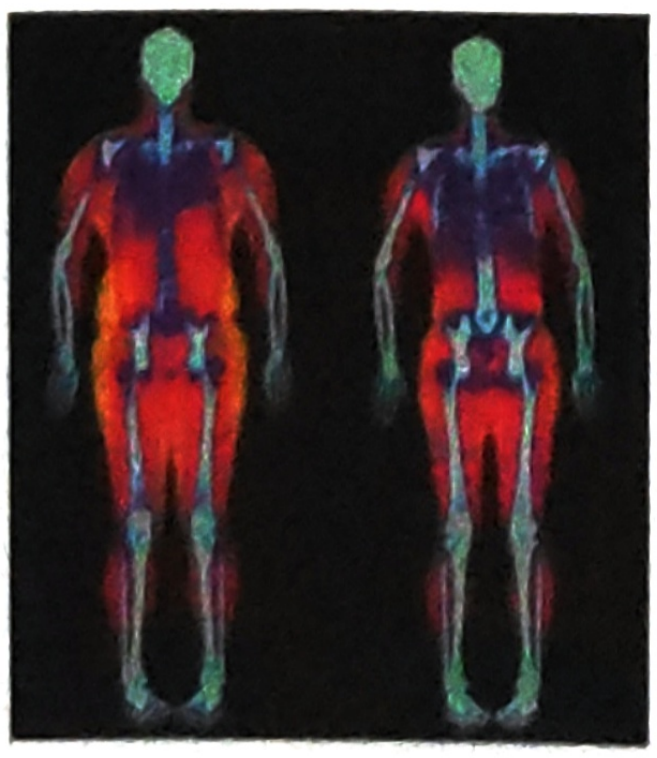

DEXA Scan

https://t.me/Latestneetpgnotes

PrepLadder

How DEXA works 00:03:05

- → 2 X-ray beams with 2 different energy peaks are passed through the body, one peak gets absorbed by the soft tissue and the other by the bone
- → Generates a two dimensional image
- → Soft tissue amount is subtracted from the total area, giving the bone mineral density

Indications for Bone mineral Density Testing 00:03:25

- → All women age 65 and older
- → All men age 70 and older
- → Adults with a fragility fracture
- → Adults with a disease or condition associated with low bone density
- → Adult taking medication associated with low bone density
- → Anyone being treated for low bone density to monitor treatment effect
- → Anyone not receiving therapy, in whom evidence of bone loss would lead to treatment
- → Women discontinuing osteoporosis treatment.

Bone Densitometry Devices 00:04:48

Central Device
- Evaluate Hip, Lumbar

Peripheral Device
- Evaluate peripheral areas

https://t.me/Latestneetpgnotes

Note:

- → Central Device – More preferred in Monitoring treatment of Osteoporosis

PrepLadder

Skeletal sites

→ Hip

→ Lumbar spine

→ Non-Dominant forearm

Note:

Best site

→ Lumbar spine since there is more trabecular content – more metabolism will be there.

Bone mineral Density 00:07:35

→ Expressed in Terms of Standard Deviation as a T score and Z score

→ T score describes the difference of bone mineral density of patient and the mean BMD of a standard young adult of 20-30 years

→ Z score describes the difference of patients BMD and the mean BMD of Age and gender matched controls.

WHO T SCORE

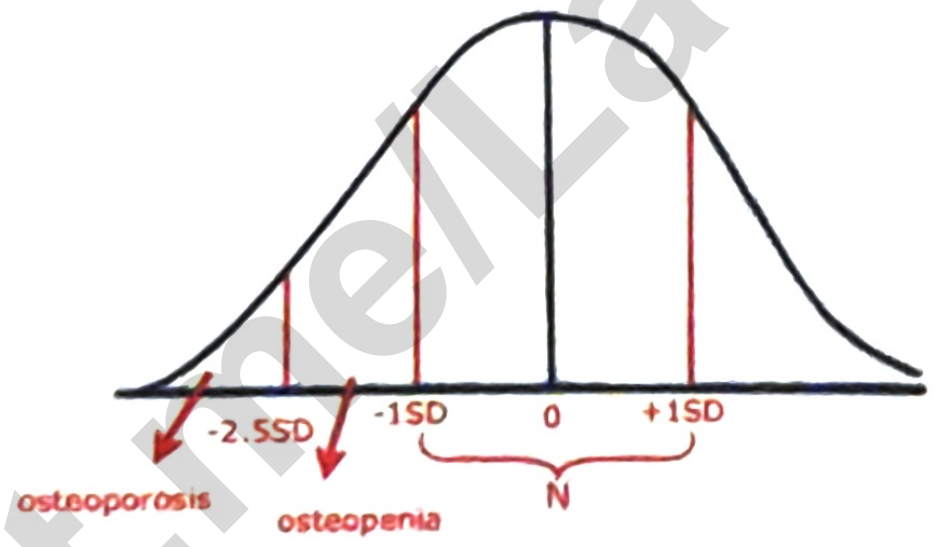

Note:

T socre

- +1 SD to – 1SD → Normal
- -1 SD to -2.5 SD → Osteopenia
- >- 2.5 SD → Osteoporosis
- >- 2.5 SD + Fragility fracture → Severe osteoporosis

Limitations of DEXA

→ It cannot distinguish between cortical and trabecular bone, or changes due to bone geometry

https://t.me/Latestneetpgnotes

PrepLadder

Quantitative CT-Scan 00:10:31

→ It provides separate estimates of trabecular and cortical bone BMD

→ Measures trabecular BMD at Lumbar spine excluding the effects of Cortical bone and Spinous process

→ Measures BMD in gms per cc

→ There is lack of reference data for comparison for QCT

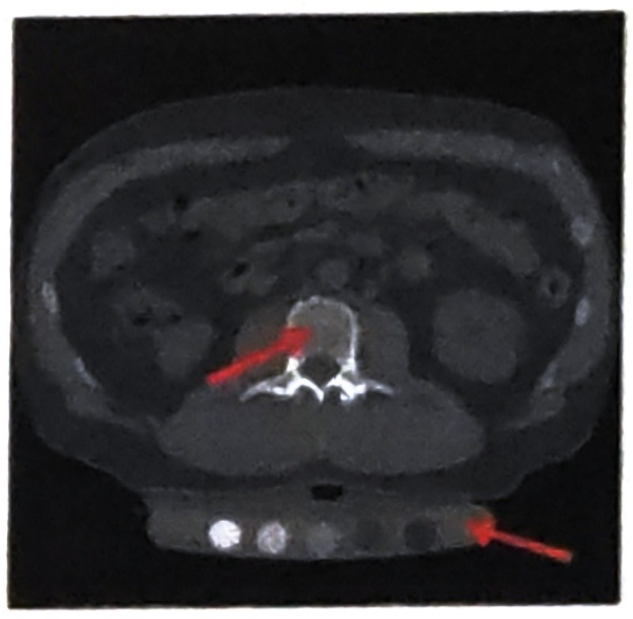

Quantitative CT – Scan

Percutaneous Vertebroplasty 00:12:20

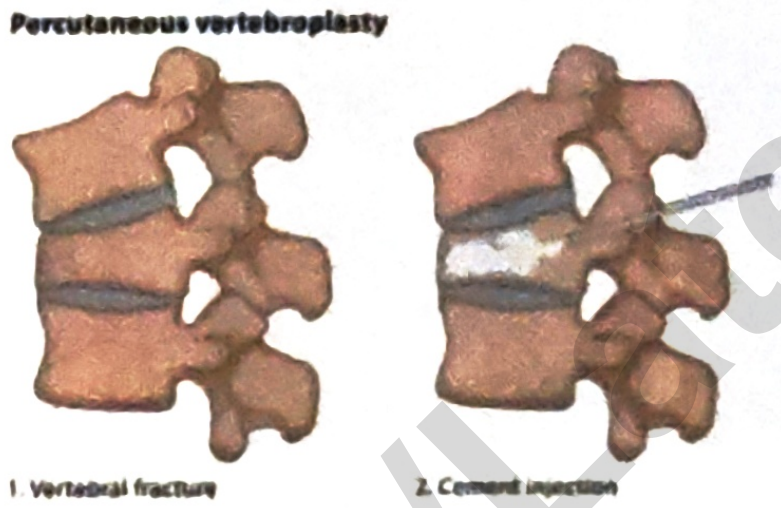

→ Interventional radiology technique – outpatient procedure

→ Cement is injected in the affected vertebral body under CT or fluoroscopy guidance

→ Cement used – "PMMA" – Polymethylmethacrylate

→ Improves stabilization of the joint and provides, significant pain relief.

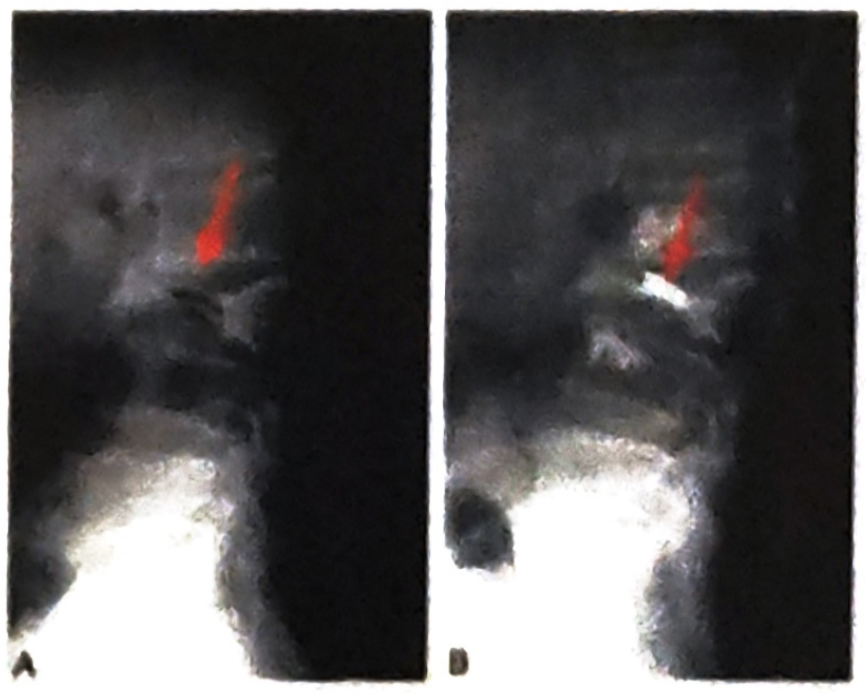

Percutaneous Vertebroplasty

https://t.me/Latestneetpgnotes

Chapter 33

CARDIO VASCULAR RADIOLOGY

Aortic aneurysm

00:00:20

- →Involve either ascending aorta, thoracic aorta & abdominal aorta
- →Syphilitic aortitis commonly involve ascending aorta causing aortic aneurysm
- →M/C cause for abdominal & thoracic aortic aneurysm – Atherosclerosis

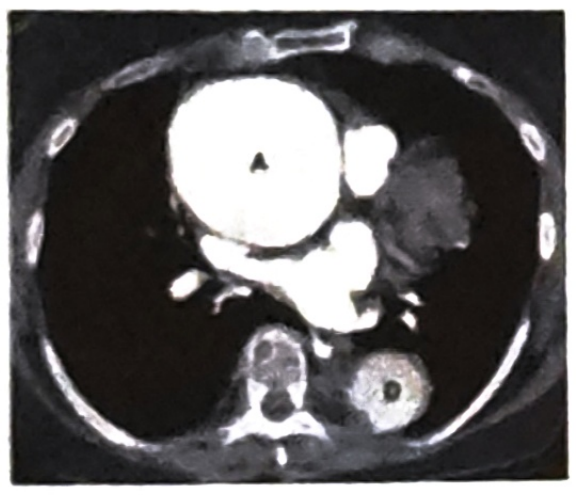	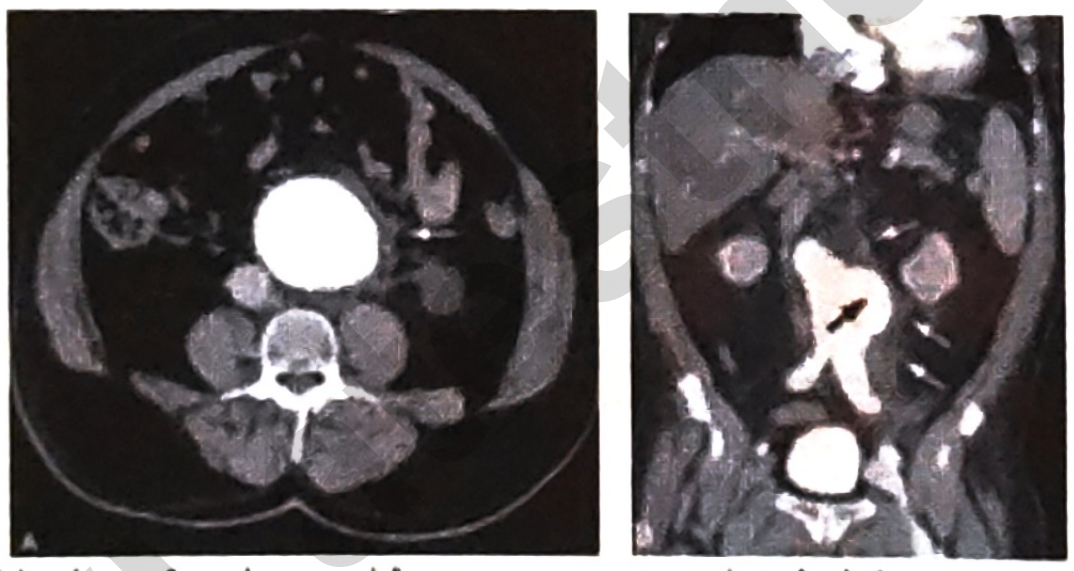
Ascending aortic aneurysm	Abdominal aortic aneurysm (axial & coronal view)

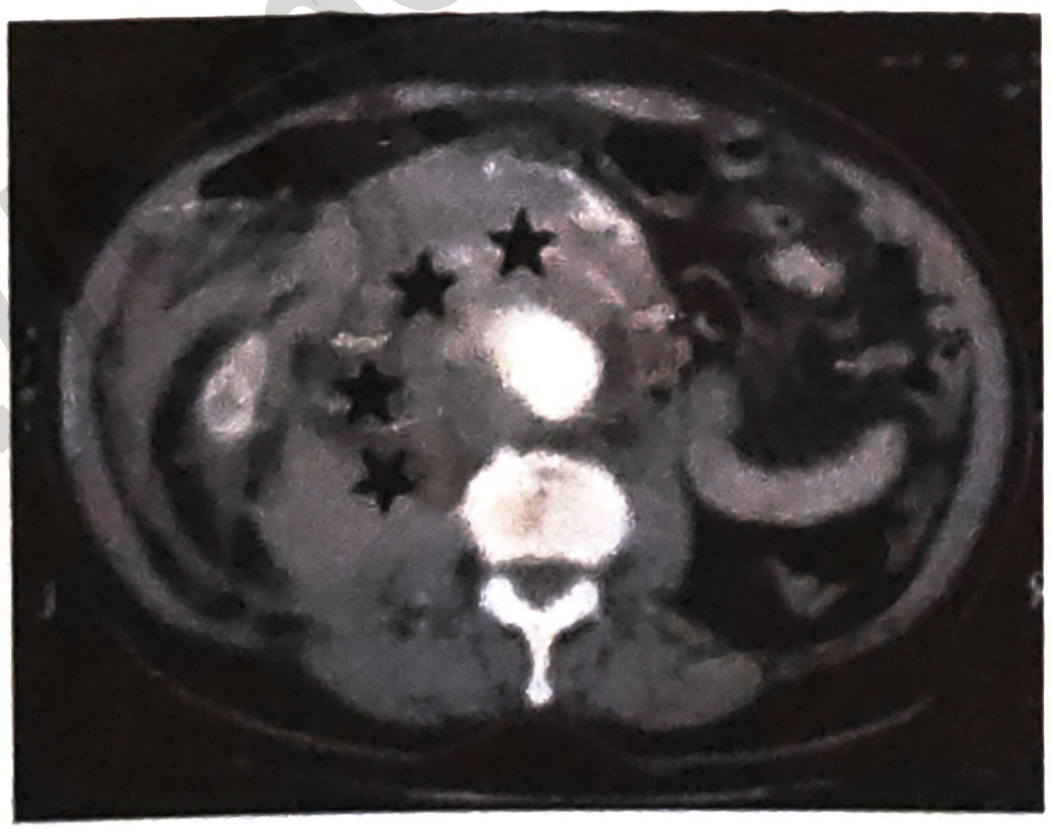

Ruptured aortic aneurysm (collection noted around the vessel)

https:/ … e/L … neetpgnotes

PrepL

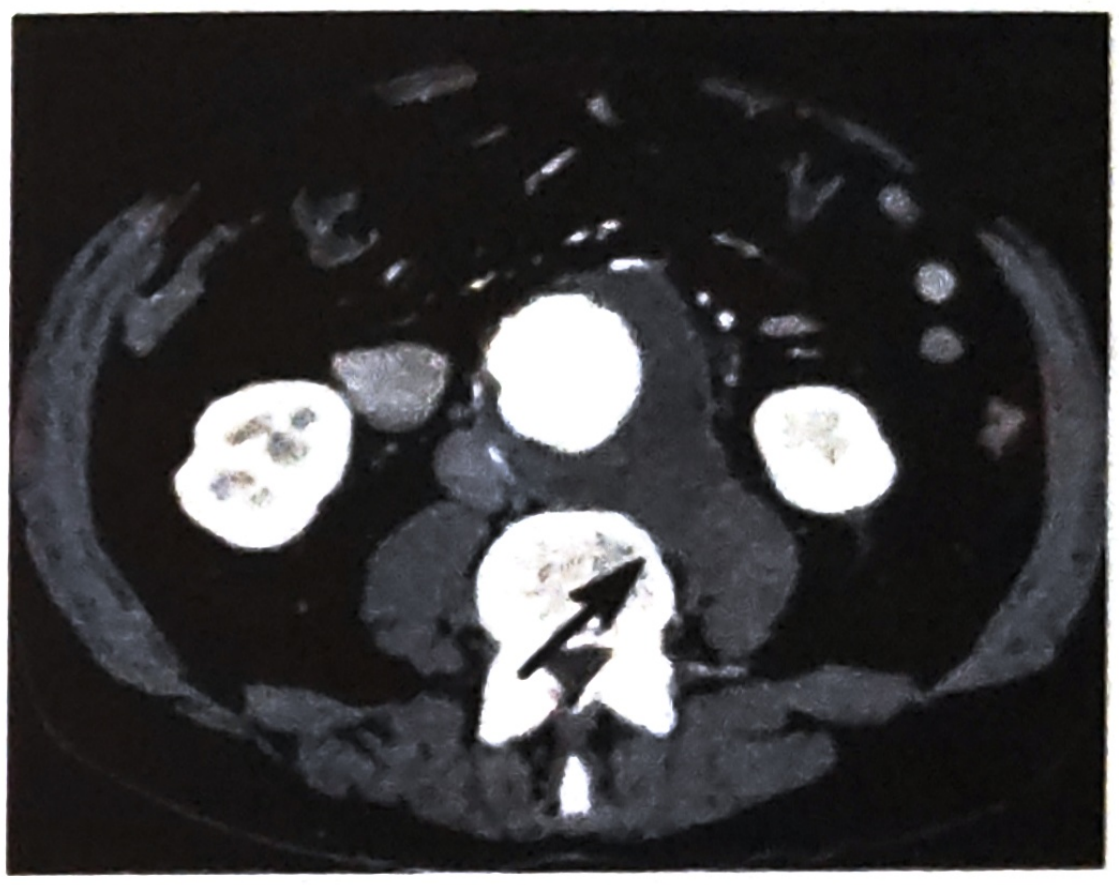

Draped aorta sign on CECT – seen in contained Rupture of Abdominal Aortic aneurysm

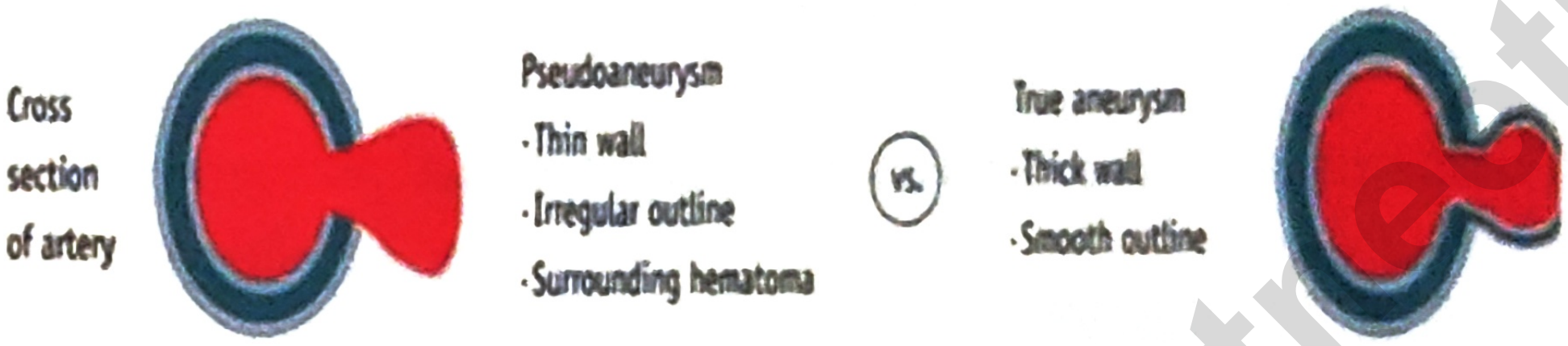

Color doppler image of Pseudo aneurysm

→Bidirectional flow of blood is seen which gives Yin-yang sign

→Also seen in Pseudo Aneurysm and in large true aneurysm



Yin-yang sign

Aortic dissection

00:08:19

→Double lumen appearance with an intimal flap

→For acute aortic dissection – TEE or MDCT with contrast

→For chronic aortic dissection – MRI

https://t.me/Latestreetpgnotes

PrepLadder

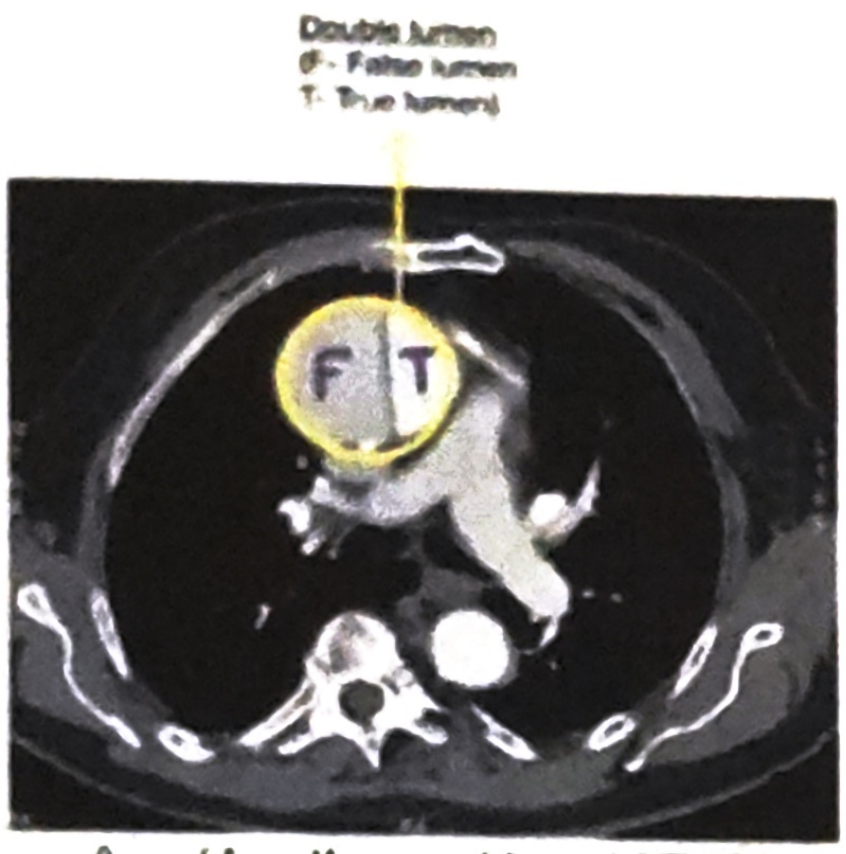

Aortic dissection (CECT)

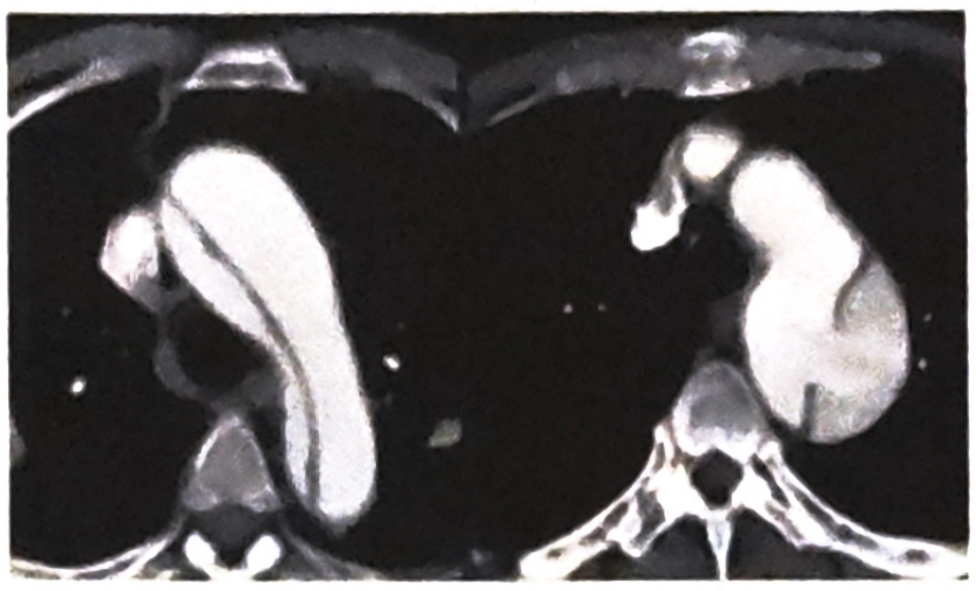

Dissection extending to Arch & descending aorta

Note:

→Dissection of arterial wall forming shreds within false lumen- "Cob web sign"

→False lumen forms an acute angle giving "Beak sign" in aortic dissection

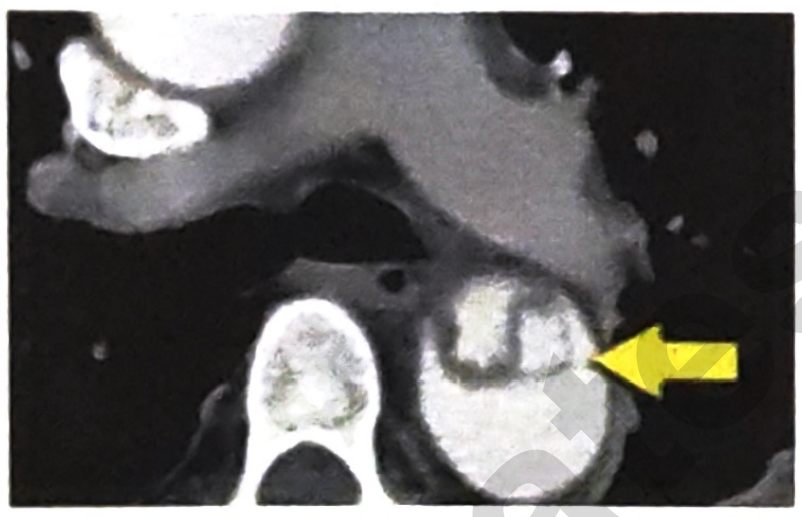

Cob web sign

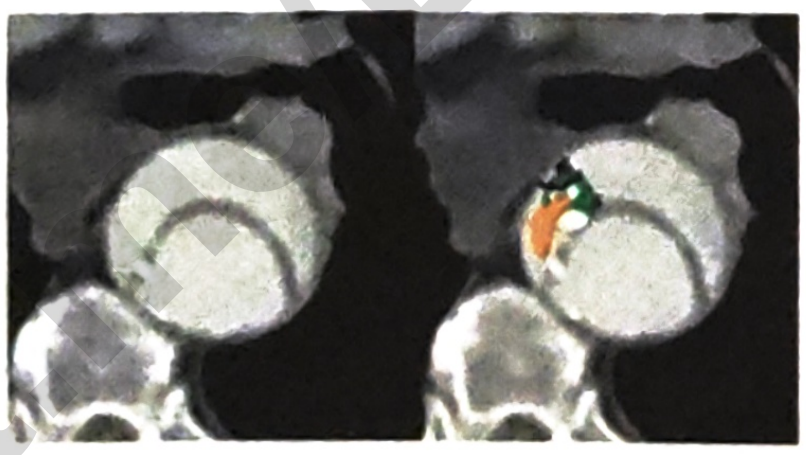

Beak sign

Classification of aortic dissection

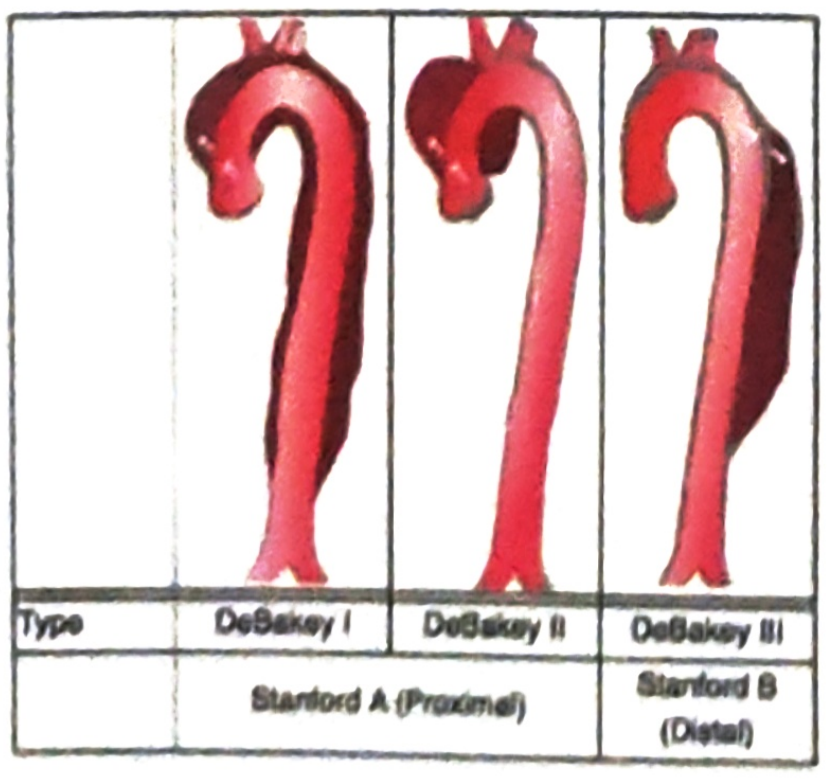

PrepLadder

https://t.me/Latestneetpgnotes

Congenital heart disease 00:10:26

ASD

→ Causes pulmonary plethora – seen in fluoroscopy is Known as "Great hilar dance"

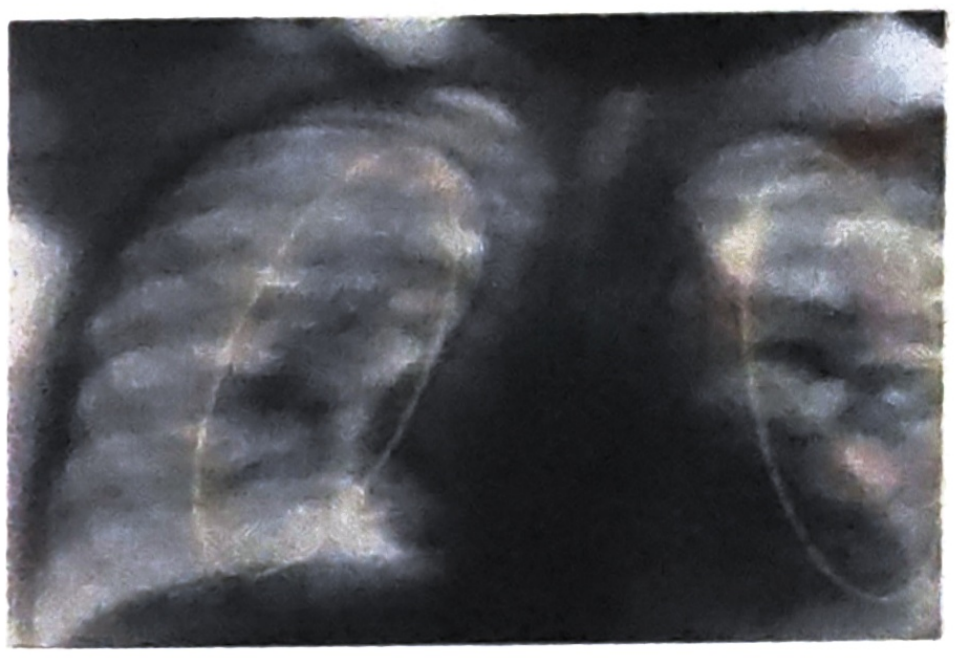

Great hilar dance

Tetralogy of Fallot 00:13:03

→ Pulmonary stenosis

→ Overriding aorta

→ Membranous VSD

→ RVH

→ "Boot shaped of heart" in X-Ray

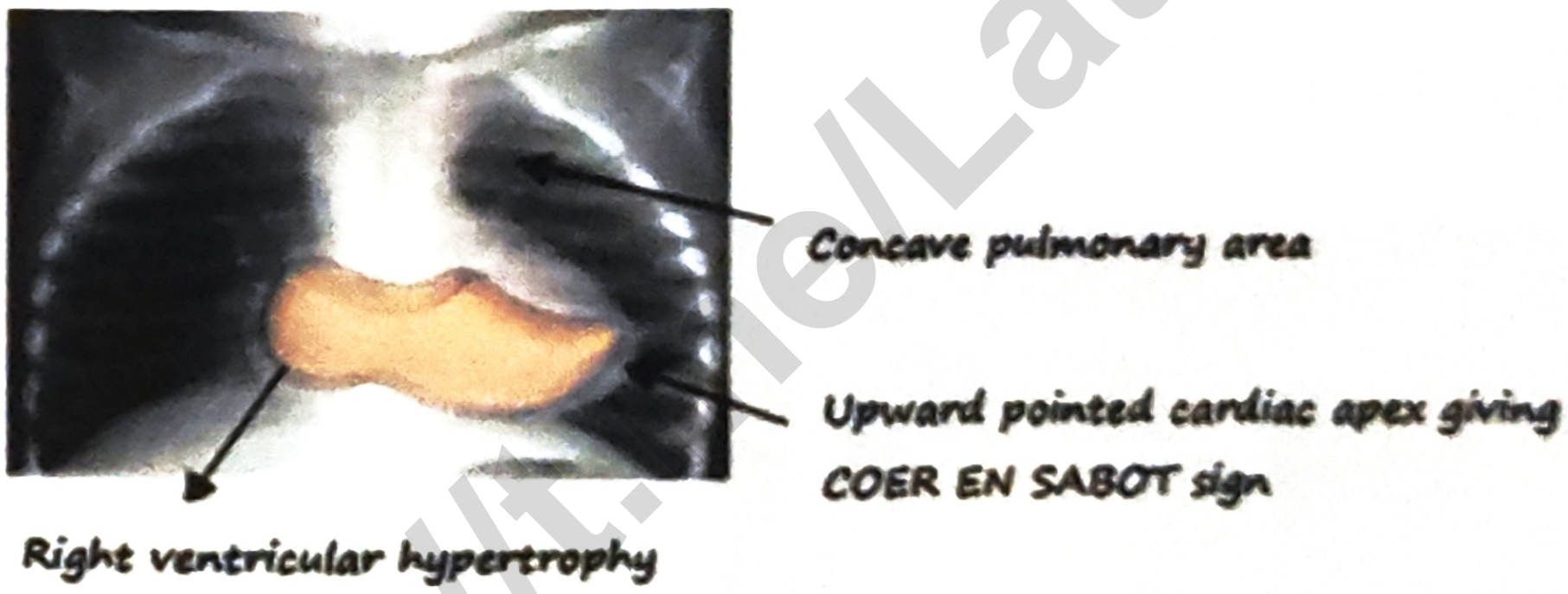

Gooseneck deformity 00:19:00

→ Seen in AVSD & also in endocardial cushion defect – Primum type of ASD

→ Aortic valve is pushed anteriorly & elongated – gives goose neck deformity in USG & cardiac angiogram

→ Leads to Sub – aortic obstruction

https://t.me/Latestneetpgnotes

PrepLadder



Gooseneck deformity – LVOT elongated seen in AVSD (Atrioventricular septal Defect)

TGA: Transposition of Great Arteries) 00:21:26

→Narrow mediastinum

→Globular heart

→"Egg on string" / "egg on side" appearance in X-ray

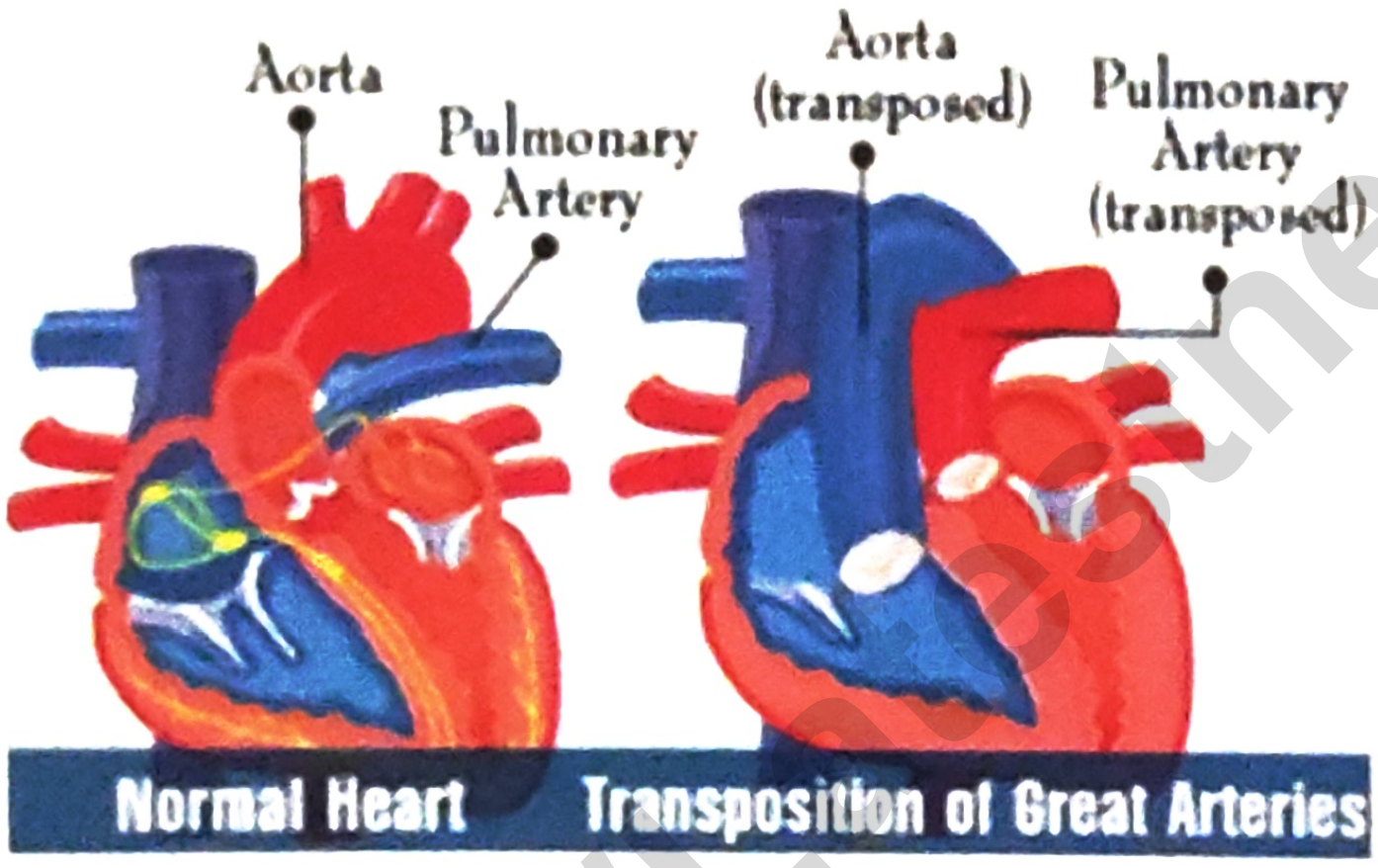

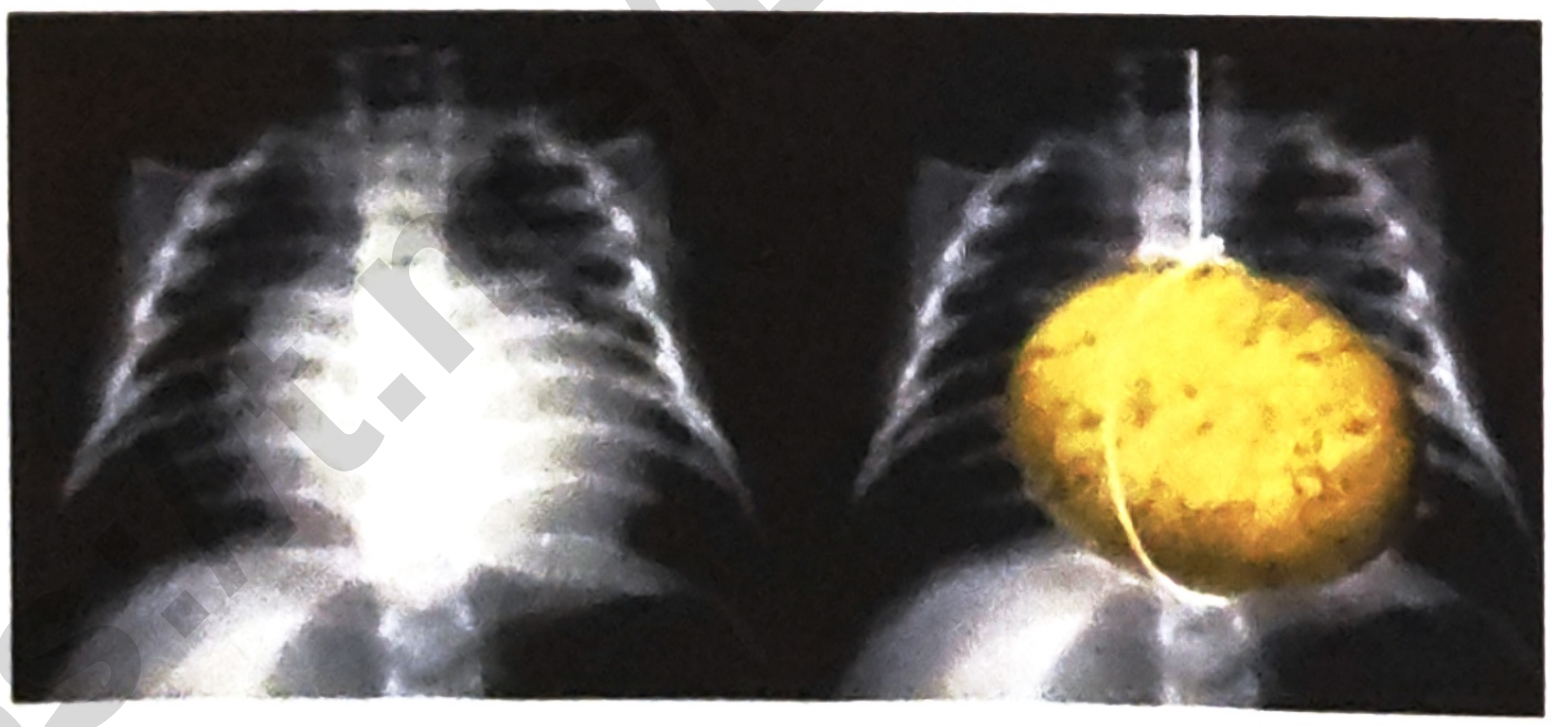

Egg on string/egg on side

Truncus arteriosus

→Persistent truncus arteriosus gives "sitting duck" appearance in radiograph

→Associated with VSD

https://t.me/Latestneetpgnotes

PrepLadder



Sitting duck appearance

Ebstein anomaly

→Has low insertion of tricuspid valve causing arterialization of Rt ventricle

→Small right ventricle

→Associated with ASD & PDA

→Gives "box shaped heart"

→Pulmonary oligemia is also seen

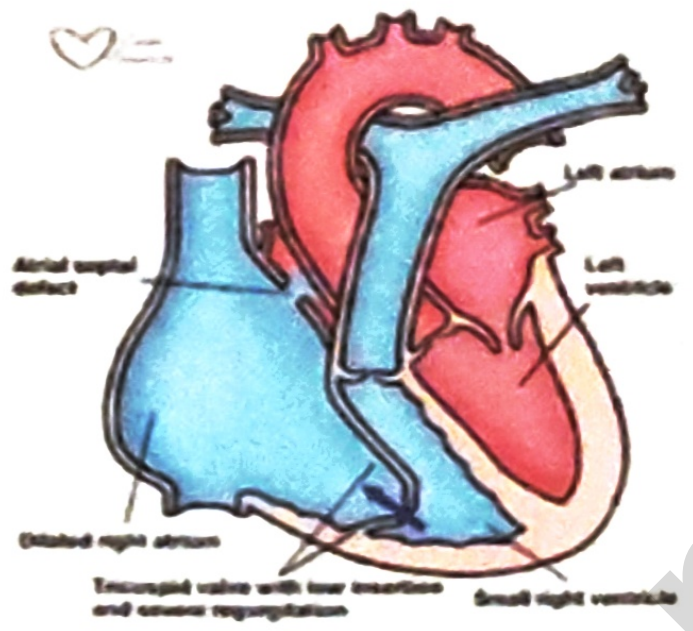

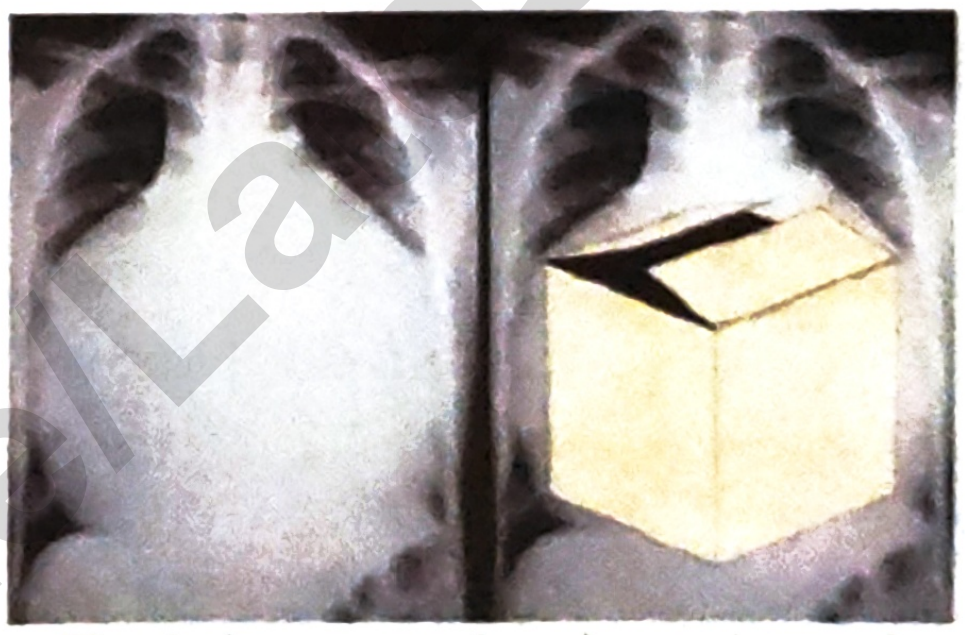

Ebstein anomaly - box shaped heart

Total anomalous pulmonary venous connection 00:26:06

→Supra cardiac TAPVC

→Snowman / figure of 8 /cottage loaf appearance

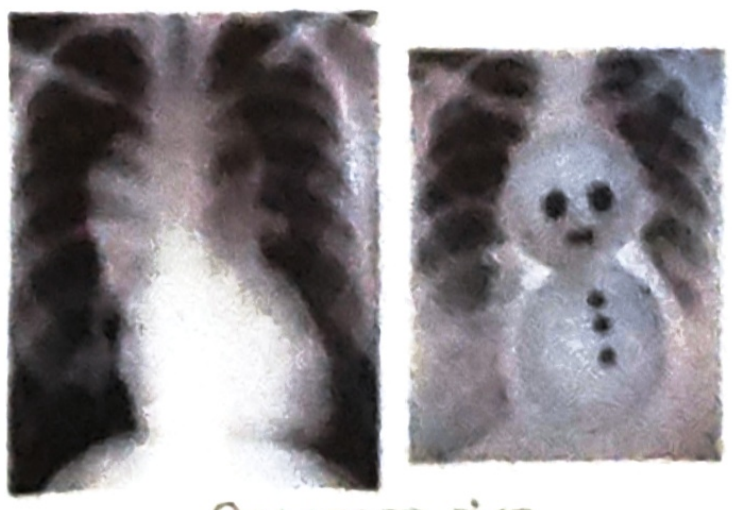

Snowman sign

https://t.me/Latestneetpgnotes

PrepLadder

Note:

→ Figure of 8 appearance is seen only in supra cardiac TAPVC & not in infra cardiac TAPVC

→ Partial anomalous pulmonary venous connection

- "Scimitar sign" is seen in PAPVC
- It is more common on right side

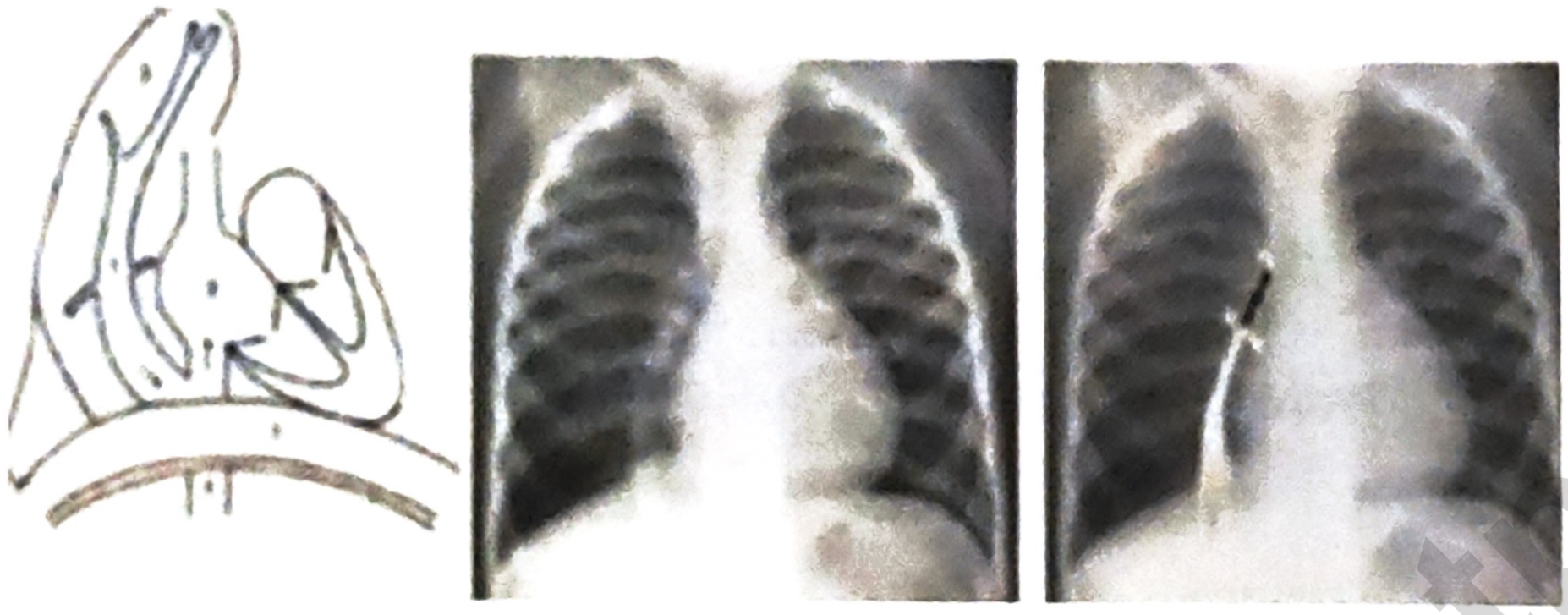

Scimitar sign

Coarctation of Aorta 00:30:26

Coarctation of Aorta

- Infantile → Preductal coarctation
- Adult → Post ductal coarctation

→ M>F

→ Turners syndrome female – more prone

→ Inferior rib notching is seen – If > 10 years

→ "3 sign" – seen in CXR

→ "Reverse 3 sign" – seen in 3-9 ribs & usually seen in 4-8 ribs

→ Inferior rib notching is seen in 3-9 ribs & usually seen in 4-8 ribs

Note:

→ Both superior & inferior rib notching can occur in hyperparathyroidism & Neurofibromatosis.

https://t.me/Latestneetpgnotes

PrepLadder

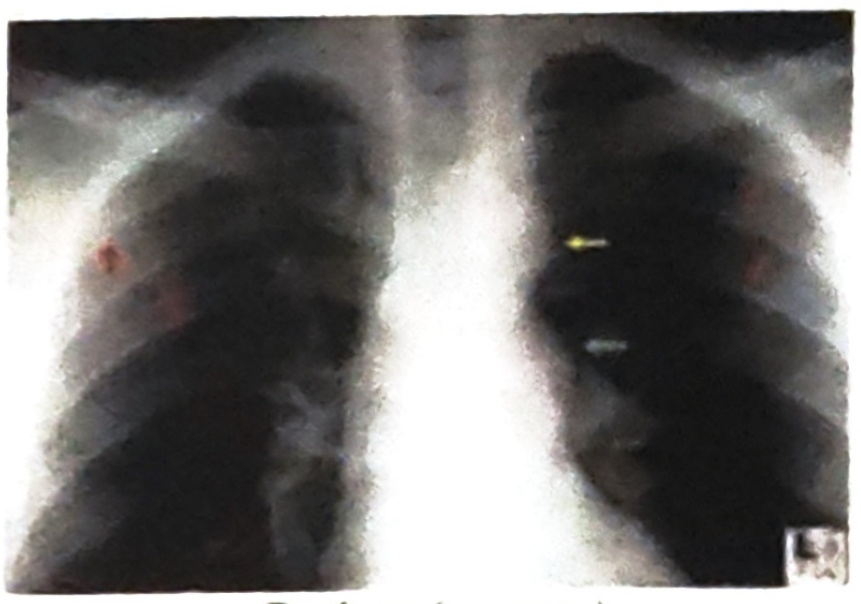

3 sign (x-ray)

Reverse 3 sign (barium swallow)

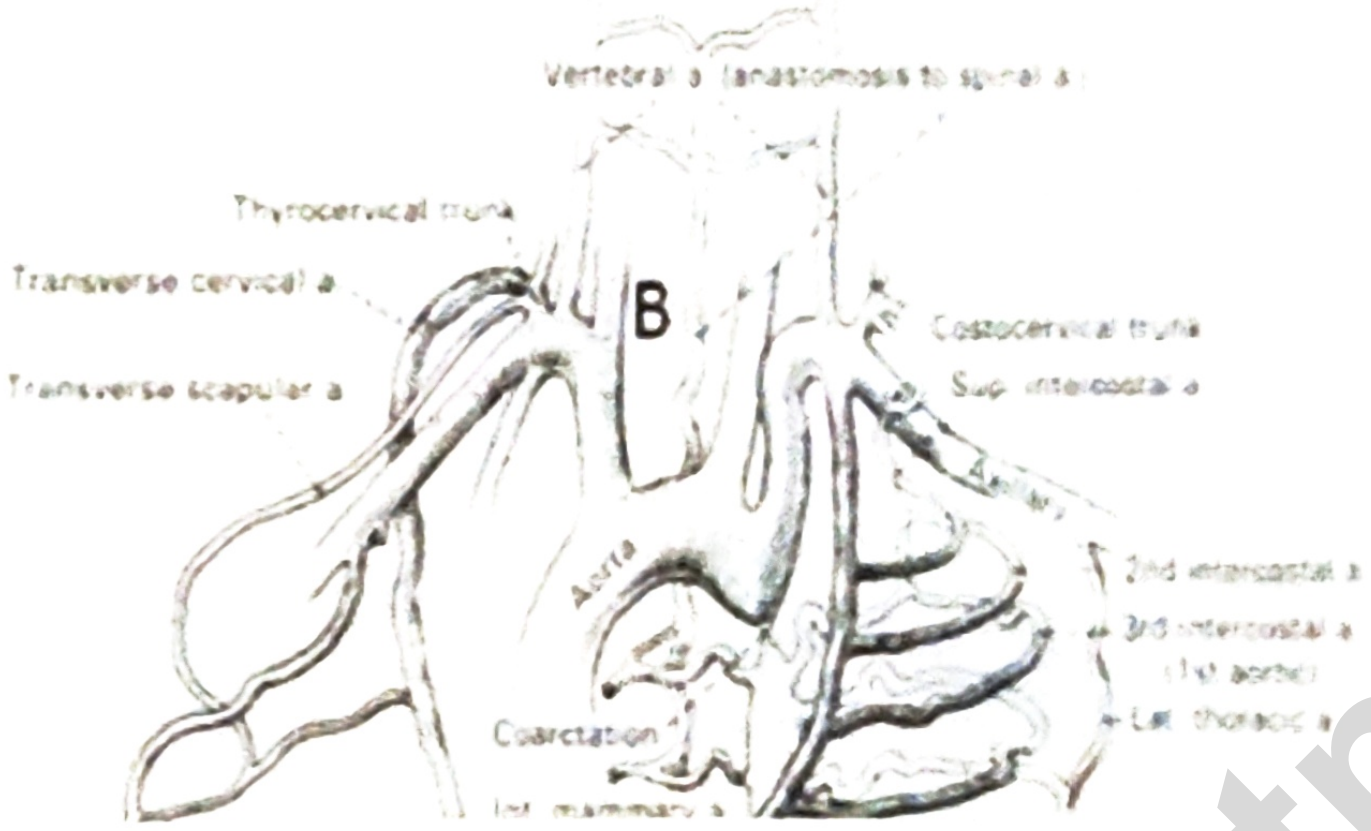

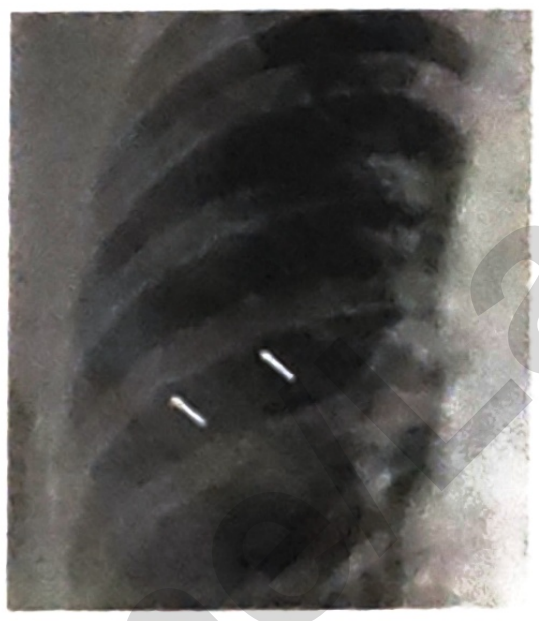

Inferior rib notching

Constrictive Pericarditis 00:37:52

→Shows calcification of Pericardium in a radiograph

→Gives "egg in cup" appearance

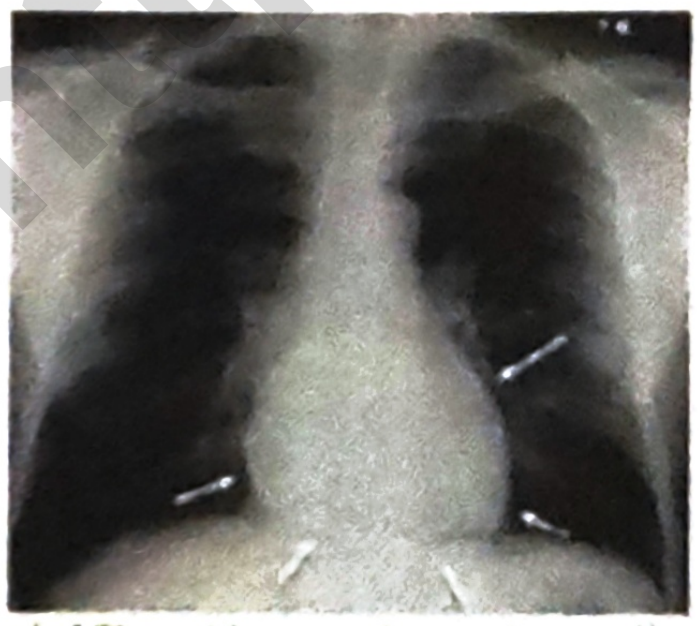

Calcification of pericardium

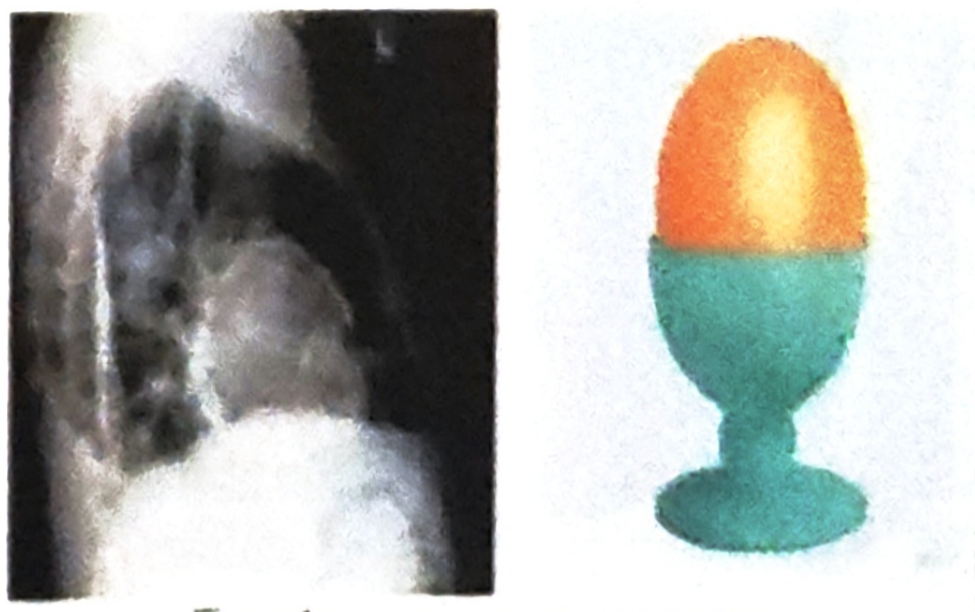

Egg in cup appearance

https://t.me/latestneetpgnotes

PrepLadder

Hypertrophic obstructive cardiomyopathy (HOMP)

→ Has asymmetrical thickening of interventricular septum

→ Has systolic anterior motion of mitral valve

→ Associated with mitral regurgitation

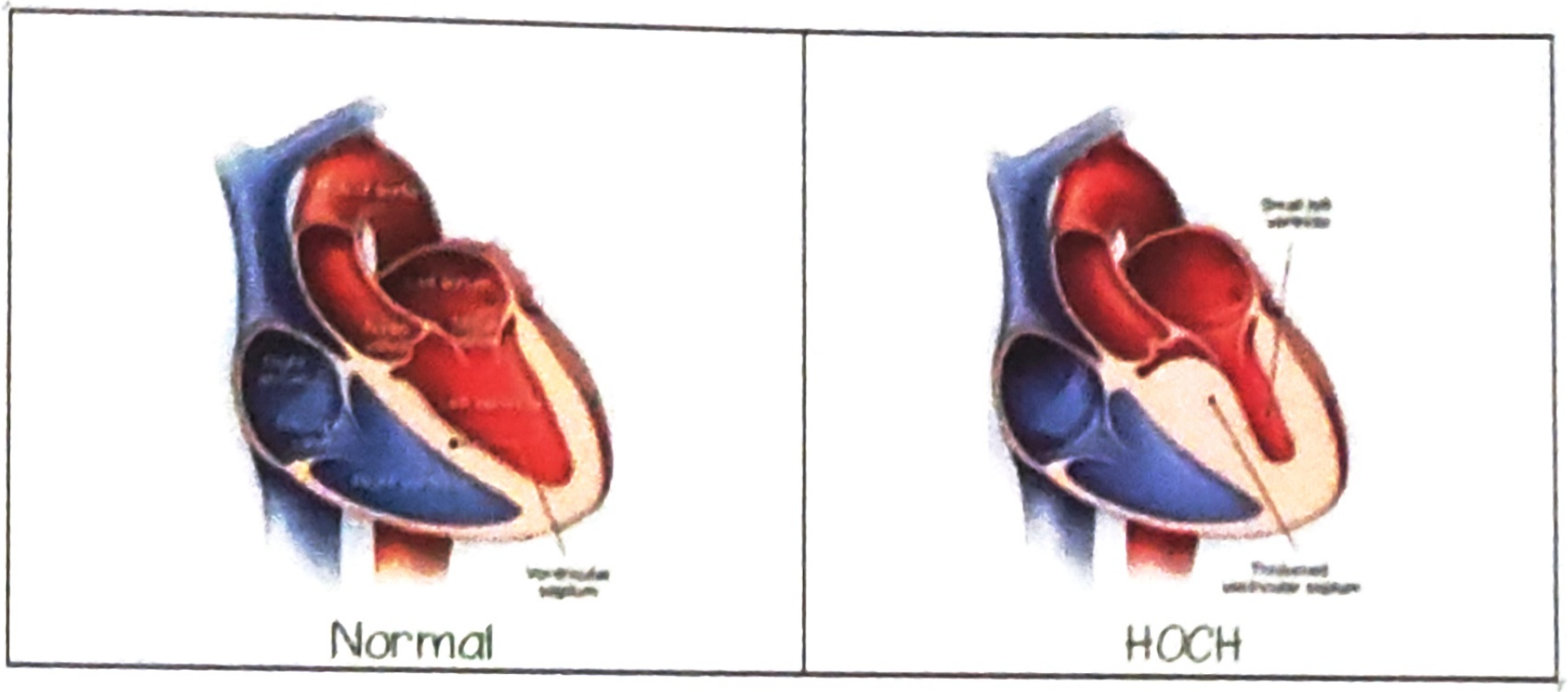

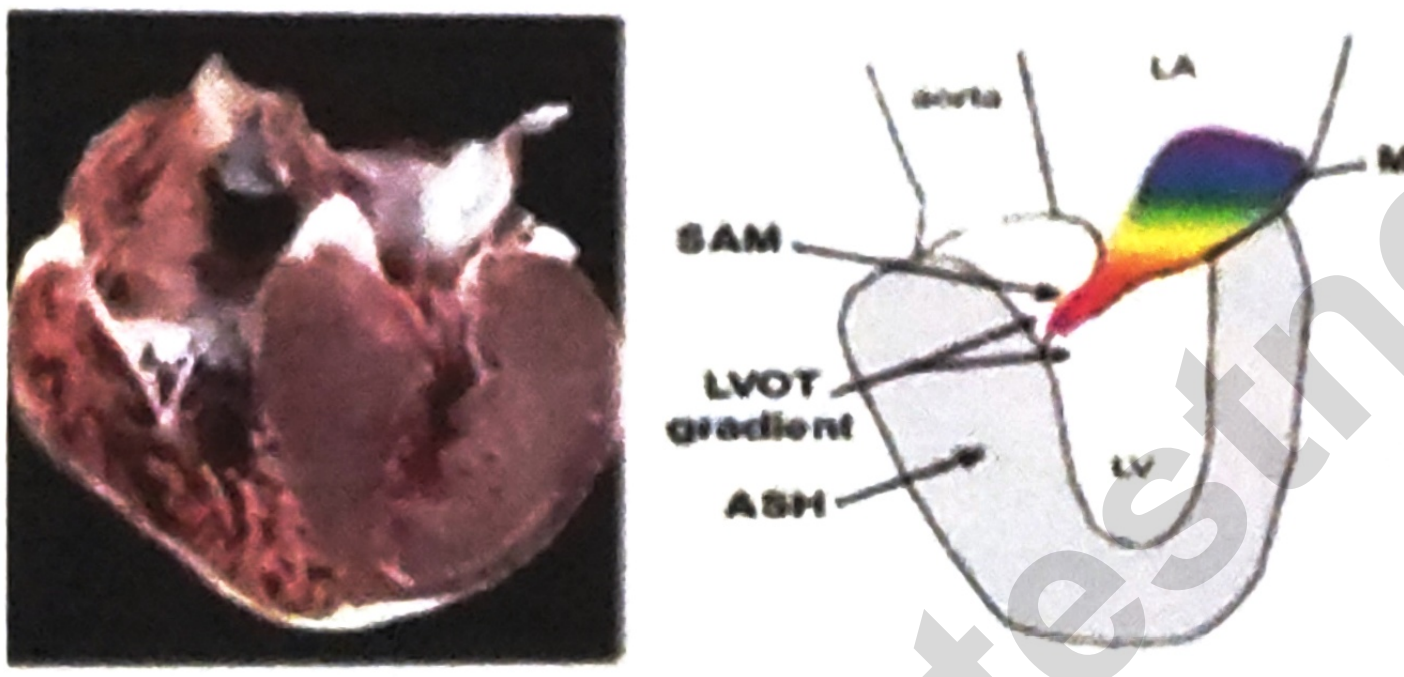

Mechanism of HOCH

Left atrial enlargement / mitral stenosis 00:40:10

→ Straightening of left heart borders

→ Widening of carina with elevated left main bronchus

→ Walking man sign

→ Double Right Heart Border / Double density sign

→ Third mogul sign

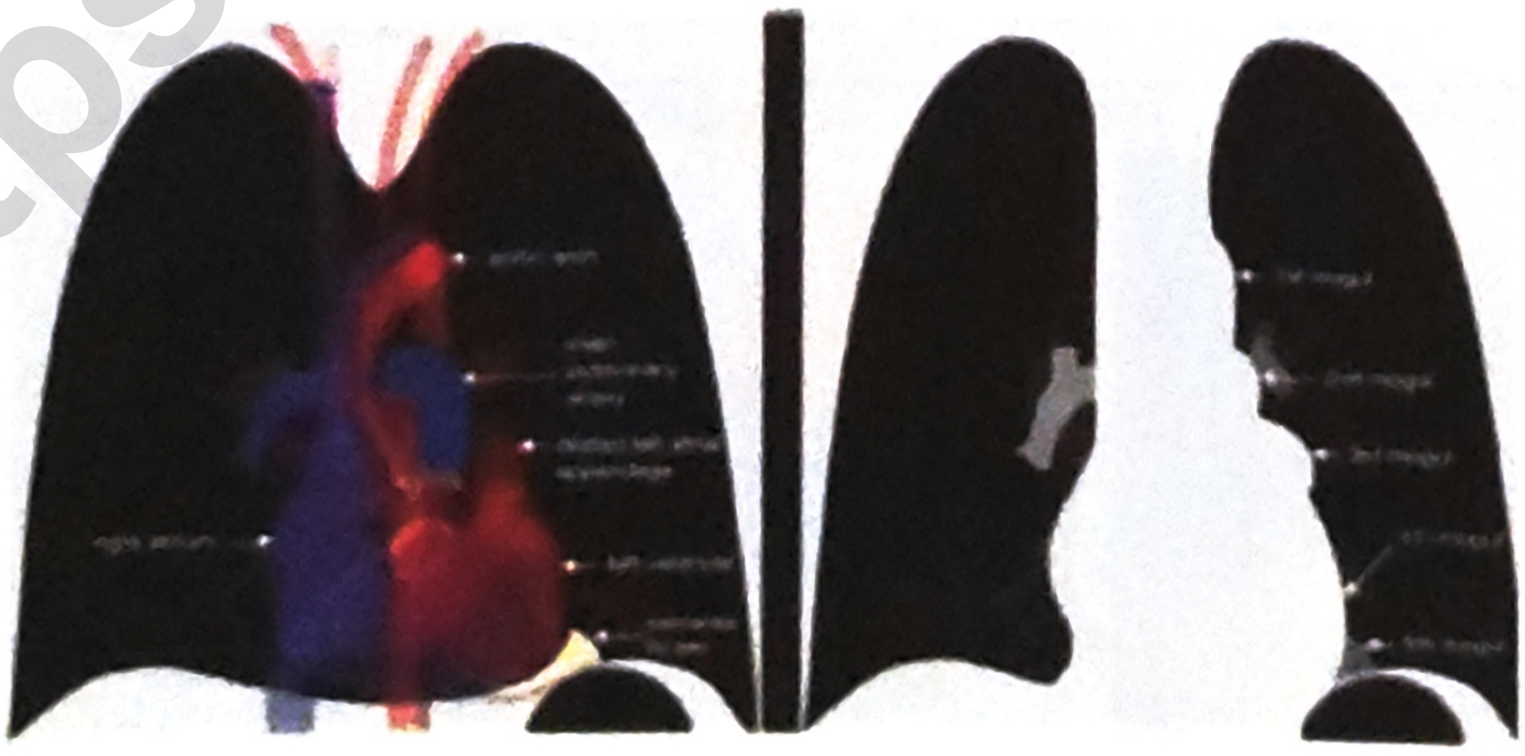

Third mogul sign – dilated left atrial appendage

https://t.me/Latestneetpgnotes

PrepLadder

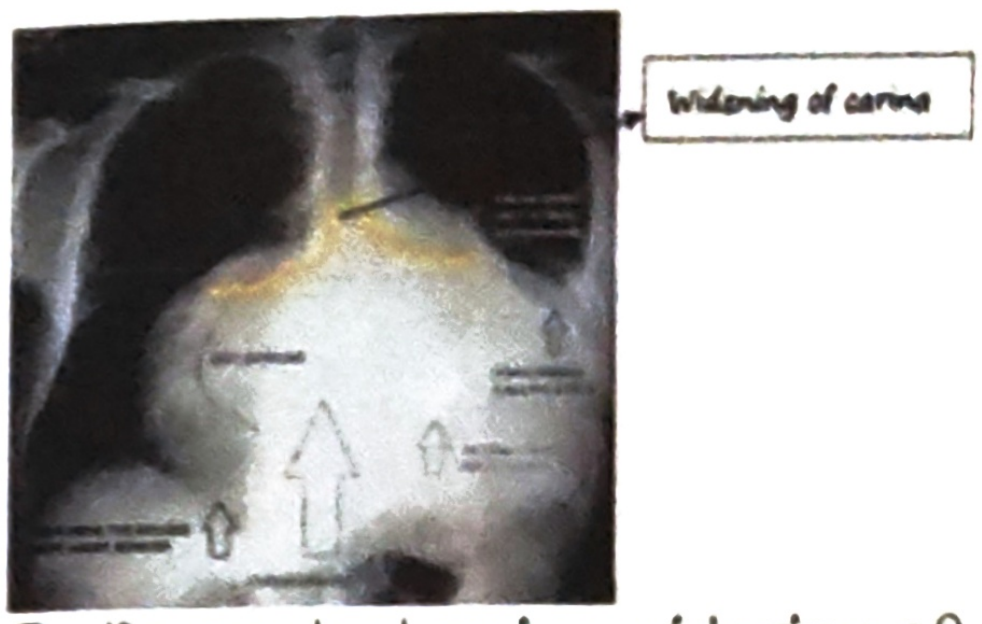

Radiograph showing widening of carina; Double density sign, third mogul sigh

Waking man sign

Note:

→Obliteration of Retrosternal spaces in seen in Right ventricular hypertrophy

→Agatston scoring

- Used to look scoring of different coronaries
- Predictive for coronary artery disease

→Pulmonary artery hypertension

- Gives "Jug handle" appearance on radiograph
- Has a diameter of › 17 cm in descending right pulmonary artery

Prominent Descending Right Pulmonary Artery

Pericardial effusion 00:47:10

→Shows money bag/leather bottle appearance on radiograph

→Also shows Oreo cookie sign – fluid in between the pericardial fat gives this sign

https://t.me/Latestneetpgnotes

PrepLadder

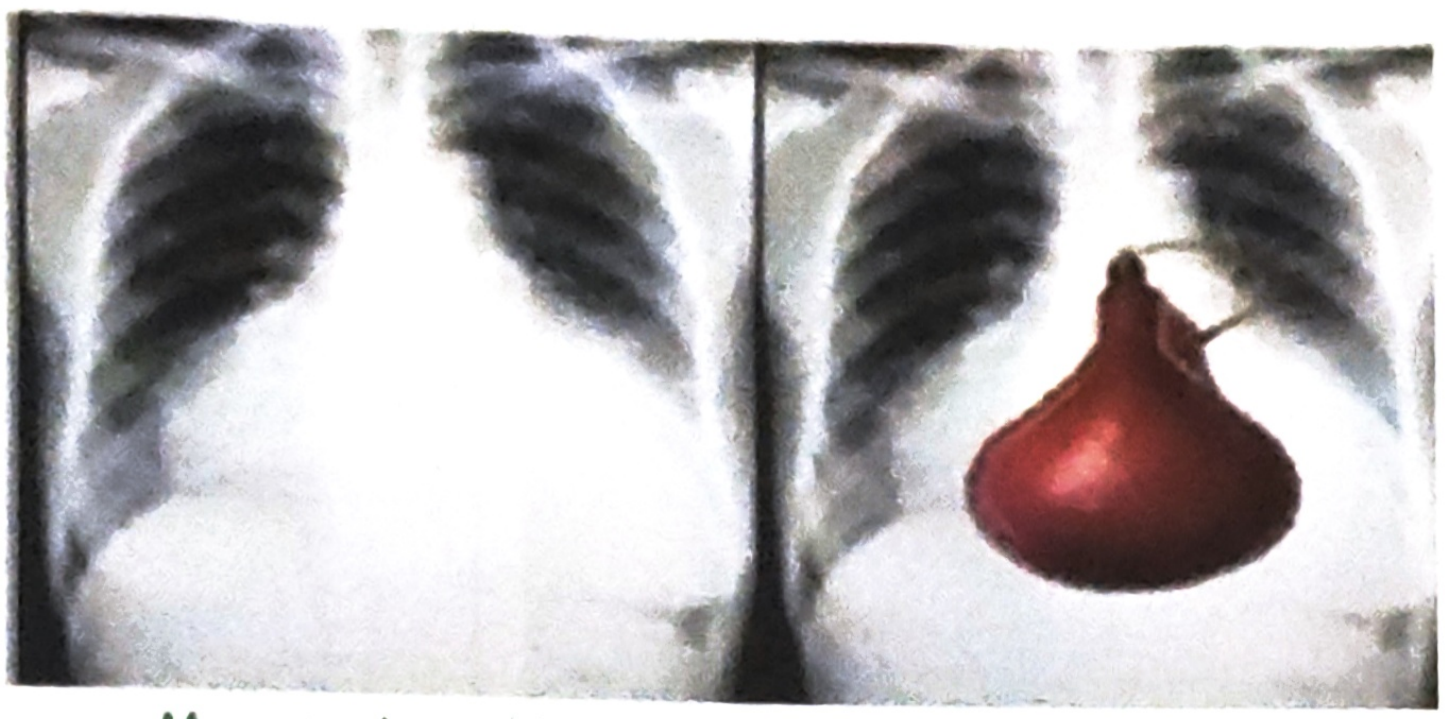

Money bag/ leather bottle appearance

Oreo cookie sign

Congestive heart failure 00:49:56

→Equalization of upper lobe & lower lobe vessels (Normal → LL vessels are more proximal than UL vessels)

→Over a period of time – cause prominence of UL vessels called

- Cephalization
- Stag antler sign
- Reverse moustache sign
- Hands up sign

→Lymphatic engorgement causing septal thickenings

- Kerley A – perihilar
- Kerley B – base of lung
  - Horizontal thin lines perpendicular to pleura

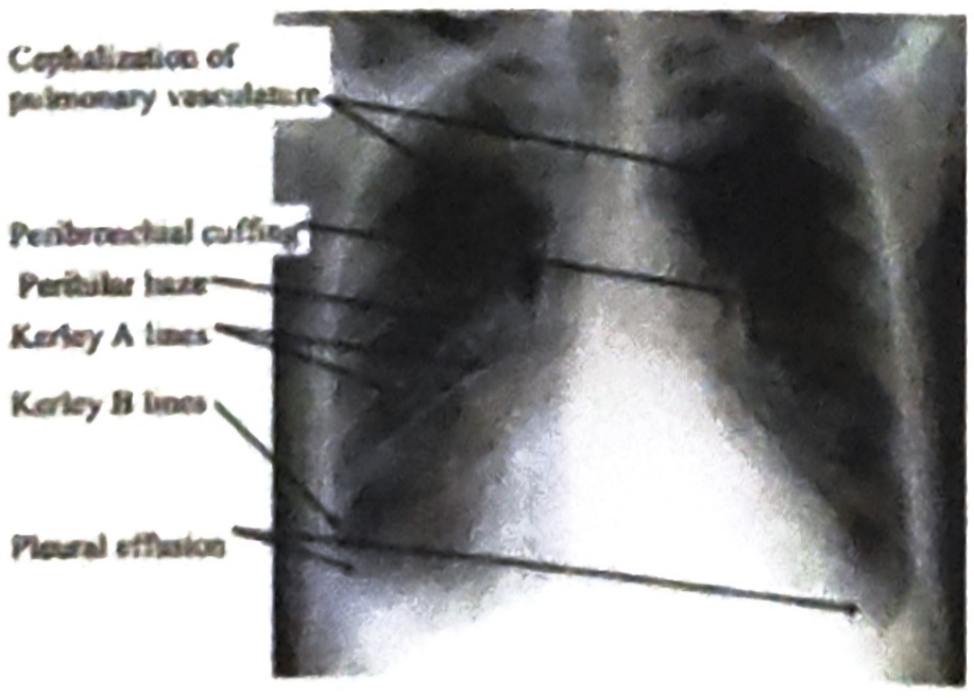

Congestive heart failure

PrepLadder

https://t.me/Latestneetpgnotes

ARDS 00:53:20

→Gives complete white out lung on radiograph

→Has ground glass opacification with decreased lung volume

White out lung / ground glass opacification

Transient tachypnea of newborn 00:54:30

→Lung volumes are normal / increased

→Seen in CS Delivered / precipitous labor baby

→Shows engorges perihilar fissures on radiograph that gets cleared spontaneously, sunray appearance

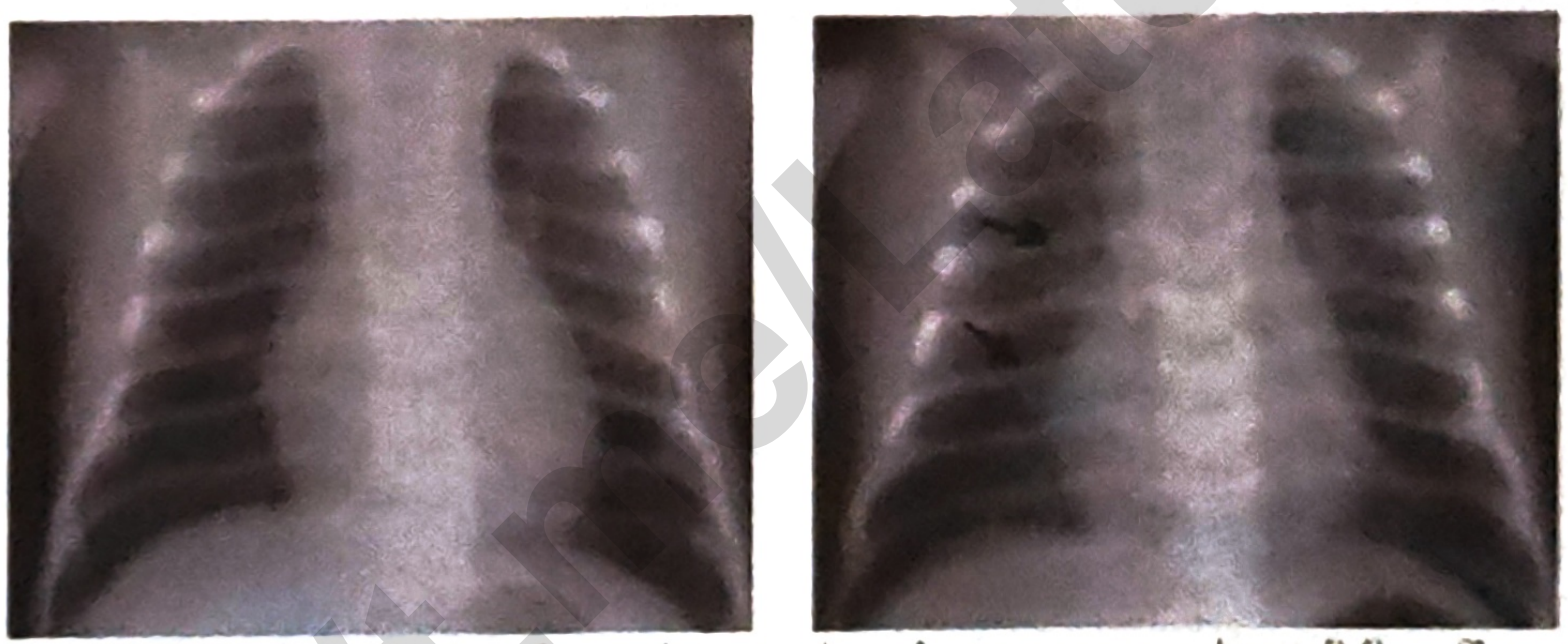

Transient tachypnea of newborn showing engorged perihilar fissure

Scimitar syndrome 00:55:20

→Partial anomalous pulmonary venous communication

→AKA

– Hypogenetic lung syndrome

– Pulmonary venolobar syndrome

→Right sided pulmonary veins crosses diaphragm and drains into IVC.

→Cause Hypoplastic lung & small pulmonary artery

https://t.me/Latestneetpgnotes

PrepLadder

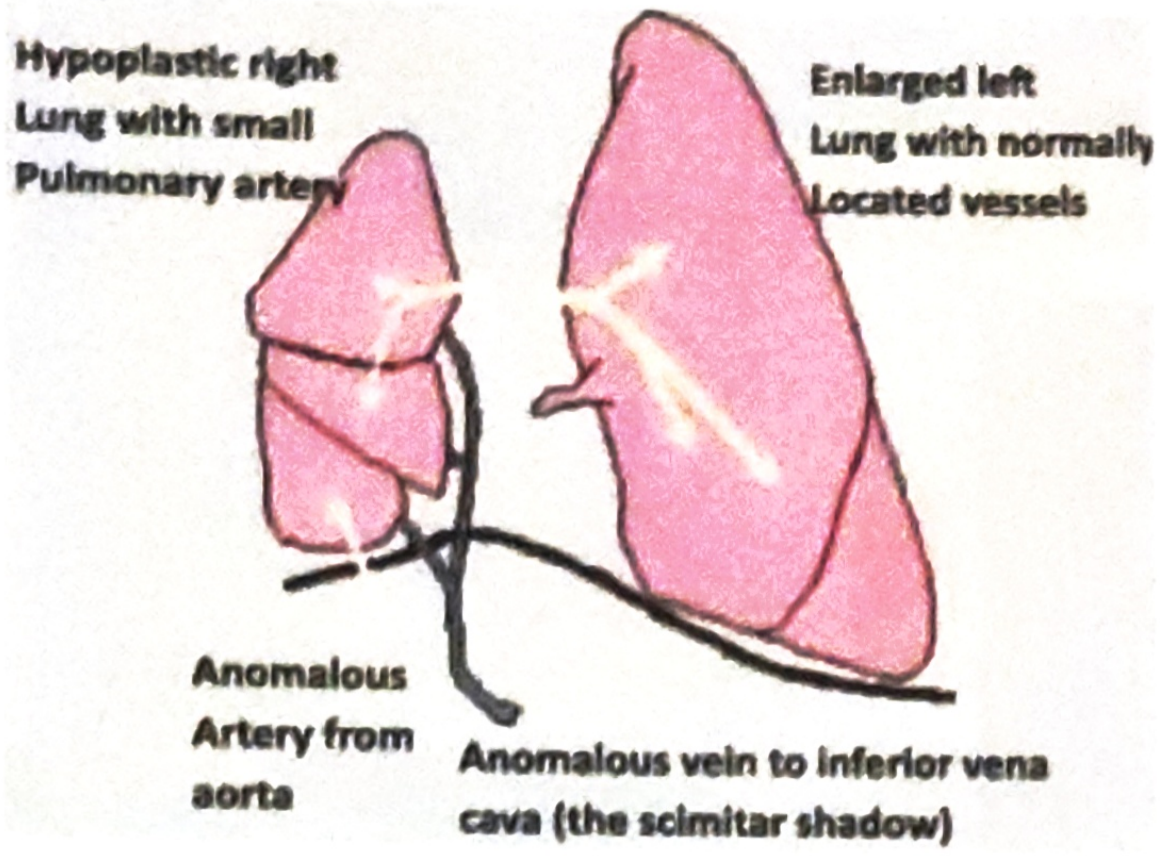

Scimitar syndrome

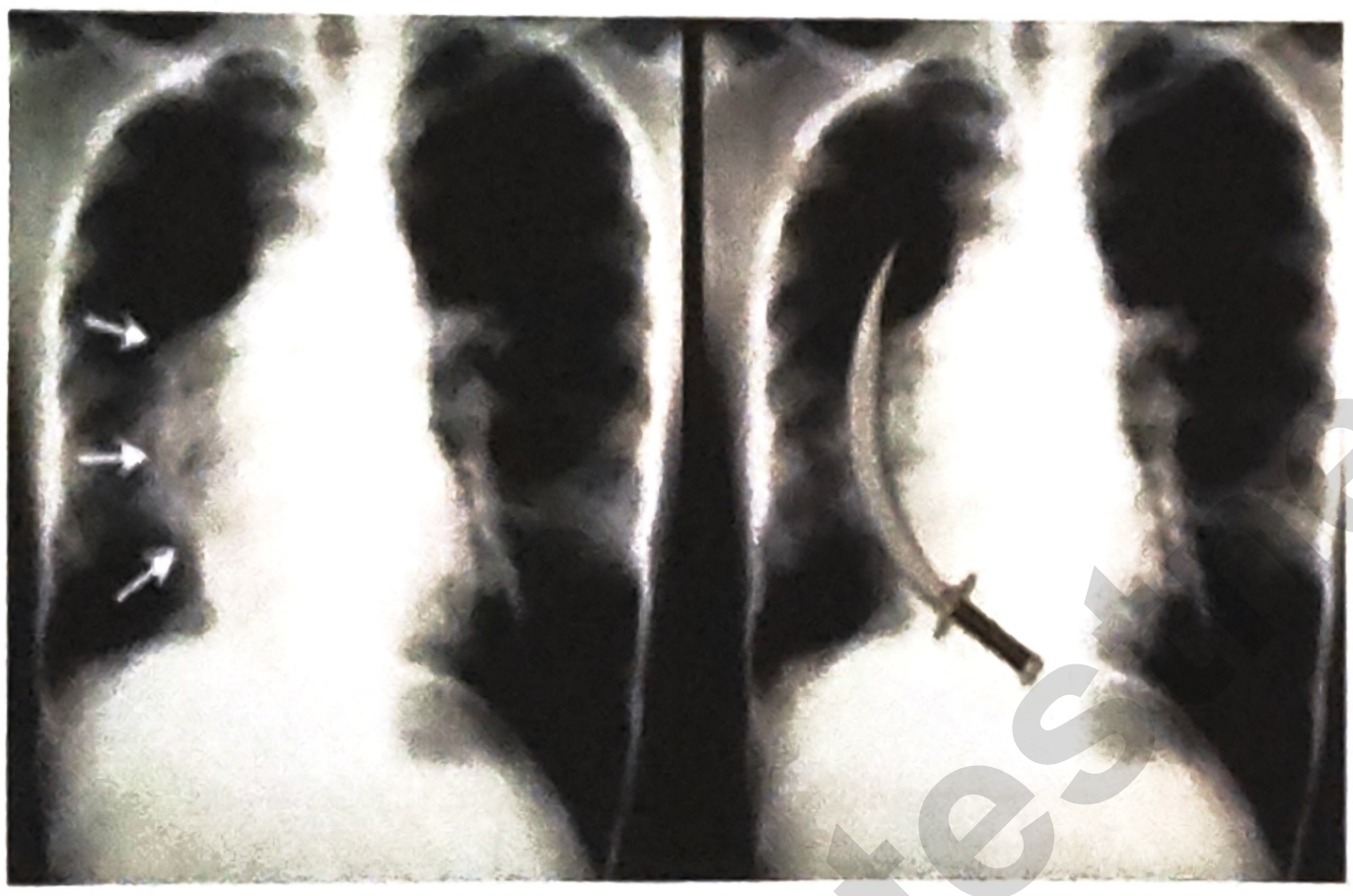

Scimitar syndrome

https://t.me/Latestneetpgnotes

PrepLadder

Chapter 34

RESPIRATORY RADIOLOGY

00:00:22

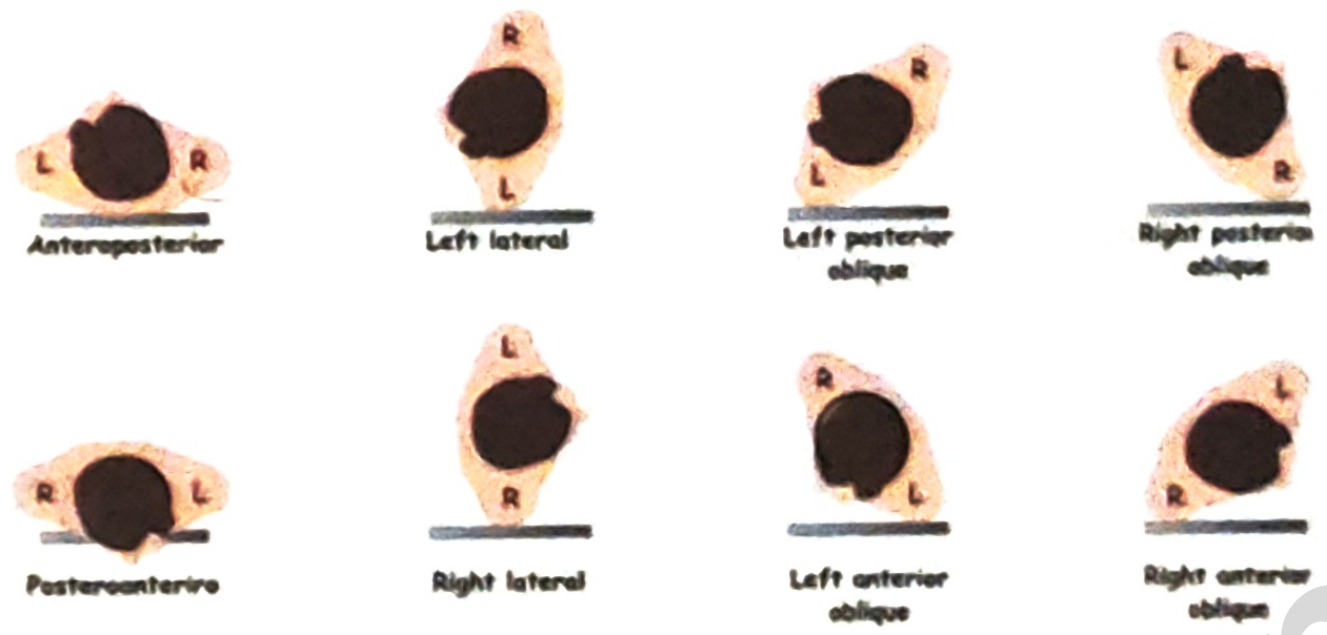

Radiographic positions



00:06:40

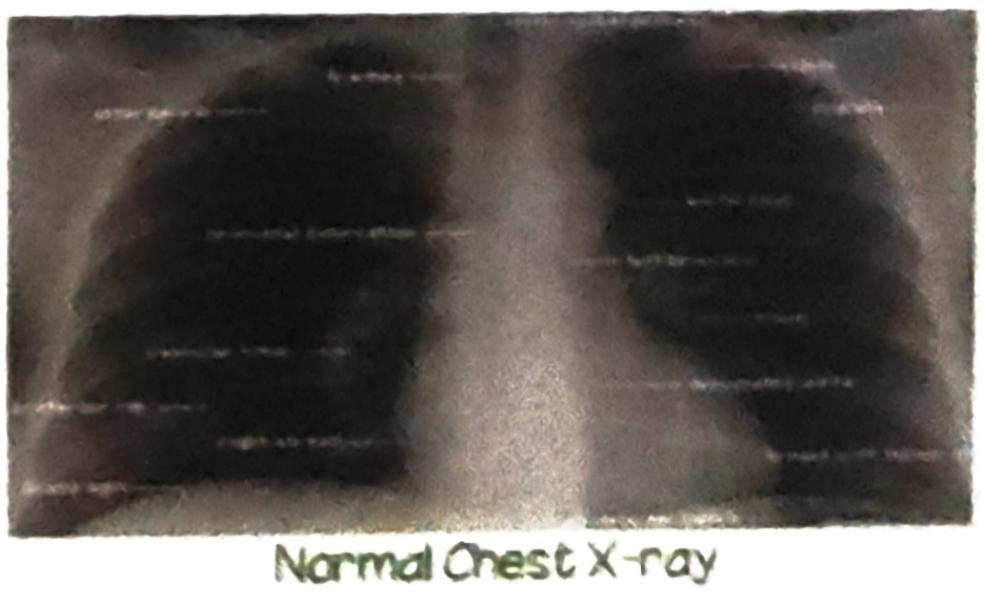

Normal Chest X-ray

https://t.me/latestneetpgnotes

PrepLadder

CXR - Inspiratory film	CXR - expiratory film

RIBS

→ Posterior ribs – more horizontal

→ Anterior ribs – oblique

→ Based on No. of ribs seen in an X-ray

- 5-7 Anterior ribs or 8-10 Posterior ribs – Good inspiratory effort
- < 5 Anterior ribs – Underinflated/ expiratory effort
- > 7 Anterior ribs – Hyperinflated lung fields

Normal Chest X ray

→ Trachea in midline

→ Medial ends of clavicle is equidistant from spinous process

Note:

→ Pneumothorax: trachea deviates to opposite side

→ Lung collapse: trachea moves to same side

→ Mitral sclerosis

- Elevation of left main bronchus
- Splaying of carina

→ Pneumonia / consolidation – No tracheal deviation

Hilum

→ Normally left hilum is higher than right hilum

→ Hilar shadow

- Formed by pulmonary arteries: (Major component) & upper lobe pulmonary vein and Bronchus

https://t.me/Latestneetpgnotes

PrepLadder

Heart border 00:12:17

→ Right Ventricle Hypertrophy – Retrosternal space is obliterated.

→ Heart borders

- Right heart border on chest X-ray – formed by SVC, Right atrium and IVC
- Right ventricles form the anterior surface of the heart, not the right heart border
- Left heart border – formed by aortic knuckle, aortic arch, main pulmonary artery, left auricle and left ventricle.
- Double right heart border – seen left atrial enlargement

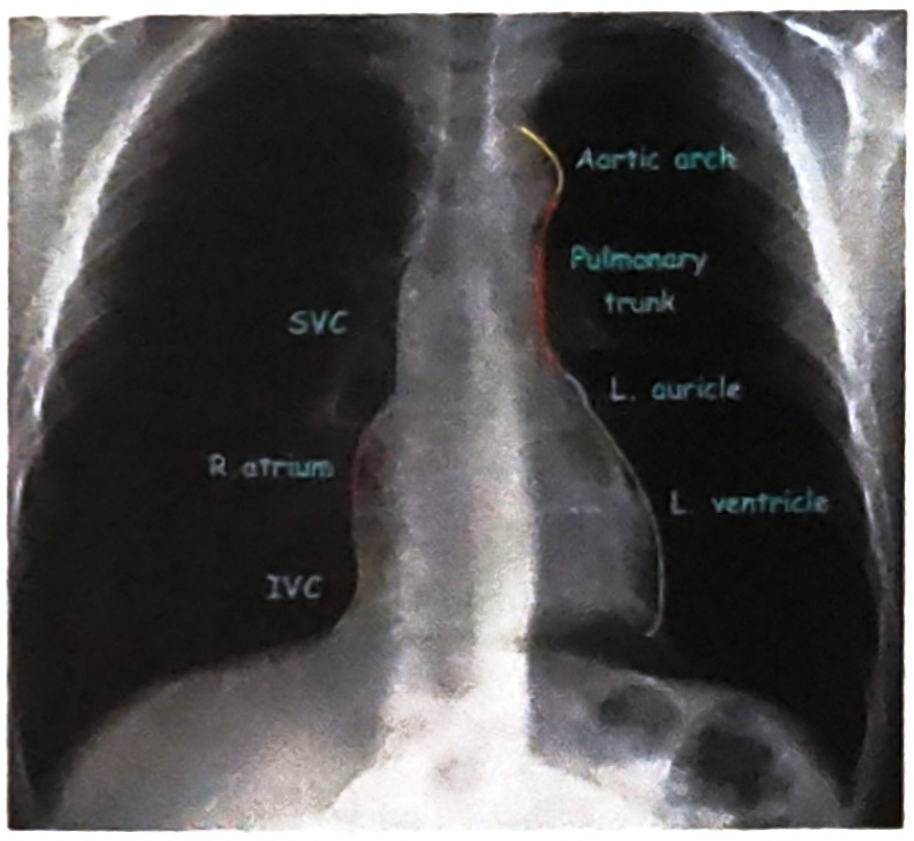

Heart borders

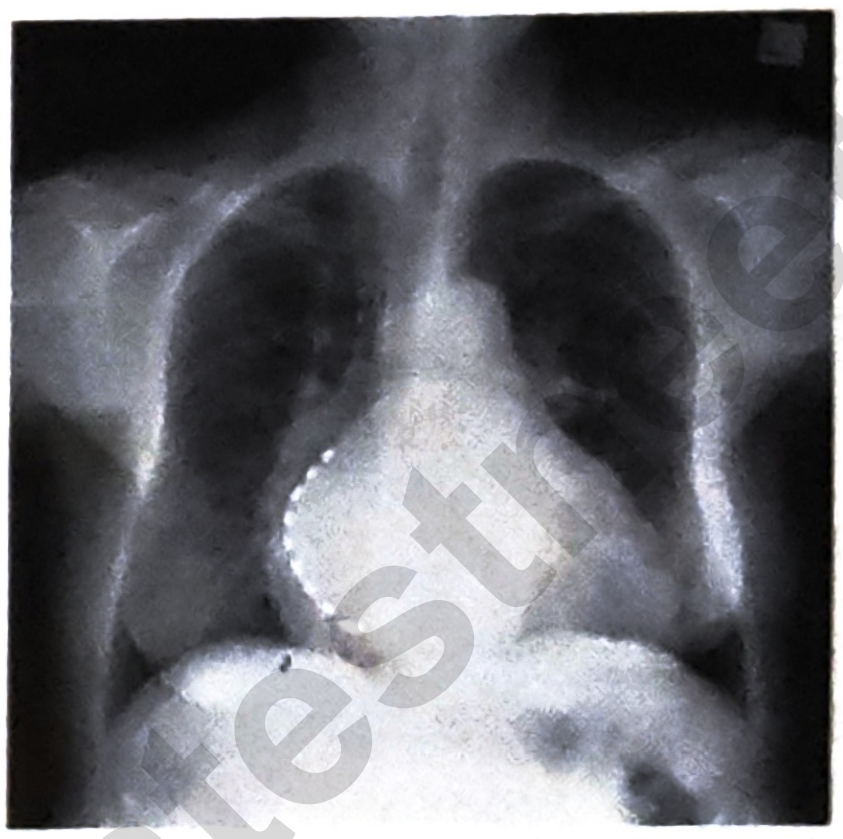

Double right heart border - LA Enlargement

Note:

→ Heart on left side pushes the Left hemi – Diaphragm downwards

CTR (Cardio Thoracic Ratio) 00:17:19

→ Cardiomegaly

- Cardio Thoracic Ratio (C/T) – C = a+b
- C/T -> 0.5 (in adults)
- C/T -> 0.6 (in neonates)



C/T ratio

PrepLadder

https://t.me/Latestpgnotes

Dextrocardia

→ Right hemidiaphragm is lower than left hemidiaphragm (Normally left hemidiaphragm lower than right)

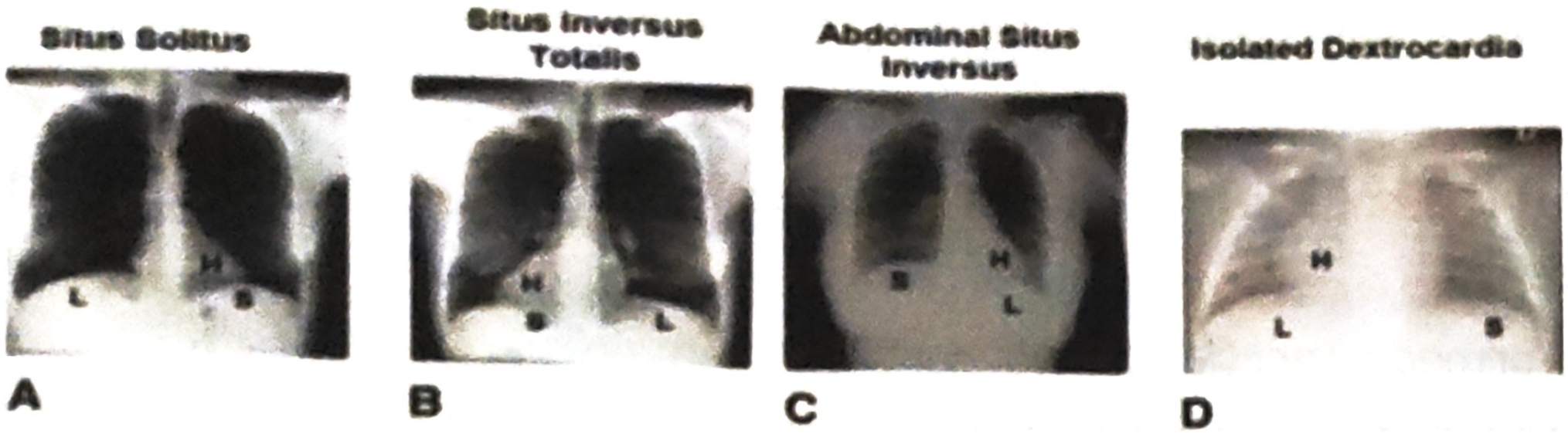

Lung fields

→ Above clavicle – Apical zone

→ To anterior aspect of 2nd rib – Upper zone

→ To Anterior aspect of 4th rib – Middle zone

→ Below that – Lower zone

Review areas of Chest X-ray

→ Costophrenic angle

→ Cardiophrenic angle

→ Hilum

→ Apex of lungs

→ Under domes of diaphragm

→ Retrocardiac region

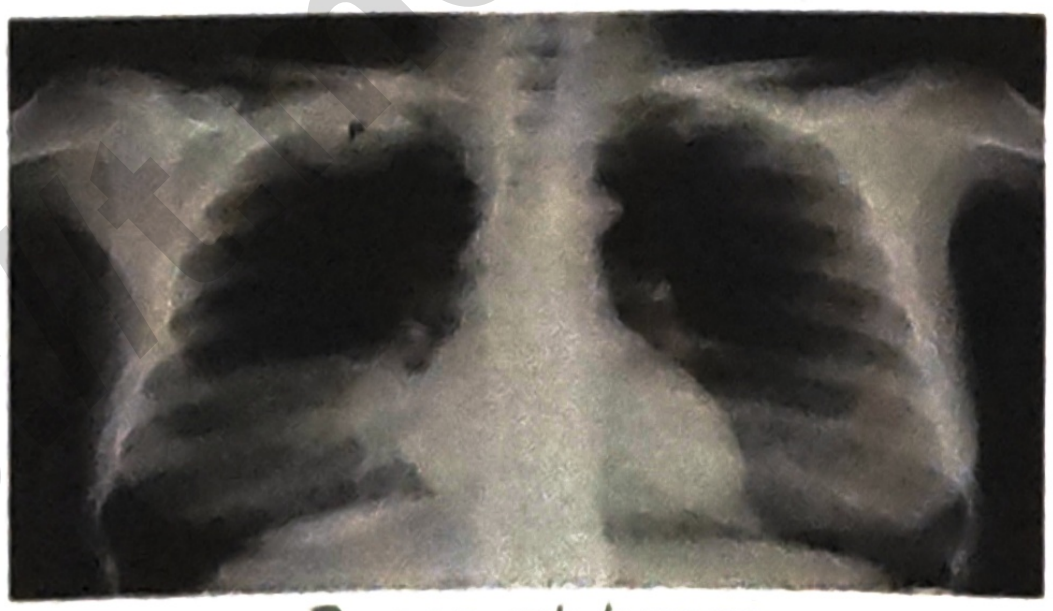

Pancoast tumor

Hilum convergence sign

00:26:10

→ Used to differentiate between dilated pulmonary Artery vs hilar mass / lymph node

- If pulmonary vessels are converging onto that area it is dilated pulmonary artery

https://t.me/Latestneetpgnotes

PrepLadder

- If pulmonary vessels pass across but do not Converge at hilum (vessels converge medical to opacity) → hilar mass

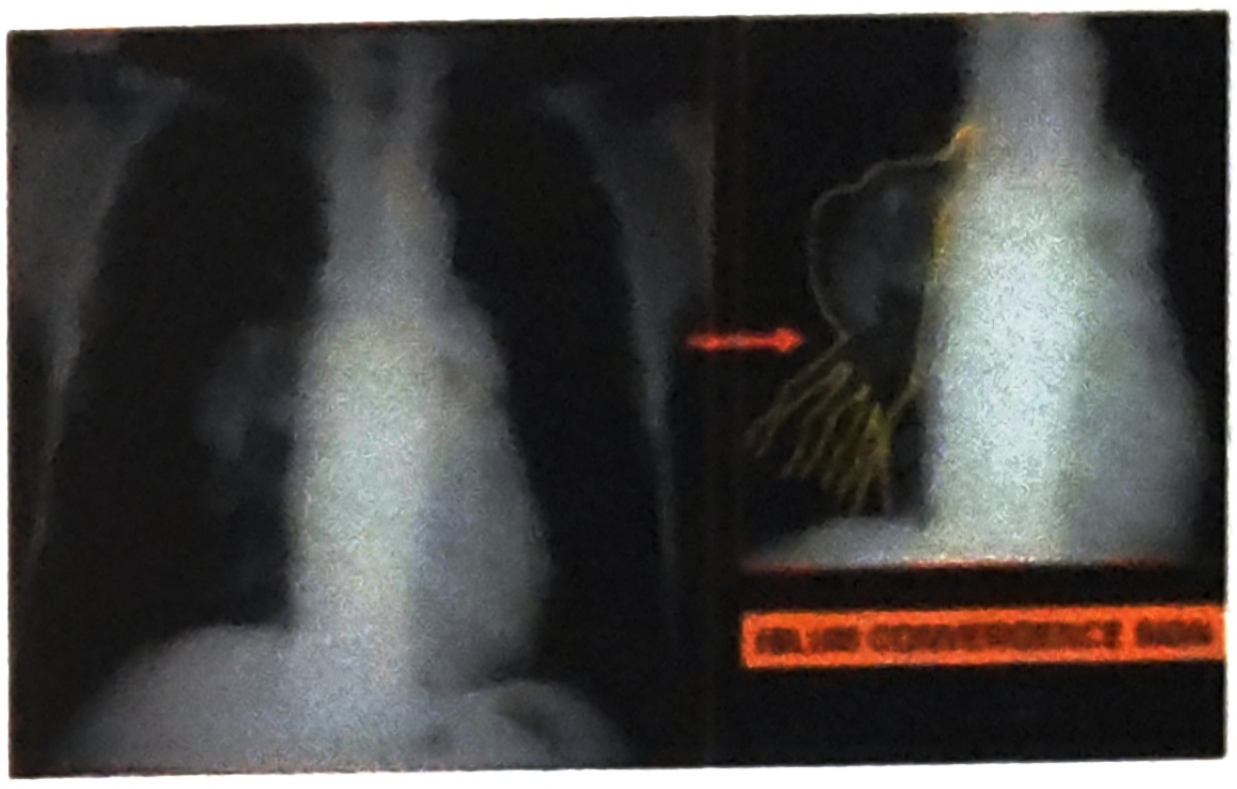

AP view	PA view
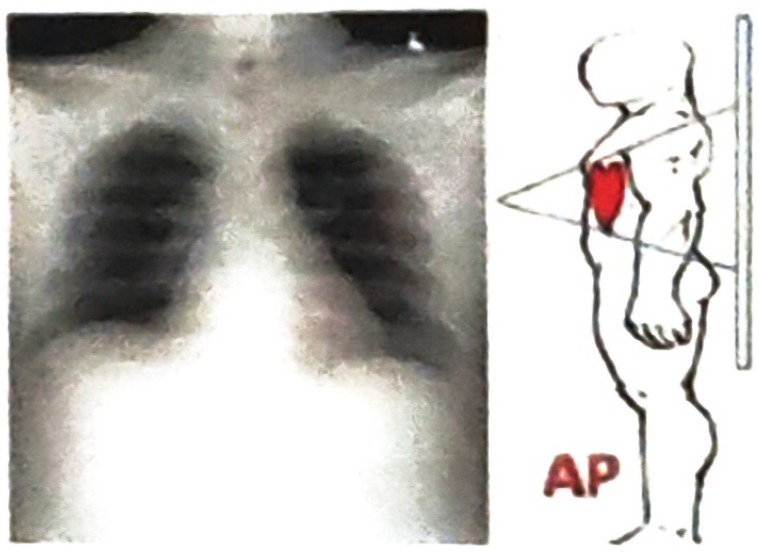	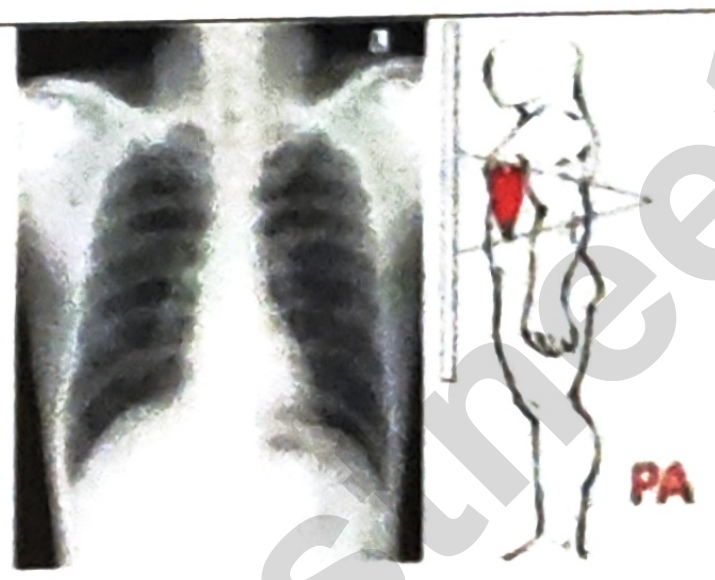
It is used for • Trauma • Condition where patient cannot move (supine)	→ It is the most commonly used Chest X- ray view
→ In normal CXR, Film Focus distance = 180 cms → In any other Conventional radiology, it is 100 cms)	
→ Apparent cardiomegaly (Heart close to x ray Source)	→ No apparent cardiomegaly (heart closer to film)
→ No gastric bubble appearance	→ Gastric bubble appearance of left side
→ Clavicle above lung apex	→ Clavicle on the lung apex
→ Medical border of scapula – more medially oriented	→ Medial border of scapula more laterally oriented in a PA view.

https://t.me/Latestneetpgnotes

PrepLadder

Note: 00:32:23

→Expiratory films – for pneumothorax

→Best view for pneumoperitoneum – Chest X Ray erect

→Best view for pleural effusion – ipsilateral lateral decubitus

→Lordotic view – Used to evaluate

- Lung apex
- Middle lobe
- Lingular Pathology

Note:

→In lateral CXR

- More black sign – Normal

→Loss of more black sign – Spine sign

- Lower Lobe pathology

Spine sign

→In lateral X ray

- The vertebral body lucency increases as you go downwards (normally)
- But sudden interruption of this lucency is called as spine sign

→Commonly occur in left lower lobe pneumonia

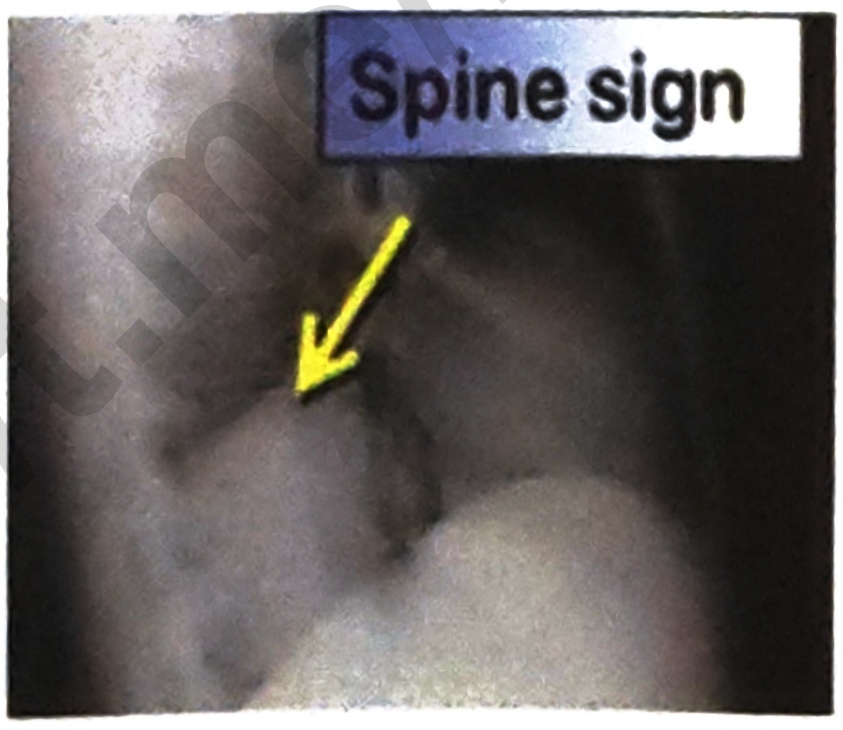

Cervicothoracic sign 00:37:28

→Differentiate Lesion in Thoracic inlet – Anterior / Posterior mediastinum / Cervical region

→Anterior mediastinum stops at the level of the superior clavicle

→Therefore, when a mass extends above the superior clavicle, it is located either in the neck or in the posterior mediastinum

https://t.me/Latestneetpgnotes

PrepLadder

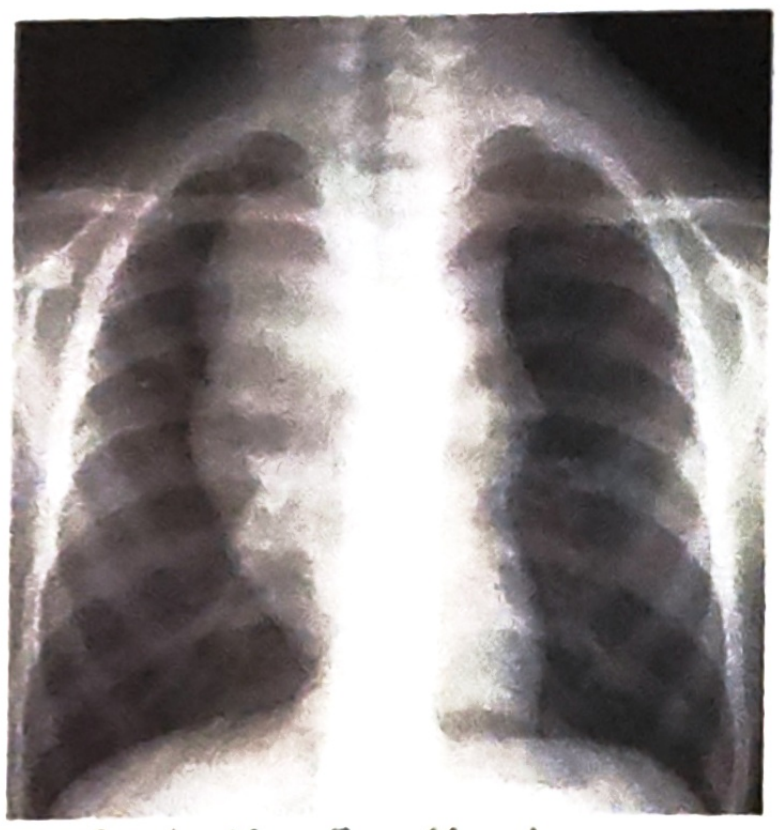

Ant. Mediastinal mass

Post. Mediastinal mass

Thoracoabdominal sign

→Differentiate lesion located close to Hemi diaphragm

→Anterior mass in lung – Mass terminates at diaphragm

→Posterior mass in lung – Mass appears to terminate below diaphragm with sharp distinct margin

Thoracoabdominal sign

Consolidation

Left lower lobe consolidation

A - No Tracheal deviation

B - Lucency of air in CP angle intact

C - Opacities with hazy irregular border

https://t.me/Latestneetpgnotes

PrepLadder

Left lung collapse

- → Ipsilateral shift of Trachea, Carina & Mediastinum
- → Bronchial cut off sign (left mainstem Bronchus)
- → Rib crowding
- → Compensatory hyperinflation of right Lung
- → Elevation of hemidiaphragm

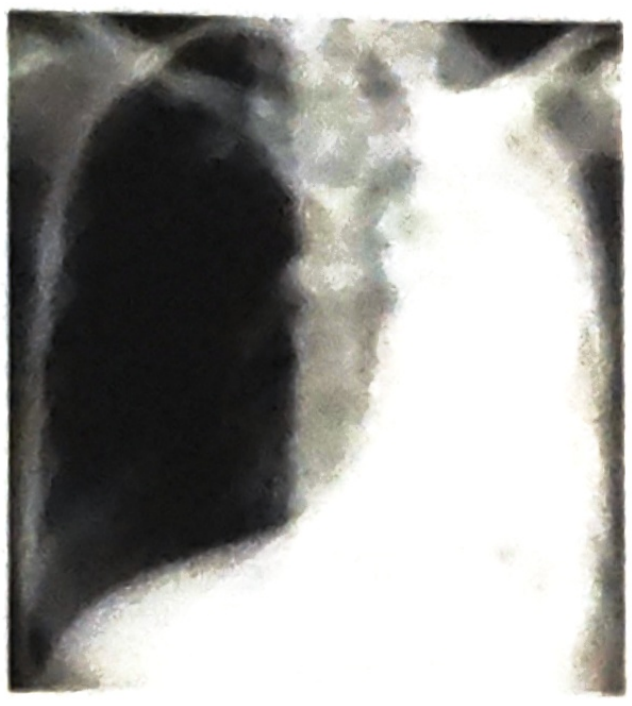

Left lung collapse

Pneumonectomy

00:46:52

- → Surgical clips
- → Rib resection
- → Opacity developing over few weeks.
- → Tracheal shift towards the opacity

Pneumonectomy

Air bronchogram sign

- → Alveolar opacities with air inside bronchus intact
- → Seen in
  - Consolidation / pneumonias
  - Pulmonary edema
  - Bronchoalveolar carcinoma
  - ARDS / hyaline membrane disease

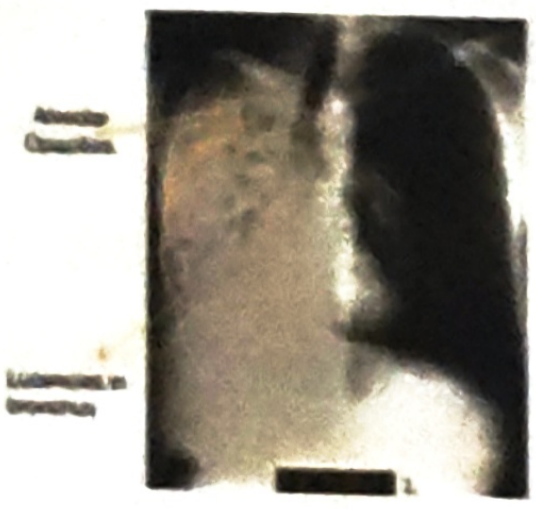

https://t.me/Latestneetpgnotes

PrepLadder

Note:

Air → lucent

Replaced by fluid	→ Pleural effusion	radiopacity
By exudates	→ consolidation	
Pneumectomy		

COPD/ Emphysema → Hyperinflated lung fields → radiolucent

COPD/ Emphysema

A - Widening of intercostal space

B - Flattening of domes of diaphragm

C - Hyperinflated lung fields

COPD

Collapse / Atelectasis

→ White

→ Sharp margin

→ Tracheal, mediastinal & hemidiaphragm shift to same side

→ Fissure shift

→ Elevation of hemidiaphragm

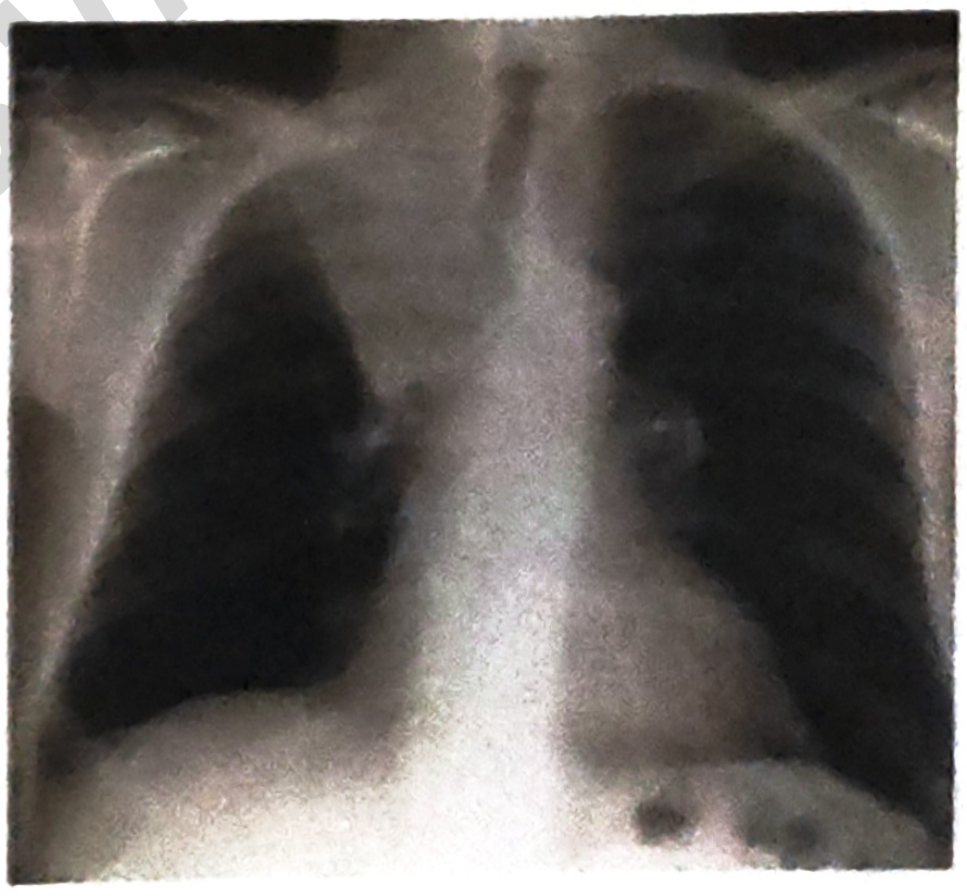

Right upper lobe collapse

https://t.me/Latestneetpgnotes

PrepLadder

Golden S sign

→Aka Reverse S-sign

→Seen in Bronchogenic carcinoma with right upper lobe collapse

→Lower convexity – Formed by Mass (Bronchogenic CA)

→Upper concavity – Formed by RUL collapse

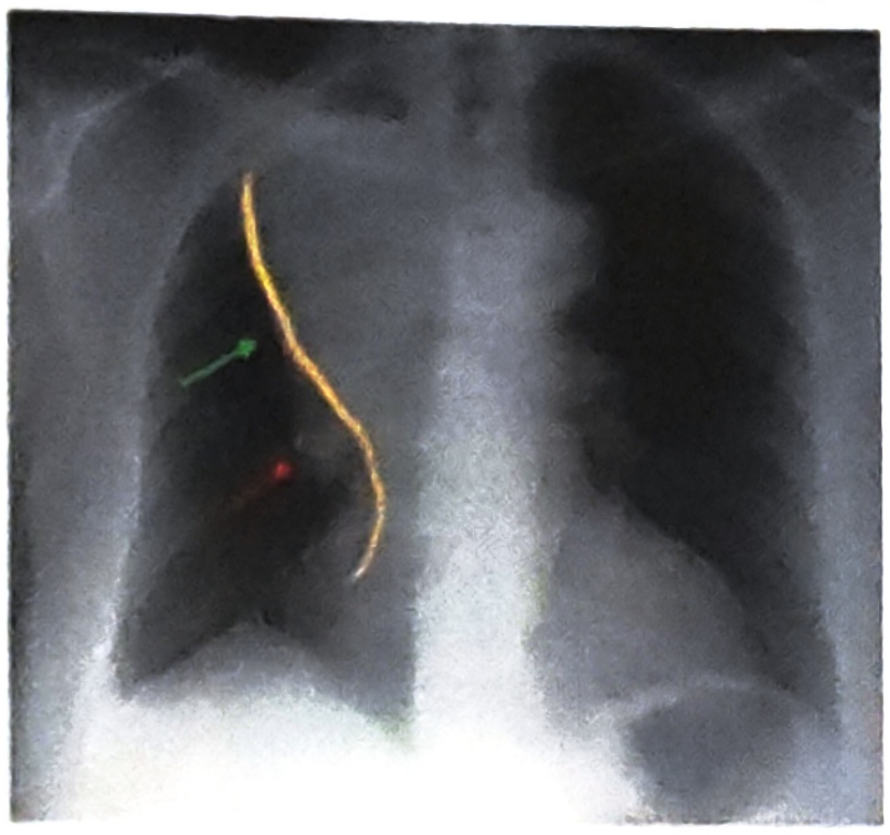

Golden S sign

Silhouette sign

00:55:18

→2 objects of same density came in close anatomical contact, their margins become obscured.

Ascending Aorta	RUL pathology
Right Heart border	RML pathology
Right hemidiaphragm	RLL pathology
Aortic Knob	Left apicoposterior pathology
Left Heart border	Lingular pathology
Left Hemidiaphragm	LLL pathology

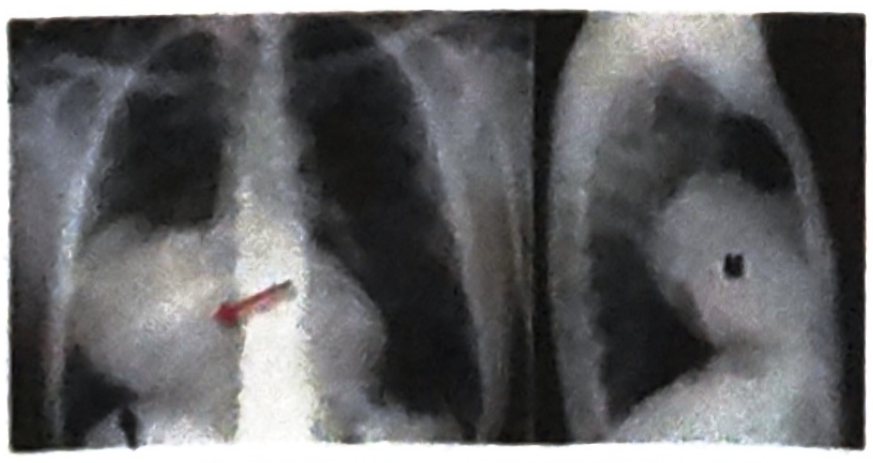

Silhouette signs

https://t.me/latestneetpgnotes

PrepLadder

Hilum overlay sign

→Used to Differentiate a hilar mass from a mass in anterior or posterior mediastinum

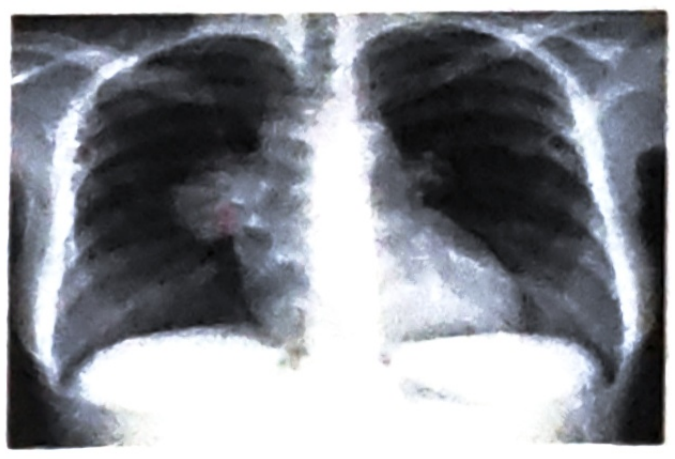

Hilum overlay sign

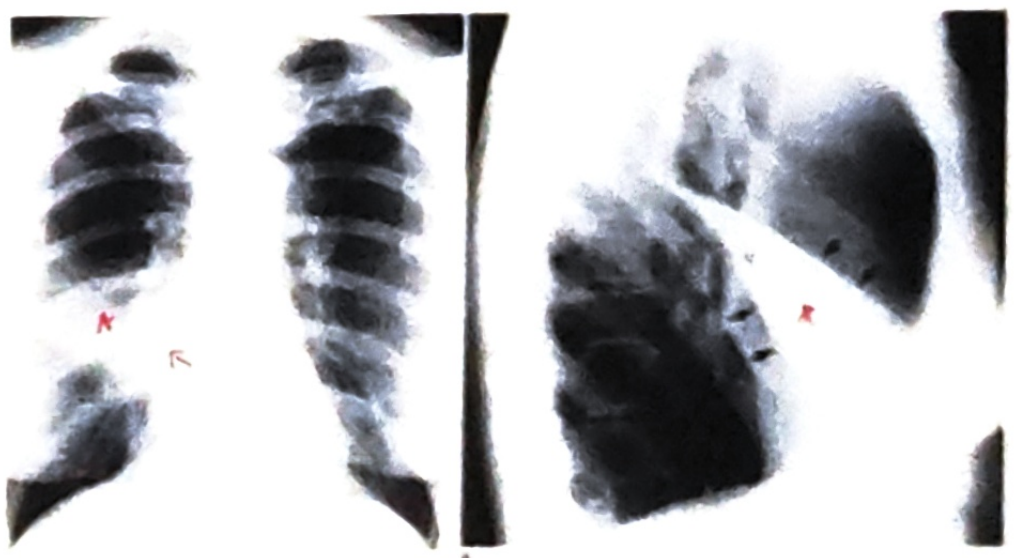

Right middle lobe collapse

Flat waist sign

→Seen in left lower lobe collapse

→Caused by leftward displacement and rotation of heart

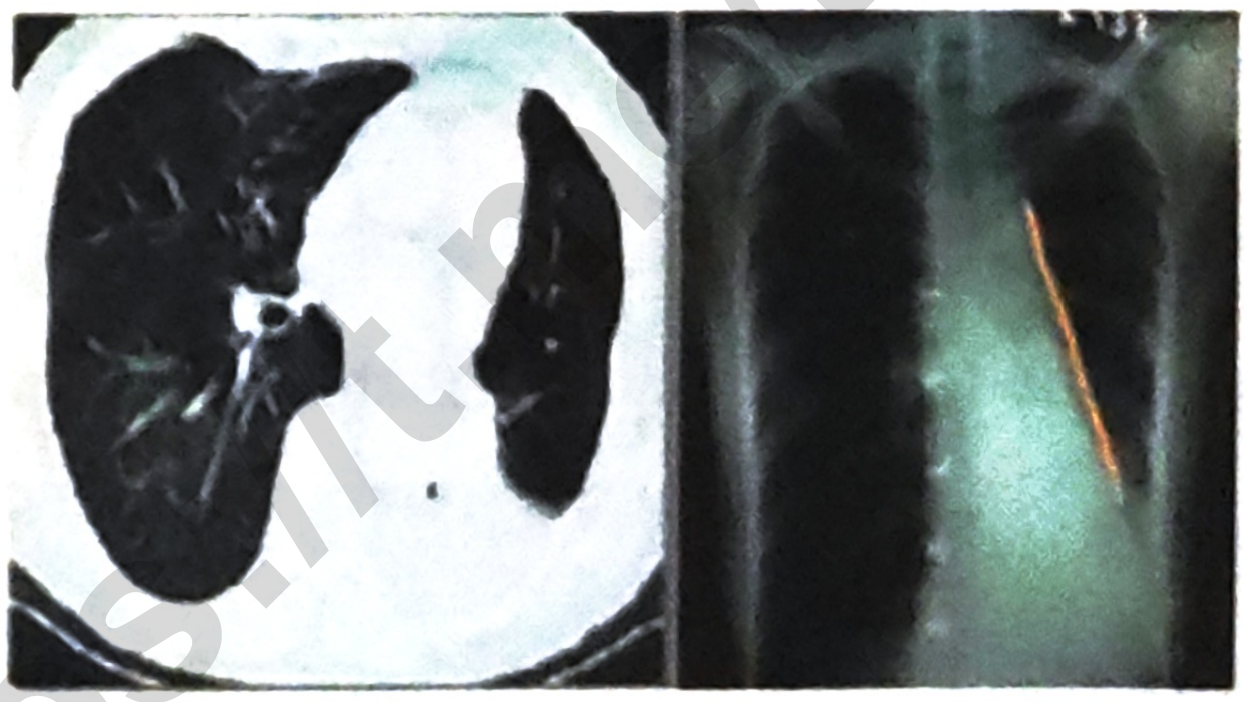

Flat waist sign

Luftsichel sign

01:04:10

→Sickle shaped lucency of air in CXR

→Seen in Left upper lobe collapse

↓

Due to compensatory hyperinflation of superior segment the left lower lobe

https://t.me/Latestneetpgnotes

PrepLadder

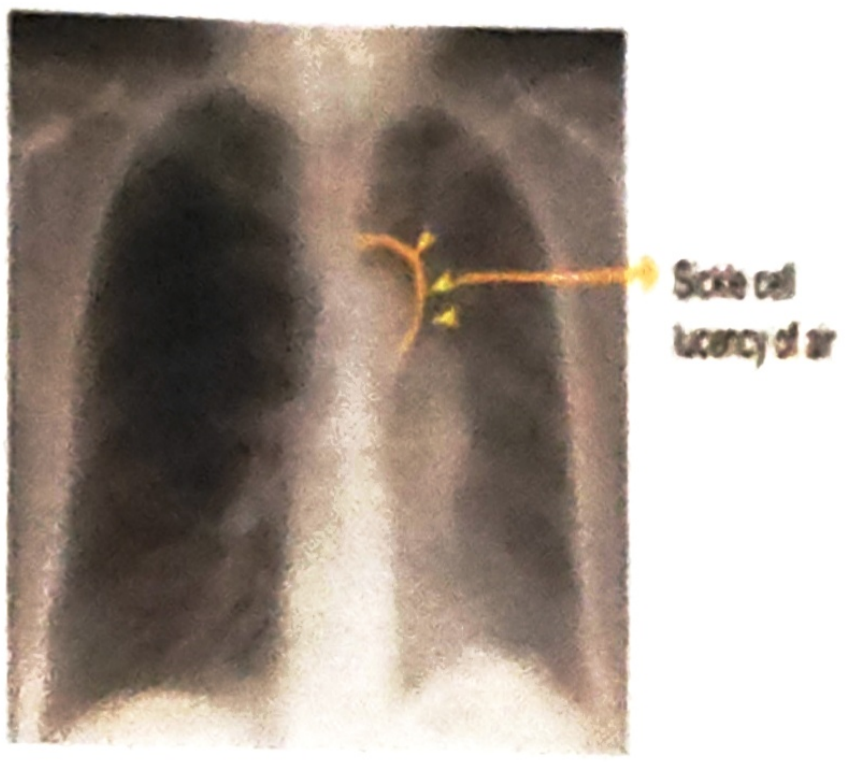

Luftsichel sign

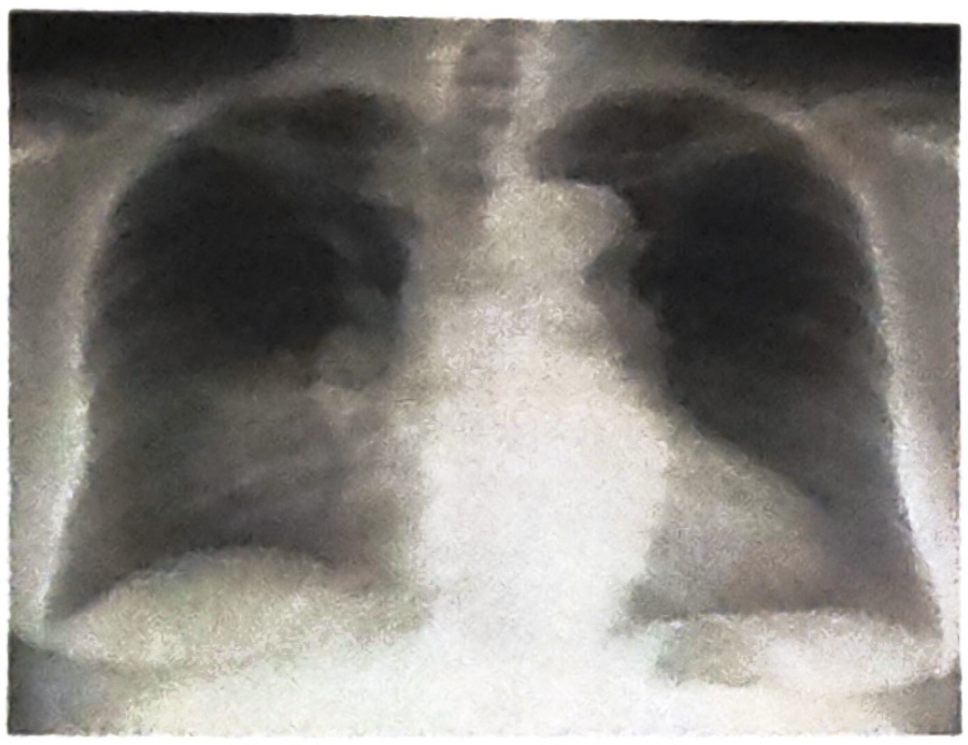
RML consolidation
- fluffy opacities, hazy margins,
Air bronchogram

RML collapse
- Sharp distinct margins

Pneumothorax 01:08:30

→Best X-ray view – Expiratory film

→IOC – CT

→CXR signs of Pneumothorax

- Absent bronchovascular markings
- Visceral pleural refection
- Deep sulcus sign in supine patient
- Double Diaphragm sign in supine patient

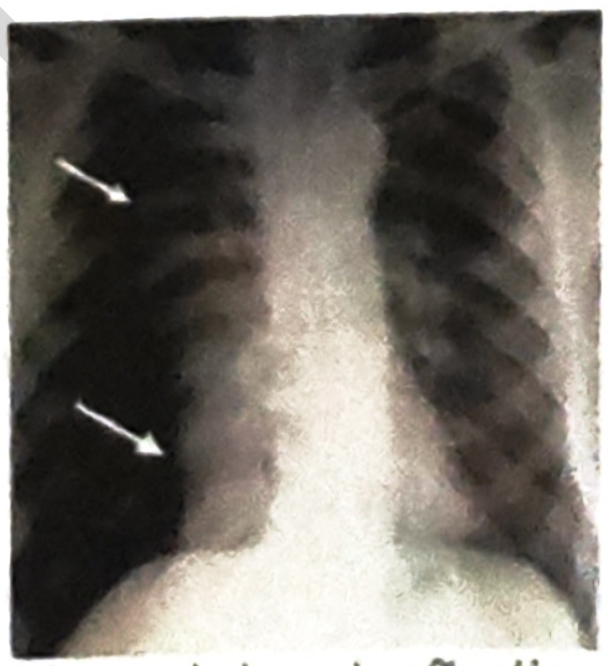
Visceral pleural reflection

Deep sulcus sign

https://t.me/latestneetpgnotes

PrepLadder

Note:

→USG is more sensitive than radiograph for pneumothorax.

→USG signs of pneumothorax

- Absent seashore sign
- Bar code sign
- Stratosphere sign

} on M-mode USG

Tension pneumothorax

→Pneumothorax with mediastinal shift

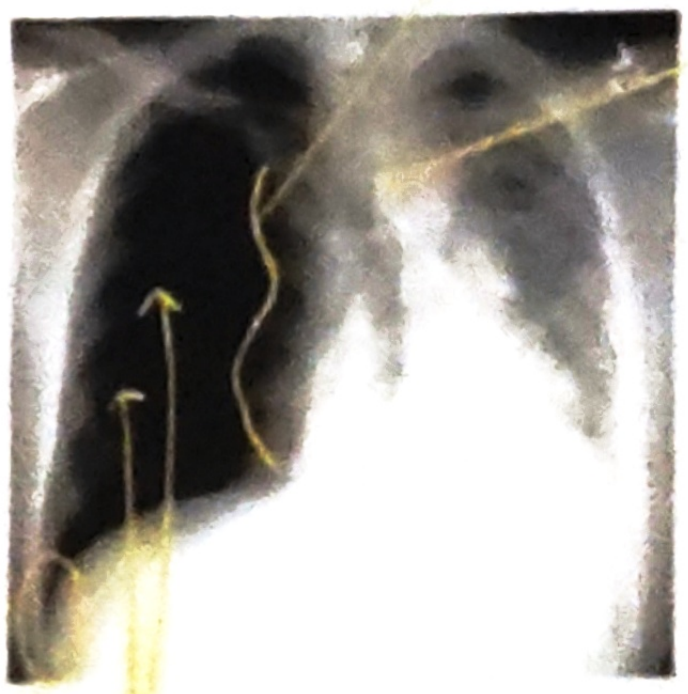

Tension pneumothorax

Fallen Lung sign

→Seen in Fracture of bronchus

↓

Lungs collapses

- Inferiorly and laterally in an upright posture
- Posteriorly in a supine posture

Note:

→Lung collapses medially and towards the hilum in pneumothorax

Fallen Lung sign

https://t.me/Latestneetpgnotes

PrepLadder

Pneumomediastinum

01:14:25

→ Normal

- Thymic sail sign – Inferior margin of Thymus forms sail sign
- Wave of mulvey sign – Costal cartilages indent on Thymus and gives wave like appearance

→ Abnormal

- Spinnaker/ Angel wing/ Thymic wing sign - Air comes between thymus & heart, Lifting the thymus away from Heart – Pneumomediastinum
- Continuous diaphragm sign
  - Air lucency under the heart
  - Pneumo mediastinum
  - Pneumopericardium
  - Pneumoperitoneum
- Hay stack sign – Air encircling the heart gives Haystack appearance
- V sign of Naclerio – Air lucency under lining the lateral border of the descending thoracic aorta and left medial hemidiaphragm (Pneumomediastinum secondary to esophageal perforation)

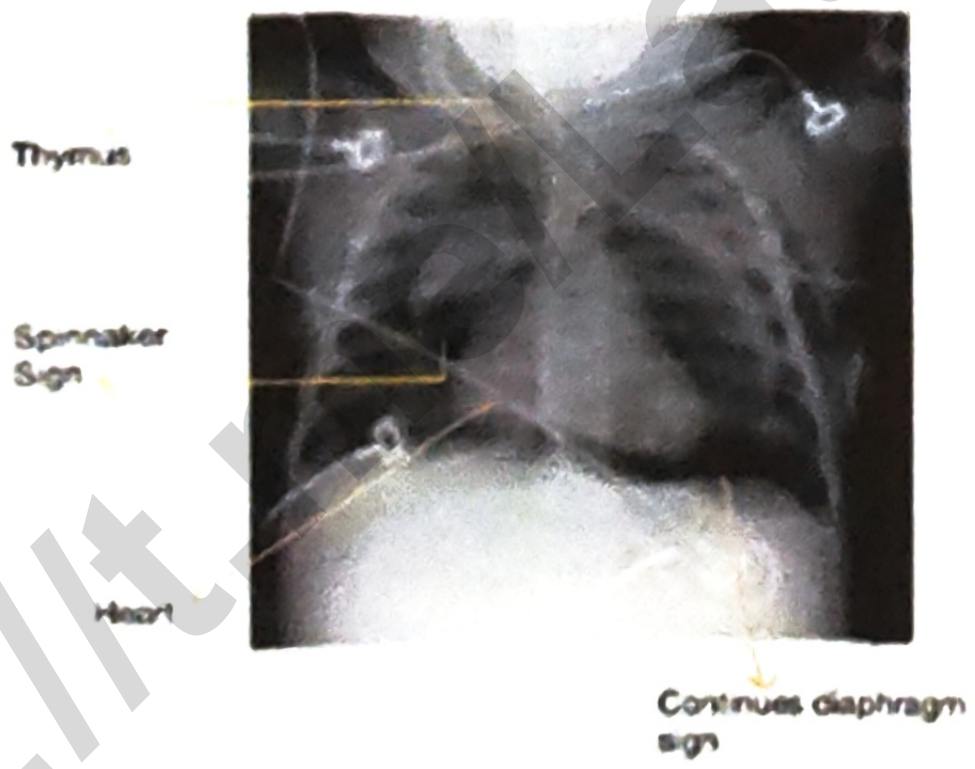

Spinnaker sign/ Continuous diaphragm sign

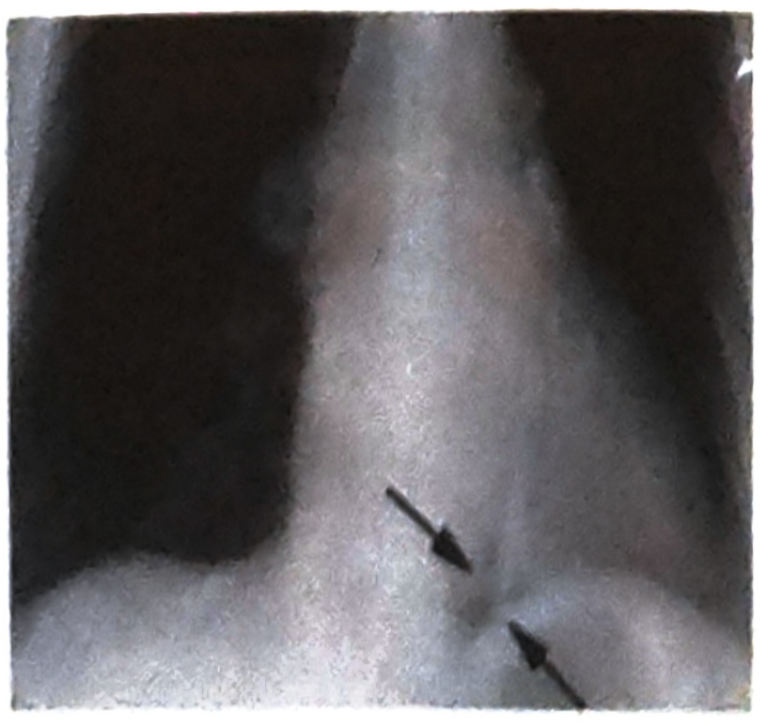

V sign of Naclerio

https://t.me/latestneetpgnotes

PrepLadder

→ IOC for air involving pathologies – CT scan
(E.g. Pneumothorax, pneumoperitoneum)

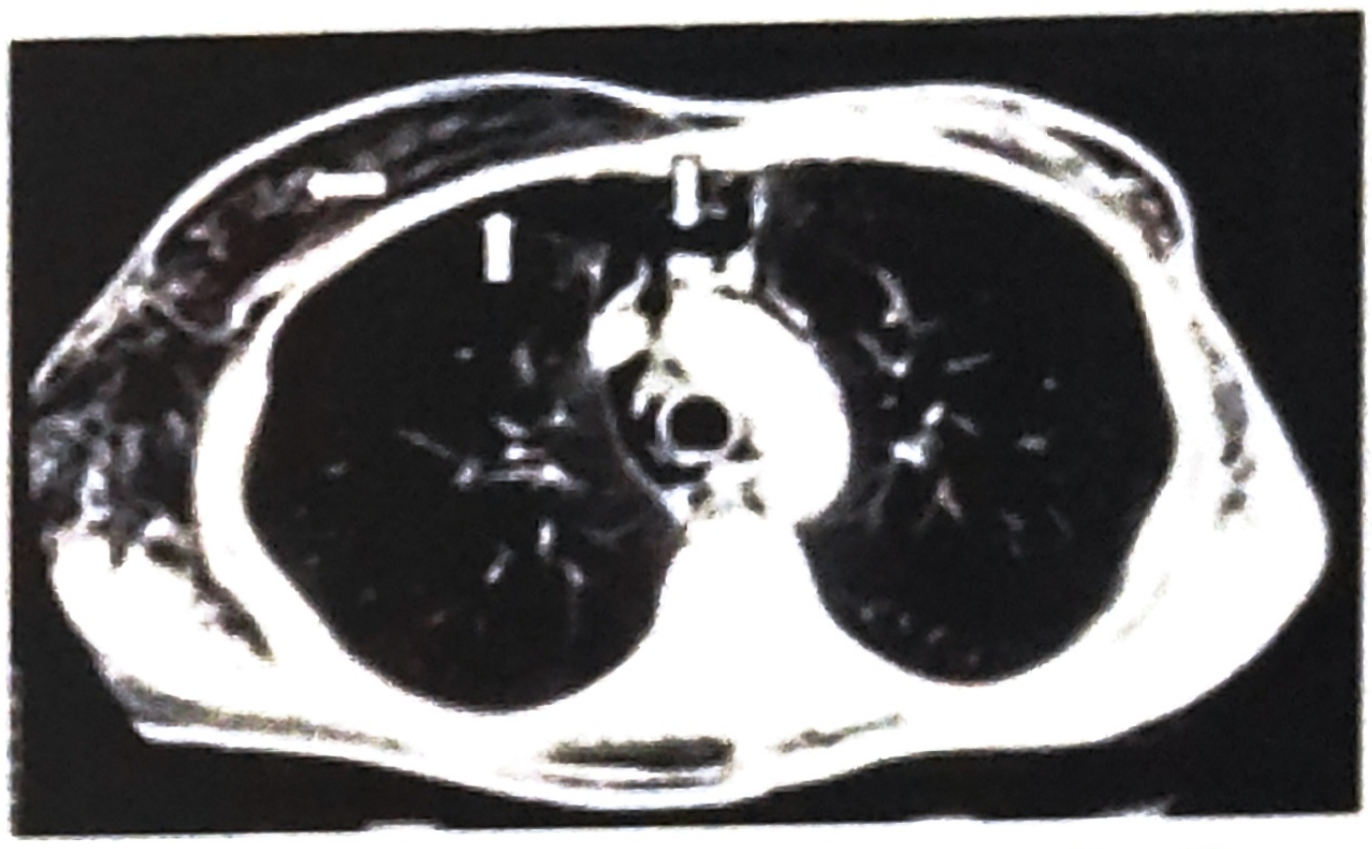

Pneumothorax + pneumomediastinum

Ring around artery Sign

→ Air around the pulmonary artery
→ Seen in Pneumomediastinum

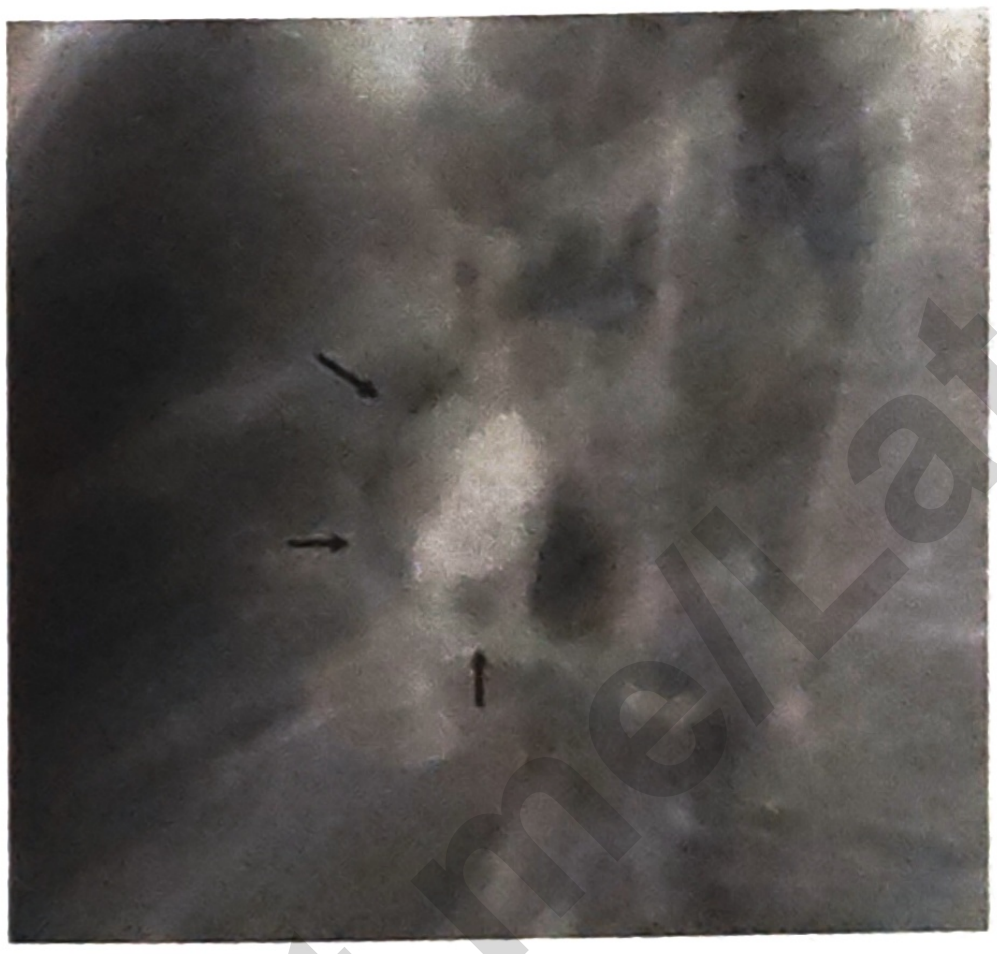

Ring around artery Sign

Other Signs of pneumomediastinum

→ Subcutaneous emphysema
→ Tubular artery sign – Gas outlining major aortic branches.
→ Double bronchial wall sign – Gas outlining Bronchial wall.

Pneumopericardium

→ Lucency of air around the heart, Which is limited by the pericardial space

https://t.me/Latestneetpgnotes

PrepLadder

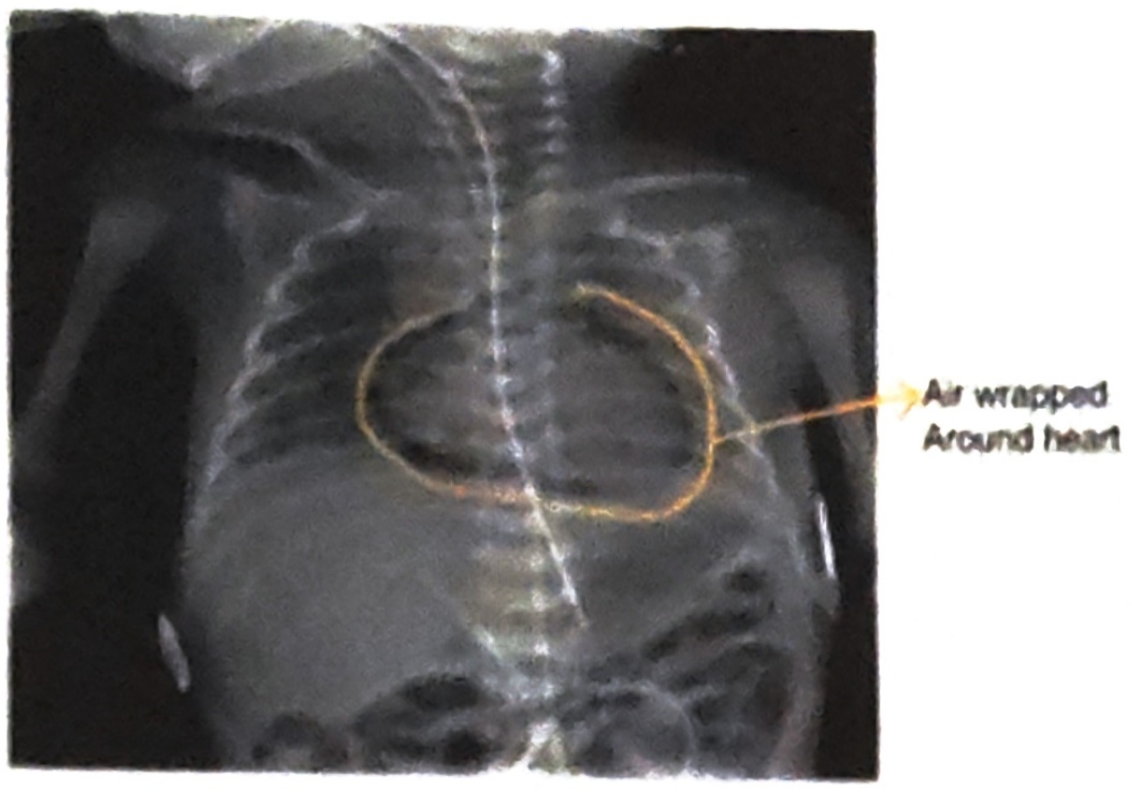

Pneumopericardium

Pneumoperitoneum

01:20:50

- →Air under right done of diaphragm – suggestive of Hollow viscus perforation/ pneumoperitoneum
- →Football sign
- →Umbilical ligament sign
- →Inverted V sign
- →Rigler's sign
- →Falciform ligament sign
- →Ligamentum teres sign
- →Uranus sign
- →Telltale triangle sign
- →Morrison gas sign / Doges Cap sign

Pseudo pneumoperitoneum

- →Chilaiditi syndrome – Bowel inter scoped between right hemidiaphragm and liver
- →Other causes
  - Subphrenic abscess
  - Basal atelectasis
  - Subpulmonic pneumothorax

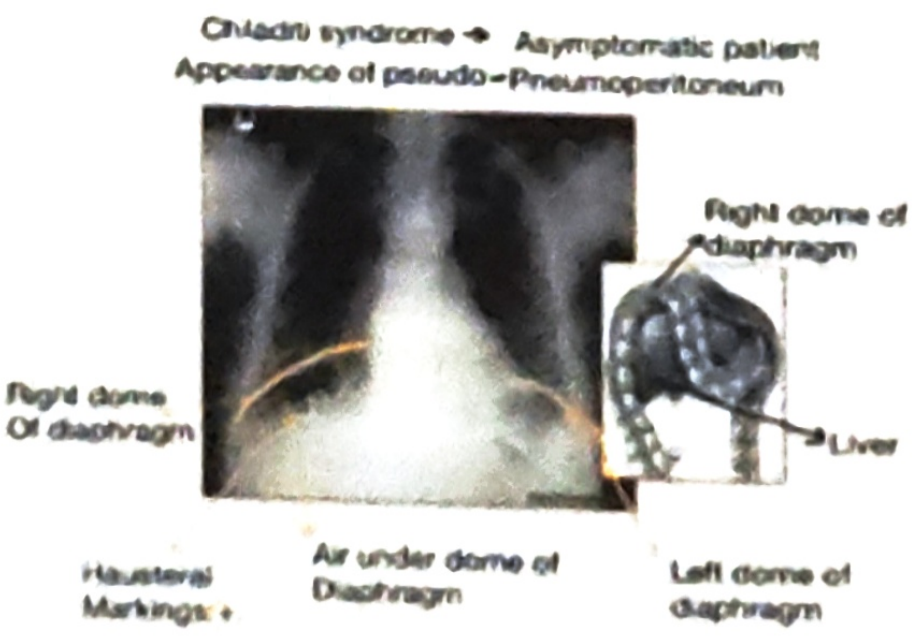

https://t.me/Latestneetpgnotes

PrepLadder

Pleural effusion

01:23:16

→ CXR findings

- Obliteration of CP angle
- Distinct border
- Concave upwards curve called ELLIS CURVE

→ Best X-ray view for Pleural effusion – Lateral decubitus view

→ Amount of fluid required to get blunting of CP angle

- 150-200 ml of fluid – on PA view
- 75 ml of fluid – on lateral view
- 15-25 ml of fluid – on lateral decubitus view

→ IOC for minimal Pleural effusion (<5 ml) – USG

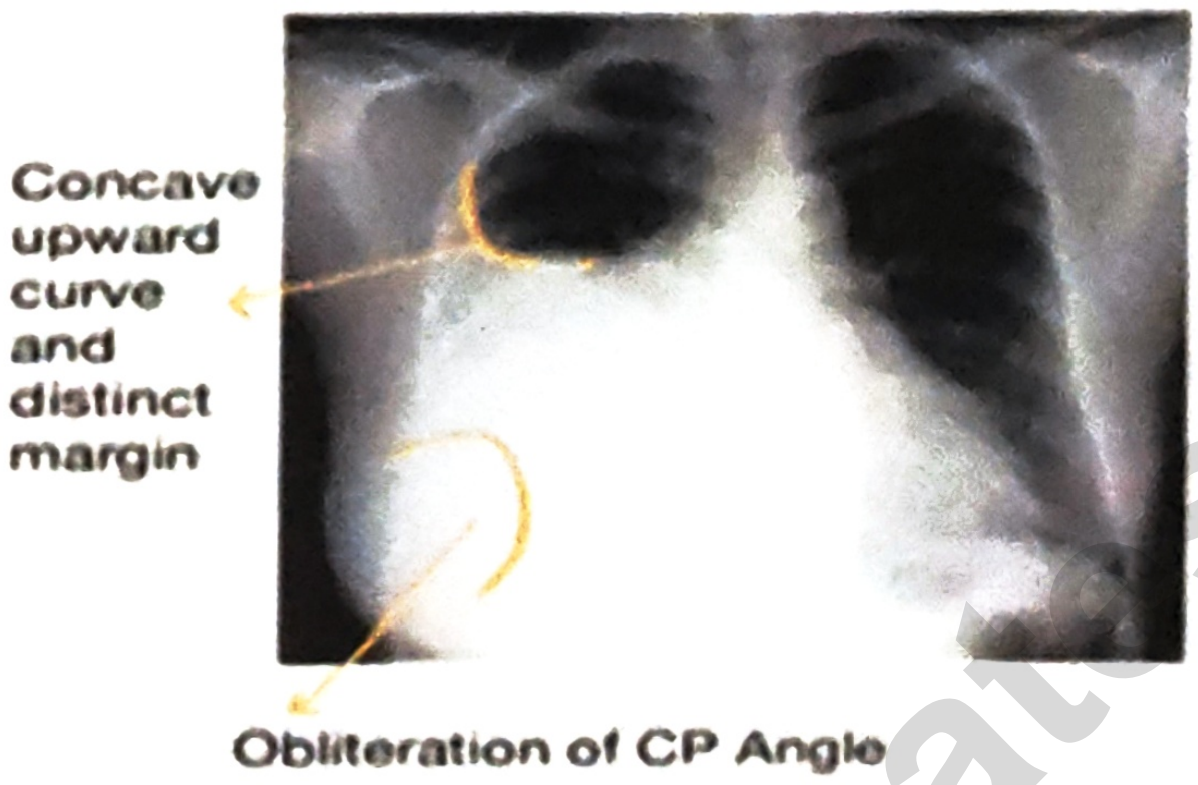

ELLIS curve

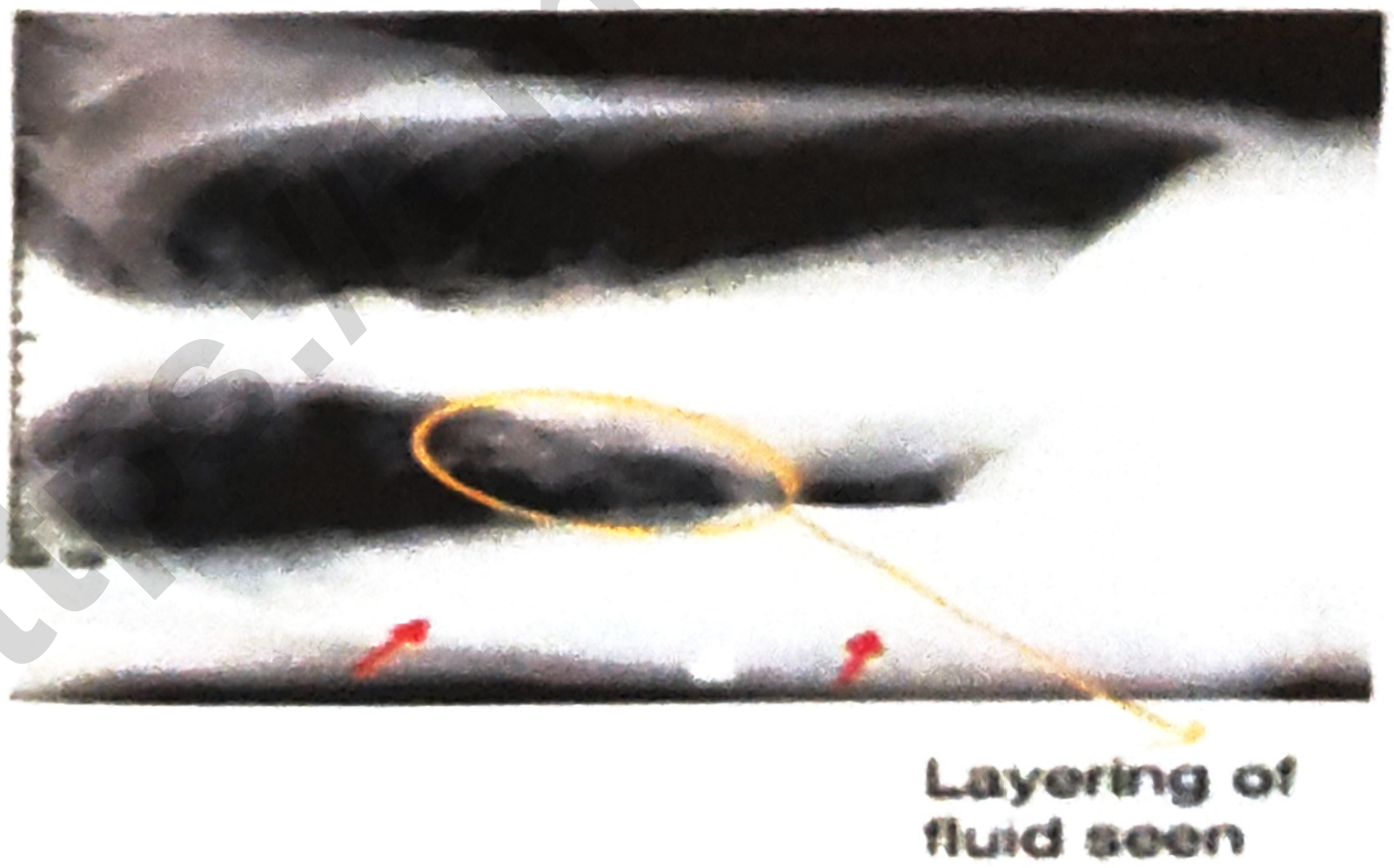

Pleural effusion – Right lateral decubitus

https://t.me/Latestneetpgnotes

PrepLadder

Massive pleural effusion

Meniscus sign

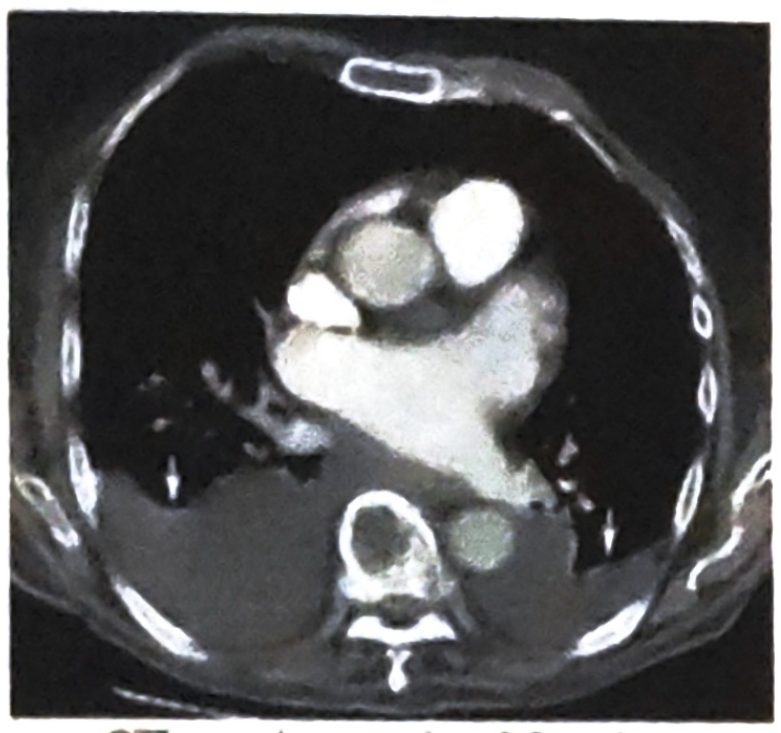

CT - pleural effusion

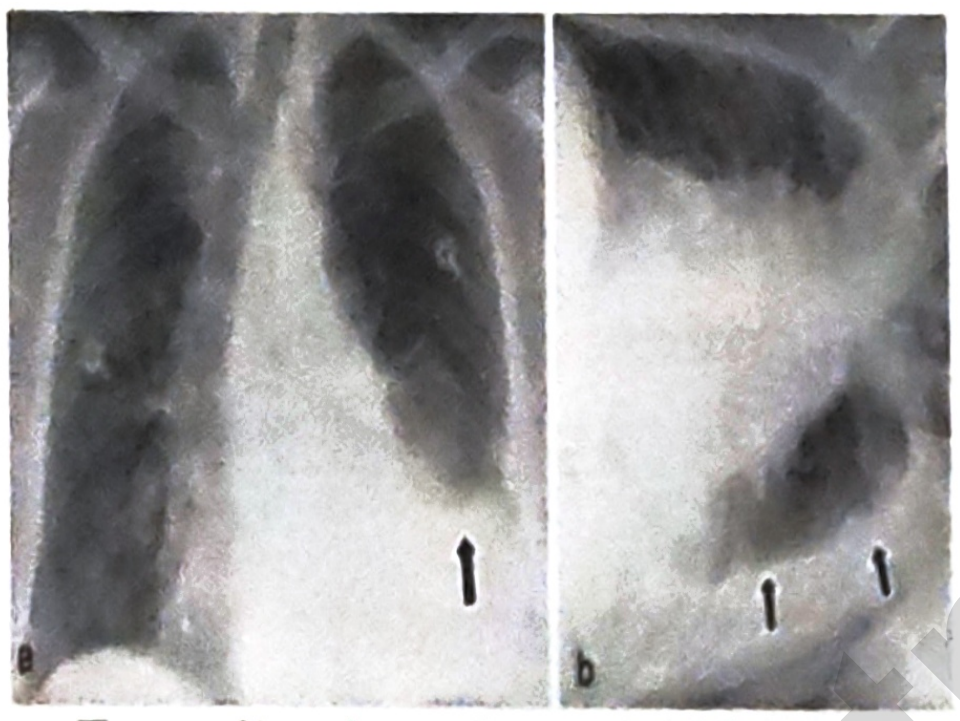

Free flowing pleural effusion

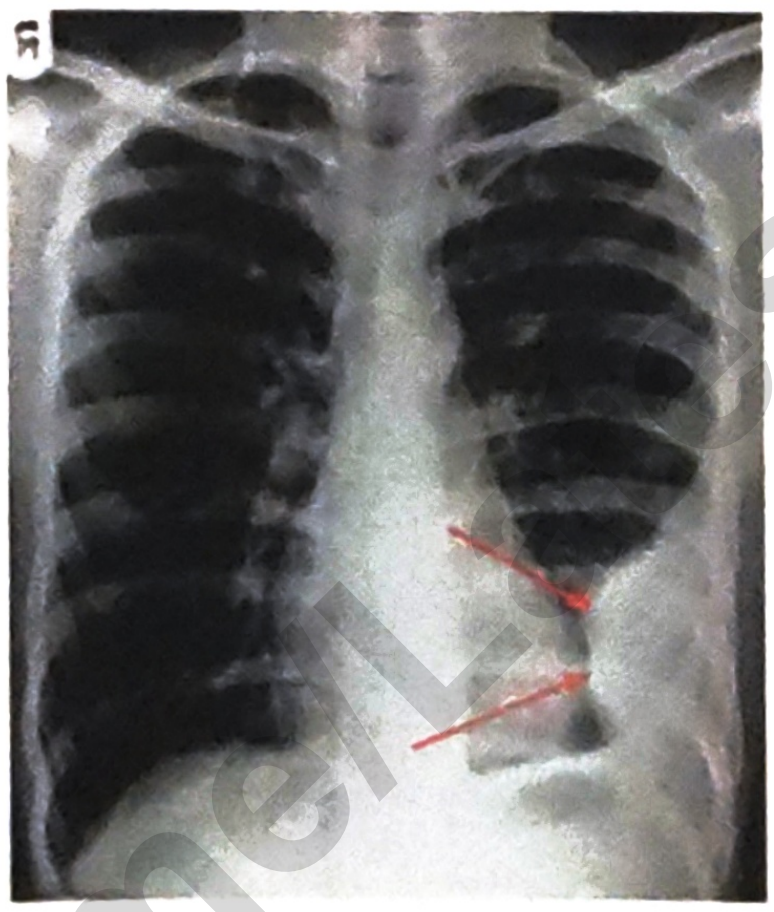

Loculated pleural effusion

Note:

→ Free flowing pleural effusion
  - Fluid moves with change in patient position

→ Loculated pleural effusion
  - Fluid does not move with change in patient position
  - D shaped collection of fluid
  - Difficult to aspirate

PrepLadder

Interlobar effusion / Phantom tumor

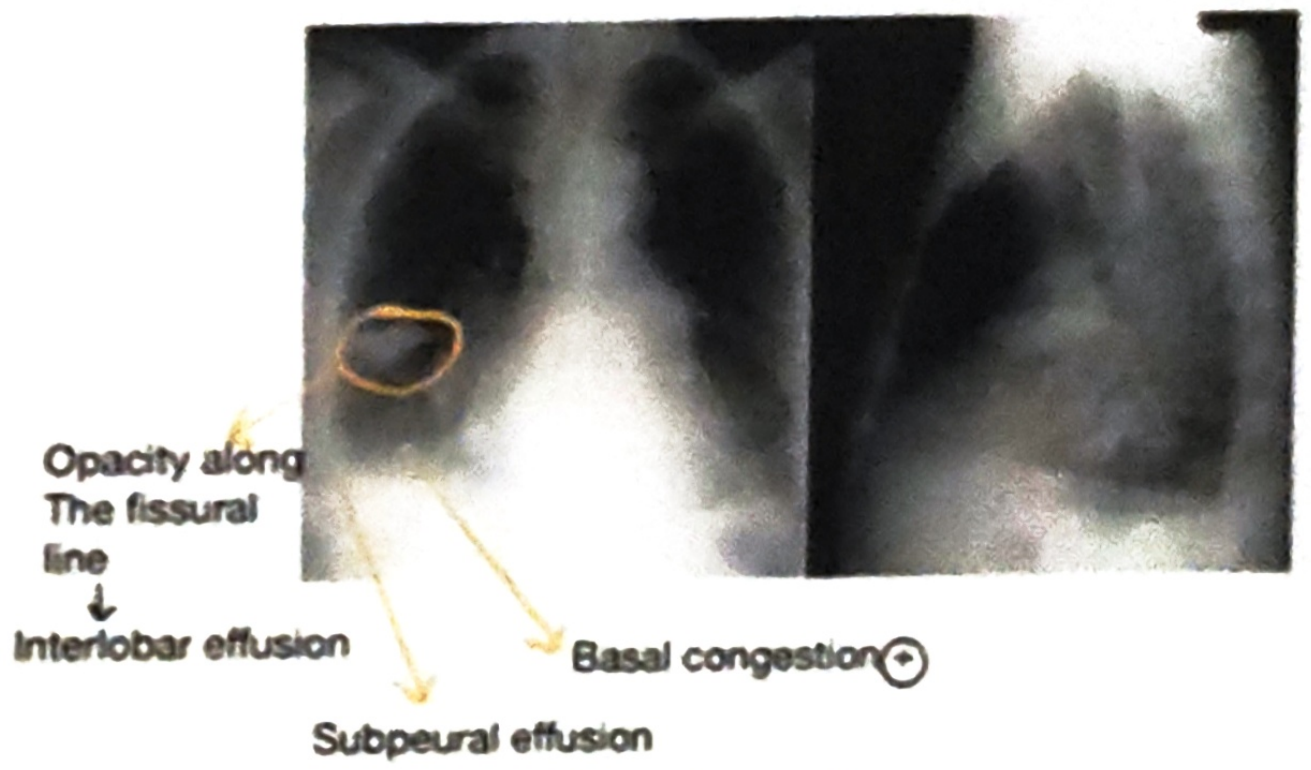

Phantom tumor
→ Congestive heart failure

Subpulmonic pleural effusion

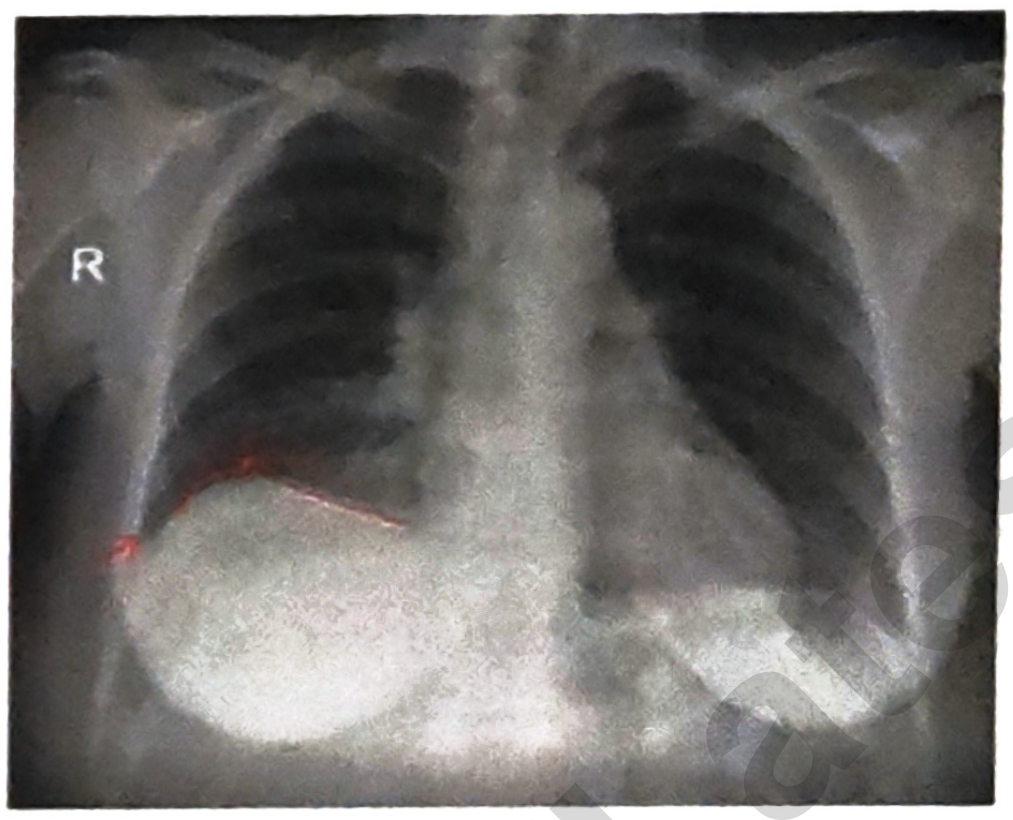

→ Lies between Lung & Diaphragm
→ Lateralization of Dome of Diaphragm

Parapneumonic effusion

→ Effusion in setting of pneumonia/ Abscess/ consolidation.

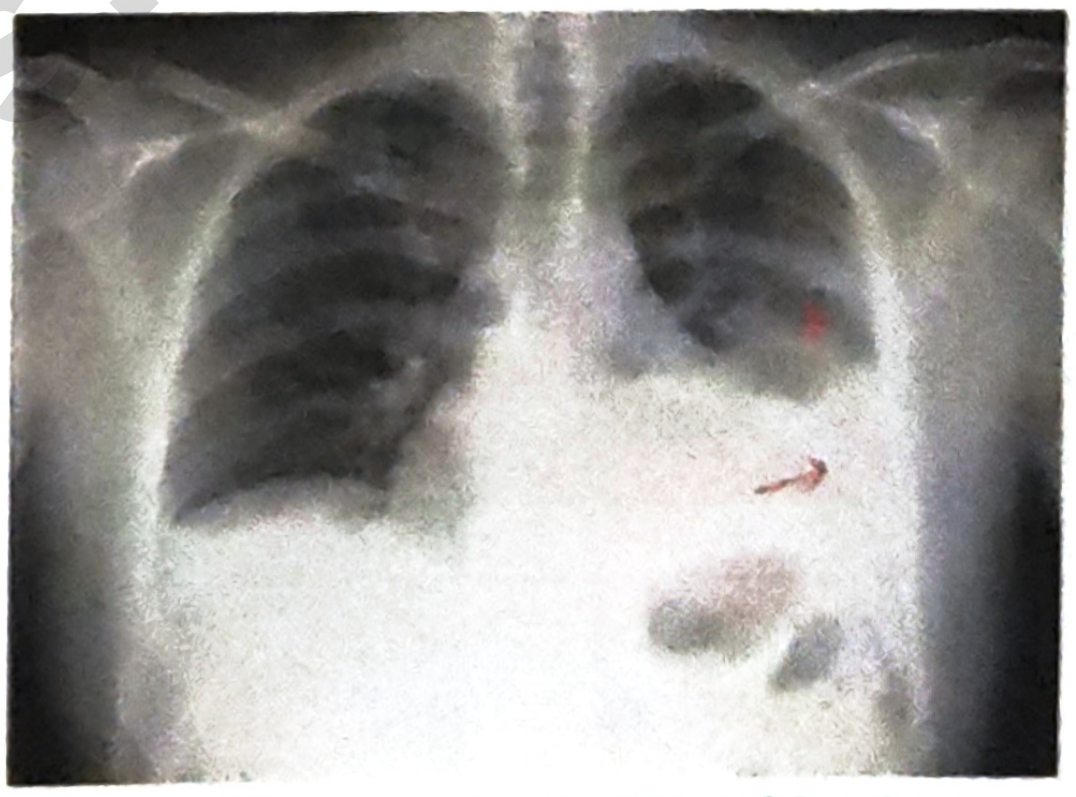

Parapneumonic effusion

https://t.me/Latestneetpgnotes

PrepLadder

Empyema

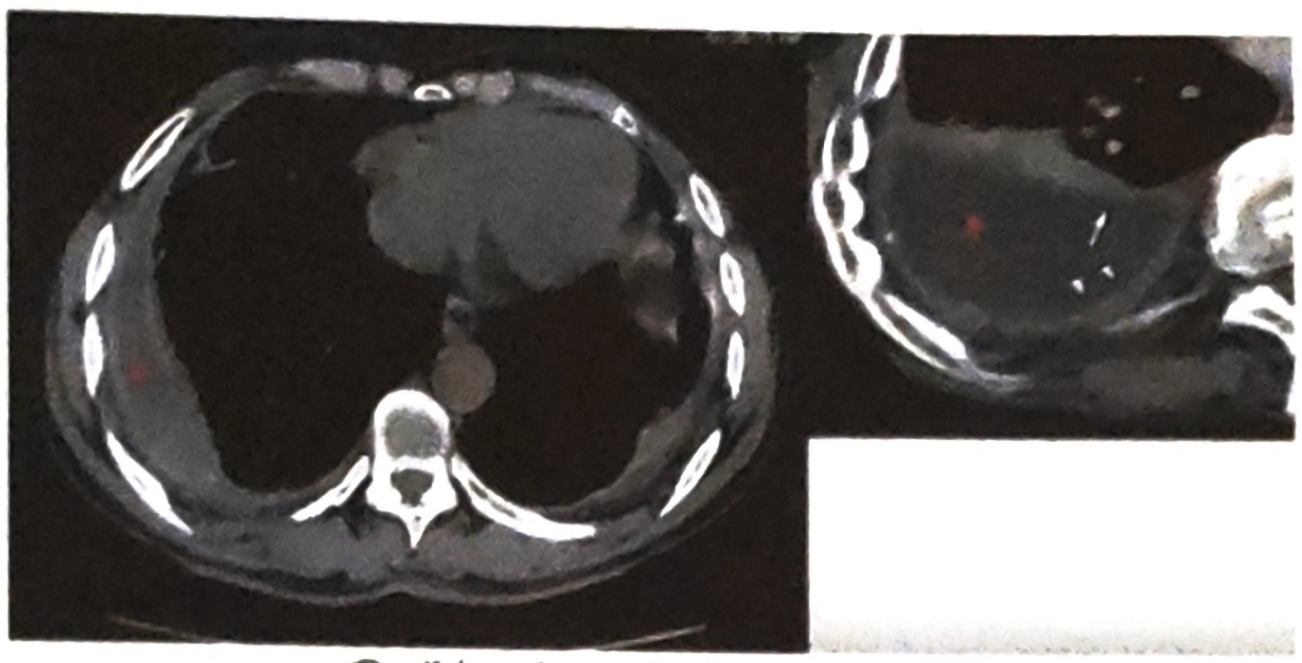

Split plural sign on CT

Hydropneumothorax

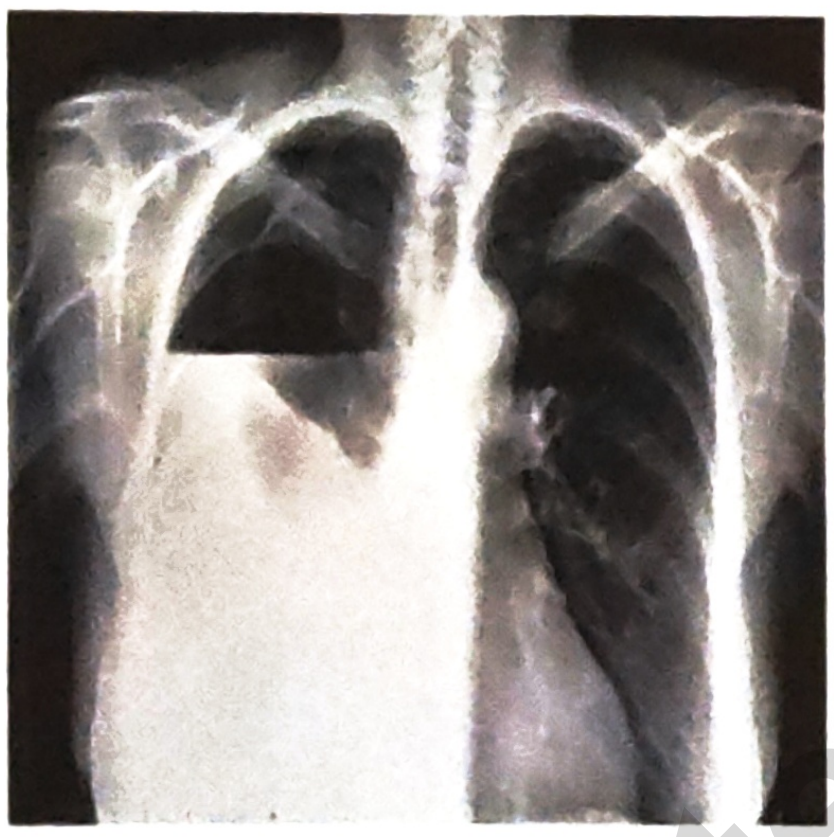

Hydropneumothorax

→ **Horizontal air fluid levels in the right hemithorax**

Air bronchogram

Chest X-ray

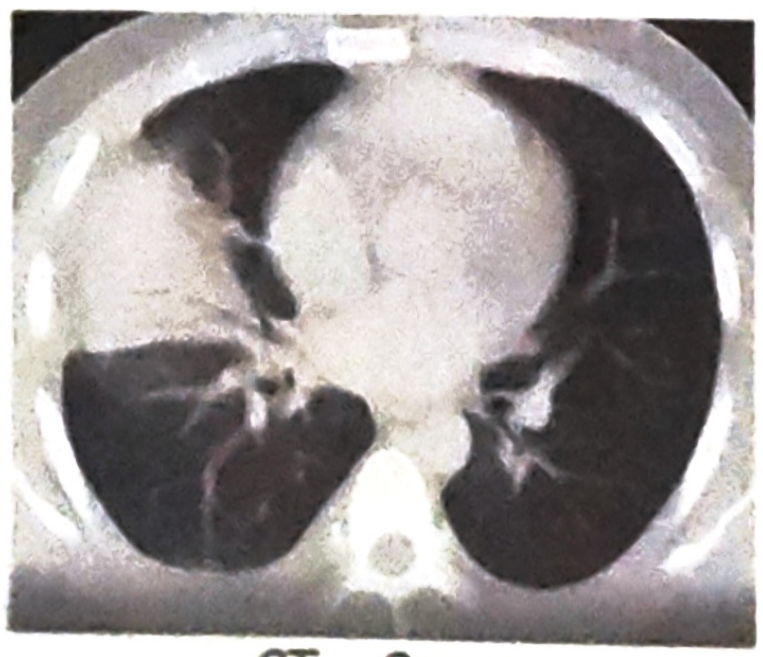

CT - Scan

https://t.me/Latestneetpgnotes

PrepLadder

CT angiogram sign

→Identification of vessels within an airless portion of lung on CECT

→The vessels are prominently seen against a back ground of low Attention material

→Associated with

- Broncho alveolar cell carcinoma
- Lymphoma
- Infectious pneumonias

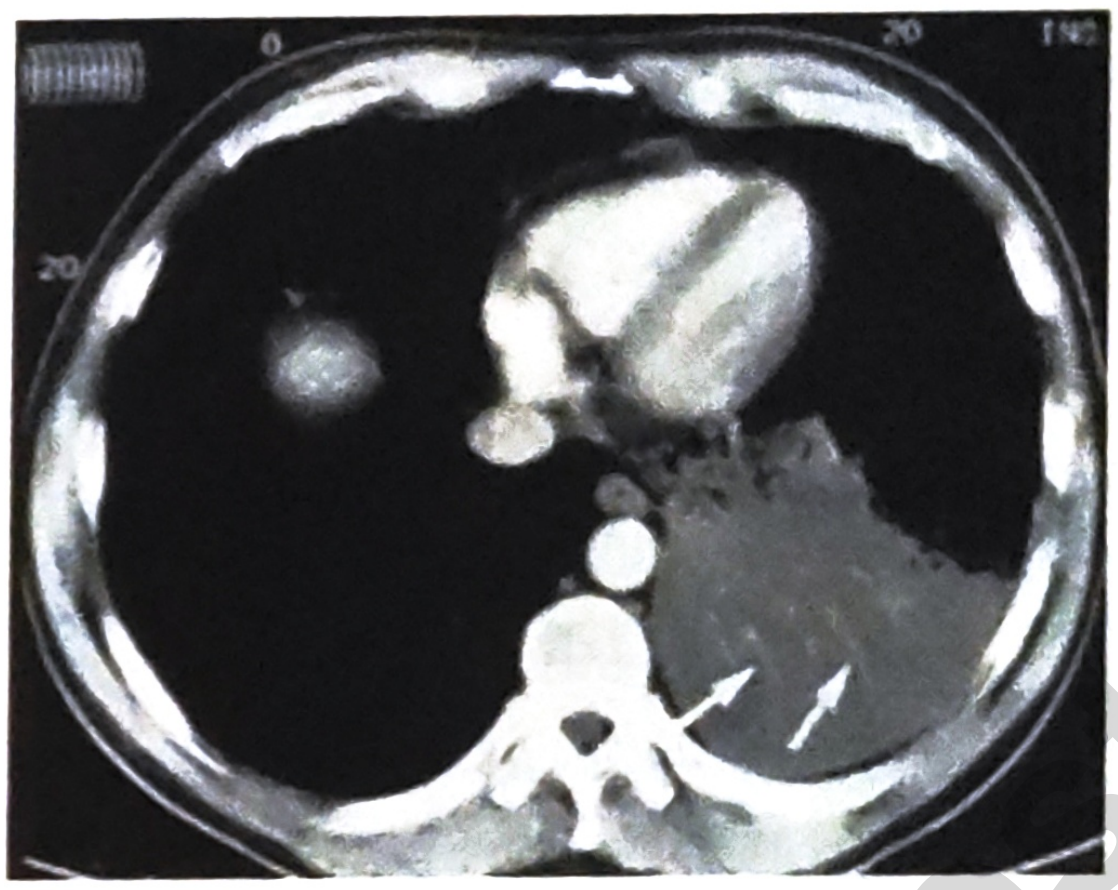

CECT – CT angiogram sign

Pneumatocele 01:35:19

→Seen in Infection with

- Staph aureus
- Pneumocystis carinii/ Pneumocystis jiroveci

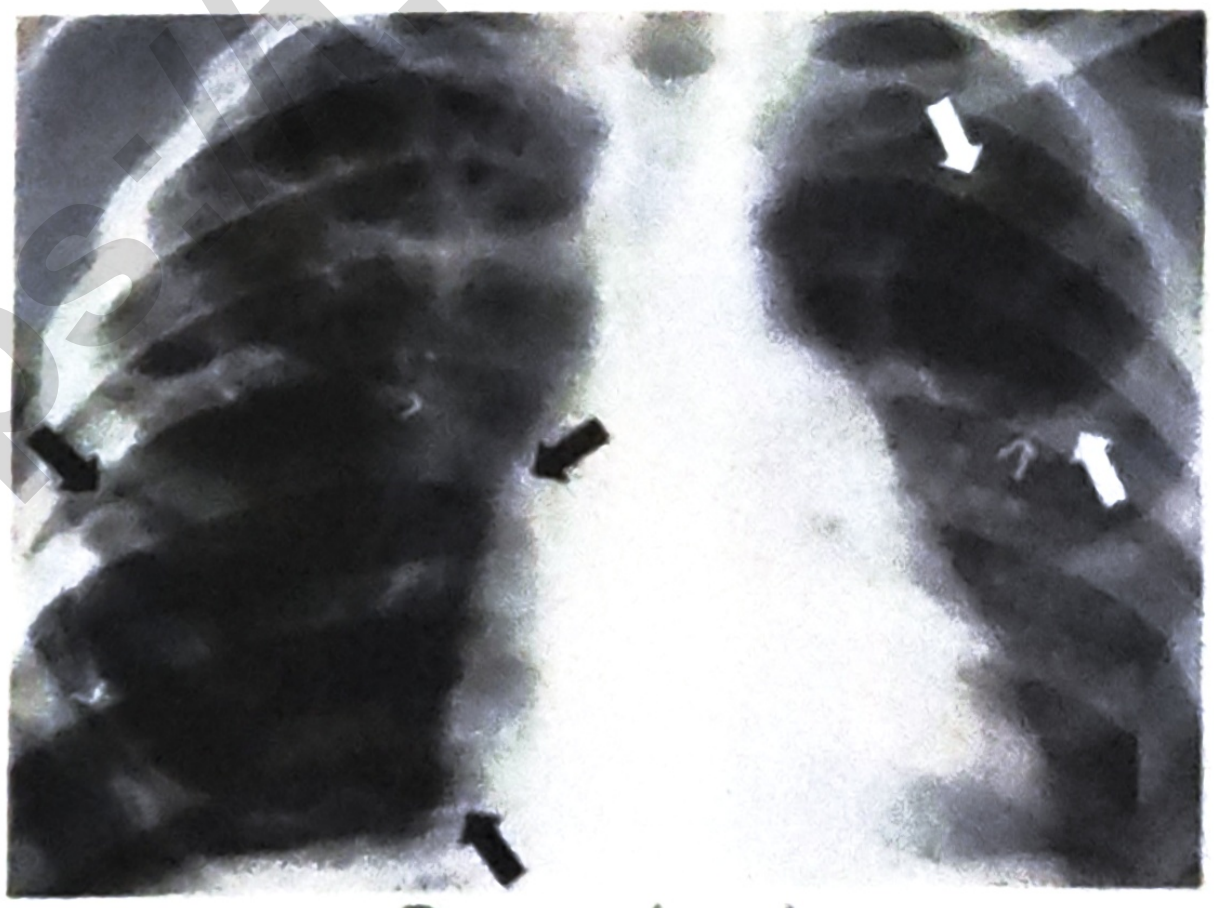

Pneumatocele

https://t.me/Latestneetpgnotes

PrepLadder

Klebsiella pneumonia

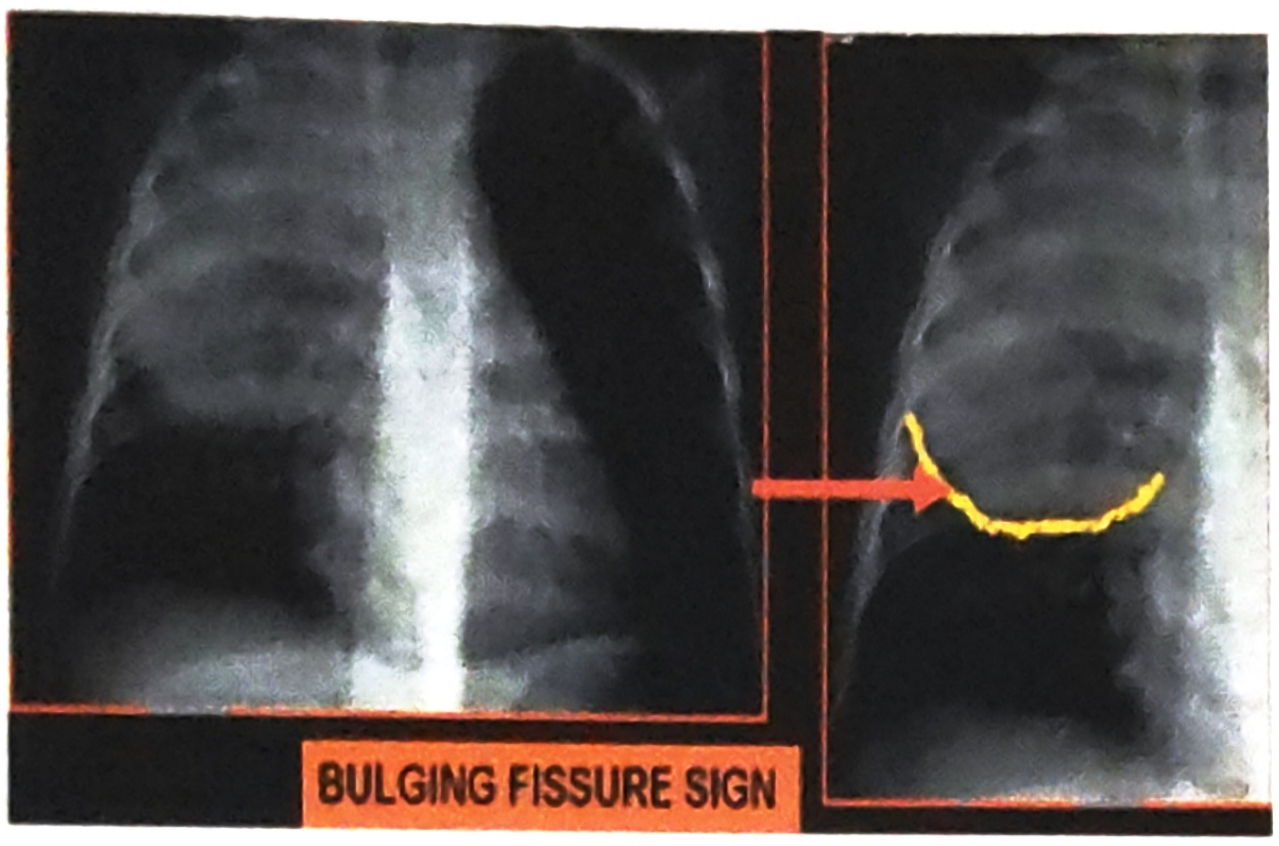

→ Aka Friedlander Pneumonia

→ Shows Bulging fissure sign

↓

Consolidation spreading rapidly, causing lobar expansion and bulging of the adjacent fissure inferiorly

Bilateral Bronchopneumonia

Interstitial pneumonia

→ Thin, fine reticular opacities in bilateral lung fields.

→ Viral pneumonia, Mycoplasma

Interstitial pneumonia

https://t.me/Latestneetpgnotes

PrepLadder

Round pneumonia

→ In child

→ Hazy margin

→ Mass like opacity mainly in middle lobes

→ Haemophilus influenza, Streptococcus – common causes.

Round pneumonia

Aspiration pneumonia

→ Opacities on the dependent portion of the lung, mainly on right side.

Aspiration pneumonia

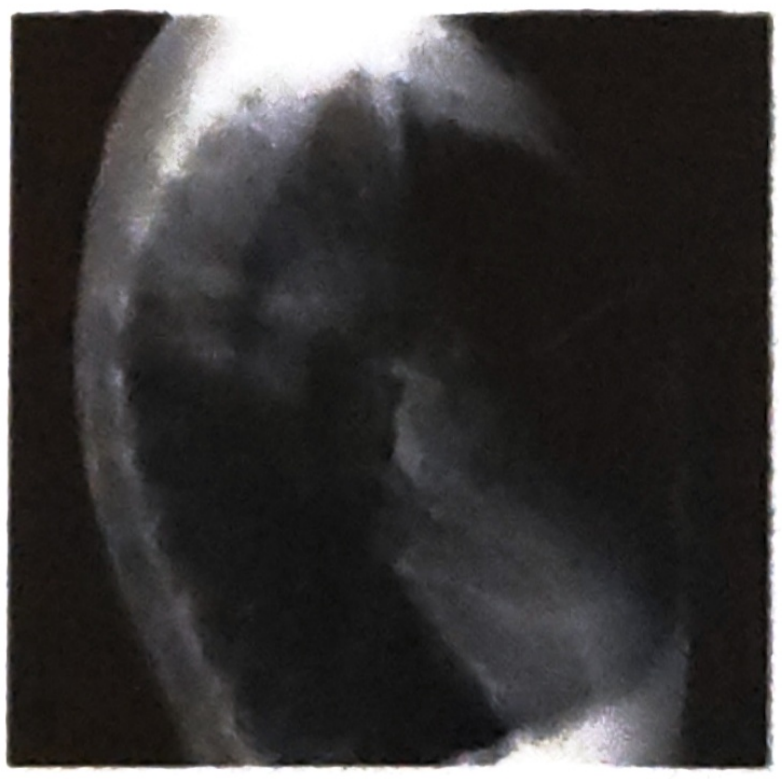

COPD – lateral X-ray

https://t.me/Latestneetpgnotes

PrepLadder

Respiratory system

Sarcoidosis
- On chest X ray
  - B/L hilar lymphnodes
  - 1,2,3 sign / garland sign
- On CT
  - Galaxy sign
  - On gallium 67 scan
- Panda sign
- Lambda sign

Aspergillosis
ABPA
- Finger in glove appearance
- Aspergilloma fungus ball
- Monod sign / Air crescent sign
- Angio invasive aspergillosis
- Halo Sign

Pulmonary edema
Shows bilateral perihilar confluent opacities BAT WING APPEARANCE

Pulmonary Thromboembolism
Radiological signs
- Hampton hump sign
- Wester mark sign
- Pallas sign
- Chang sign

Investigatoin
- IOC for pulmonary embolism: CT Angio
- In iodine allergies and pregnancy IOC- v/q scan
- Gold standard for PE - pulmonary angiography

Respiratory System

Pleural effusion
- Best X ray view: lateral decubitus view
- Findings :
  - Obliteration of CP angle
  - Distinct border
  - Concave upward curve Called Ellis CURVE

COPD
A-Widening of intercostal space
B-flattening of domes of diaphragm
C-Hyper inflated lung fields

Bronchiectasis
- Shows signet ring sign and tram track appearance

Bronchogenic Carcinoma
- Golden's sign or Reverse S signs
- Seen in Bronchogenic carcinoma with right upper right lobe collapse

https://t.me/Latestmedpgnotes

Chapter 35

ANGIOGRAPHY

Digital subtraction angiography

00:00:31

→ An X-ray procedure where pre-contrast & post contrast images are digitally subtracted – giving contrast opacified vessels

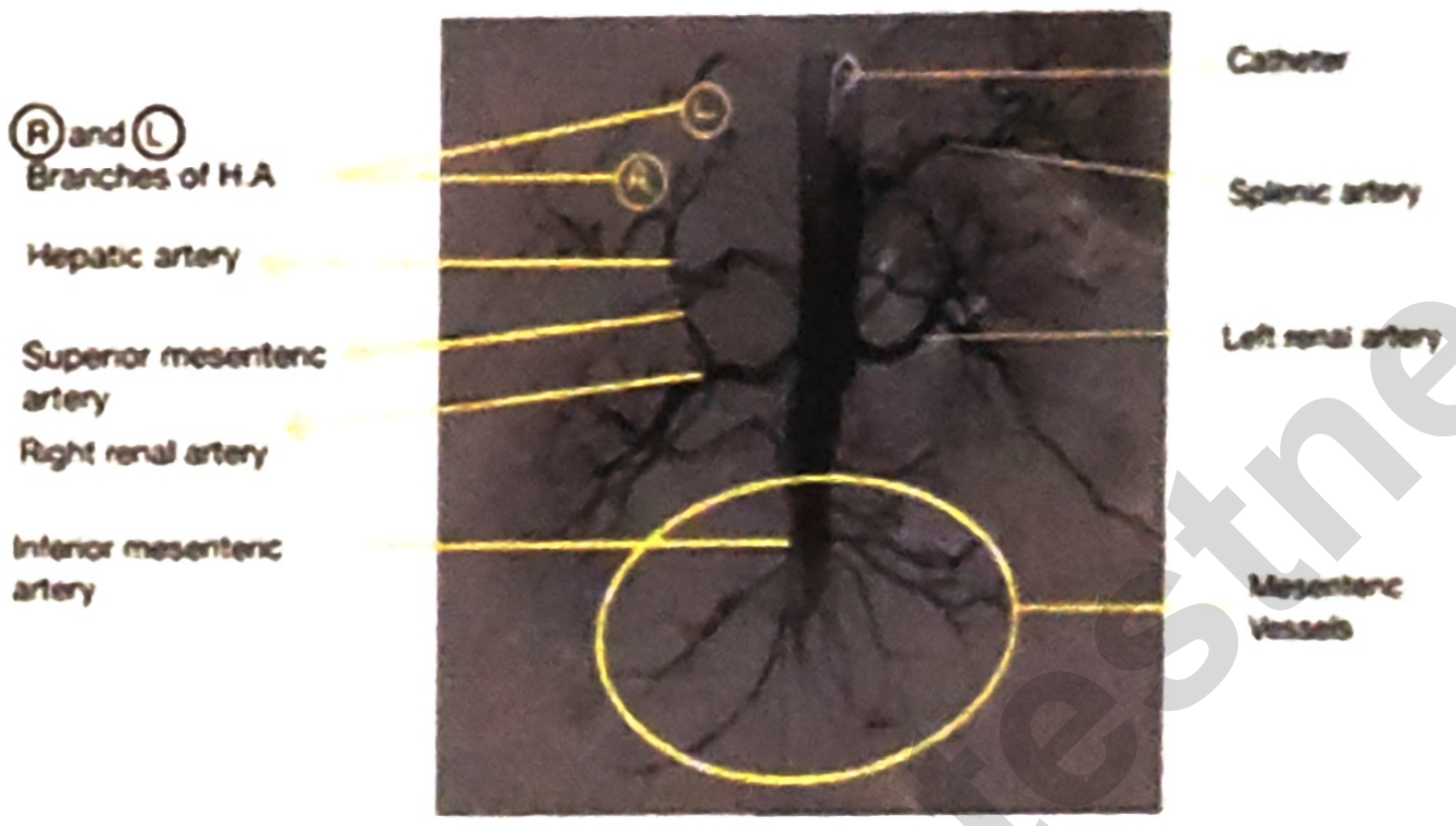

Digital subtraction angiography

CT angiography	MR-angiography
→ Bone are white & vessels are Visible	→ Bones are black & vessels are white → Gadolinium is used as contrast → "Time of flight" software – used For MR angiography without Contrast

https://t.me/Latestneetpgnotes
PrepLadder

Bovine arch

→M/C congenital anomaly associated with arch of aorta

→Right brachiocephalic & Left common carotid artery takes common origin

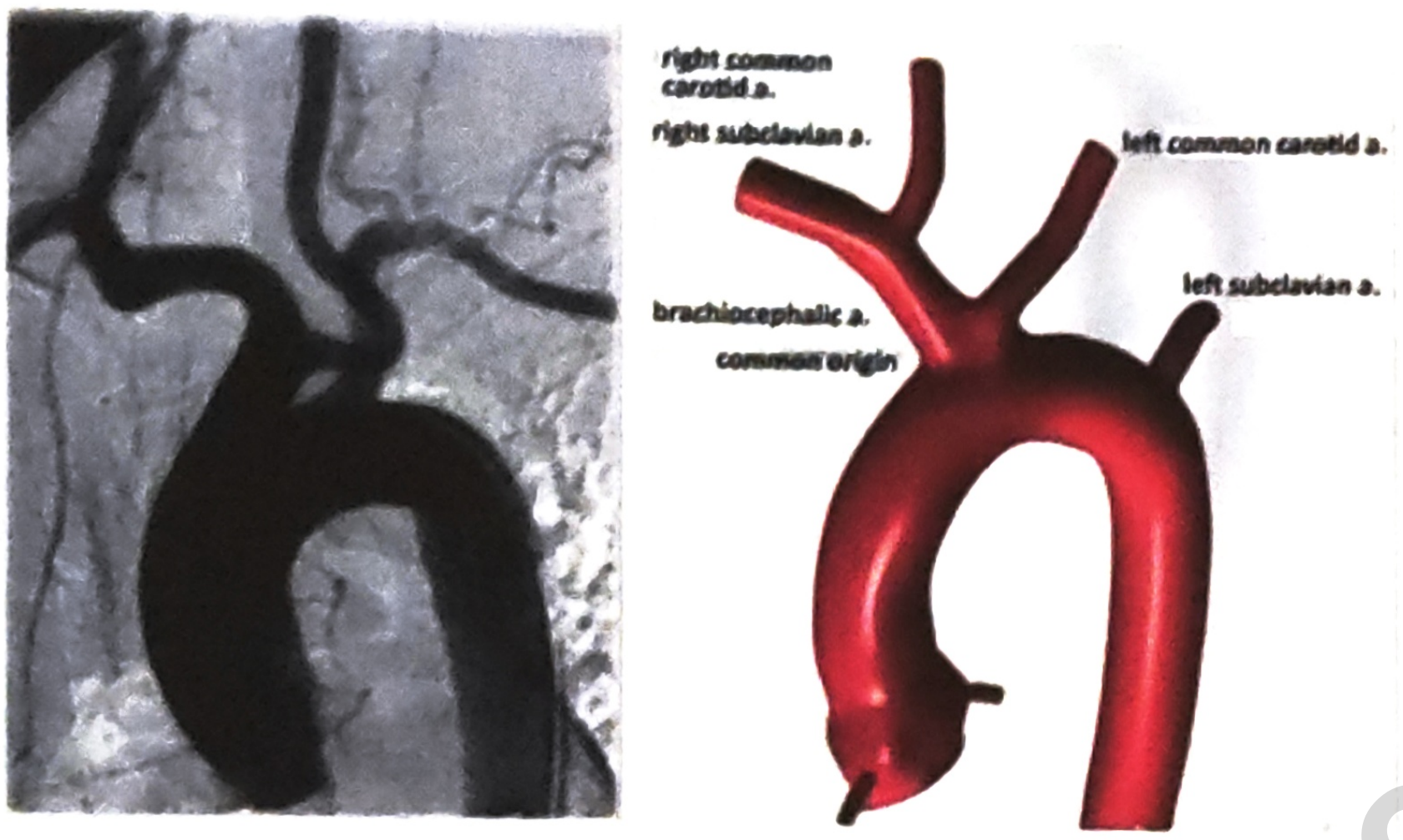

Celiac artery in angiogram

00:03:00

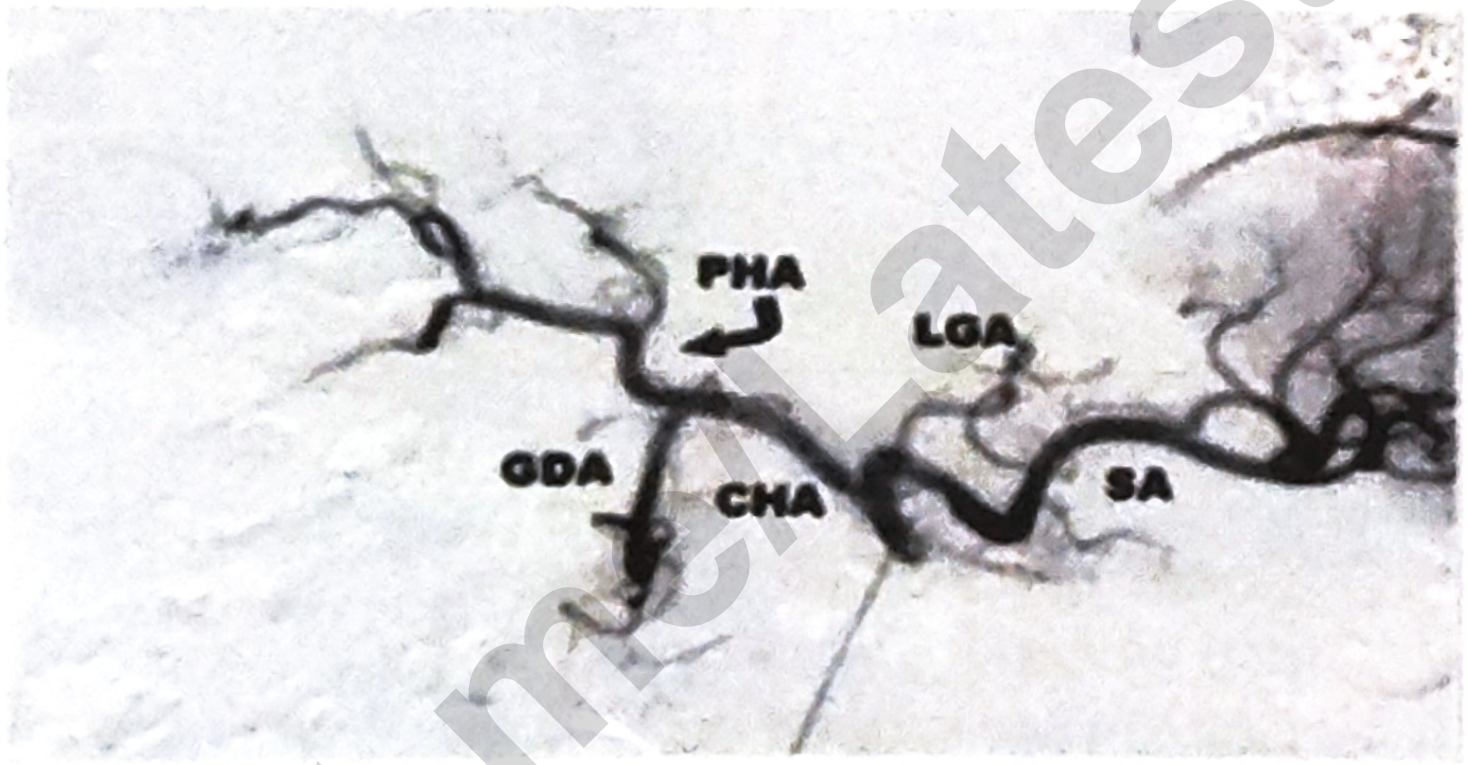

LGA – Left Gastric artery;
CHA – Common Hepatic artery
GDA – Gastroduodenal artery;
SA – Splenic artery;
PHA – Proper hepatic artery

Superior mesenteric artery

→Chief artery of Midgut

→Superior mesenteric vein is always to right of SMA – if there is change in this position, it indicates midgut volvulus

→Divides into right & left branches:

https://t.me/Latestneetpgnotes

PrepLadder

Superior mesenteric artery → Right side branches • Middle colic A • Right colic A → Left side branches • Jejunal A • Ileal A	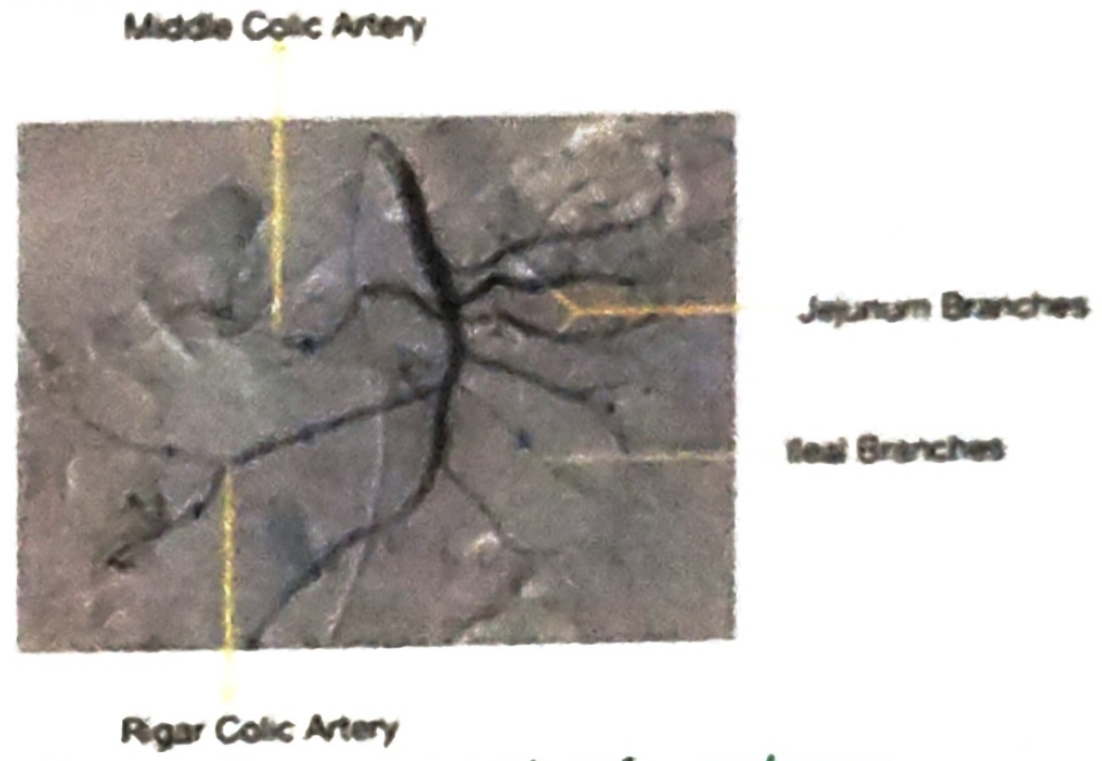 Superior mesenteric artery
Inferior mesenteric artery → Left sided branches • Left colic A • Sigmoidal A • Superior rectal A.	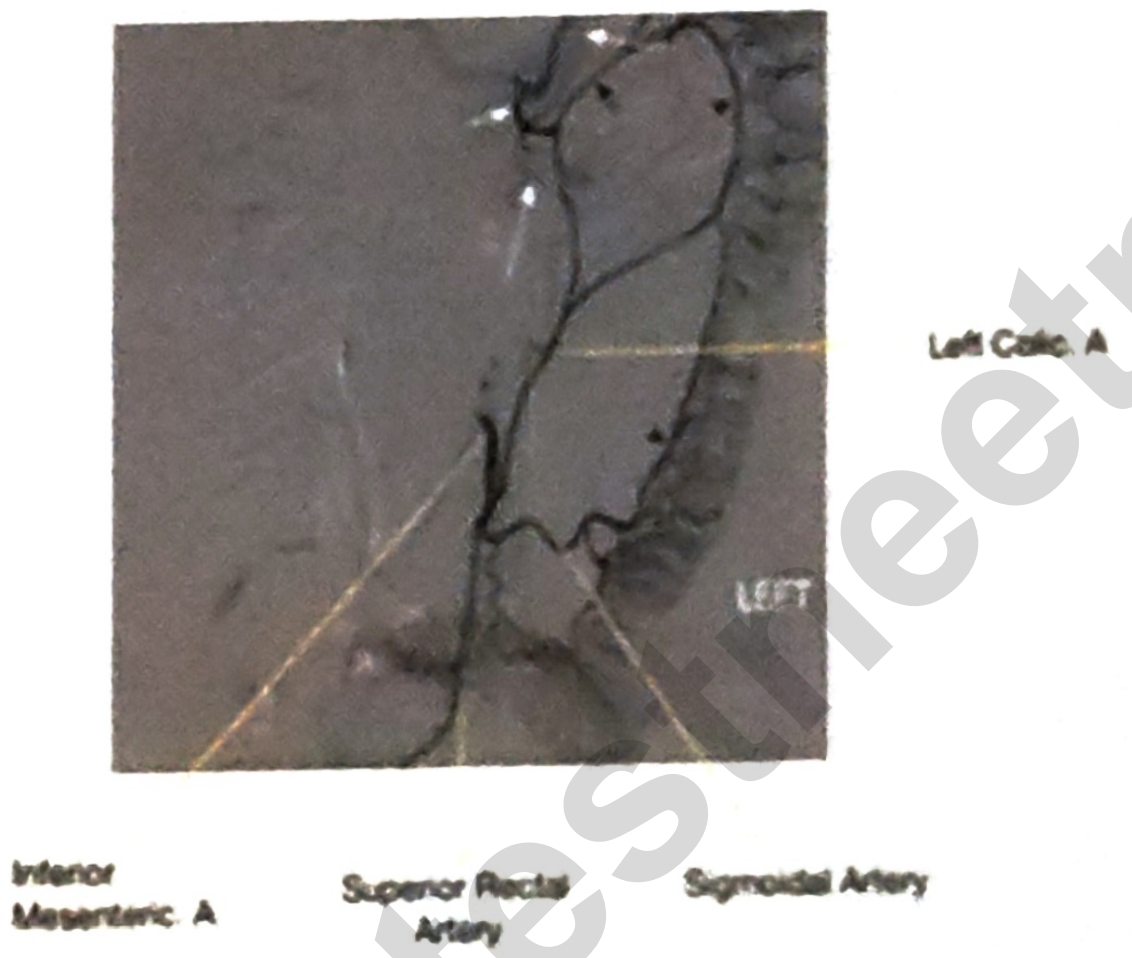 Inferior mesenteric artery

Coronary Angiogram

00:07:42

CT scan image showing coronary vessels

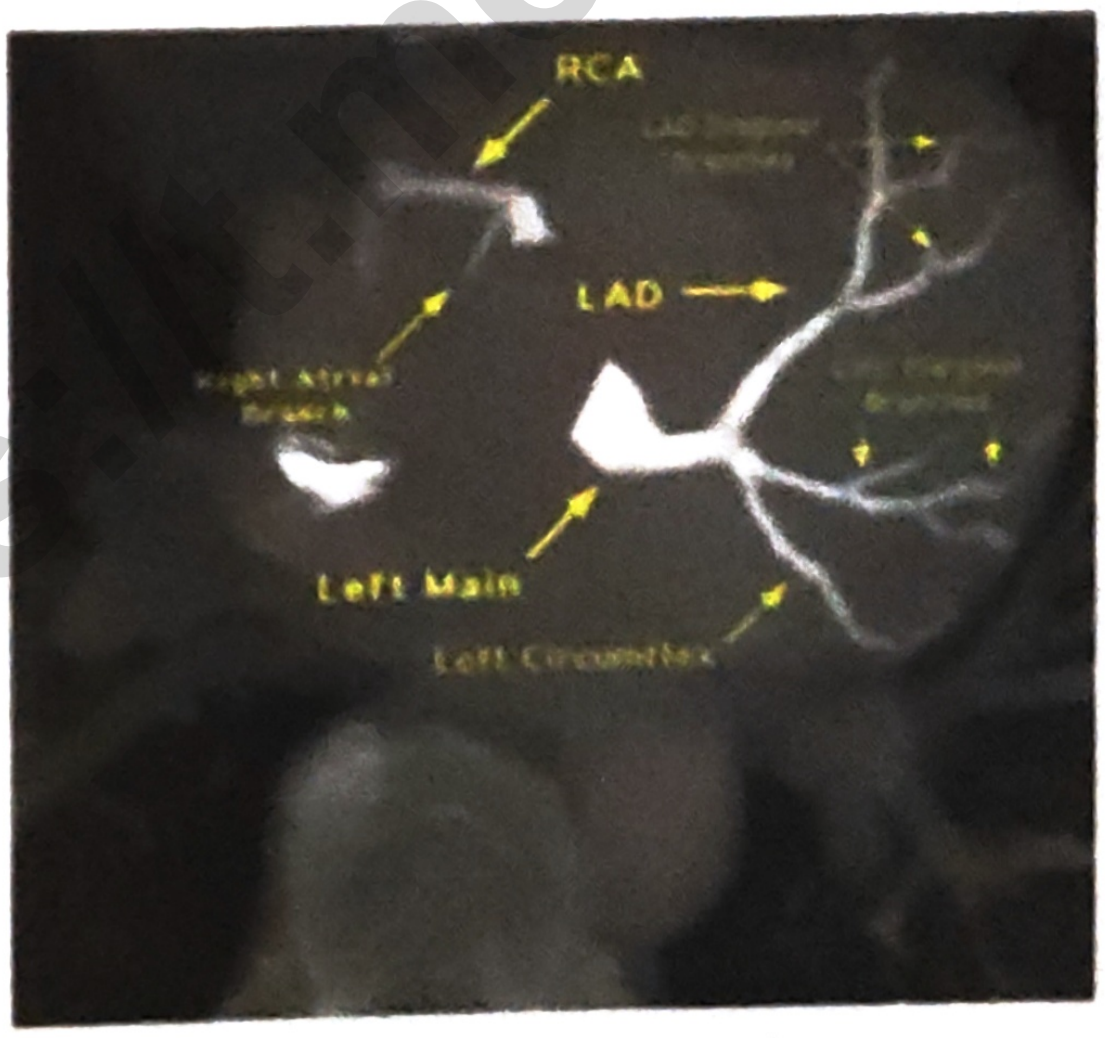

Coronary vessels

https://t.me/Latestneetpgnotes

PrepLadder

MR angiography showing circle of willis 00:12:55

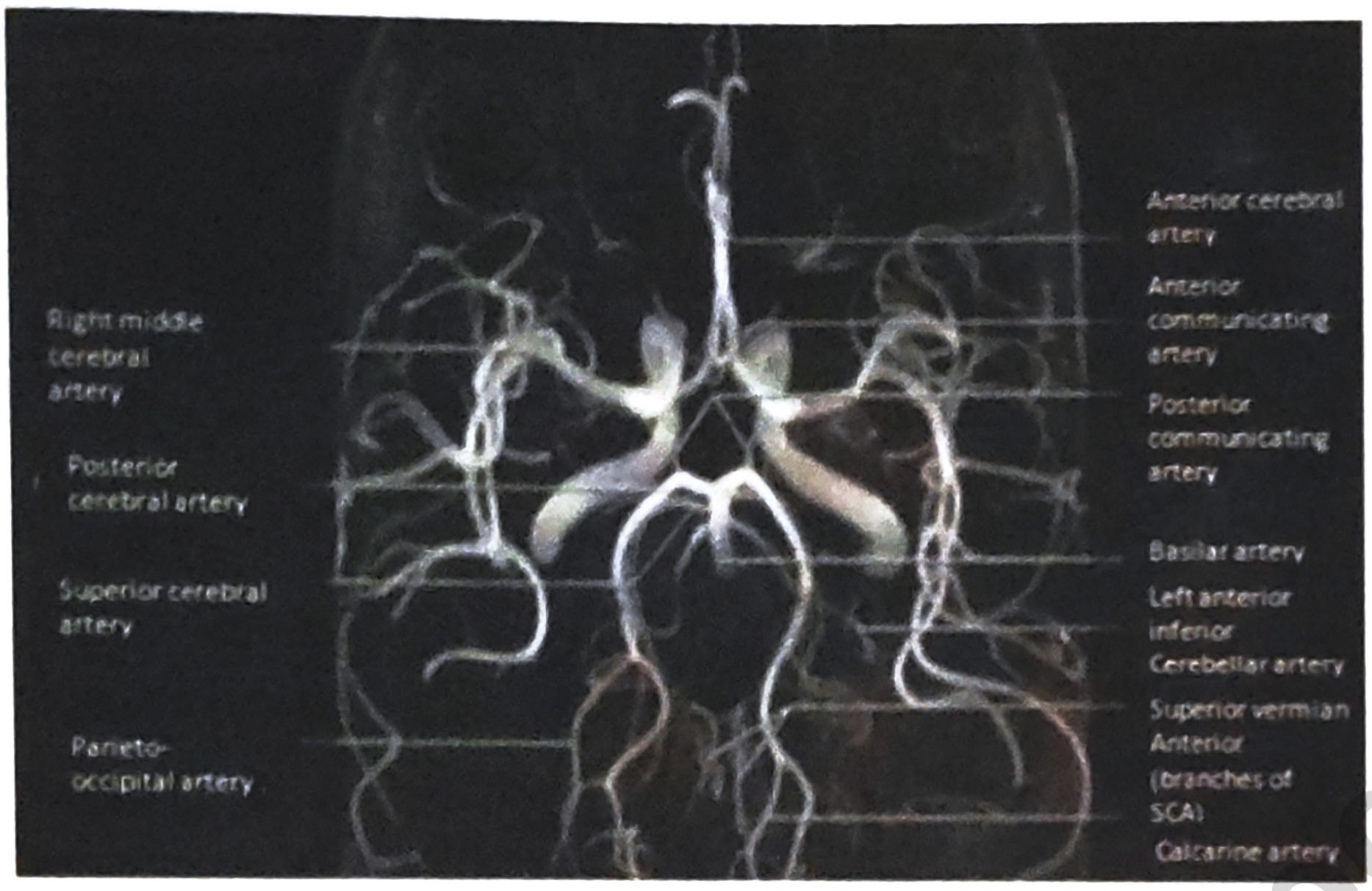

MR venography showing Dural venous sinuses 00:16:01

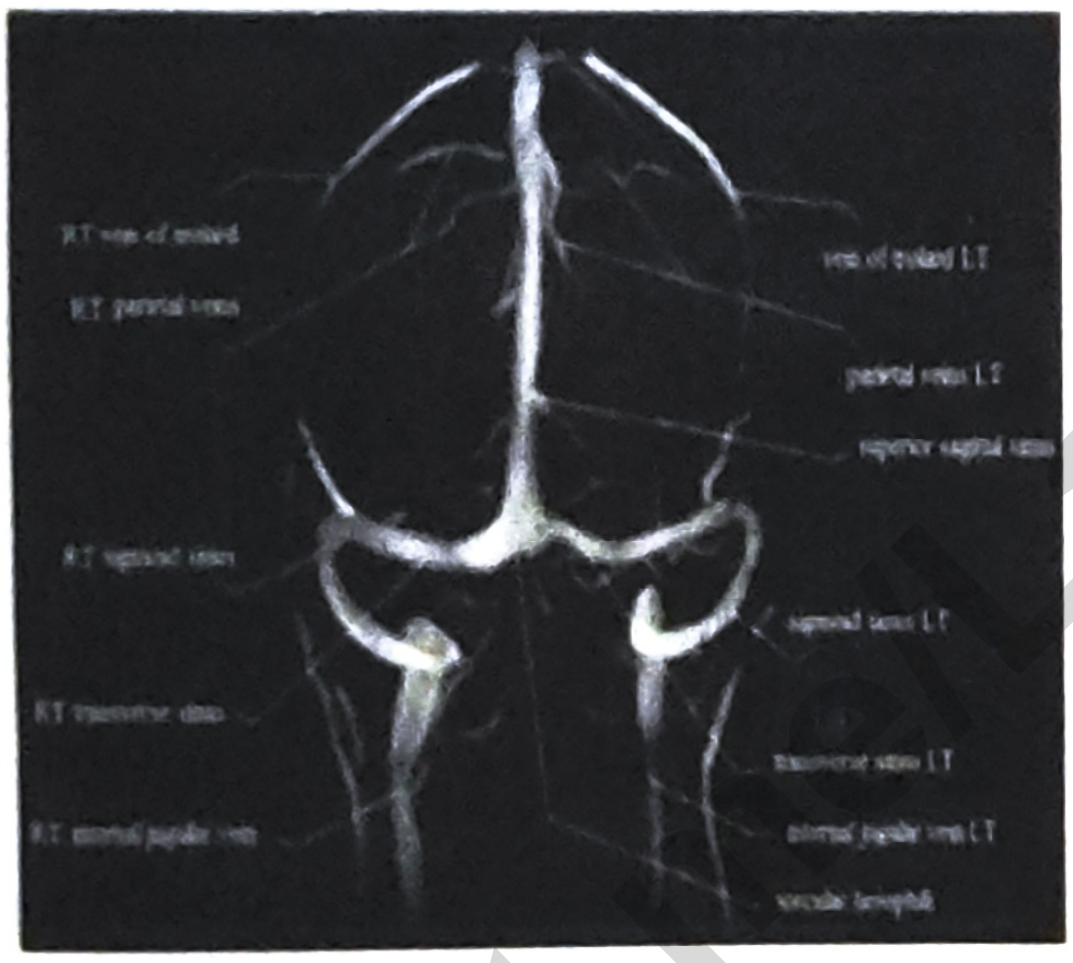

Coronal view

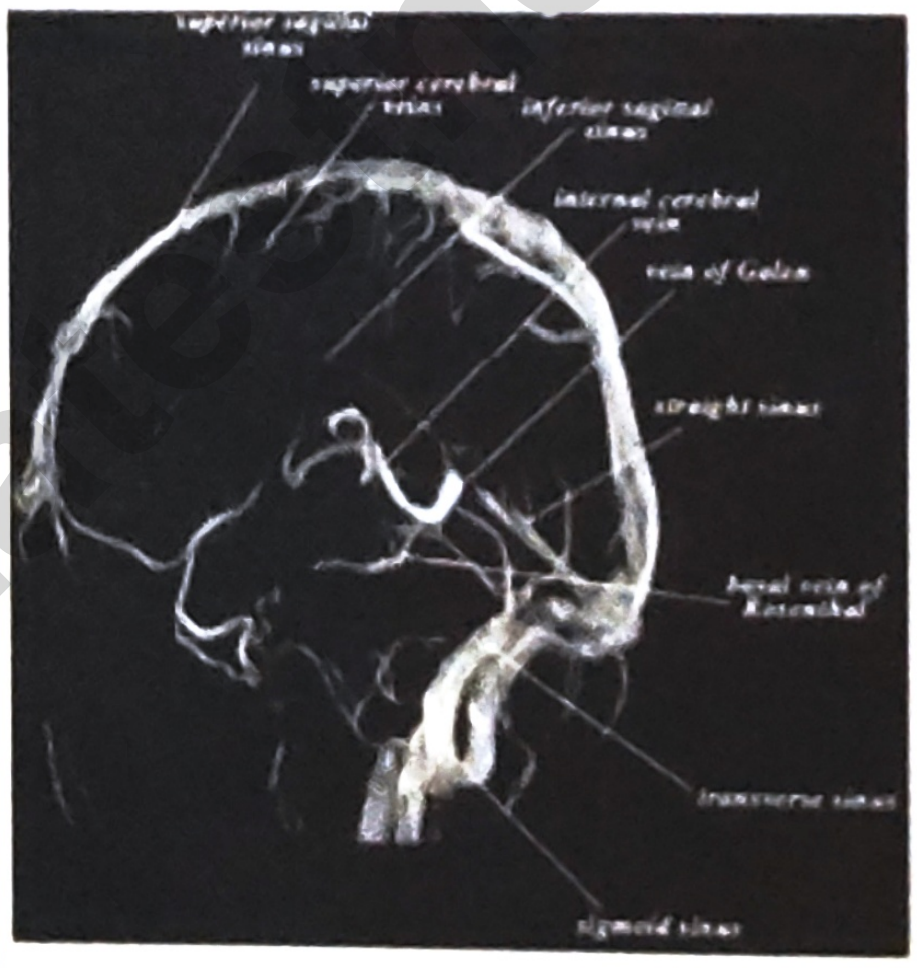

Sagittal view

Transverse / lateral sinus thrombosis

- →Shows filling defect in Dural venous sinuses in MR venography or contrast study-known as Griesinger sign
- →Seen in CSOM (chronic suppurative osteomyelitis)

https://t.me/Latestneetpgnotes

PrepLadder

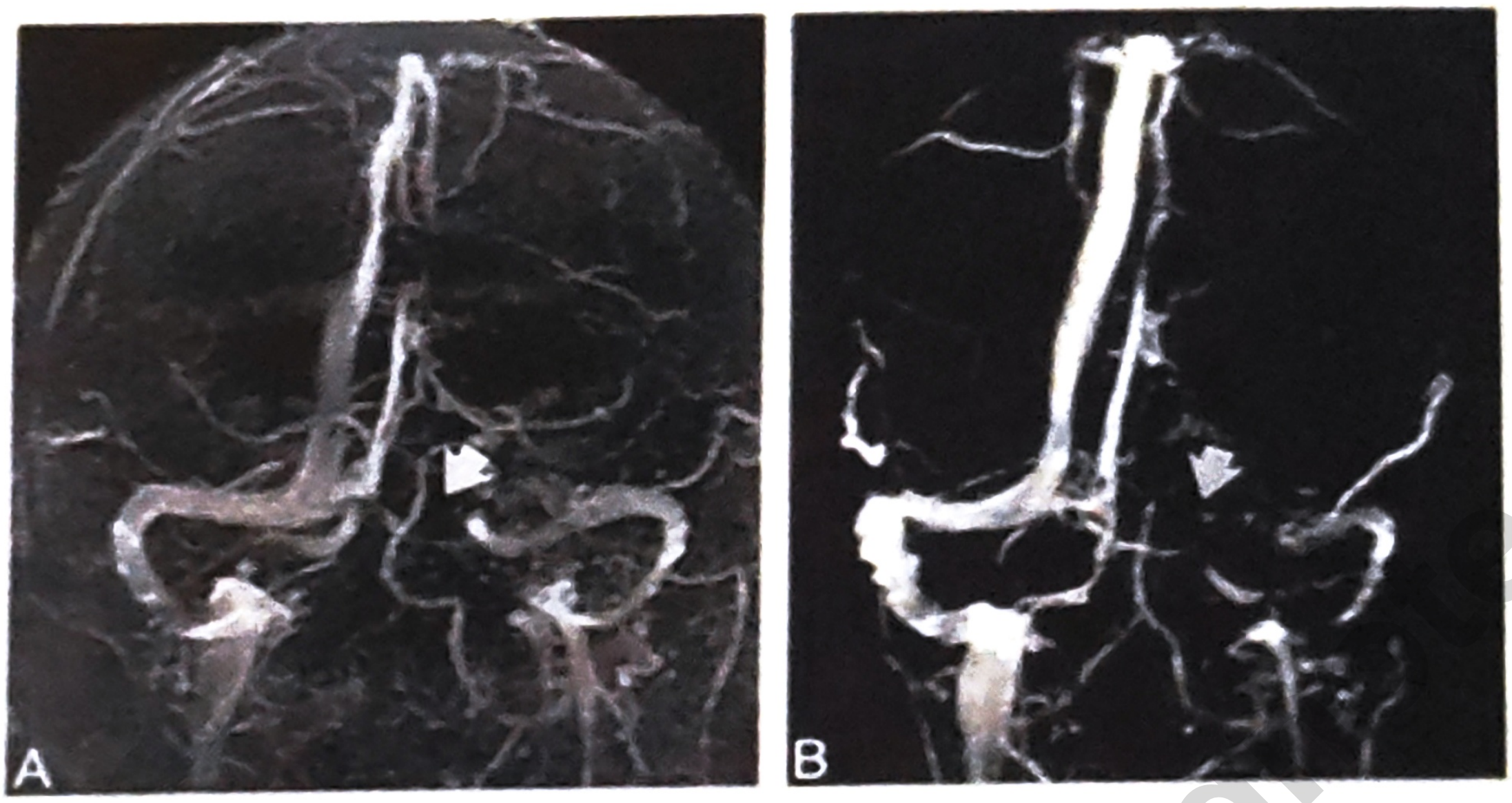

Sinus thrombosis

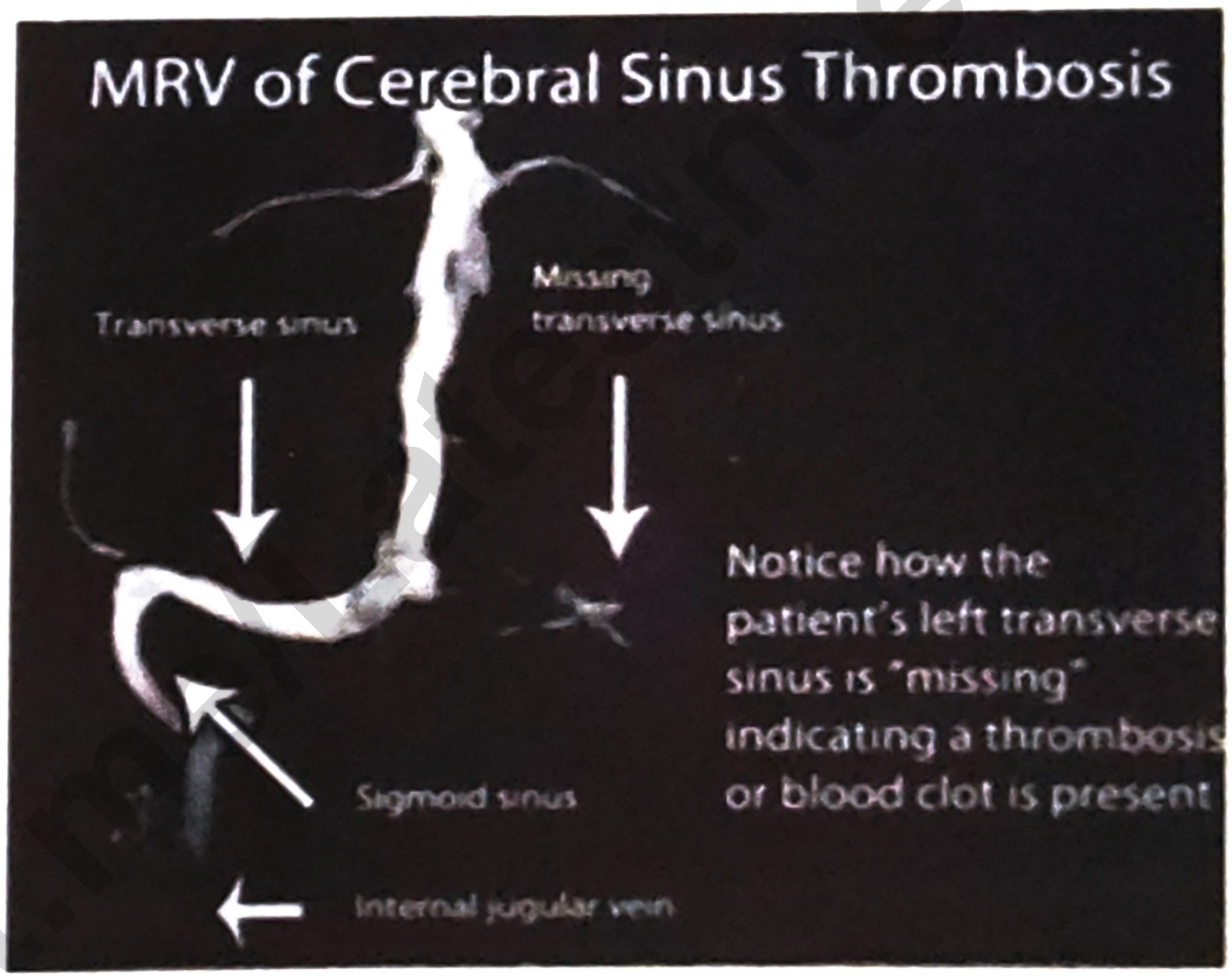

Chapter 36

CONTRAST AGENTS

Contrast agents

00:00:32

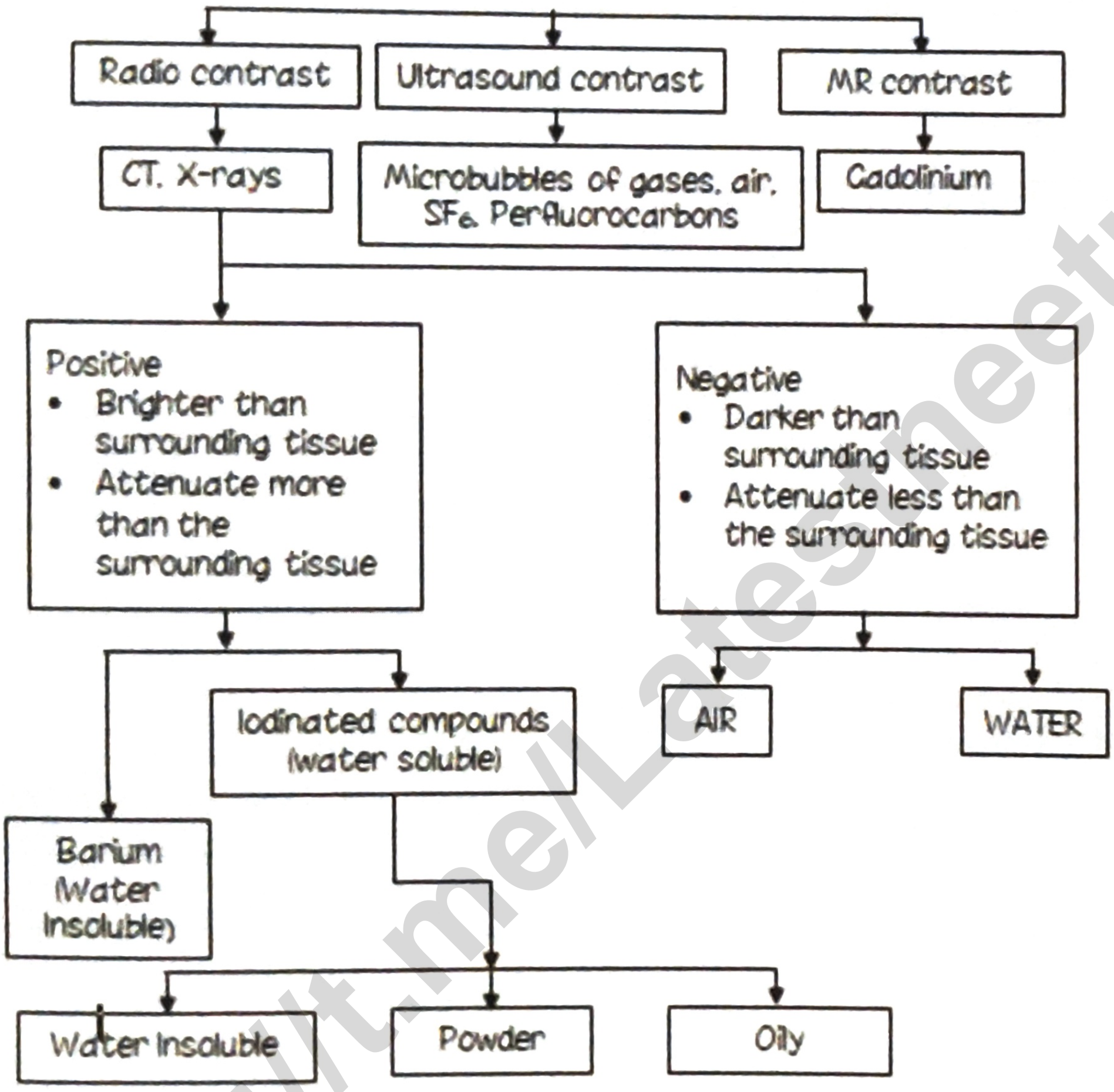

$BaSO_4$

00:06:45

→High Atomic number-56

→Inert, doesn't interface in digestion

→Not absorbed, Non toxic

→Coat Mucosa Uniformly

→Water insoluble, used as suspension

→C/I in Bowel perforation – Peritonitis, Mediastinitis

https://t.me/Latestneetpgnotes

PrepLadder

Barium Studies

• Barium Swallow	– Esophagus
• Barium Meal	– Stomach and duodenum
• Barium Meal Follow through	– Small bowel, jejunum & ileum
• Barium enema	– Large Bowel

Iodinated Compounds

00:08:25

→Iodine- Radiopaque, atomic no. 53

Water soluble	Water Insoluble Suspension	Oily
• Tri-iodinated compounds	• Di-iodopyridines	• Myodil • Lipiodol • Iophendylate

Water Soluble Iodinated compounds

→Tri-iodinated Compounds

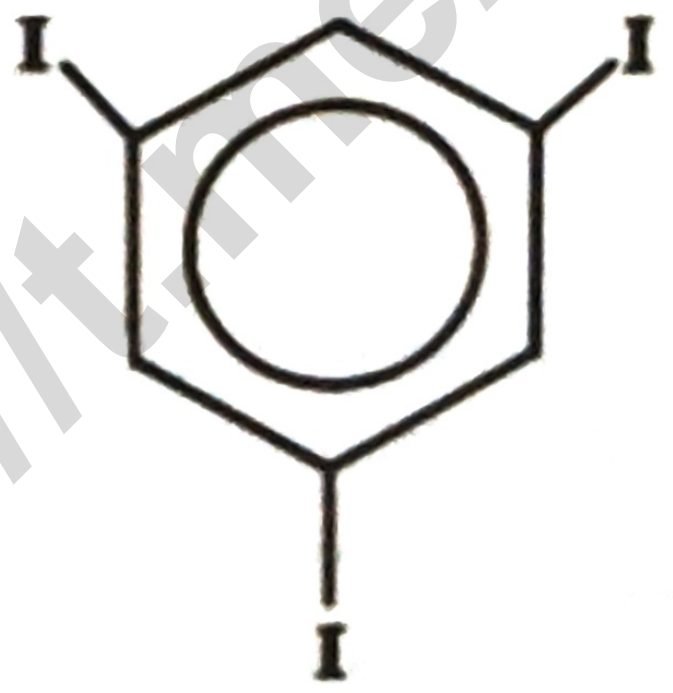

→ Iodine particle ratio

- Iodine - Radio opaque, used as Contrast
- Particle-Increases osmolality &increases nephrotoxic
- I/P = So Ideal contrast should have high I/P ratio

PrepLadder

https://t.me/Latestneetpgnotes

	Iodine Particle	Osmolarity	Examples
Ionic Monomers	3:2	High Osmolar (1400-1600 mOsm)	• Diatrizoate (Gastrografin, Urografin) • Metrizoate • Iothalamate
Ionic Dimers	6:2 3:1	Low osmolar (600 – 800 mOsm)	• Ioxaglate
Non-Ionic Monomers	3:1	Low osmolar (600 – 800 mOsm)	• Iohexol (Omnipaque) • Iopamidol • Ioversol
Non-Ionic Dimers	6:1	Iso Osmolar (290-300 mOsm)	• Iodixanol (Visipaque) • Iotrolan

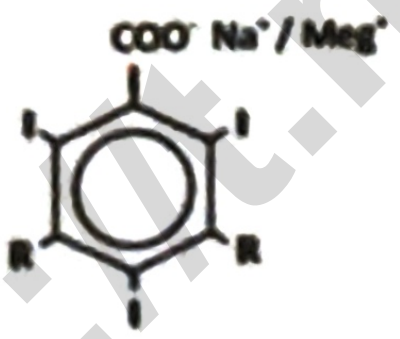

Ionic Monomer
3 Iodine atoms : 2 Particles, Ratio: 1.5

Non-Ionic Monomer
3 Iodine atoms : 1 Particles, Ratio: 3.0

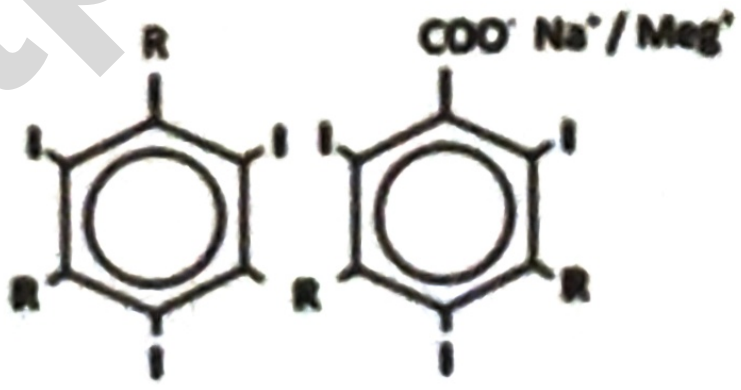

Ionic Dimer
6 Iodine atoms : 2 Particles, Ratio: 3.0

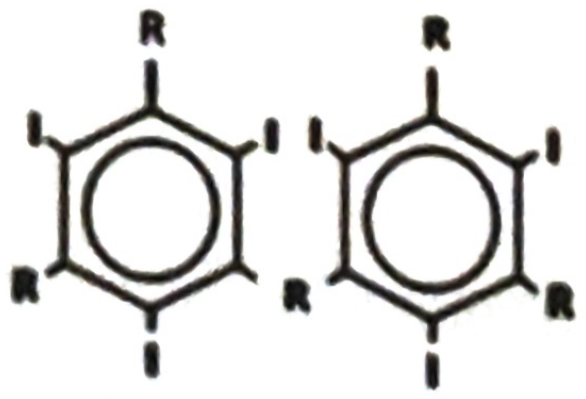

Non-Ionic dimer
6 Iodine atoms : 1 Particles, Ratio: 6.0

https://t.me/Latestneetpgnotes

PrepLadder

Water soluble iodinated compounds				
Biliary Excretion	Renal Excretion			
• Iopanoic acid(Tele paque) • Calcium ipodate	High Osmolar	Low Osmolar	Low Osmolar	Iso osmolar
	• Ionic Monomers	• Ionic Dimers	• Non-ionic Monomers	• Non-Ionic Dimers
	• I/P ratio- 3:2 • 1400-1600 mOsm	• I/P ratio - 3:1	• I/P ratio - 3:1	• I/P ratio - 6:1 • 290-300 mOsm
	• Diatrizoate (Gastrografin, Urografin) • Metrizoate • Iothalamate (Conray)	• Ioxaglate	• Iohexol (Omnipaque) • Iopamidol • Ioversol	• Iodixanol (Visipaque) • Iotrolan (Isovisit)

CIN (Contrast induced Nephropathy) 00:27:07

→ Definition

- Impairment of renal function within 48-72 hour of intravenous contrast administration. Measured as either
  - 25% increase in serum creatinine from baseline (or)
  - 0.5 mg/dl in absolute serum creatinine value

→ Markers of CIN

- Serum cystatin C Levels
- Neutrophil Gelatinase associated Lipocalcin (NAGL)
- eGFR <60ml/min

https://t.me/Latestneetpgnotes

Risk Factor for Contrast Medium – Induced Nephropathy

Patient-Related	→ eGFR <60 mL/min/1.73m^2 before intra-arterial administration → eGFR <45 ml/min/1.73m^2 before intravenous administration → In particular in combination with • Diabetic nephropathy • Dehydration • Congestive heart failure (NYHA grade 3-4) and low LVEF • Recent myocardial Infraction [<24h] • Intra-aortic balloon pump • Peri-procedural hypotension • Low hematocrit level • Age Over 70 • Concurrent administration of nephrotoxic drugs → Known or suspected acute renal failure
Procedure related	→ Intra-arterial administration of contrast medium → High-Osmolality agents → Large doses of contrast medium → Multiple contrast medium administration within a few day

Severity Classification for contrast – Induced Anaphylactoid Reactions		
Minor	Moderate	Severe
• Urticaria (limited)	• Urticaria (diffuse)	• Cardiovascular shock
• Pruritus	• Angioedema	• Respiratory arrest
• Erythema	• Laryngeal edema	• Cardiac Arrest
	• Bronchospasm	

https://t.me/Latestreetpgnotes

PrepLadder

Note:

→ Single best step in prevention of CIN – Maintain Hydration

→ Iodinated contrast agents should not be given to Pregnant female (Crosses Blood Placental Barrier)

→ Can be given to Breastfeeding mother

Gastrografin

00:37:08

→ It is a Salt of Diatrizoate
- Ionic monomer
- High osmolality

→ Avoid Gastrografin in TEF - because of risk of pulmonary edema

→ Can be used in perforation peritonitis / hollow Viscus perforation

→ Therapeutic enema for constipation / meconium Ileus

Iohexol

→ Aka Omnipaque
- Non-Ionic Monomer
- Low Osmolar/ Water Soluble iodinated Contrast

→ Preferred Contrast In
- Hollow Viscera Perforation
- Esophageal perforation

→ TEF (Dianosil – used for TEF & Bronchography)

USG Contrast Agents

00:41:40

→ Microbubbles of Air, Gases, SF6, Perfluorocarbons

→ Air – Hyperechoic

→ No Need for Baseline Renal Function tests before USG Contrast

Contrast Enhanced EUS (CE EUS)

- Microbubbles have a high degree of echogenicity. The echogenicity difference between the gas in the microbubbles and the soft tissue surroundings of the body is immense. Thus the microbubble contrast agents enhances the reflection of the ultrasound waves, to produce a unique sonogram with increased contrast due to the high echogenicity difference.

https://t.me/Latestneetpgnotes

PrepLadder

→ Ultrasound contrast agents – encapsulated Microbubbles

→ Important USG Contrast agents

- Sonavist, Levovist, Optison
- Sonagen/ echogen
- Sonavue – SF6
- Sona Rx – Oral

} I.V

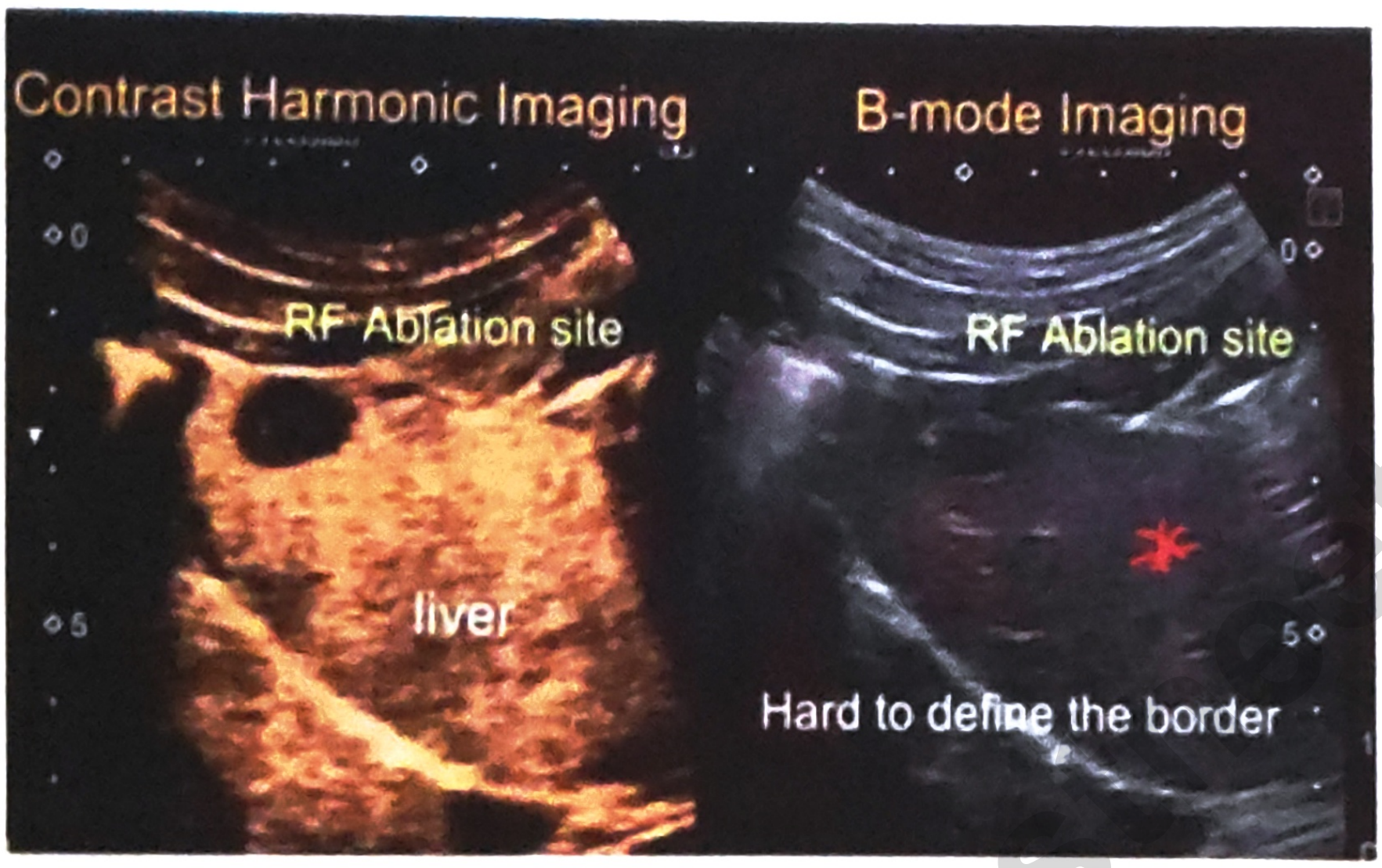

MRI contrast agents

00:46:20

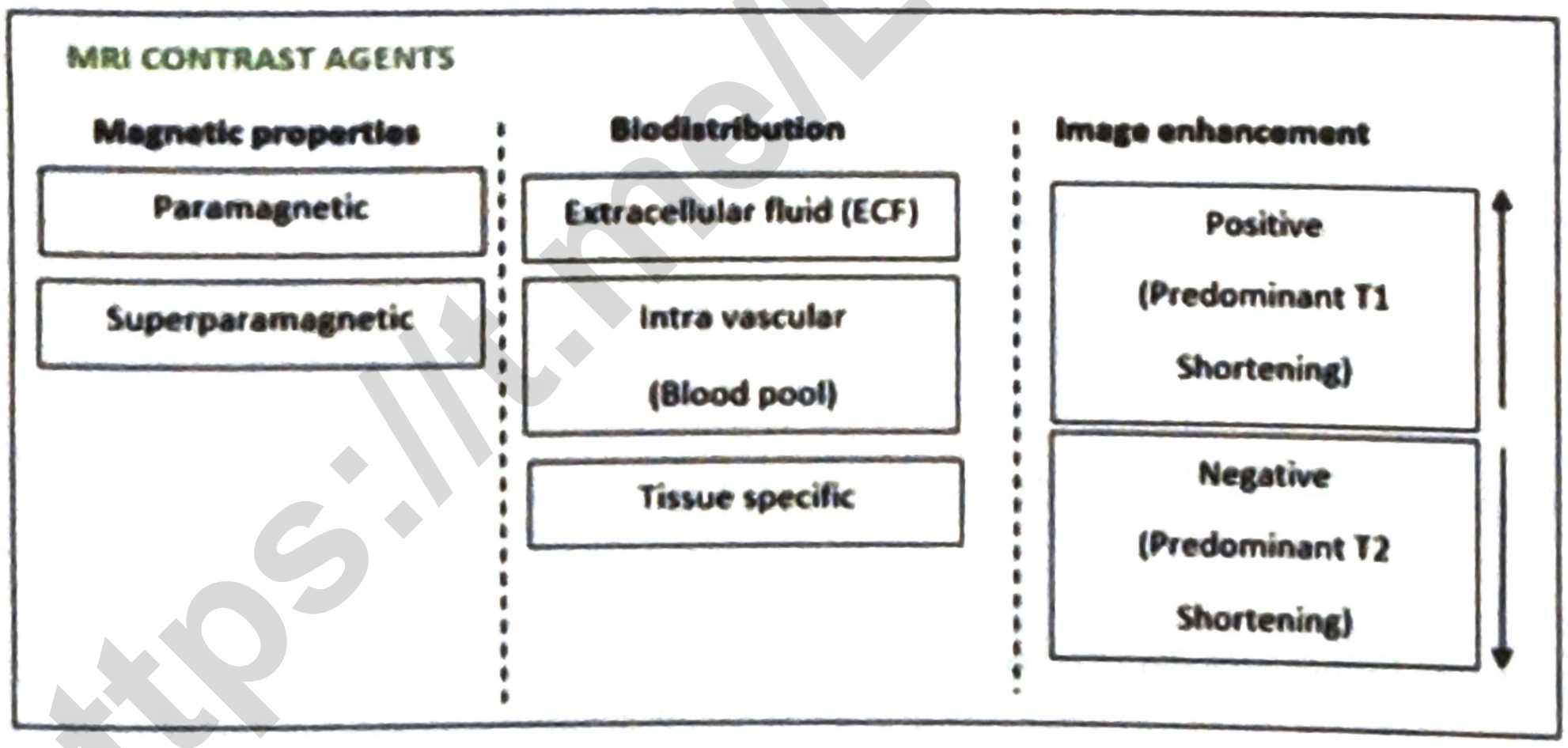

Paramagnetic	Superparamagnetic
• Gadolinium • Manganese	• SPIO (Super paramagnetic Iron Oxide)

https://t.me/Latestpgnotes

PrepLadder

Gadolinium

→Atomic number - 64

→Paramagnetic Compounds

→Shortens both T1 & T2 relaxation (Predominant effect on T1)

→Toxic– hence, coupled with DTPA

→Crosses Placental barrier- avoid CE-MRI in pregnancy

→Doesn't cross Blood brain barrier

MRI Contrast agents	
Positive Relaxation Agents	Negative Relaxation Agents
• Predominantly Affect T1 Relaxation	• Predominantly Affects T2 Relaxation
• Predominant T1 shortening	• Predominant T2 Shortening
• Increased Signal	• Decreased Signal
• Gadolinium	• Iron oxide (SPIO)

Classification of MRI Contrast Agents	
1) Intravascular, Extracellular space	• Gadolinium – DTPA
2) RES specific agents	• Ferrumoxide (SPIO)
3) Hepatocyte Selective Agents	• GD-BOPTA (Gadobenate Dimeglumine) • Gd-EOB-DTPA (Gadoxetate) • Mangafodipir Trisodium

https://t.me/Latestneetpgnotes

Prep

Gadolinium-Based Contrast Media

→ Nephrogenic Systemic Fibrosis

- A diagnosis of nephrogenic systemic fibrosis (NSF) should only be made if the Yale NSF Registry clinical and histopathology criteria are met. The link between NSF and gadolinium-based contrast agents was recognized in 2006.

→ Clinical features of NSF

- Onset: From the day of exposure for up to 2-3 months, sometimes up to years after exposure
- Initially
  - Pain
  - Pruritus
  - Swelling
  - Erythema
  - Usually starts in the leg
- Later
  - Thickened skin and subcutaneous tissues-'woody' texture and browny plaque
  - Fibrosis of internal organs, e.g. muscle, diaphragm, heart, liver, lungs
- Result
  - Contractures
  - Cachexia
  - Death in a proportion of patients

Patients	
→ At higher risk	• Patients with CKD 4 and 5 (GFR <30 mL/min) • Patients on dialysis • Patients with acute kidney insufficiency
→ At lower risk	• Patients with CKD 3 (GFR 30-59 mL/min)
→ Not at risk of NSF	• Patients with stable GFR>60 mL/min

https://t.me/Latestneetpgnotes

PrepLadder

Nephrogenic System fibrosis	
Intermediate Risk of NSF	Low Risk of NSF
• Gadobenate Dimeglumine • Gadofosveset trisodium • Gadoxetate disodium	• Gadobutrol • Gadoterate Meglumine • Gadoteridol

ACR CATEGORY	GENERIC NAME	BRAND NAME (US)
GROUP 1 Agents associated with greatest number of NSF cases	• Gadodiamide • Gadoversetamide • Gadopentetate-Dimeglumine	• Omniscan™ • OptiMARK™ • Magnevist
Group 2 Agents associated with Few-if any-unconfounded NSF cases	• Gadoteridol • Gadobutrol • Gadobenate Dimeglumine	• ProHance • Gadovist • MultiHance
Group 3 Agents that have only recently appeared on the US market	• Gadoxetic acid disodium salt • Gadofosveset trisodium	• Eovist • Ablavar

https://t.me/Latestneetpgnotes

PrepLadder

Chapter 37

WOMEN IMAGING

Note:

→IOC for routine screening of breast ca
- Mammography (>40 yrs)

→Screening ix for high risk-
- (+) family Hx
- BRCA (+) - Mammography + MRI
- P53 (+)

→Ix to evaluate a lump in a young female - USG

→Ix for differentiating lump in lactating mothers - USG

→Ix for differentiating scar Vs residual/recurrence of Ca
- MRI

→IOC in Breast / silicone implant - MRI

BIRADS: (Breast imaging reporting & data system) 00:03:55

→System used for reporting breast lesions

→Can be done USG/MRI/mammography

Grade	Findings	Advice
0	Incomplete evaluation	Should be completed
1	Normal	Routine Mammography
2	Benign (e.g. Fibroadenoma)	Routine Mammography
3	Probably benign (> 2 % chances)	Short term follow up
4	Probably malignant (2-95% chances)	Biopsy
5	Malignant > 95%	Biopsy
6	Biopsy proven malignancy	Definitive Mgt.

https://t.me/Latestneetpgnotes

Dynamic contrast enhanced MRI

00:11:40

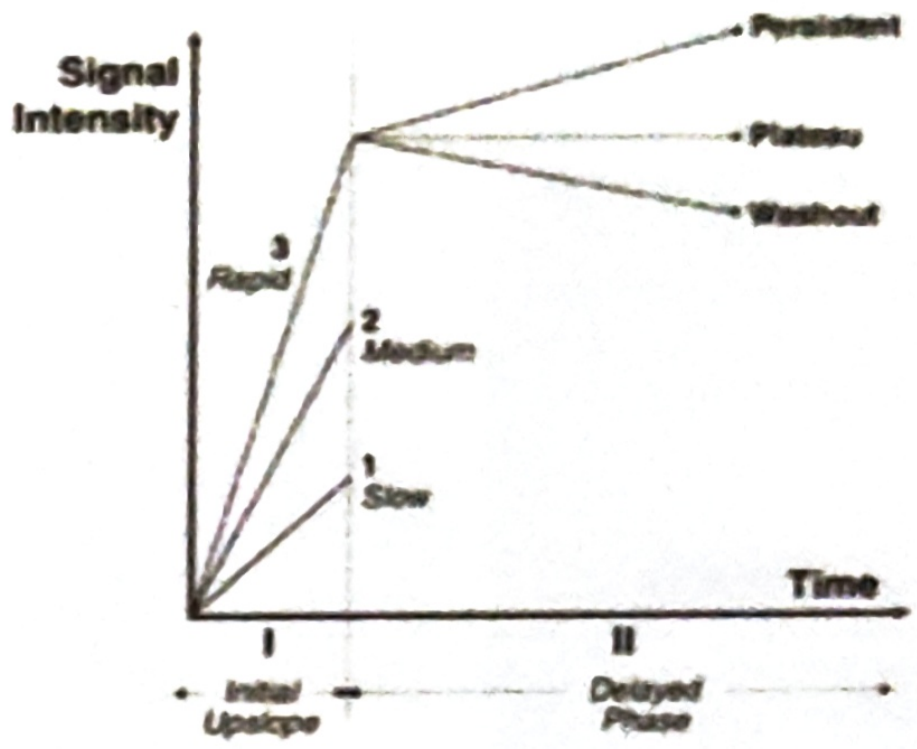

Types

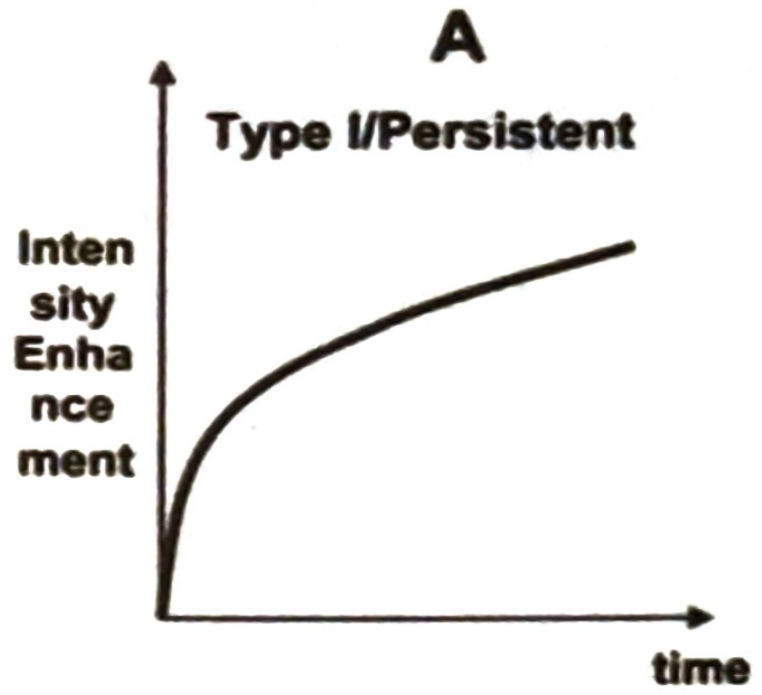

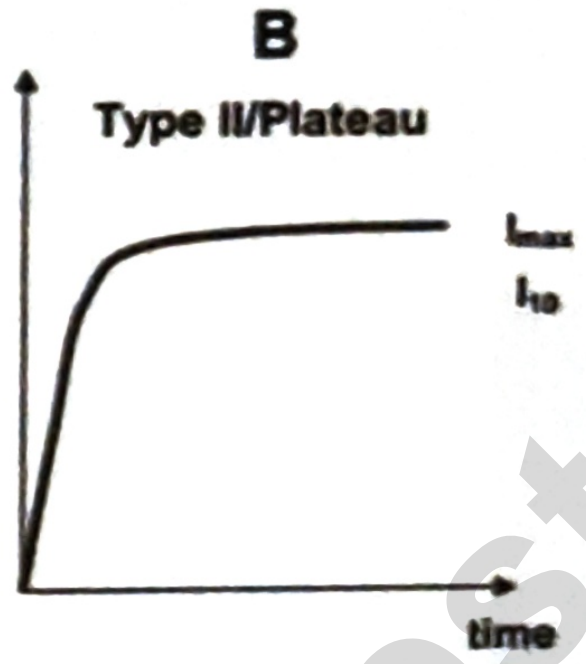

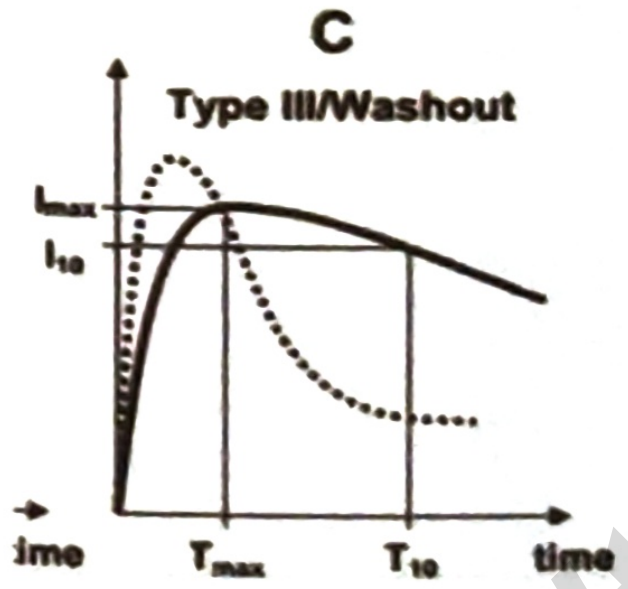

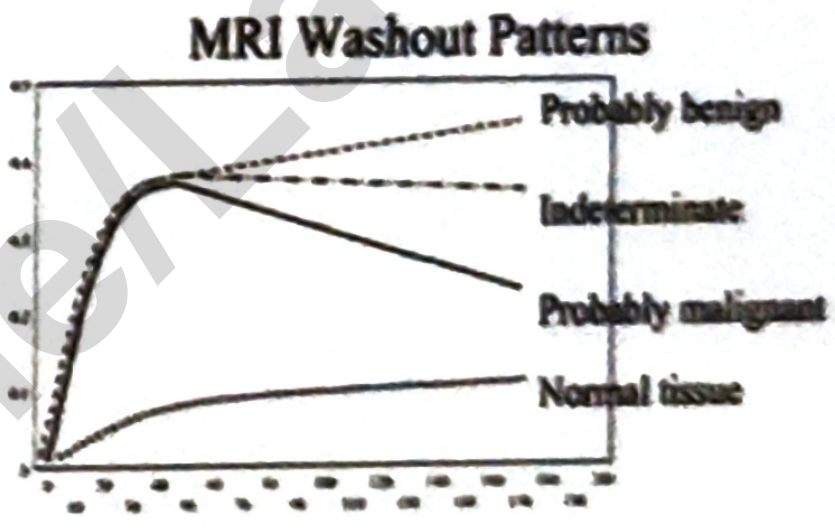

Note:

→ Absent of breast shadow on one side may indicate

- Post mastectomy patient (or)
- Poland syndrome

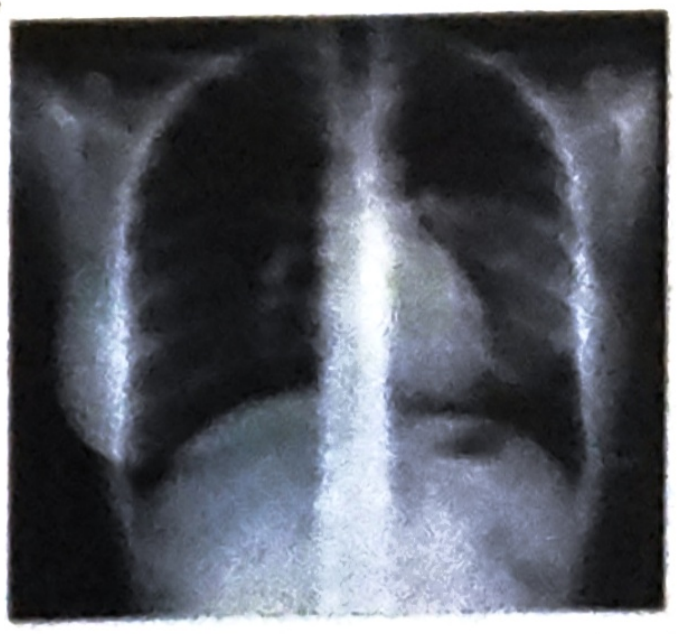

Post mastectomy chest X-ray

https://t.me/latestneetpgnotes

PrepLadder

Intracapsular breast implant rupture

Linguine sign will be present in MRI	Stepladder sign will be present in USG
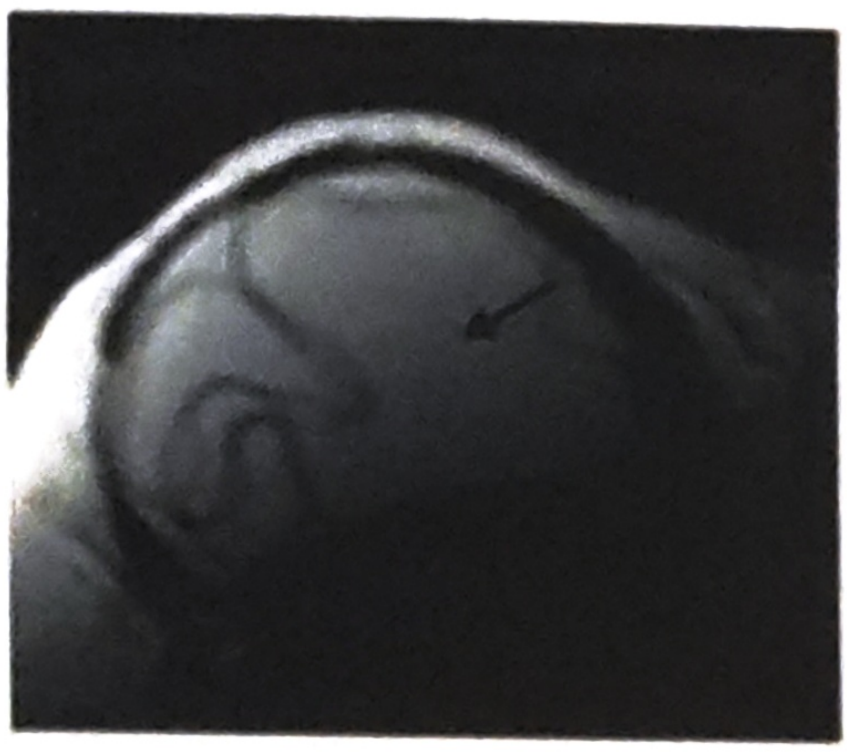	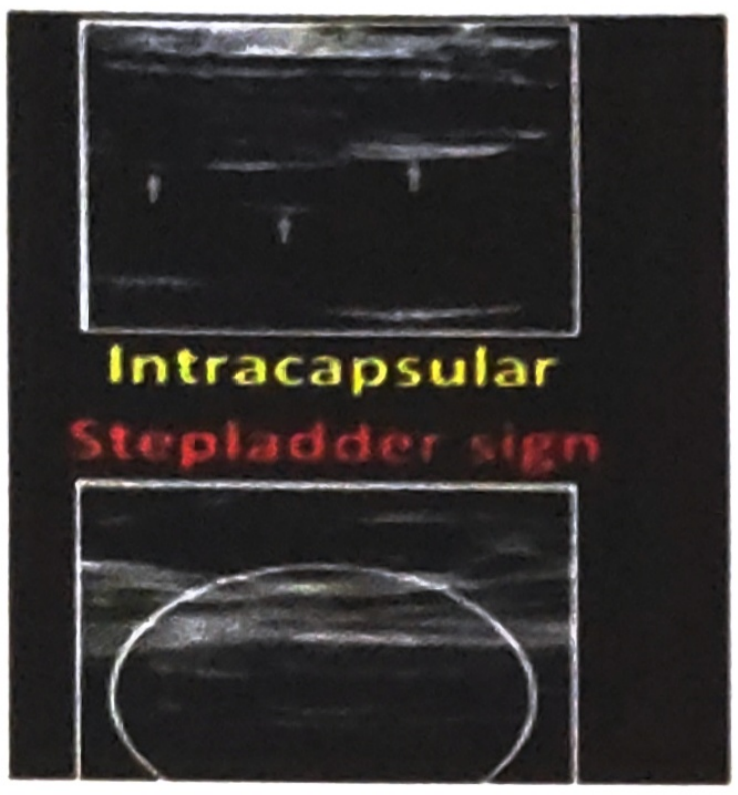

Extracapsular breast implant rupture

→Snowstorm appearance is seen in USG

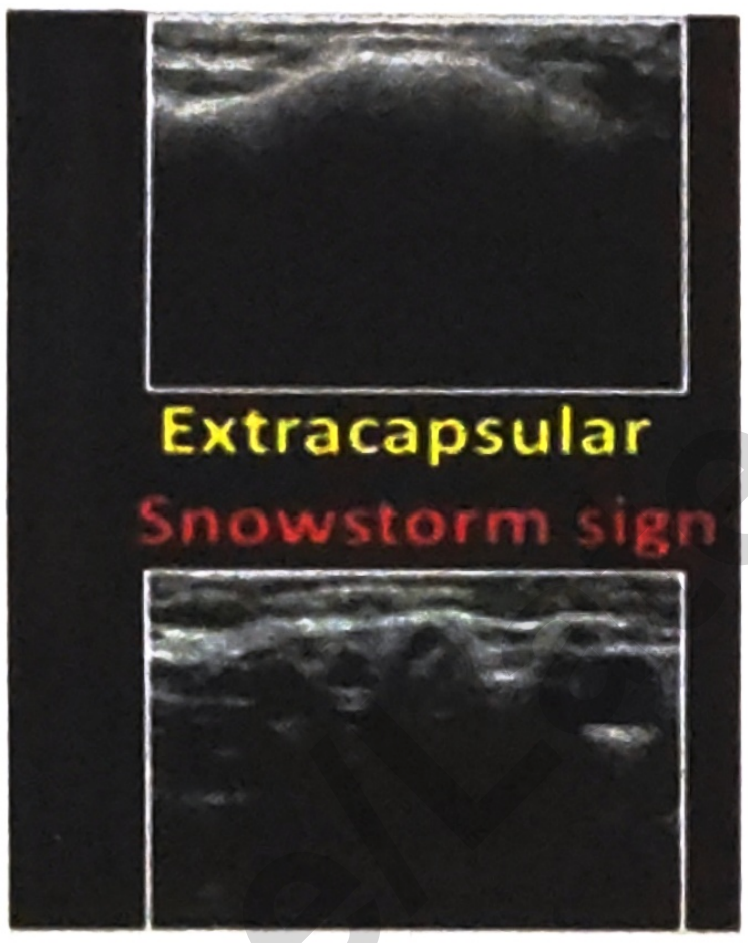

Hysterosalpingography

00:19:08

→Best time to do is 6th – 10th day of menstrual cycle (to avoid damage to undiagnosed pregnancy)

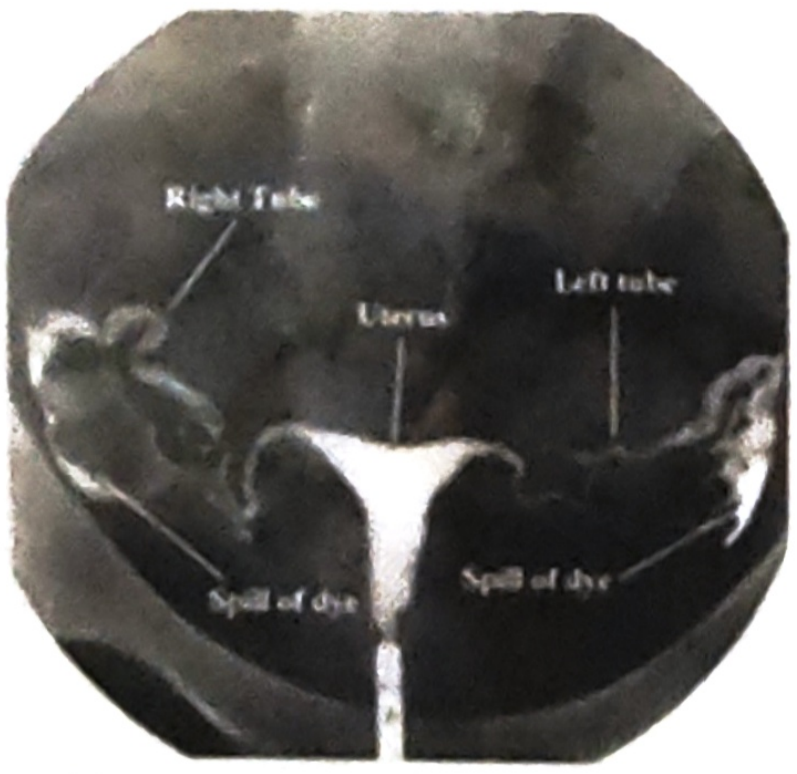

Hysterosalpingography

https://t.me/bestneetpgnotes

PrepLadder

Uterine anomalies

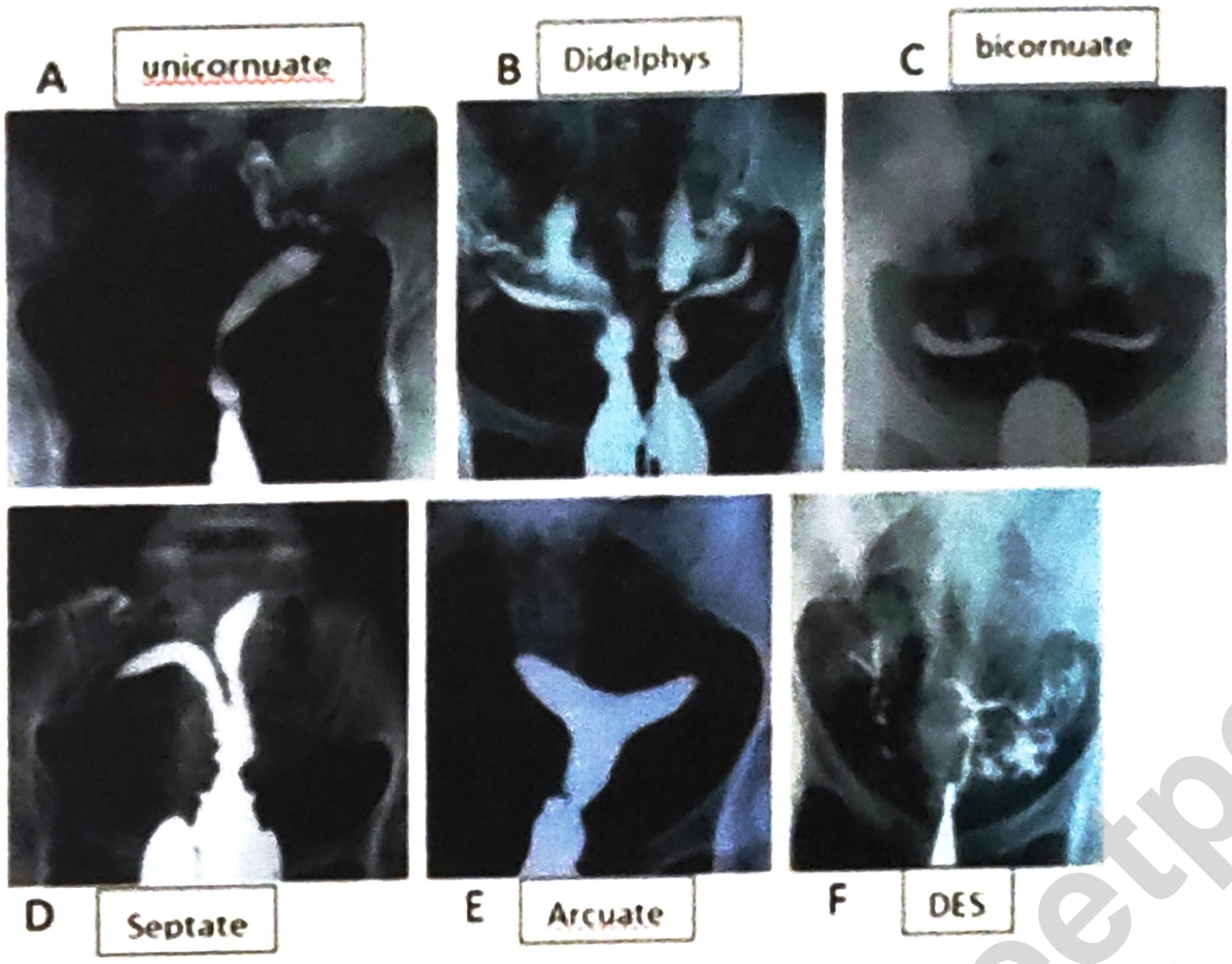

Genital TB

00:22:22

→ Gives beaded appearance of fallopian tube

Hydrosalpinx

→ Shows bilaterally distended fallopian tube

Bilateral Hydrosalpinx

Rectosigmoid endometriosis

00:23:05

→ Proliferation of rectal muscle around the endometrial growth gives – Mushroom Cap sign

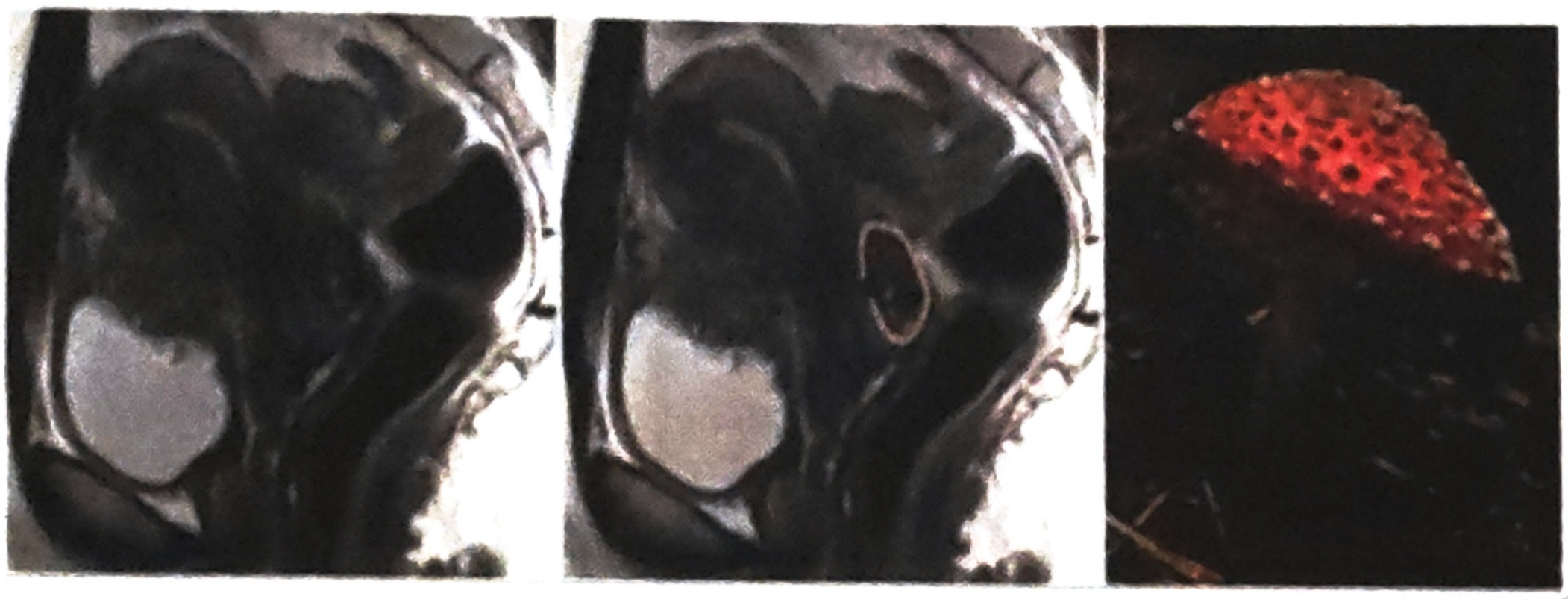

Rectosigmoid endometriosis

Rectosigmoid endometriosis

https://t.me/Latestneetpgnotes

PrepLadder

Chapter 38

Dental Radiology

Tooth Anatomy

00:00:15

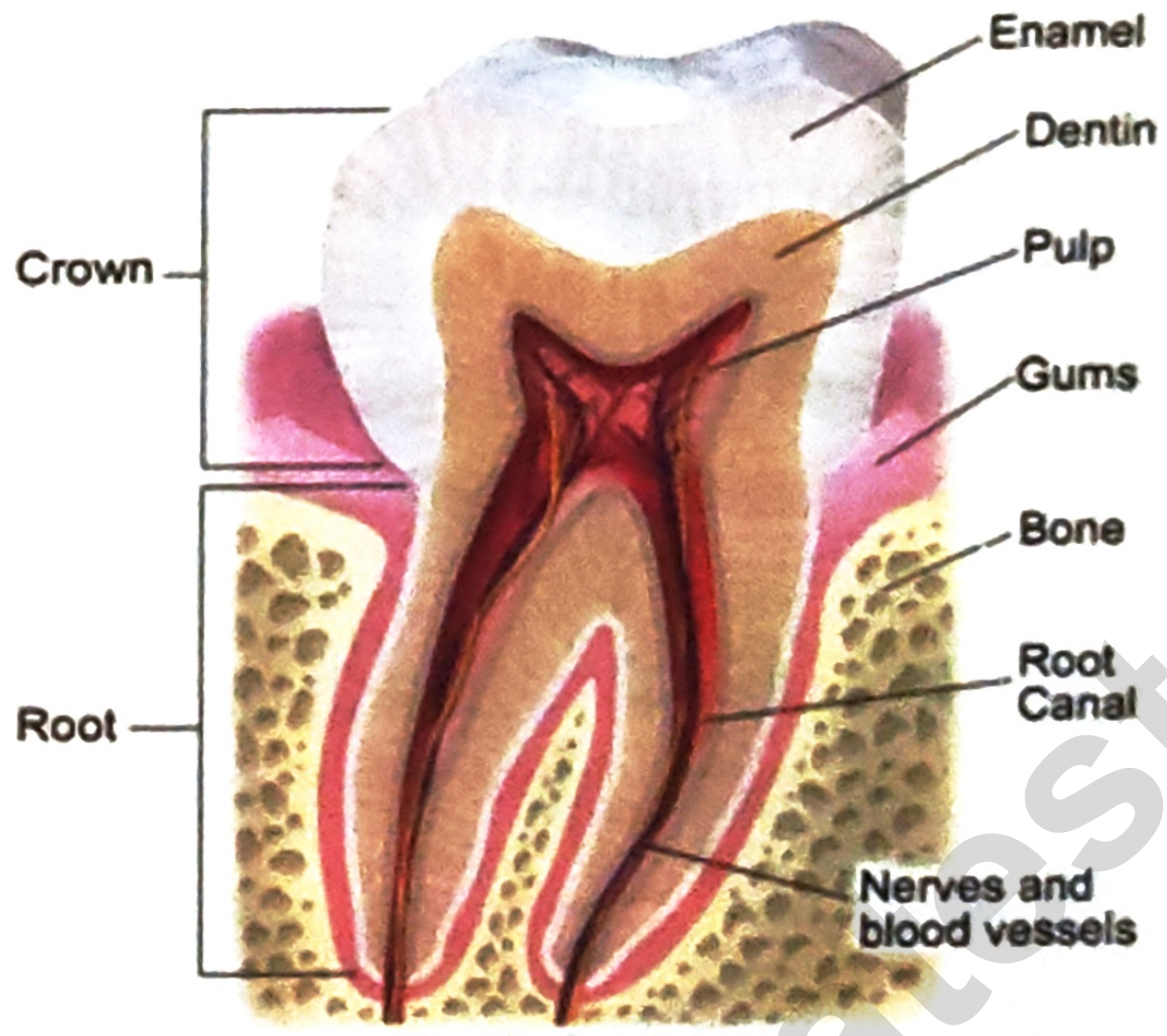

Tooth Anatomy

On Evaluation of the teeth, we have variant radiographs

→Intra Oral radiographs

→Extra Oral radiographs

→Orthopantomography

Intra Oral Radiographs

00:00:50

→These have a very good depiction of the tooth with its Peri apical region.

→It has a small film size, so it is not useful to evaluate a very large Lesions.

→But they give very good detail about few teeth with good clarity (2-4 teeth)

https://t.me/Latestneetpgnotes

PrepLadder

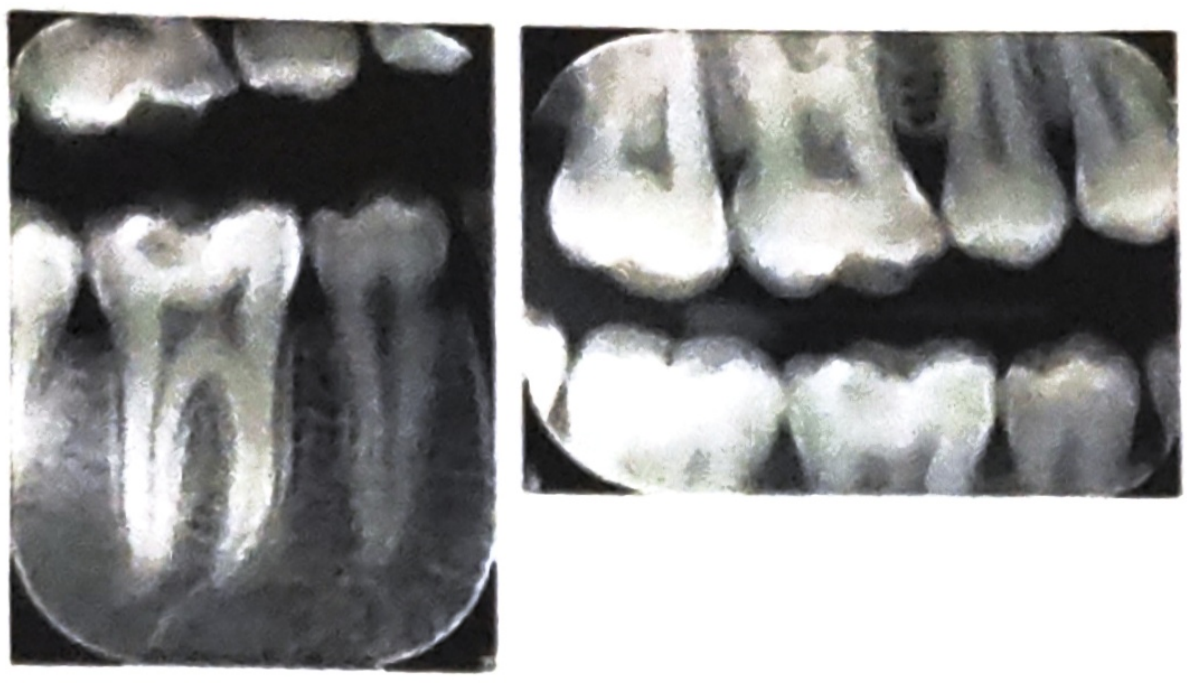

Intra oral radiographs

Extra Oral Radiographs 00:01:42

- →Used to evaluate larger Lesion
- →Can take lateral radiograph, frontal radiograph to evaluate lesion in the maxilla, mandible and the skull region.
- →There is a good amount of superimposition of the skull base with the maxilla, so we generally prefer water's view to see the lesions better.

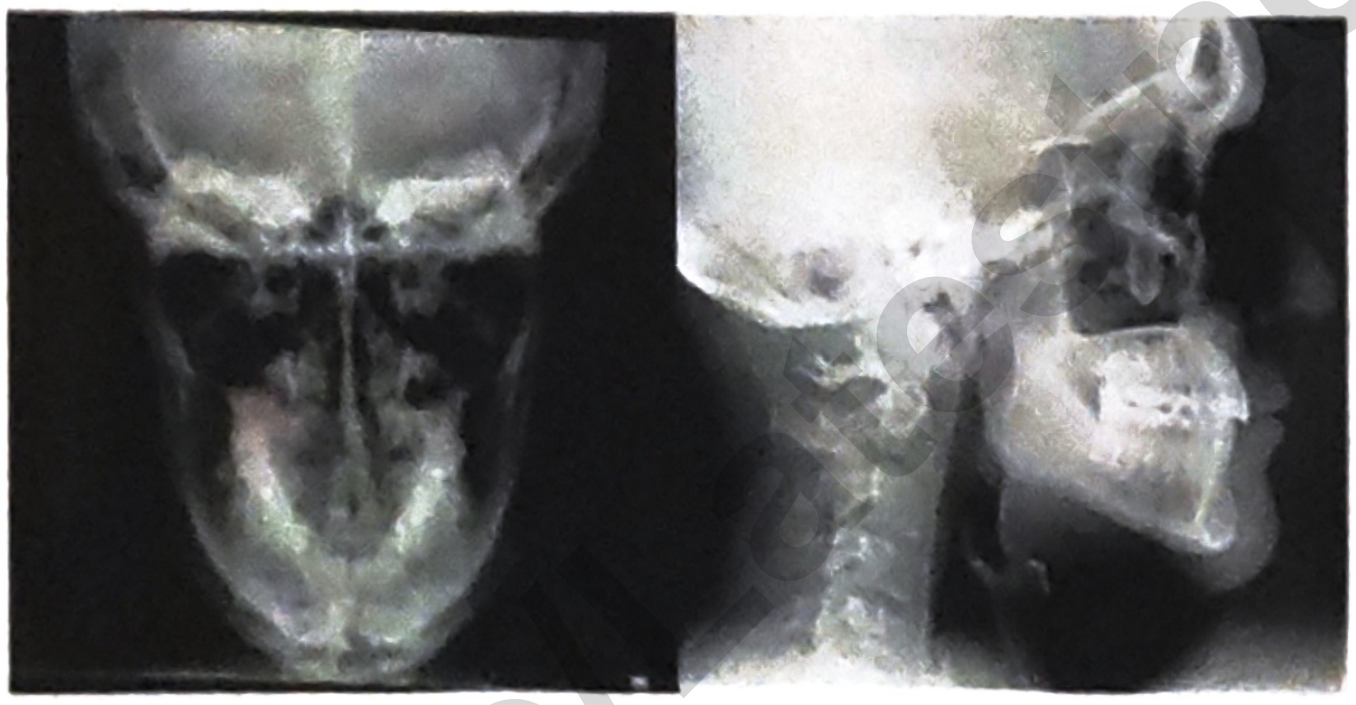

Extraoral radiographs

Orthopantomography 00:02:10

- →It is the radiographic technique which evaluate both the upper and lower jaw in a single film.
- →It is a Sectional radiology, which evaluates a broad area by moving the equipment across.
- →It is associated with low radiation dose.
- →Clarity is not as good as intra Oral.

Orthopantomography

https://t.me/neetpgnotes

PrepL

Odontogenic cyst 00:02:55

→Arise from epithelial residues of tooth forming tissues, develop during or after Formation of teeth.

→This can be inflammatory Cyst:

- Radicular and residual Cyst

→And developmental:

- Dentigerous Cyst
- Odontogenic Keratocyst (OKC)

Radicular (Residual Cyst) 00:03:59

→Most Common Odontogenic Cyst

→Inflammatory Cyst, develops at the root apex of a caries teeth due to Proliferation of epithelial cell rests of Malassez.

→Develops at apex of Non-Vital teeth, mainly upper lateral incisors or 1st Molar.

→Extraction causes resolution, if it does not resolve then called residual Cyst. Aka Peri apical Cyst.

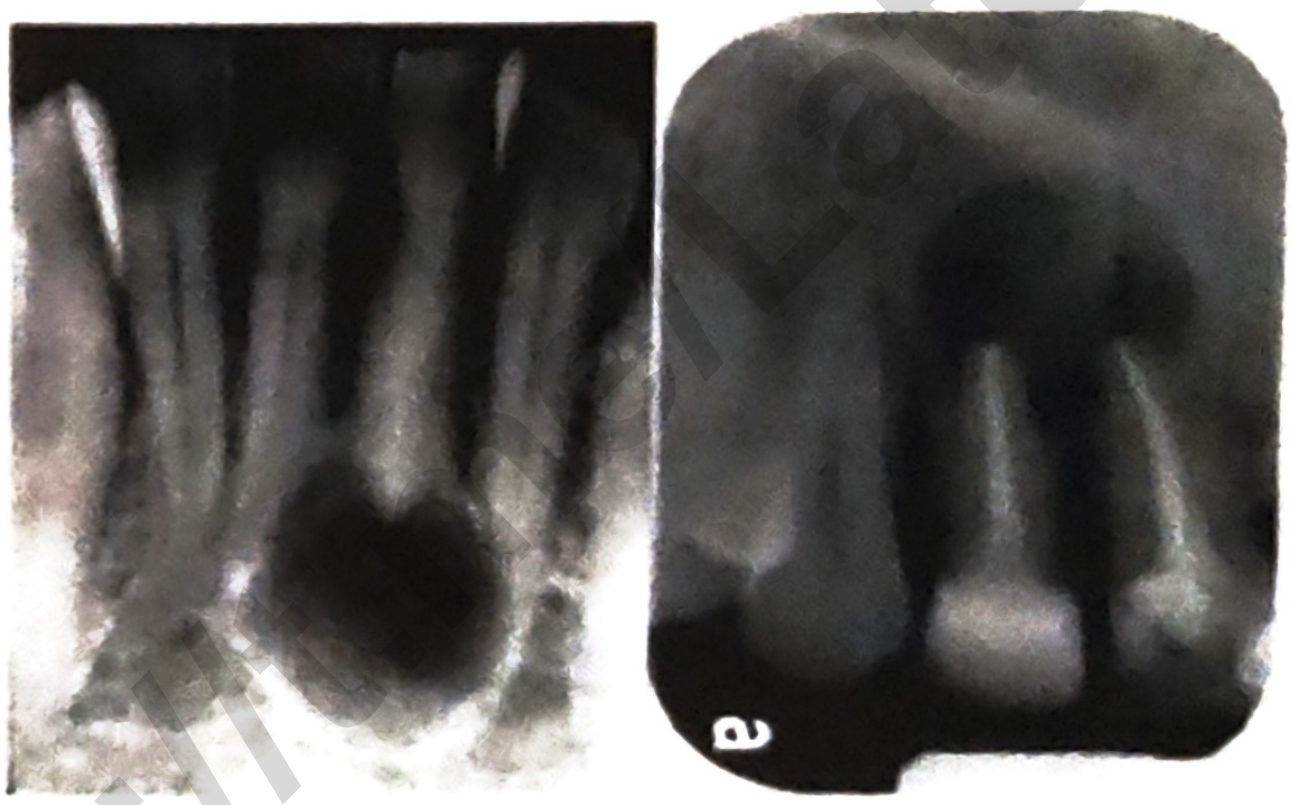

Radicular cyst

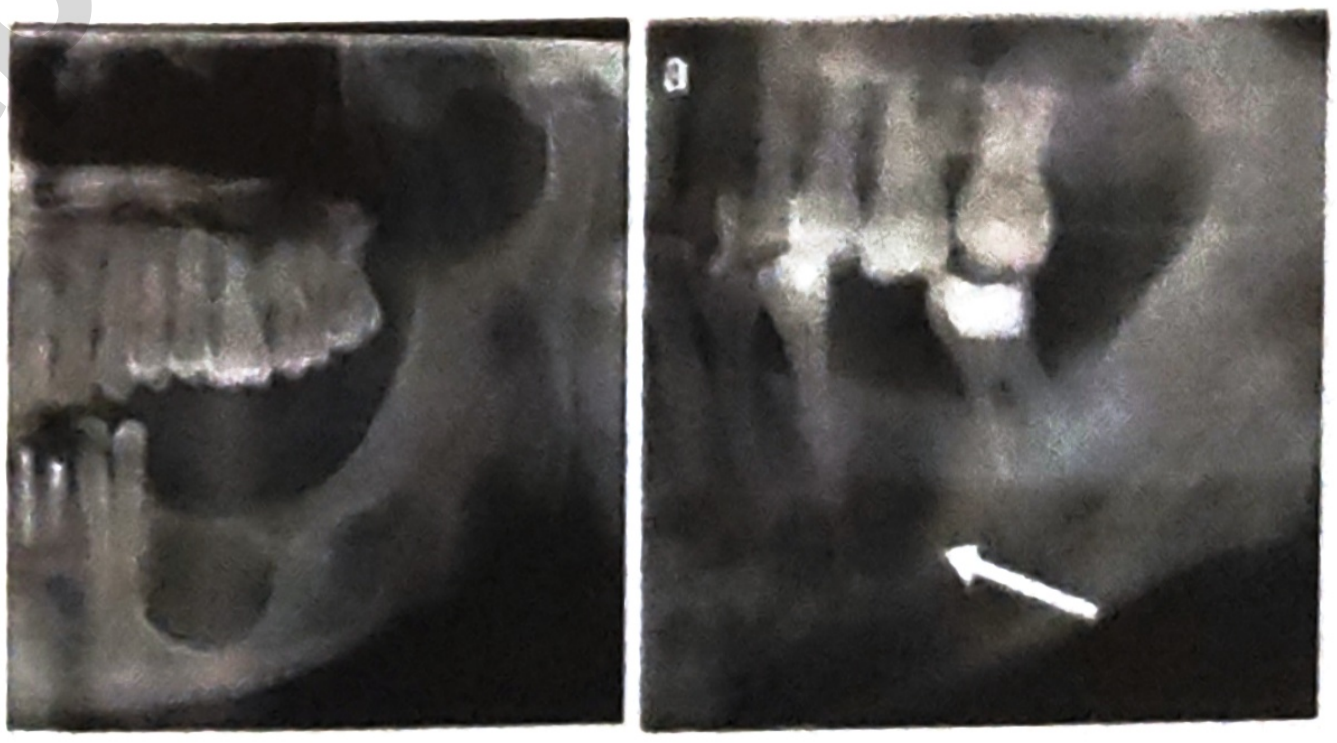

Residual cyst

https://t.me/latestneetpgnotes

PrepLadder

Dentigerous Cyst (Follicular Cyst) 00:06:25

→ Forms within the lining of dental follicle with fluid accumulation between enamel epithelium and Crown of a unerupted developing teeth.

→ M/C type of Non inflammatory Odontogenic Cyst.

→ Arises from reduced enamel epithelium surrounding the crown of an unerupted tooth.

→ Unilocular radiolucency with impacted tooth with Pericoronal radiolucency, attached to the tooth at its neck with crown appearing to lie within the cyst.

→ 75% located in mandible, usually 3rd molar.

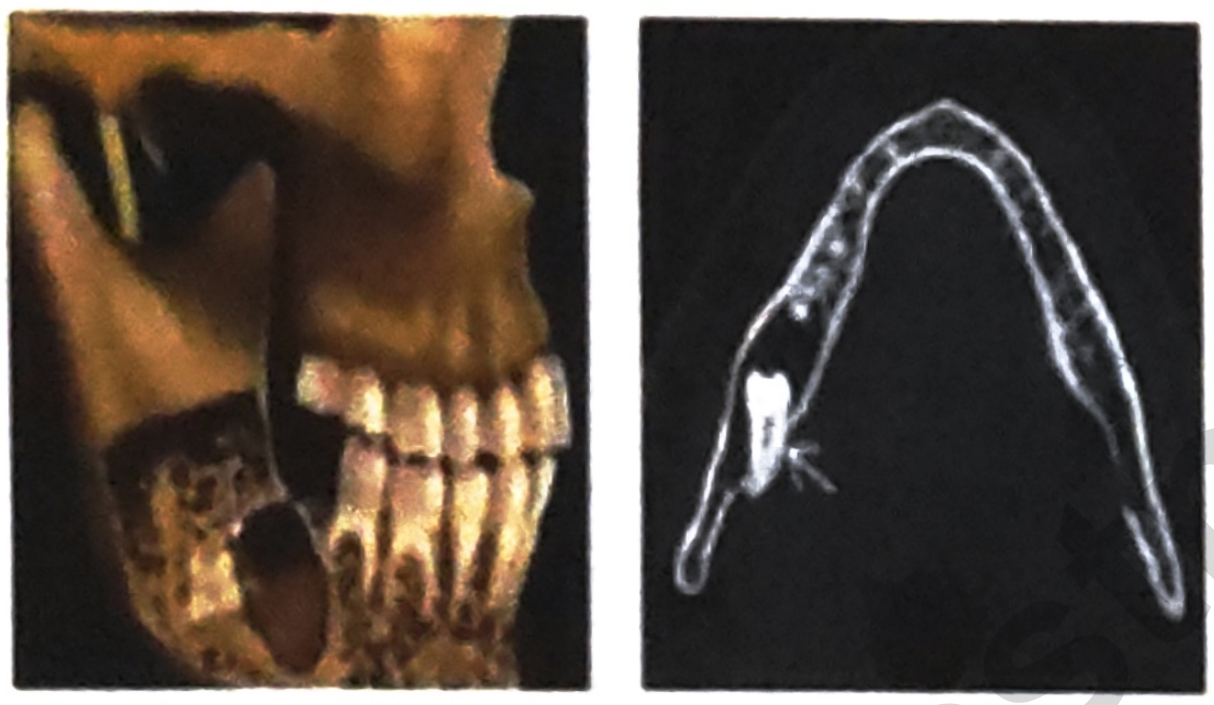

Dentigerous cyst (follicular cyst)

Odontogenic Keratocyst (OKC) 00:08:21

→ Development jaw cyst with aggressive behaviour and high recurrence rate.

→ Arises from epithelial remnant of dental lamina.

→ Usually Unilocular lucent lesion mostly at the Posterior body and ramus of mandible, extending along the mandible length with scalloped well-defined margins.

→ Cyst not associated with tooth Crown Or unerupted tooth.

→ Multilocular OKC may resemble ameloblastoma

→ Contain cheery material within and shows diffusion restriction on MRI.

→ Preferred treatment is surgical enucleation. Curettage has high recurrence.

https://t.me/Latestneetpgnotes

PrepLadder

Odontogenic Keratocyst

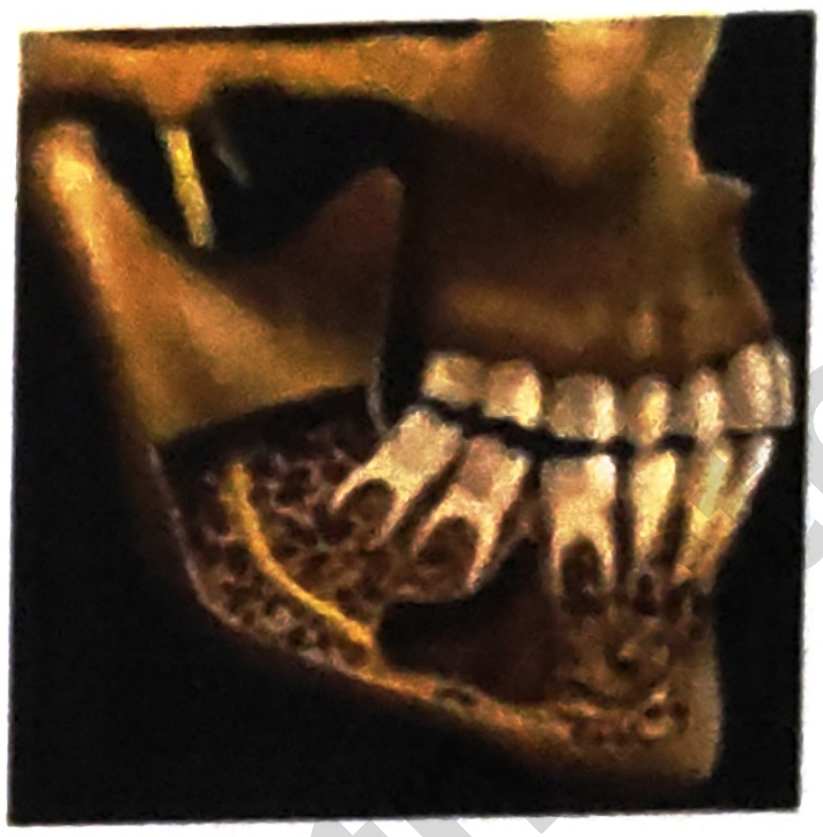

Odontogenic Keratocyst

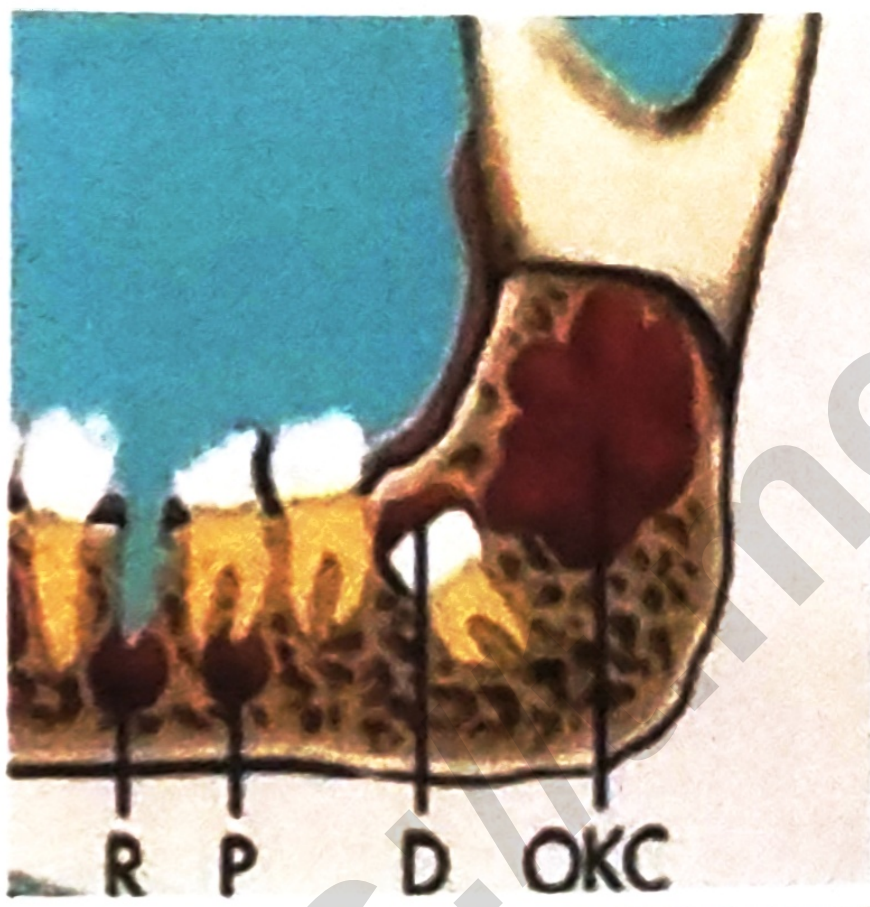	R – Residual cyst P – Periapical cyst D – Dentigerous cyst OKC – Odontogenic keratocyst

Ameloblastoma

00:12:37

→ Locally invasive benign neoplasm arising from Odontogenic epithelium.

→ Bubbly multilocular mixed cystic solid mass in Posterior body or ramus of mandible.

→ Multilocular radiolucency containing septa and locules of variable size giving honey comb, Soap bubbly appearance.

→ Jaw expansion and resorption of adjacent tooth roots.

https://t.me/Latestpgnotes

PrepL

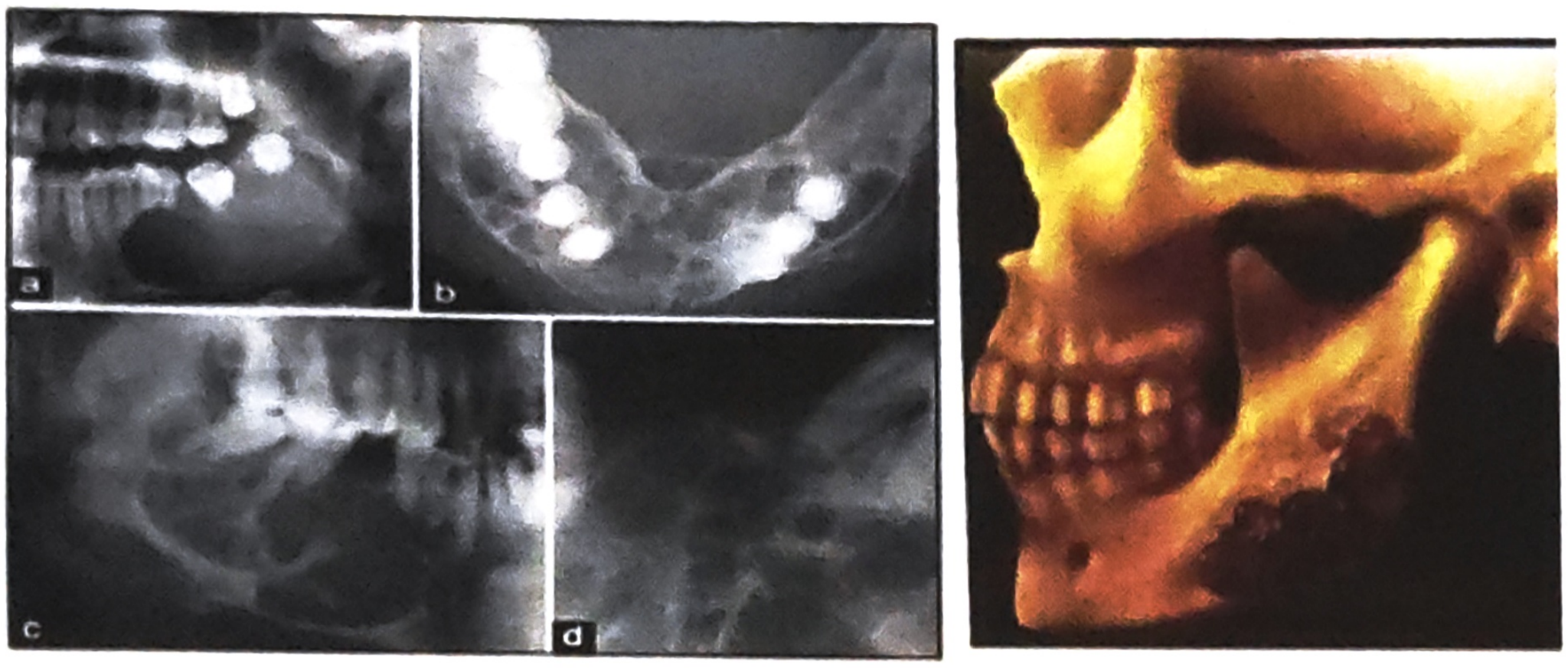

Ameloblastoma

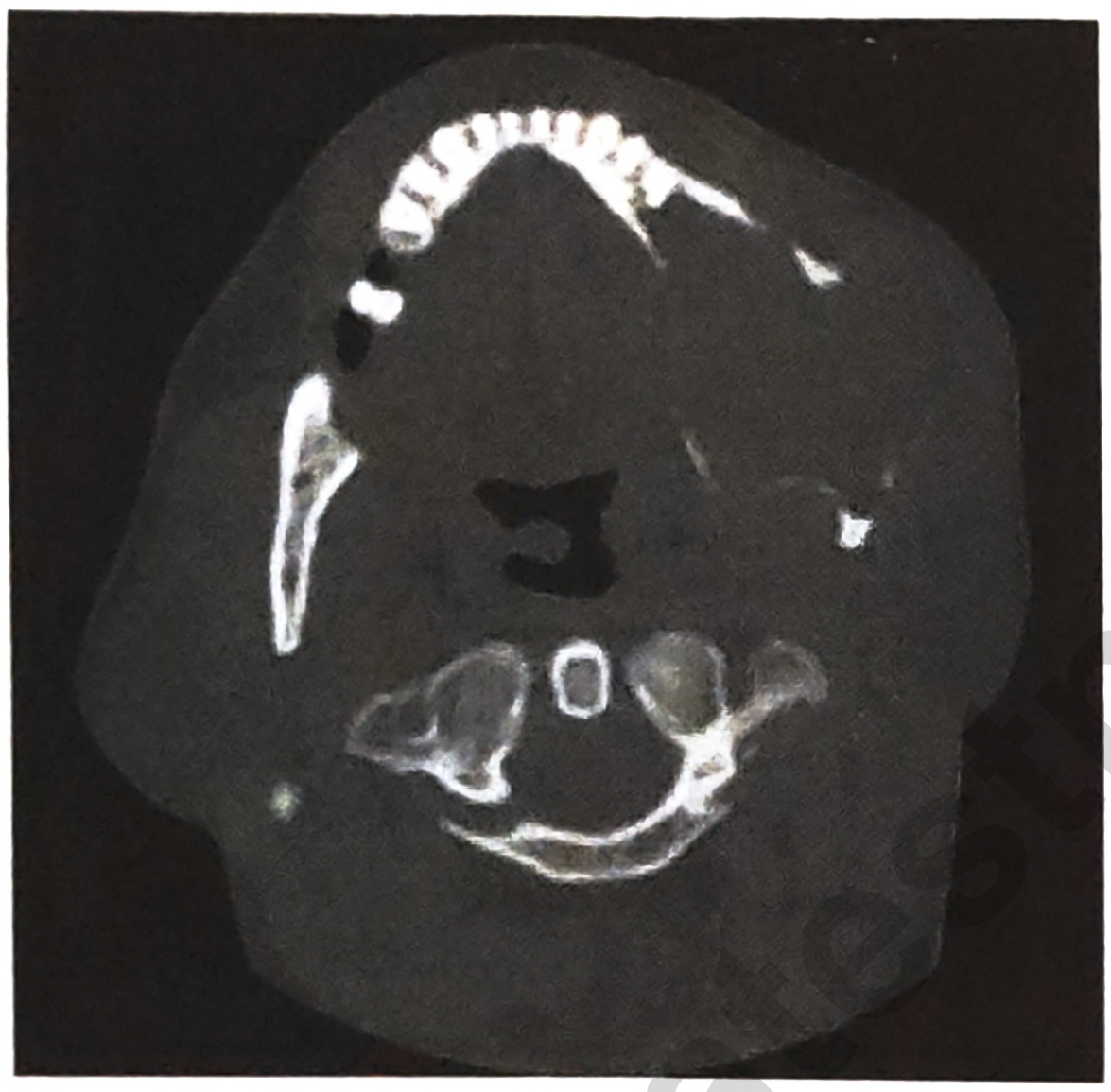

Thinning of cortex expansion – ameloblastoma (CT scan)

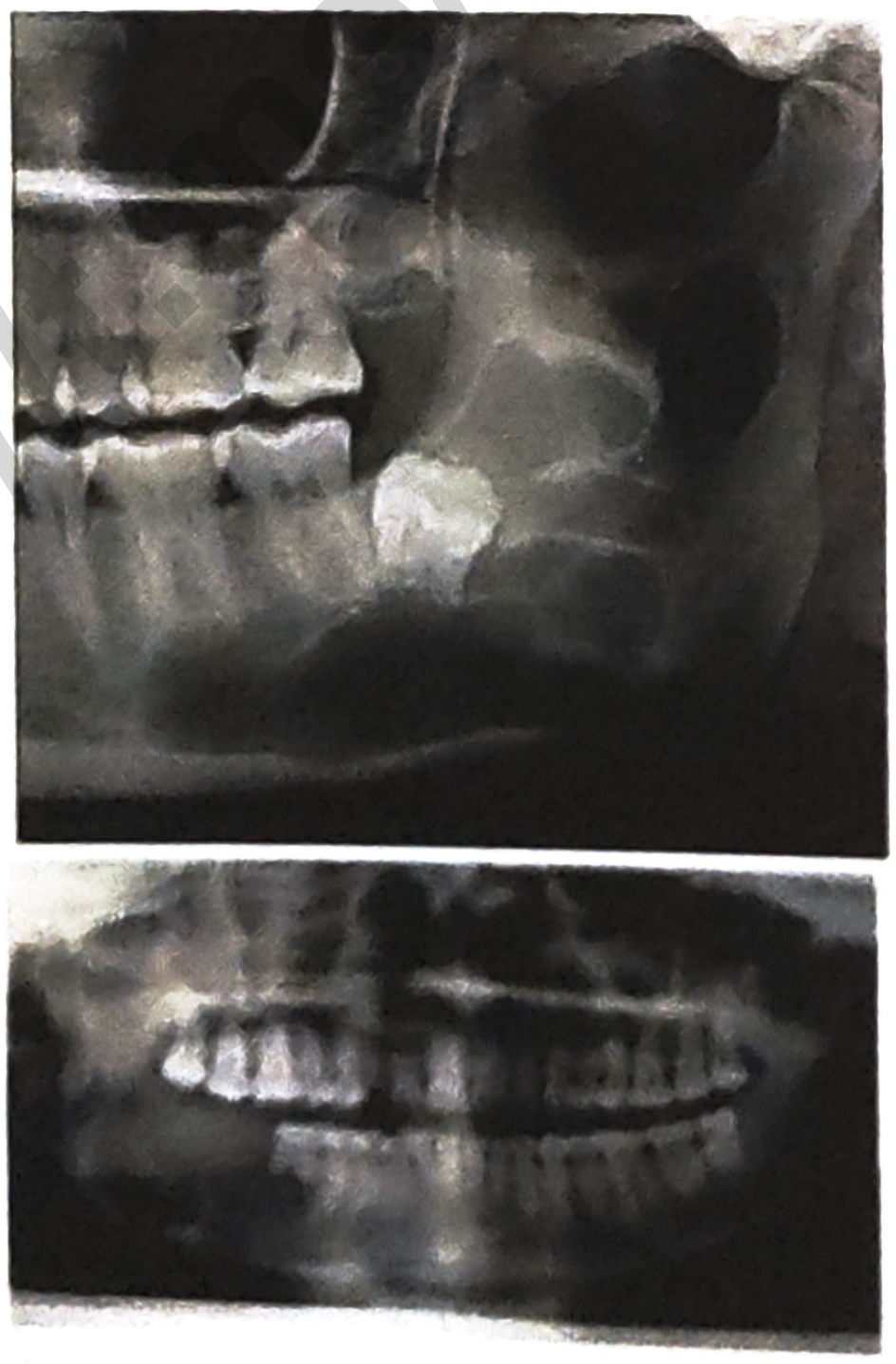

Soap bubble/ honey comb appearance – ameloblastoma

https://t.me/Latestneetpgnotes

OWN YOUR DREAM

Hello. I am Ashish Bhilange. I am currently studying at Government Medical College, Dhule, Maharashtra. I come from an average middle-class family and my beginnings are rather humble. Throughout school, I was an average student. However, I had always dreamt of becoming a doctor. This is the dream that kept me going all through my childhood.

Fuelled by my dreams and passion, I studied very hard during my NEET UG preparation days. However, my result was not that great. It was rather disappointing. In the first counselling, I could not get MBBS, I was offered a seat in BDS instead.

This wasn't the result that I wanted. I considered myself a failure and it hit me hard. I was completely heartbroken. I felt depressed and even suicidal thoughts crossed my mind. However, the support and encouragement of my family kept me going. In the following counselling, things changed. By the grace of god and with the blessings of my family, I got admission in a Government MBBS College. It was like a new lease of life for me. I felt re-energized once again.

I joined college and started studying hard. Even though the initial years were tough, I kept positive. My preparation and efforts weren't yielding the result I was expecting but I persevered.

During the second prof. I enrolled for PrepLadder. It helped me a ton. I started studying with renewed determination. I finally managed to secure 2nd rank in my college during the university exams, with distinction in subjects of Pharmacology and Forensic Medicine. My efforts have started bearing fruit.

Now, I am preparing for PG entrance with the support of PrepLadder app and I am sure I'll make it. So, never give up on your dreams. Stay positive and don't let negative thoughts bring you down. Let my experience teach you that dreams do come true, if you have faith.

https://t.me/Latestneetpgnotes

Ashish Bhilange

Government Medical College,
Dhule, Maharashtra

“

There is only one thing that makes it impossible to achieve a dream: the fear of failure.

- Paulo Coelho

FOR MORE FREE NOTES AND EBOOKS VISIT https://t.me/Latestneetpgnotes CLICK THIS PAGE TO JOIN!!!!

https://t.me/Latestneetpgnotes